



Abdomen And Pelvic Ultrasound Scan Report

Name : Mr.Radha Krishna K.N

Date : 09/02/2022

Ref by : Bajaj Allianz

Age / Gender : 41 Years / Male

Liver : Normal in size, shape and echotexture. No focal lesion seen.

No intrahepatic biliary dilatation seen.MPV & CBD is normal.

Gall Bladder: GB is normal. Normal in wall thickness, No abnormal intraluminal echoes.

Pancreas : Normal in size and echotexture. No focal lesions.Pancreatic duct appears normal.

Spleen : Normal in size, shape and echotexture.

Kidneys : Both Kidney's are normal in size, shape and position.

No Calculi / Hydronephrosis seen. Cortico-Medullary differentiation is good.

Right Kidney : 107 x 18 mm Left Kidney : 111 x 18 mm

Urinary Bladder : Normal in contour and wall thickness with clear contents.


Post Void = Nil.

Prostate : Measures **32 x 33 x 32 mm, Volume = 17 cc** Normal in size, shape and echotexture.

IMPRESSION:

- Normal Sonologic Study.

Dr. Mohan Kumar
Consultant Radiologist


BANGALORE DIAGNOSTICS CENTRE
198, 12th Main, 3rd Block
Rajajinagar, Bangalore-560 010



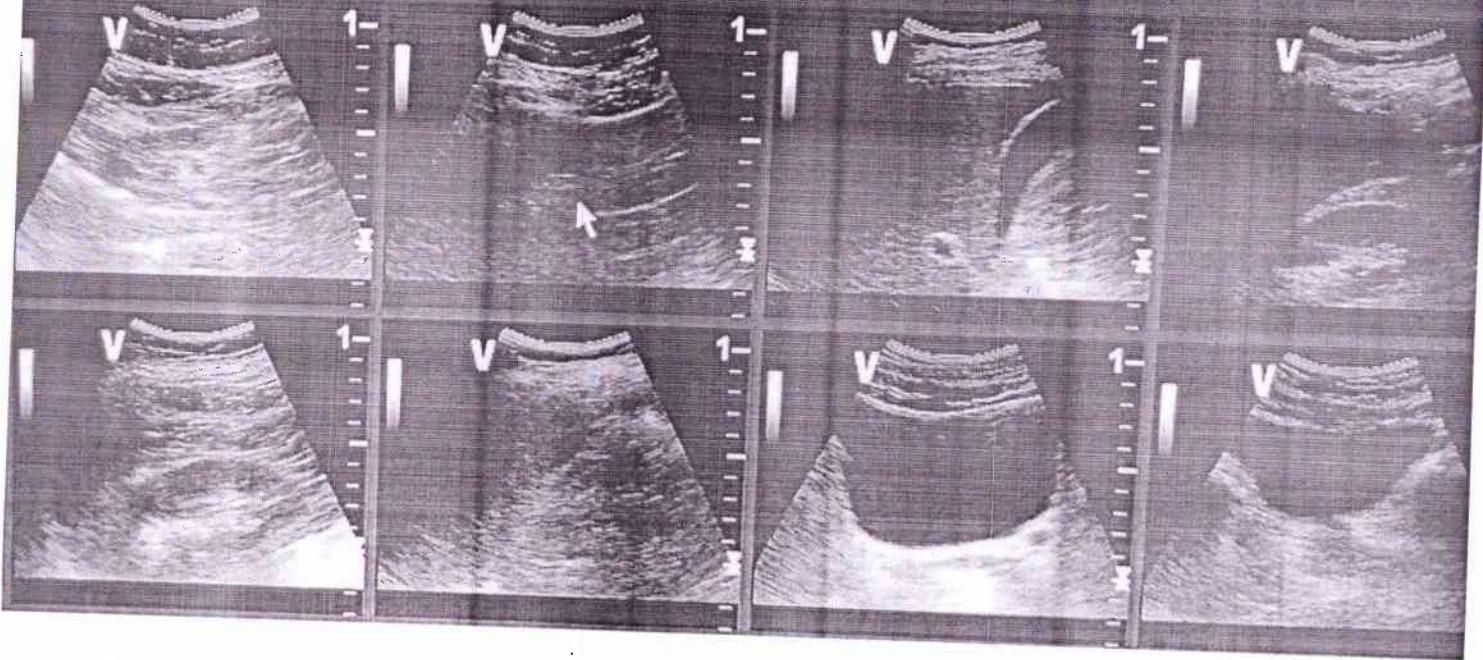
GE Healthcare

09/02/22 10:14:40 AM

USR

RADHAKRISHNA K N 31,

922022-3B



BANGALORE DIAGNOSTICS CENTRE
196, 12th Main, 3rd Block
Rajajinagar, Bangalore-560 010