

LETTER OF APPROVAL / RECOMMENDATION

To,

The Coordinator,
Mediwheel (Arcofemi Healthcare Limited)
Helpline number: 011- 41195959

Dear Sir / Madam,

Sub: Annual Health Checkup for the employees of Bank of Baroda

This is to inform you that the following employee wishes to avail the facility of Cashless Annual Health Checkup provided by you in terms of our agreement.

PARTICULARS	EMPLOYEE DETAILS
NAME	MRS. ROUT SHASWATI
EC NO.	116775
DESIGNATION	SINGLE WINDOW OPERATOR A
PLACE OF WORK	DUTTAPUKUR
BIRTHDATE	22-07-1987
PROPOSED DATE OF HEALTH CHECKUP	03-03-2022
BOOKING REFERENCE NO.	21M116775100012454E

This letter of approval / recommendation is valid if submitted along with copy of the Bank of Baroda employee id card. This approval is valid from **23-02-2022** till **31-03-2022** The list of medical tests to be conducted is provided in the annexure to this letter. Please note that the said health checkup is a **cashless facility** as per our tie up arrangement. We request you to attend to the health checkup requirement of our employee and accord your top priority and best resources in this regard. The EC Number and the booking reference number as given in the above table shall be mentioned in the invoice, invariably.

We solicit your co-operation in this regard

Yours faithfully,

Sd/-

Chief General Manager
HRM Department
Bank of Baroda

(Note: This is a computer generated letter. No Signature required. For any clarification, please contact Mediwheel (Arcofemi Healthcare Limited))

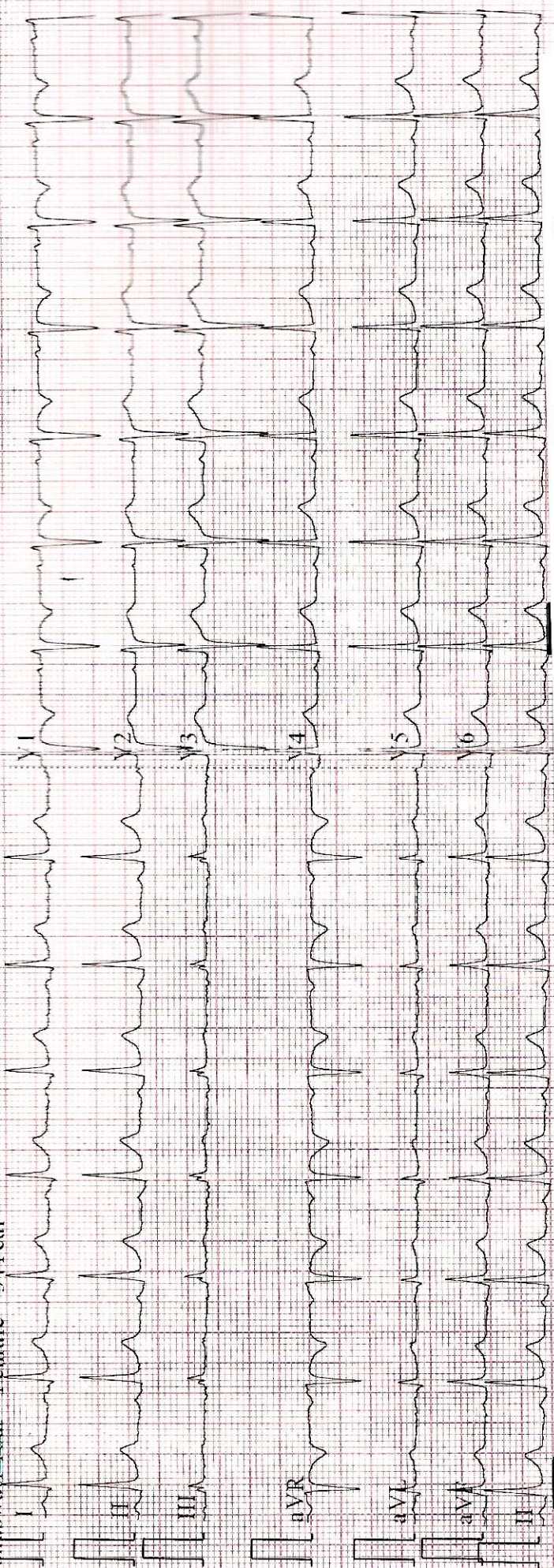


Patho Treat Diagnostic Centre
& Poly Clinic
75 Dum Dum Road, Kol-700074
Phone No. - (033) 2360 3641

ID: 658
shaswati routh Female 34Year

EPL

03-03-2022 12:23:54



03-03-2022 12:23:54
HR : 85 bpm
P : 94 ms
PR : 139 ms
QRS : 94 ms
QT/QTc : 357.427 ms
P/QRS/T : 34.51/44
RV5/AVI : 1.136/0.995 mV

ID: 658
shaswati routh
Female 34Year

0.67 25Hz 25mm/s 10mm/mV 2*5s - Ir ♥88 I-I

Diagnosis Information:
Sinus Rhythm
Normal ECG

DR. Ujjwal Das
MBBS (Hons), MD (Med),
DM (Cardio), DNB (Cardio),
Reg. No. - 64909 (MBCI)

Report Confirmed by:



Patho Treat

TEST REPORT

DIAGNOSTIC CENTRE & POLYCLINIC

Medical Fitness Certificate

Regd. Off - 75, Dum Dum Road, Kolkata - 700 074

Phone No.: (033) 2560 3641 / 3642, (033) 6526 0026, (Infront of Motijheel College of Commerce)

"It is certified that Mr./Ms. Shalwati Koul Employee ID: _____ employed with
M/s. BANK OF BARODA has been carefully examined by me on date 03/03/22

DOB	22/07/83	Age (Yrs)	34	Sex (M/F)	MB No.														
-----	----------	-----------	----	-----------	--------	--	--	--	--	--	--	--	--	--	--	--	--	--	--

S N	Investigation Details	Summary of Investigation
1	BLOOD EXAMINATION	normal
2	Urine Routine Examination	normal
3	OTHERS	normal
4	Height, Weight/ BMI	159cm, 76 kg
5	BP/ Pulse	90/70, 82/min

Based on medical examination conducted he/she is (Pls tick (✓) appropriate box)

FIT to work (Found free from any infectious or communicable diseases)

NOT FIT to work

Name of the Medical Examiner: _____

Signature of Medical Examiner: Dr. Debasis Banerjee

Stamp Of Medical Examiner: M.B.B.S., MD (Medicine)

Registration Number: Reg. No. 42951

FINAL IMPRESSION:

Physically fit & healthy.

Patho Treat Diagnostic Centre
& Polyclinic
Hospital Road, Kol-700074
Phone No. (033) 2560 3641



Patho Treat

DIAGNOSTIC CENTRE & POLYCLINIC

TEST REPORT

Regd. Off : 75, Dum Dum Road, Kolkata - 700 074

Phone No.: (033) 2560 3641 / 3642, (033) 6526 0026, (Infront of Motijheel College of Commerce)


ID NO: B/03/04
PT.NAME= MRS SHASWATI ROUT
SEX: F AGE: 34 YRS

DATE OF RECEIPT: 03.03.2022

DATE OF REPORT: 03.03.2022

Reference By: BANK OF BARODA

<u>INVESTIGATION</u>	<u>RESULT / UNIT</u>	<u>REFERENCE VALUE</u>
TOTAL TRI-iodothyronin (T3)	92ng/dl	(60 – 181)
TOTAL THYROXINE (T4)	5.1ng/dl	(4.5 – 10.9)
THYROID STIMULATING HORMONE	3.50nl/ml	(0.35 – 5.5)


DR. SUMANA MAJUMDAR
M.B.B.S., MD
(PATHOLOGIST)



Patho Treat

DIAGNOSTIC CENTRE & POLYCLINIC

TEST REPORT

Regd. Off : 75, Dum Dum Road, Kolkata - 700 074
Phone No.: (033) 2560 3641 / 3642, (033) 6526 0026, (Infront of Motijheel College of Commerce)

ID NO: B/03/04
PT.NAME= MRS SHASWATI ROUT
SEX: F AGE: 34 YRS


DATE OF RECEIPT: 03.03.2022

DATE OF REPORT: 03.03.2022

Reference By: BANK OF BARODA

HEMATOLOGY

<u>TEST</u>		<u>RESULT</u>
"ABO" GROUPING	:	"A"
Rh (D) FACTOR	:	POSITIVE



DR.SUMANA MAJUMDAR
M.B.B.S.,MD
(PATHOLOGIST)



Patho Treat

TEST REPORT

DIAGNOSTIC CENTRE & POLYCLINIC

Regd. Off : 75, Dum Dum Road, Kolkata - 700 074

Phone No.: (033) 2560 3641 / 3642, (033) 6526 0026, (Infront of Motijheel College of Commerce)

DATE OF RECEIPT: 03.03.2022

ID NO: B/03/04

PT.NAME= MRS SHASWATI ROUT

SEX: F AGE: 34 YRS

DATE OF REPORT: 03.03.2022

Reference By: BANK OF BARODA

REPORT ON EXAMINATION OF BLOOD

INVESTIGATION

RESULT & UNIT

GLYCOSYLATED HB%
(HBA1C)

5.04%

REFERENCE RANGE :-

Below 6.0 % ----- Normal Value
6.0 % - 7.0 % ----- Good Control
7.0 % - 8.0 % ----- Fair Control
8.0 % - 10.0 % ----- Unsatisfactory Control
Above 10.0 % ----- Poor Control

DR.SUMANA MAJUMDAR
M.B.B.S.,MD
(PATHOLOGIST)



Patho Treat

DIAGNOSTIC CENTRE & POLYCLINIC

TEST REPORT

Regd. Off : 75, Dum Dum Road, Kolkata - 700 074

Phone No.: (033) 2560 3641 / 3642, (033) 6526 0026, (Infront of Motijheel College of Commerce)

ID NO: B/03/04

PT.NAME= MRS SHASWATI ROUT

SEX: F AGE: 34 YRS

DATE OF RECEIPT: 03.03.2022

DATE OF REPORT: 03.03.2022

Reference By: BANK OF BARODA

DIGITAL X-RAY CHEST PA VIEW

- No focal lesion seen bilateral lung fields.
- Domes of diaphragms are smooth and regular.
- Costophrenic angles are clear.
- Cardiac shadow is normal.
- Mediastinum is central.
- Both hila are normal in position and density.
- Bony thorax shows no abnormality.

IMPRESSION

Normal Study.

DR. VIMLESH JI VIMAL
M.B.B.S.,MD,
DMRD (Radiologist)



Patho Treat

DIAGNOSTIC CENTRE & POLYCLINIC

TEST REPORT

Regd. Off : 75, Dum Dum Road, Kolkata - 700 074

Phone No.: (033) 2560 3641 / 3642, (033) 6526 0026, (Infront of Motijheel College of Commerce)

ID NO: B/03/04

PT.NAME= MRS SHASWATI ROUT

SEX: F AGE: 34 YRS

DATE OF RECEIPT: 03.03.2022

DATE OF REPORT: 03.03.2022

Reference By: BANK OF BARODA

REPORT ON THE BIO-CHEMICAL EXAMINATION

<u>TEST</u>	<u>RESULT</u>	<u>UNIT</u>	<u>NORMAL VALUE</u>
TRIGLYCERIDES	85.00	mg / dL	(65.00 - 170.00)
HDL - CHOLESTEROL	43.00	mg / dL	(30 . 00 - 55 . 00)
LDL - CHOLESTEROL (By Enzymatic Method at 370C)	112.00	mg / dL	(up to 150.00)
VLDL	17.0	mg / dL	(16 . 00 - 40 . 00)
CHOLESTEROL - TOTAL	172.00	mg / dL	(150 . 00 - 250 . 00)
LDL/HDL	2.6:1		

DR.SUMANA MAJUMDAR
M.B.B.S.,MD(PATHOLOGIST)



Patho Treat

DIAGNOSTIC CENTRE & POLYCLINIC

TEST REPORT

Regd. Off : 75, Dum Dum Road, Kolkata - 700 074

Phone No.: (033) 2560 3641 / 3642, (033) 6526 0026, (Infront of Motijheel College of Commerce)

ID NO: B/03/04

PT.NAME= MRS SHASWATI ROUT

SEX: F AGE: 34 YRS

DATE OF RECEIPT: 03.03.2022


DATE OF REPORT: 03.03.2022

Reference By: BANK OF BARODA

REPORT ON THE BIO - CHEMICAL EXAMINATION

<u>TEST</u>	<u>RESULT</u>	<u>UNIT</u>	<u>NORMAL VALUE</u>
SUGAR (F)	78.0	mg / dl	(70 - 110)
SUGAR (PP)	97.0	mg / dl	(110 - 140)
CREATININE	0.79	mg / dL	(0.70 - 1.20)
URIC - ACID	4.3	mg/dL	(Male - 3.4 - 7.0 Female - 2.4 - 5.7)
BUN	11.2	mg/dL	(5 - 23)

DR. SUMANA MAJUMDAR
M.B.B.S., MD
(PATHOLOGIST)



Patho Treat

DIAGNOSTIC CENTRE & POLYCLINIC

TEST REPORT

Regd. Off : 75, Dum Dum Road, Kolkata - 700 074

Phone No.: (033) 2560 3641 / 3642, (033) 6526 0026, (Infront of Motijheel College of Commerce)

ID NO: B/03/04

PT.NAME= MRS SHASWATI ROUT

SEX: F AGE: 34 YRS

DATE OF RECEIPT: 03.03.2022

DATE OF REPORT: 03.03.2022

Reference By: BANK OF BARODA

PHYSICAL EXAMINATION

Quantity 40 ml
Colour straw
Appearance slightly hazy
Sediment Nil
Sp. Gravity 1.010

CHEMICAL EXAMINATION

Reaction Acidic
Albumin Nil
Proteins Nil
Sugar Nil
Acetone Negative
Bile Salt Negative
Bile Pigment Negative
Phosphates Nil
Chyle -----
Occult Blood Negative
Urobilinogen -----
Bence-Jones -----

MICROSCOPIC EXAMINATION

Unorganized Examination
Crystals Not Found
Organized Constituents
Not Found

CASTS

Cellular (Pus Cell) Not Found
Hyaline Not Found
Granular Not Found
Fatty Not Found
Others Not Found

CELLS

Epithelial Cells (2 - 3 / HPF)
Pus Cells (0 - 1 / HPF)
R.B.C. Not Found
Others Nil
Bacteria Not Found

DR. SUMANA MAJUMDAR
M.B.B.S., MD
(PATHOLOGIST)



Patho Treat

DIAGNOSTIC CENTRE & POLYCLINIC

TEST REPORT

Regd. Off : 75, Dum Dum Road, Kolkata - 700 074

Phone No.: (033) 2560 3641 / 3642, (033) 6526 0026, (Infront of Motijheel College of Commerce)

DATE OF RECEIPT: 03.03.2022

ID NO: B/03/04

PT.NAME= MRS SHASWATI ROUT

DATE OF REPORT: 03.03.2022

SEX: F AGE: 34 YRS

Reference By: BANK OF BARODA

TEST	RESULT & UNIT	NORMAL RANGE
HAEMOGLOBIN (Cyanmethemoglobin Method)	12.3 gm %	Male :- (13 - 18) Female :- (11.5 - 16.5)
Total R.B.C	4.15 Million / cmm	3.5 - 6.5 Million / cmm
Total W.B.C	3700 / cmm	(4000 - 11000) / cmm
Platelets Count	1.77 lac / cmm	(1.5 - 4.0) lac / cmm

Differential Count W.B.C

TEST	RESULT & UNIT	NORMAL RANGE
Neutrophils	73%	(40 - 80) %
Lymphocytes	22%	(20 - 40) %
Eosinophils	03 %	(2 - 10) %
Monocytes	02 %	(1 - 6) %
Basophils	00 %	(0 - 2) %

Hemogram

TEST	RESULT & UNIT	NORMAL RANGE
PCV	37%	(38 - 54) %
MCV	86.4 Um ³	(77 - 93) Um ³
MCH	29.6 g %	(26 - 32) g %
MCHC	34.3 %	(27 - 35) %

Morphology of RBC : Normocytic, Normochromic.

ESR(Westergern Method): 1st Hour-22/mm (MALE : 0 -14 FEMALE : 0-20)

DR.SUMANA MAJUMDAR
M.B.B.S.,MD
(PATHOLOGIST)



Patho Treat

DIAGNOSTIC CENTRE & POLYCLINIC

TEST REPORT

Regd. Off : 75, Dum Dum Road, Kolkata - 700 074

Phone No.: (033) 2560 3641 / 3642, (033) 6526 0026, (Infront of Motijheel College of Commerce)

DATE OF RECEIPT: 03.03.2022

ID NO: B/03/04

PT.NAME= MRS SHASWATI ROUT

SEX: F AGE: 34 YRS

DATE OF REPORT: 03.03.2022

Reference By: BANK OF BARODA

REPORT ON THE BIO - CHEMICAL EXAMINATION

INVESTIGATION	RESULT	UNIT	NORMAL RANGE
Bilirubin Total	0.52	mg / dL	(0.2 - 1.2)
Bilirubin Conjugated	0.23	mg / dL	(0.05 - 0.25)
Bilirubin Unconjugated	0.29	mg / dL	(0.2 - 0.75)
S.G.P.T/ ALT	28	U/L	(9 - 43)
S.G.O.T/ AST	22	U/L	(Male : 10 - 35) (Female : 10-31)
ALP (Alkaline Phosphatase)	117	U/L	(Up to 5Yrs. F: 48-406, M: 75-389 5-10 Yrs.F: 96-332, M: 93-362 11- 15 Yrs. F: 52-162, M:74-390 16- 19 Yrs.F: 47-119, M:52-171 Adult - F: 35-141, M: 40-129)
Total Protein	6.89	g / dL	(6.0 - 8.0)
Albumin	4.35	gm / dL	(3.5 - 5.2)
Globulin	2.54	g / dL	(2.8 - 4.3)
A G Ratio	1.71		
GAMMA GT	27	U/L	Up to 40 U/L

DR.SUMANA MAJUMDAR
M.B.B.S.,MD
(PATHOLOGIST)



Patho Treat

DIAGNOSTIC CENTRE & POLYCLINIC

TEST REPORT

Regd. Off : 75, Dum Dum Road, Kolkata - 700 074

Phone No.: (033) 2560 3641 / 3642, (033) 6526 0026, (Infront of Motijheel College of Commerce)

Associate Code : D1

Received On : 03/03/2022

Patient's Name : MRS SHASWATI ROUT

Reported On : 04/03/2022

ID Number : 11840/C-664

Age/Sex : 34Y/FEMALE

Referred By : SELF

Sample Source :

ClinicPro/gebjan
Page 1 of 1

ULTRASONOGRAPHY OF WHOLE ABDOMEN

LIVER

It is enlarged 17.2 cm in size. Parenchymal echotexture is normal. No focal parenchymal lesion is seen. Intrahepatic biliary radicles not dilated.

PORTA

PV : Normal in diameter with echofree lumen. PV measures 0.9 cm.

CD : Normal in caliber. No calculus is seen up to traceable part. CD measures 0.3 cm.

GALL BLADDER

Gall bladder is normally distended with normal wall thickness. No intraluminal calculus is noted.

PANCREAS

Normal in size . **Echogenicity raised.** No focal S.O.L. or calcification noted. Main pancreatic duct – not dilated.

SPLEEN

Spleen is normal in size (9.0 cm). Parenchymal echotexture is normal. Splenic vein at its hilum is not dilated.

KIDNEY

Both kidneys are normal in size , shape and outline. Cortical echogenicity appears normal on both sides. Central echocomplexes are normal. Corticomedullary differentiation is maintained.

A large cortical cyst 8.1 x 7.9 cm noted at upper pole of right kidney.

DR. S. PAL
M.B.B.S.(KOL).
APUSC-CBET(WBUHS)
CONSULTANT SONOLOGIST

DR. V. J. VIMAL
MD,DMRD
CONSULTANT RADIOLOGIST

Checked by.....

Patho Treat

DIAGNOSTIC CENTRE & POLYCLINIC

TEST REPORT

Regd. Off : 75, Dum Dum Road, Kolkata - 700 074

Phone No.: (033) 2560 3641 / 3642, (033) 6526 0026, (Infront of Motijheel College of Commerce)

URETERS

Not visualized hence not dilated.

URINARY BLADDER

Urinary bladder is well distended and normal in wall thickness. No intraluminal pathology or intramural mass lesion seen.

UTERUS

Uterus is anteverted and normal in size 7.5 x3.4 x5.2 cm. Myometrial echotexture appears homogeneous . Endometrial cavity in midline location and no focal lesion seen.

OVARIES

Both ovaries are normal in size , shape and echotexture.

POUCH OF DOUGLAS

No free fluid is visible in the pouch of douglas.

**IMPRESSION : 1. Hepatomegaly
2. Fatty pancreas.
3.Right renal large cortical cyst.**

DR. S. PAL
M.B.B.S.(KOL),
APUSC-CBET(WBUHS)
CONSULTANT SONOLOGIST


DR. V. J. VIMAL
MD,DMRD
CONSULTANT RADIOLOGIST

Checked by.....