

28/5/22



Monika Yadav B2y1F

Routine eye check up
Nil systemic illness.

O/E unaided 6/6, NB
Color vision - NAD
Aut seg - B/L NAD

Imp: Eye examination - WM



Ado
Annual eye check up

hgf
28/5/22

Consultant
Department of Ophthalmology
SIGNATURE HOSPITAL
Gurugram

(This is only professional opinion and not the diagnosis. Please correlate clinically)

Sector 37-D, BPTP, Dwarka Express Way, Gurugram, Hry.,

Ph.: 0124-6034444, 8526000000, E-mail : signaturehospital@gmail.com, Web.: www.thesignaturehealthcare.com

PARK GROUP OF HOSPITAL : ★ West Delhi ★ South Delhi ★ Gurugram ★ Faridabad ★ Panipat ★ Karnal

| | |
|--|--|
| Patient Name : Mrs. MONIKA YADAV | UHID : 15004 |
| Age / Gender : 32 Years 8 Months 28Days / Female | IPNO : |
| Referred By : Dr. CMO | Registered : 28/09/2022/ 9.08 AM |
| Req.No : 22227781 | Sample Collection Dt & Tm : 28/09/2022/ 10.47 AM |
| Sample ID : 2237323 | Sample Receiving Dt & Tm : 28/09/2022/ 10:47 AM |
| Patient Type : OPD | Report Released on : 28/09/2022/ 11.42 AM |
| Bed No : | |

HEMATOLOGY


Complete Blood Count -CBC(HB\TLC\PCV\RBC\Platelet)

| TEST NAME | RESULT | UNITS | BIOLOGICAL | SPECIMEN TYPE |
|----------------------------------|-------------|---------------|--------------------|---------------|
| TEST METHOD | | | REFERENCE INTERVAL | |
| Hemoglobin (Hb) (Colorimetry) | 10.8 | gm/dl | 11.5 - 15.0 | WHOLE BLOOD |
| TLC (Electrical Impedence) | 7540 | cell/cumm | 4500 - 11000 | EDTA WHOLE |
| DIFFERENTIAL COUNT | | | | |
| Neutrophils (Flow Cytometry) | 60 | % | 40 - 75 | EDTA WHOLE |
| Lymphocytes (Flow Cytometry) | 30 | % | 20 - 45 | EDTA WHOLE |
| Monocytes (Flow Cytometry) | 06 | % | 1 - 10 | EDTA WHOLE |
| Eosinophil (Flow Cytometry) | 04 | % | 1 - 6 | EDTA WHOLE |
| Basophil | 00 | % | 0 - 1 | |
| RBC (Electrical Impedence) | 4.5 | millions/cumm | 4.2 - 5.4 | EDTA WHOLE |

-**** End of Report ****-

Lab Technician Dr.NishaTiwari
(MD.Microbiology)


 Dr. Neha Gupta
 MBBS,MD(Pathology)
 (Consultant Pathologist)


 Dr. Shreya Pradhan
 MBBS,MD(Microbiology)
 (Consultant Microbiologist)

(This is only professional opinion and not the diagnosis. Please correlate clinically)

Sector 37-D, BPTP, Dwarka Express Way, Gurugram, Hry.,

Ph.: 0124-6034444, 8526000000, E-mail : signaturehospital@gmail.com, Web.: www.thesignaturehealthcare.com

PARK GROUP OF HOSPITAL : ★ West Delhi ★ South Delhi ★ Gurugram ★ Faridabad ★ Panipat ★ Karnal

| | |
|--|--|
| Patient Name : Mrs. MONIKA YADAV | UHID : 15004 |
| Age / Gender : 32 Years 8 Months 28Days / Female | IPNO : |
| Referred By : Dr. CMO | Registered : 28/09/2022/ 9.08 AM |
| Req.No : 22227781 | Sample Collection Dt & Tm : 28/09/2022/ 10.47 AM |
| Sample ID : 2237323 | Sample Receiving Dt & Tm : 28/09/2022/ 10:47 AM |
| Patient Type : OPD | Report Released on : 28/09/2022/ 11.42 AM |
| Bed No : | |


HEMATOLOGY


| | | | | |
|--|------|---------------|-----------|------------|
| PCV (Electrical Impedance Calculation) | 36.8 | % | 36 - 46 | EDTA WHOLE |
| MCV (Electrical Impedance Calculation) | 80.8 | f | 76 - 96 | EDTA WHOLE |
| MCH (Electrical Impedance Calculation) | 23.7 | pg | 27 - 34 | EDTA WHOLE |
| MCHC (Electrical Impedance Calculation) | 29.3 | gm/dl | 30 - 36 | EDTA WHOLE |
| RDW | 15.3 | % | 11 - 16 | |
| PLATELETE COUNT (Electrical Impedance) | 356 | 1000/microLit | 150 - 450 | EDTA WHOLE |

-**** End of Report ****-

Lab Technician

Dr.NishaTiwari
(MD.Microbiology)


 Dr. Neha Gupta
 MBBS,MD(Pathology)
 (Consultant Pathologist)


 Dr. Shreya Pradhan
 MBBS,MD(Microbiology)
 (Consultant Microbiologist)

Page 2 of 2

(This is only professional opinion and not the diagnosis. Please correlate clinically)

Sector 37-D, BPTP, Dwarka Express Way, Gurugram, Hry.,

Ph.: 0124-6034444, 8526000000, E-mail : signaturehospital@gmail.com, Web.: www.thesignaturehealthcare.com
PARK GROUP OF HOSPITAL : ★ West Delhi ★ South Delhi ★ Gurugram ★ Faridabad ★ Panipat ★ Karnal

| | |
|--|--|
| Patient Name : Mrs. MONIKA YADAV | UHID : 15004 |
| Age / Gender : 32 Years 8 Months 28Days / Female | IPNO : |
| Referred By : Dr. CMO | Registered : 28/09/2022/ 9.08 AM |
| Req.No : 22227781 | Sample Collection Dt & Tm : 28/09/2022/ 10.47 AM |
| Sample ID : 2237323 | Sample Receiving Dt & Tm : 28/09/2022/ 10:47 AM |
| Patient Type : OPD | Report Released on : 28/09/2022/ 12.27 PM |
| Bed No : | |


BIOCHEMISTRY


Renal Profile


| TEST NAME | RESULT | UNITS | REFERENCE INTERVAL | BIOLOGICAL SPECIMEN TYPE |
|----------------------------------|--------|--------|--------------------|--------------------------|
| TEST METHOD | | | | |
| BLOOD UREA (Urease UV/GLDH) | 15 | mg/dl | 13 - 45 | SERUM |
| SERUM CREATININE (Jaffe Rate) | 0.7 | mg/dl | 0.6 - 1.2 | SERUM |
| URIC ACID (Enzymatic/Uricase) | 3.2 | mg/dl | 2.5 - 6.8 | SERUM |
| ELECTROLYTES | | | | |
| SODIUM (ISE-Indirect) | 144 | mmol/L | 132 - 150 | SERUM |
| POTASSIUM (ISE-Indirect) | 4.4 | mmol/L | 3.5 - 5.5 | SERUM |

-**** End of Report ****

Lab Technician


 Dr. Nisha Tiwari
 (MD. Microbiology)


 Dr. Neha Gupta
 MBBS, MD(Pathology)
 (Consultant Pathologist)


 Dr. Shreya Pradhan
 MBBS, MD(Microbiology)
 (Consultant Microbiologist)

Page 1 of 2

(This is only professional opinion and not the diagnosis. Please correlate clinically)

Sector 37-D, BPTP, Dwarka Express Way, Gurugram, Hry.,

Ph.: 0124-6034444, 8526000000, E-mail : signaturehospital@gmail.com, Web.: www.thesignaturehealthcare.com

PARK GROUP OF HOSPITAL : ★ West Delhi ★ South Delhi ★ Gurugram ★ Faridabad ★ Panipat ★ Karnal

| | |
|--|--|
| Patient Name : Mrs. MONIKA YADAV | UHID : 15004 |
| Age / Gender : 32 Years 8 Months 28Days / Female | IPNO : |
| Referred By : Dr. CMO | Registered : 28/09/2022/ 9.08 AM |
| Req.No : 22227781 | Sample Collection Dt & Tm : 28/09/2022/ 10.47 AM |
| Sample ID : 2237323 | Sample Receiving Dt & Tm : 28/09/2022/ 10:47 AM |
| Patient Type : OPD | Report Released on : 28/09/2022/ 12.28 PM |
| Bed No : | |

BIOCHEMISTRY

Liver Function Test Profile


| TEST NAME | RESULT | UNITS | BIOLOGICAL REFERENCE INTERVAL | SPECIMEN TYPE |
|--|--------|-------|----------------------------------|---------------|
| TEST METHOD | | | | |
| <u>BILIRUBIN TOTAL AND DIRECT</u> | | | | |
| BILIRUBIN TOTAL (Diazonium Salt) | 0.5 | mg/dl | 0.1 - 1.2 | SERUM |
| BILIRUBIN DIRECT (Diazonium Salt) | 0.3 | mg/dl | 00 - 0.3 | SERUM |
| BILIRUBIN INDIRECT (CALCULATED) | 0.2 | md/dl | 0 - 0.9 | |
| SGOT/AST (UV-KINETIC) | 15 | U/l | 0 - 45 | SERUM |
| SGPT/ALT (UV-KINETIC) | 14 | U/l | 0 - 45 | SERUM |
| ALKALINE PHOSPHATASE (ALP) (Kinetic) | 62 | U/l | 39 - 118 | SERUM |

-**** End of Report ****-

Lab Technician

Dr.NishaTiwari
(MD.Microbiology)


 Dr. Neha Gupta
 MBBS,MD(Pathology)
 (Consultant Pathologist)


 Dr. Shreya Pradhan
 MBBS,MD(Microbiology)
 (Consultant Microbiologist)

(This is only professional opinion and not the diagnosis. Please correlate clinically)

Sector 37-D, BPTP, Dwarka Express Way, Gurugram, Hry.,

Ph.: 0124-6034444, 8526000000, E-mail : signaturehospital@gmail.com, Web.: www.thesignaturehealthcare.com

PARK GROUP OF HOSPITAL : ★ West Delhi ★ South Delhi ★ Gurugram ★ Faridabad ★ Panipat ★ Karnal

| | |
|--|--|
| Patient Name : Mrs. MONIKA YADAV | UHID : 15004 |
| Age / Gender : 32 Years 8 Months 28Days / Female | IPNO : |
| Referred By : Dr. CMO | Registered : 28/09/2022/ 9.08 AM |
| Req.No : 22227781 | Sample Collection Dt & Tm : 28/09/2022/ 10.47 AM |
| Sample ID : 2237323 | Sample Receiving Dt & Tm : 28/09/2022/ 10:47 AM |
| Patient Type : OPD | Report Released on : 28/09/2022/ 12.28 PM |
| Bed No : | |

BIOCHEMISTRY

PROTEINS


| | | | | |
|---------------------------|------|-------|-----------|-------|
| TOTAL PROTEIN (Biuret) | 6.5 | g/dl | 6.0 - 8.3 | SERUM |
| ALBUMIN (BCG- DYE) | 4.2 | g/dl | 3.2 - 5.0 | SERUM |
| GLOBULIN Calculated | 2.3 | gm/dl | 1.5 - 3.6 | |
| A/G RATIO Calculated | 1.83 | | 0.9 - 2.0 | |

-**** End of Report ****-

Lab Technician

Dr.NishaTiwari
(MD.Microbiology)


 Dr. Neha Gupta
 MBBS,MD(Pathology)
 (Consultant Pathologist)


 Dr. Shreya Pradhan
 MBBS,MD(Microbiology)
 (Consultant Microbiologist)

(This is only professional opinion and not the diagnosis. Please correlate clinically)

Sector 37-D, BPTP, Dwarka Express Way, Gurugram, Hry.,

Ph.: 0124-6034444, 8526000000, E-mail : signaturehospital@gmail.com, Web.: www.thesignaturehealthcare.com

PARK GROUP OF HOSPITAL : ★ West Delhi ★ South Delhi ★ Gurugram ★ Faridabad ★ Panipat ★ Karnal

| | |
|--|--|
| Patient Name : Mrs. MONIKA YADAV | UHID : 15004 |
| Age / Gender : 32 Years 8 Months 28Days / Female | IPNO : |
| Referred By : Dr. CMO | Registered : 28/09/2022/ 9.08 AM |
| Req.No : 22227781 | Sample Collection Dt & Tm : 28/09/2022/ 10.47 AM |
| Sample ID : 2237323 | Sample Receiving Dt & Tm : 28/09/2022/ 10:47 AM |
| Patient Type : OPD | Report Released on : 28/09/2022/ 12.30 PM |
| Bed No : | |

CLINICAL PATHOLOGY


Urine Routine And Microscopy.


| TEST NAME | RESULT | UNITS | REFERENCE INTERVAL | BIOLOGICAL SPECIMEN TYPE |
|---------------------------------------|-------------|-------|--------------------|--------------------------|
| TEST METHOD | | | | |
| QUANTITY | 30 ML | | | |
| COLOUR | PALE YELLOW | | | |
| TURBIDITY | CLEAR | | | |
| SPECIFIC GRAVITY (Bromthymol Blue) | 1.030 | | 1.003-1.030 | Urine |
| PH (Chromatography) | 5.5 | | 4.7-7.0 | Urine |

-**** End of Report ****-

Lab Technician


 Dr.NishaTiwari
 (MD.Microbiology)


 Dr. Neha Gupta
 MBBS,MD(Pathology)
 (Consultant Pathologist)


 Dr. Shreya Pradhan
 MBBS,MD(Microbiology)
 (Consultant Microbiologist)

(This is only professional opinion and not the diagnosis. Please correlate clinically)

Sector 37-D, BPTP, Dwarka Express Way, Gurugram, Hry.,

Ph.: 0124-6034444, 8526000000, E-mail : signaturehospital@gmail.com, Web.: www.thesignaturehealthcare.com

PARK GROUP OF HOSPITAL : ★ West Delhi ★ South Delhi ★ Gurugram ★ Faridabad ★ Panipat ★ Karnal

| | |
|--|--|
| Patient Name : Mrs. MONIKA YADAV | UHID : 15004 |
| Age / Gender : 32 Years 8 Months 28Days / Female | IPNO : |
| Referred By : Dr. CMO | Registered : 28/09/2022/ 9.08 AM |
| Req.No : 22227781 | Sample Collection Dt & Tm : 28/09/2022/ 10.47 AM |
| Sample ID : 2237323 | Sample Receiving Dt & Tm : 28/09/2022/ 10:47 AM |
| Patient Type : OPD | Report Released on : 28/09/2022/ 12.30 PM |
| Bed No : | |

CLINICAL PATHOLOGY

MICROSCOPIC EXAMINATION - URINE

| | | | | |
|--------------------------------------|------------|------|-------|-------|
| PUS CELLS (Microscopic) | 1-2 | /HPF | 0 - 3 | Urine |
| RBC- Urine (Per Oxidase Reaction) | FULL FIELD | /HPF | NIL | Urine |
| EPITHELIAL CELLS | 0-1 | /HPF | 0 - 5 | |
| CAST | NIL | | NIL | |
| CRYSTALS | NIL | | NIL | |
| BACTERIA | NIL | | | |
| OTHERS | NIL | | | |

COMMENTS: Actual numerical values for WBCs, RBCs and Epithelial cells are not defined and must be correlated clinically.


Test Methods: Reagent strip analysis and urine sediment microscopy.

Reagent strip / chemical analysis are based on: pH-Double Indicator principle; Specific gravity Ion exchange method; Glucose Glucose oxidase-peroxidase/Benedicts; Protein Acid-base indicator/Sulfosalicylic acid; Urobilinogen Coupling reaction/Ehrlichsreaction, Bilirubin Coupling reaction, Ketones Nitroprusside method/Rotheras test.

-**** End of Report ****-

Lab Technician Dr.NishaTiwari
(MD.Microbiology)


 Dr. Neha Gupta
 MBBS,MD(Pathology)
 (Consultant Pathologist)


 Dr. Shreya Pradhan
 MBBS,MD(Microbiology)
 (Consultant Microbiologist)

(This is only professional opinion and not the diagnosis. Please correlate clinically)

Sector 37-D, BPTP, Dwarka Express Way, Gurugram, Hry.,

Ph.: 0124-6034444, 8526000000, E-mail : signaturehospital@gmail.com, Web.: www.thesignaturehealthcare.com

PARK GROUP OF HOSPITAL : ★ West Delhi ★ South Delhi ★ Gurugram ★ Faridabad ★ Panipat ★ Karnal

DEPARTMENT OF IMAGING & INTERVENTIONAL RADIOLOGY, THE SIGNATURE HOSPITAL

| | |
|--------------------|------------------|
| NAME: MONIKA YADAV | DATE: 28/09/2022 |
| AGE: 32 Y/F | MR NO.: 15004 |

USG WHOLE ABDOMEN

LIVER: is normal in size and echotexture. No evidence of any focal lesion or IHBR dilation is present. Portal vein and CBD are normal in caliber at porta.

GALL BLADDER is well distended and lumen is echofree. Wall thickness is normal. No pericholecystic fluid is seen.

SPLEEN: is normal in size and echotexture. No focal lesion is seen.

PANCREAS: is normal in size and echotexture. Peripancreatic fat planes are clear. MPD is not dilated.

RIGHT KIDNEY: is normal in size and position and outline corticomedullary differentiation is maintained. There is no evidence of any focal lesion / calculus / backpressure changes.

LEFT KIDNEY: is normal in size and position and outline corticomedullary differentiation is maintained. There is no evidence of any focal lesion / calculus / backpressure changes.

URINARY BLADDER is well distended. Wall thickness is normal. No evidence of any focal lesion.

UTERUS: is normal in size, shape and position. Myometrial echotexture is normal. There is no focal lesion. **Heterogeneous echogenicity of endometrium noted without any vascularity (Needs clinical correlation in view of recent MTP history)**

OVARIES: Both ovaries are normal.

Cul de Sac is clear.

IMPRESSION:

- No significant abnormality.

Please correlate clinically



Dr. Gura
Senior Consultant
Diagnostic & Interventional Radiology

(This is only professional opinion and not the diagnosis. Please correlate clinically)

Sector 37-D, BPTP, Dwarka Express Way, Gurugram, Hry.,

Ph.: 0124-6034444, 8526000000, E-mail : signaturehospital@gmail.com, Web.: www.thesignaturehealthcare.com

PARK GROUP OF HOSPITAL : ★ West Delhi ★ South Delhi ★ Gurugram ★ Faridabad ★ Panipat ★ Karnal

| | | | |
|---|-------|-------|-------------|
| UID | 15004 | Date: | 28 Sep 2022 |
| Name/Age/Sex : MONIKA YADAV 32Yr / Female | | | |
| Treating Dr. : | | | |

X-RAY CHEST PA VIEW

FINDINGS:

The lungs on the either side show equal translucency.

The peripheral pulmonary vasculature is normal.

No focal lung lesion is seen.

Bilateral CP angles are normal.

Both hila are normal in size, have equal density and bear normal relationship.

The heart and trachea are central in position and no mediastinal abnormality is visible.

The cardiac size is normal.

The domes of the diaphragms are normal in position, and show smooth outline.

IMPRESSION:

No significant abnormality detected.

Suggest clinical correlation and follow up.



Dr. Avinash Rathod (DMRD)
Consultant Radiologist
Reg. No. 2011/05/1616/1616

(This is only professional opinion and not the diagnosis. Please correlate clinically)

Sector 37-D, BPTP, Dwarka Express Way, Gurugram, Hry.,

Ph.: 0124-6034444, 8526000000, E-mail : signaturehospital@gmail.com, Web.: www.thesignaturehealthcare.com
PARK GROUP OF HOSPITAL : ★ West Delhi ★ South Delhi ★ Gurugram ★ Faridabad ★ Panipat ★ Karnal

TRANSTHORACIC ECHO- DOPPLER REPORT

| | |
|-------------------------|------------------|
| NAME - MRS.MONIKA YADAV | AGE/SEX -32/F |
| MR. NO. - 15004 | DATE - 28/9/2022 |

M-MODE / 2-D DESCRIPTION

- ❖ **Left Ventricle:** No regional wall motion abnormality. LVEF ~ 60 %.
- ❖ **Left Atrium:** Normal.
- ❖ **Right atrium:** It is Normal Sized.
- ❖ **Right ventricle:** It is Normal Sized. RV Systolic Function is Normal.
- ❖ **Aortic valve:** Aortic Cusps are Normal.
- ❖ **Mitral valve:** It Appears Normal.
- ❖ **Tricuspid valve:** It Appears Normal.
- ❖ **Pulmonic valve:** It Appears Normal.
- ❖ **Main pulmonary artery & its branches:** Appear Normal.
- ❖ **Pericardium:** No Pericardial Effusion Seen
- ❖ **Inter atrial septum:** It is Intact.
- ❖ **Inter ventricular septum:** It is Intact.
- ❖ **IVC:** It is Normal in Size, collapsing & Respiratory Variability.
- ❖ **Clot / Vegetation:** No Intracardiac Clot, Vegetation.

Measurements (mm):

| LEFT HEART | | | RIGHT HEART | | |
|--------------------------------------|-------------------------|---------------------------------|-----------------------------|-------------------------|--------------------|
| | Observed values (mm) | Normal values | | Observed values (mm) | Normal values |
| Aortic root | 30 | 20-36 (22mm/M ²) | IVC size | - | 17-21mm |
| Aortic valve opening | | 15-26 (mm/M ²) | IVC respiratory variability | | >50% |
| LA size | 32 | 19-40 (mm/M ²) | RA size | - | <18cm ² |
| LA volume index (ml/M ²) | | <34 ml/M ² | | | |
| LVID(D) | 50 | (ED=37-56) | RV basal | | 24-42mm |
| LVID(S) | 40 | | RV mid cavity | - | 20-35mm |
| IVS(D) | 9 | (ED=6-12) | RV longitudinal | - | 56-86mm |
| | | | RVOT proximal | - | 18-33mm |
| PW(D) | 11 | (ED=5-10) | TAPSE | - | >15mm |
| | | | RV free wall thickness | - | <5mm |
| LVEF(%) | 60% | 55%-70% | RVEF | | >44% |

(This is only professional opinion and not the diagnosis. Please correlate clinically)

Sector 37-D, BPTP, Dwarka Express Way, Gurugram, Hry.,

Doppler velocities (cm/sec)

| Aortic valve | | Pulmonary valve | |
|--------------|-----|--------------------------|-----|
| Max/ Vel | 119 | Max velocity | 111 |
| Max/ PG | | Max PG | |
| Mitral valve | | Tricuspid valve | |
| E | 62 | Max Velocity | |
| A | 63 | PASP | - |
| DT | - | E/E' (>6) | - |
| E/A | - | S' Velocity (>10cm2/sec) | - |

Regurgitation

| MR | | TR | |
|----------|-----|----------|-----|
| Severity | Nil | Severity | Nil |
| AR | | PR | |
| Severity | Nil | Severity | Nil |

Final Interpretation:

- No regional wall motion abnormality. LVEF ~ 60 %
- Normal Cardiac Chamber Dimension.
- No MR, No AR. No TR.
- Grade I Diastolic dysfunction.
- No Vegetation, Pericardial Effusion.



Dr. AJAY DUA
 DNB (Medicine), DNB (Cardiology)
 Sr. Consultant Interventional Cardiology

(This is only professional opinion and not the diagnosis. Please correlate clinically)

Sector 37-D, BPTP, Dwarka Express Way, Gurugram, Hry.,

Ph.: 0124-6034444, 8526000000, E-mail : signaturehospital@gmail.com, Web.: www.thesignaturehealthcare.com

PARK GROUP OF HOSPITAL : ★ West Delhi ★ South Delhi ★ Gurugram ★ Faridabad ★ Panipat ★ Kamal

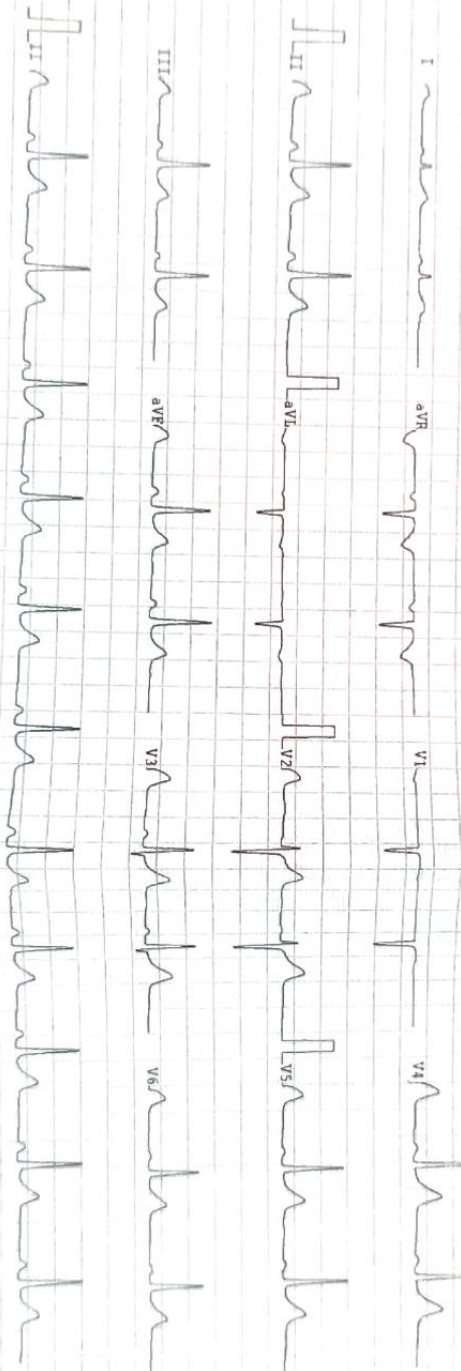SEC 37D GURURAM

PATIENT INFORMATION

ID: 22673 CASE:
NAME:
AGE: GENDER: SMOKER:
HEIGHT: CMS WEIGHT: KG
DOCTOR: DR AJAY DUA
REF:
DATE/TIME: 28/09/2022 09:09:17

ECG SETTINGS

PRINTING MODE: AUTO 3+1
GAIN: mm/mV: 10
SPEED: mm/Sec: 25
FILTER Hz: 0.05 - 35
NOTCH/BLC: ON/OFF
RHYTHM LEAD: II



OBSERVATIONS

HEART RATE: 69 bpm
R-R: 876 ms
P-R: 148 ms
P-DUR: 96 ms
QRS: 70 ms
T-DUR: 230ms
ST-DUR: 62 ms
QT: 362 ms
QTc: 376 ms
P-AXIS: 72°
R-AXIS: 80°
T-AXIS: 69°
ST-AXIS: 93°

REMARKS

INTEL