

Patient's name	: HEMANTKUMAR P TRIPATHI	Age/Sex	: 44 Years/Male
Referred by	: Self	Reg. No	: 7007
Date	: 03/02/2022	Mobile	: 9909007079
Patient's Id	: HT59	Ref ID.	:

Fitness Certificate

GENERAL EXAMINATION

Height (cms) : 176

Weight (kgs) : 93.0

Blood Pressure : 130/90 mmHg

Pulse : 79/Min

No Clubbing/Cynosis/Pallor/Pedel Oedem

Systemic Examination:


Cardio vascular System - S1,S2 Normal, No Murmur

Respiratory system - AEBE

Central Nervous System - No FND

Abdomen - Soft, Non Tender, No Organomegaly

----- End of Report -----


Dr Jinen M Shah
DNB (Medicine)FCCS (USA)

This is an electronically authenticated report.
Note: (LL-Very Low, L-Low, HH-Very High)

Approved On : 03/02/2022 4:53:00 PM
Generated On : 03/02/2022 17:02





ए.स. नं. 92529
E.C. No.

नाम (Name) : हेमन्तकुमार पी. त्रिपाठी / HEMANTKUMAR P. TRIPATHI
पदनाम (Designation) : Officer JM-1
धारक के हस्ताक्षर (Signature of Holder)



[Handwritten signature]


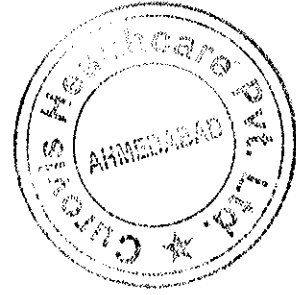
22/07/2021
जारी करने की तारीख
Date of issue

[Handwritten signature]

जारीकर्ता प्राधिकारी
Issuing Authority

[Handwritten signature]

Dr. Jinen M. Shah
DNB (Medicine) FCCS (USA)
Reg. No. G-20693



Patient's name : HEMANTKUMAR P TRIPATHI Age/Sex : 44 Years/Male
 Referred by : Self Reg. No : 7007
 Date : 03/02/2022 Mobile : 9909007079
 Patient's Id : HT59 Ref ID. :

HEMOGRAM REPORT

Performed on 5-Part Fully Auto Hematology Analyzer SIEMENS ADVIA 2120i)

Test	Result	Unit	Biological Reference Interval
Sample Type:	EDTA		
Haemoglobin:	15.3	gm/dL	13.5 - 18.0
Total WBC Count:	7000	/microlitre	4000 - 10500
Platelets Count:	326000	/microlitre	1,50,000 - 4,50,000
Differential Count:			
Neutrophils:	61	%	40-80
Lymphocytes:	36	%	20-40
Eosinophils:	02	%	Upto 6
Monocytes:	01	%	2-10
Basophils:	00	%	<1-2
RBC indices:			
RBC Count:	4.70	*10 ⁶ /microL	4.5 - 5.5
HCT:	46.7	%	40 - 50
MCV:	99.4	fL	83-101
MCH:	32.6	pg	27-32
MCHC:	32.8	%	31.5-34.5
RDW:	12.5	%	11.6 - 14.0
Erythrocytes Sedimentation Rate(ESR): (By AUTO ESR-10, USA)			
ESR 1st Hr:	05	mm	2 - 15 mm in 1Hr.
Thick Smear Preparation:			
Haemoparasite:	Malarial parasites are not seen.		
Peripheral Smear Examination:			
RBCs:	Normocytic & Normochromic.		
Platelet:	Platelet adequate & normal on smear.		

J.P. Panchal

Dr. Jaimin Panchal
MBBS,MD(Pathology)



This is an electronically authenticated report.
 Note:((LL-Very Low, L-Low, HH-Very High)

Patient's name	: HEMANTKUMAR P TRIPATHI	Age/Sex	: 44 Years/Male
Referred by	: Self	Reg. No	: 7007
Date	: 03/02/2022	Mobile	: 9909007079
Patient's Id	: HT59	Ref ID.	:

Approved On : 03/02/2022 15:18:00
Generated On : 03/02/2022 16:40



Patient's name : HEMANTKUMAR P TRIPATHI Age/Sex : 44 Years/Male
Referred by : Self Reg. No : 7007
Date : 03/02/2022 Mobile : 9909007079
Patient's Id : HT59 Ref ID. :

GLYCOSYLATED HAEMOGLOBIN (HbA1C) ESTIMATION

Test	Result	Unit	Biological Reference Interval
Sample Type: EDTA			
Glycosylated Haemoglobin (HbA1C)	5.40	%	Pre-Diabetic (Adult): 5.7 - 6.4 Diabetic (Adult): >6.5 Therapeutic goal for glycemic control: <7.0
Mean Blood Glucose Level (An average of 2 -3 Months)	108.28		

Method : HPLC on D-10, Bio-Rad,USA

INTERPRETATION:

- * Blood sample can be drawn at any time. Fasting is not required.
- * Reflects average blood sugar levels for the 2 to 3 months period before the test.
- * Provides information for evaluating diabetic treatment modalities and tracks control of blood glucose of particular value in diabetic children, diabetics in whom the renal threshold for glucose is abnormal, unstable insulin dependent diabetics where blood sugars vary markedly from day to day.
- * High value in poorly controlled DM and moves towards normal in patients with optimal control.



Dr. Jaimin Panchal
MBBS,MD(Pathology)

-----End of Report-----

This is an electronically authenticated report.
Note:((LL-Very Low, L-Low, HH-Very High)

Approved On : 03/02/2022 15:18:00
Generated On : 03/02/2022 16:40



'B' Block, Mondeal Business Park, Near Gurudwara, Bodakdev, S.G. Highway, Ahmedabad-380054, Gujarat.

Patient's name : HEMANTKUMAR P TRIPATHI Age/Sex : 44 Years/Male
Referred by : Self Reg. No : 7007
Date : 03/02/2022 Mobile : 9909007079
Patient's Id : HT59 Ref ID. :

BLOOD GROUP

Sample Type: EDTA
ABO Group : "O"
Rh Type : Positive

BLOOD GLUCOSE LEVEL

Test	Result	Unit	Biological Reference Interval
Sample Type:	Flouride		
Fasting Blood Glucose (Hexokinase) Collection Time:	78.3	mg/dl	70-110
Collection Time:			
Post Prandial Blood Glucose (2 Hrs) (Hexokinase)	95.9	mg/dl	80-140
Post Prandial Urine Glucose (2 Hrs)	Nil		

Tests Performed on Fully Auto DRY Chemistry Analyzer VITROS-250




Dr. Jaimin Panchal

MBBS,MD(Pathology)

----- End of Report -----

This is an electronically authenticated report.
Note: (LL-Very Low, L-Low, HH-Very High)

Approved On : 03/02/2022 15:18:00
Generated On : 03/02/2022 16:40



Patient's name : HEMANTKUMAR P TRIPATHI Age/Sex : 44 Years/Male
 Referred by : Self Reg. No : 7007
 Date : 03/02/2022 Mobile : 9909007079
 Patient's Id : HT59 Ref ID. :

LIPID PROFILE

(Performed on Semi Auto Chemistry Analyzer BeneSphera)

Test	Result	Unit	Biological Reference Interval
Sample Type: Fasting Serum			
S.Cholesterol (Oxidase Peroxidase)	206	mg/dL	< 200 Desirable 200-239 Boderline High > 240 High
S.HDLC (Direct) (Phosphotungstic Acid)	40.8	mg/dL	< 40 Low > 60 High
S.Triglyceride (GPO-POD)	274.8	mg/dL	< 150 mg/dl Normal 150-199 Boderline High 200-499 High > 500 Very High
S.VLDL (Calculated)	54.96	mg/dL	10-40 Normal
S.LDLC (Calculated)	110.24	mg/dL	< 100 Optimal 100-129 Near to above optimal 130-159 Boderline high 160-189 High >190 Very High
S.Cholesterol / HDLC Ratio (Calculated)	5.05		< 4 Normal 4-6 Borderline 6-8 Risklevel > 8 High Risk
S.LDLC / HDLC Ratio (Calculated)	2.7		< 3 Normal 3-4 Borderline 4-6 Risk Level > 6 High Risk
Cholesterol / HDLC Ratio (Calculated)	5.05		< 3.5 Normal
Triglyceride / HDLC Ratio (Calculated)	6.74		< 2 Normal > 4 Risk Level > 6 High Risk
Non HDLC (Calculated)	165.2		< 130 Normal 130 - 159 Near Normal 160 - 189 Borderline 190 - 219 Risklevel > 220 High Risk



J. Panchal

Dr. Jaimin Panchal

MBBS,MD(Pathology)

End of Report

This is an electronically authenticated report.
 Note:((LL-Very Low, L-Low, HH-Very High)

Approved On : 03/02/2022 15:18:00
 Generated On : 03/02/2022 16:40

Patient's name : HEMANTKUMAR P TRIPATHI Age/Sex : 44 Years/Male
 Referred by : Self Reg. No : 7007
 Date : 03/02/2022 Mobile : 9909007079
 Patient's Id : HT59 Ref ID. :

LIVER FUNCTION TEST

(Performed on Fully Auto DRY Chemistry Analyzer VITROS-250)

Test	Result	Unit	Biological Reference Interval
Sample Type: Serum			
S.Bilirubin			
Total Bilirubin	0.69	mg/dl	0 - 1.2
(Azobilirubin)			
Conjugated Bilirubin	0.12	mg/dl	0 - 0.4
(Dual Wavelength spectrophotometric)			
Unconjugated Bilirubin	0.57	mg/dl	0.0 - 1.1
(Dual Wavelength spectrophotometric)			
S.G.P.T. (ALT)	29.6	IU/L	0 - 49
(Kinetic with Pyridoxal 5-Phosphate)			
S.G.O.T. (AST)	31.6	IU/L	Up to 46
(Kinetic with Pyridoxal 5-Phosphate)			
S.ALP (Alkaline Phosphatase)	164.7	U/L	80 - 306
(4-Nitrophenyl phosphate)			
S.Protein			
Total Protein	7.27	gm/dl	6.3 - 8.2
(Biuret)			
Albumin	4.63	gm/dl	3.5 - 5.2
(BCG)			
Globulin	2.64	gm/dl	1.9 - 3.5
(Calculated)			
Albumin Globulin Ratio	1.75		
S.GammaGT	80.1	IU/L	15-73
(L-Gamma Glutamyl-4-Nitroanilide)			

SERUM LDH LEVEL


Test	Result	Unit	Biological Reference Interval
Sample Type: Serum			
LDH Activity (Lactate Dehydrogenase):	205.38	U/L	120 - 246
Pyruvate to lactate Kinetic Method			

#Tests Performed on Fully Auto DRY Chemistry Analyzer VITROS-250

J.P. Panchal

Dr. Jaimin Panchal

MBBS,MD(Pathology)



This is an electronically authenticated report.
 Note:(LL-Very Low, L-Low, HH-Very High)

Approved On : 03/02/2022 15:18:00
 Generated On : 03/02/2022 16:40

'B' Block, Mondeal Business Park, Near Gurudwara, Bodakdev, S.G. Highway, Ahmedabad-380054, Gujarat.

Patient's name : HEMANTKUMAR P TRIPATHI Age/Sex : 44 Years/Male
Referred by : Self Reg. No : 7007
Date : 03/02/2022 Mobile : 9909007079
Patient's Id : HT59 Ref ID. :

RENAL FUNCTION TEST

(Performed on Fully Auto DRY Chemistry Analyzer VITROS-250)

Test	Result	Unit	Biological Reference Interval
Sample Type: Serum			
S.Urea (Urease with indicator dye)	24.7	mg/dl	Male: 19.6-43.6 Female: 15.2-37.0
S.Creatinine (Enzymatic)	0.96	mg/dL	0.55 - 1.30
S.Uric Acid (Uricase)	6.35	mg/dL	Male: 3.5-8.5 Female: 2.5-6.2

Prostate Specific Antigen

(Carried out on miniVIDAS, Biomerieux)

Test	Result	Unit	Reference Interval
S.PSA : (Prostate Specific Antigen)	0.370	ng/ml	M : Healthy Male upto 4.00


Dr. Jaimin Panchal

MBBS,MD(Pathology)

----- End of Report -----

This is an electronically authenticated report.
Note:((LL-Very Low, L-Low, HH-Very High)

Approved On : 03/02/2022 15:18:00
Generated On : 03/02/2022 16:41



Patient's name : HEMANTKUMAR P TRIPATHI Age/Sex : 44 Years/Male
Referred by : Self Reg. No : 7007
Date : 03/02/2022 Mobile : 9909007079
Patient's Id : HT59 Ref ID. :

THYROID FUNCTION TEST
(by CLIA on SIEMENS ADVIA Centaur XP)


Test	Result	Unit	Biological Reference Interval
Sample Type: Serum			
S.T3 (Total Triiodothyronine by CLIA)	1.02	ng/mL	1 - 23 Months: 1.17 - 2.39 2 - 12 Years: 1.05 - 2.07 13 - 20 Years: 0.86 - 1.92 Adult: 0.6 - 1.81
S.T4 (Total Thyroxine by CLIA)	9.20	mcg/dL	3.2 - 12.6
S.TSH (Thyroid Stimulating Hormone by CLIA)	1.197	microU/mL	0 -12 Yrs: 0.77 - 5.64 12-19 Yrs: 0.75-3.69 19-100 Yrs: 0.35 -5.50

Dr. Jaimin Panchal
MBBS,MD(Pathology)

----- End of Report -----

This is an electronically authenticated report.
Note:((LL-Very Low, L-Low, HH-Very High)

Approved On : 03/02/2022 15:18:00
Generated On : 03/02/2022 16:41



Patient's name : HEMANTKUMAR P TRIPATHI Age/Sex : 44 Years/Male
 Referred by : Self Reg. No : 7007
 Date : 03/02/2022 Mobile : 9909007079
 Patient's Id : HT59 Ref ID. :

URINE ROUTINE ANALYSIS

Sample Type: Fresh Urine

Physical Examination
(Naked Eye Observation)

	Result	Biological Ref. Value
Amount	20 ml	>10 ml
Colour	Pale Yellow	Pale Yellow
Appearance	Clear	Clear

Chemical Examination

pH (Dip stick)	6.0	4.5-8.0
Specific Gravity (Bromothymol Blue)	1.020	1.002-1.030
Albumin (Tetrabromophenol)	Present (+)	Absent
Glucose (Specific Glucose Oxidase/Peroxidase)	Absent	Absent
Bilirubin (Azo-coupling reaction)	Absent	Absent
Acetone (Sodium Nitroprusside Reaction)	Absent	Absent
Urobilinogen (Modified Ehrlich Reaction)	Absent	Absent
Nitrites (Diazolization Reaction)	Absent	Absent

Microscopic Examination


(After centrifugation at 1500 RPM for 10min./hpf)

Pus Cells(WBCs)	1-2	Absent
Red Blood Cells(RBCs)	2-4	Absent
Epithelial cells	Occasional	
T.Vaginals	Absent	Absent
Spermatozoa	Absent	Absent
Casts	Absent	Absent
Crystals	Absent	Absent
Amorphous Material	Absent	Absent

J. Panchal

Dr. Jaimin Panchal

M.B.B.S, MD(Pathology)



----- End of Report -----

This is an electronically authenticated report.

Note: (LL-Very Low, L-Low, HH-Very High)

Approved On : 03/02/2022 15:18:00

Generated On : 03/02/2022 16:41

Patient's name	: HEMANTKUMAR P TRIPATHI	Age/Sex	: 44 Years/Male
Referred by	: Self	Reg. No	: 7007
Date	: 03/02/2022	Mobile	: 9909007079
Patient's Id	: HT59	Ref ID.	:

Electrocardiogram


Findings

Normal Sinus Rhythm.


Within Normal Limit.

----- End of Report -----

This is an electronically authenticated report.
Note:((LL-Very Low, L-Low, HH-Very High)

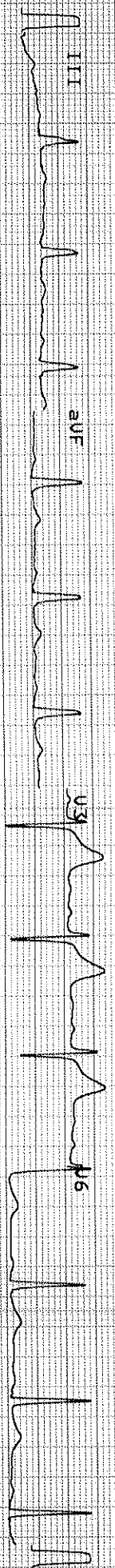
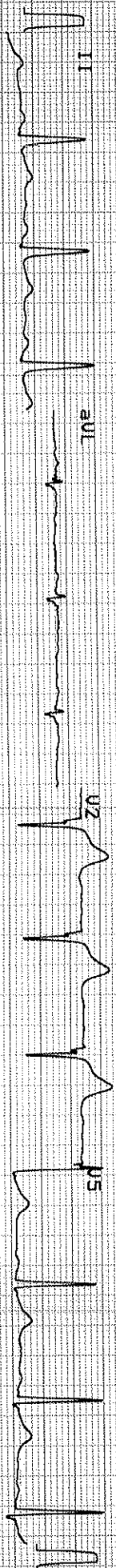Dr Jinen M Shah
DNB (Medicine) FCCS (USA)

Approved On : 03/02/2022 4:53:00 PM
Generated On : 03/02/2022 17:02



Hemantkumar
Tripathi
13
44 years / 93 kg
176 cm / 93 kg
Male

HR 79/min
Axis: P 35°, QRS 49°, T 62°
Intervals: RR 758 ms, P 96 ms, PR 148 ms, QRS 90 ms, QT 360 ms, QTc 414 ms (Bazett)
10 mm/mV



10 mm/mV

25 mm/s

0.05-25 Hz F50 S5E SBS 03.02.2022 10:10:18

CURIOUS HEALTHCARE

RT-102Plus-1.24 C

Part No.2.157017M C6 0123

088

Patient's name	: HEMANTKUMAR P TRIPATHI	Age/Sex	: 44 Years/Male
Referred by	: Self	Reg. No	: 7007
Date	: 03/02/2022	Mobile	: 9909007079
Patient's Id	: HT59	Ref ID.	:

2D Echo Colour Doppler

OBSERVATION:

2 D Echo and color flow studies were done in long and short axis, apical and Sub coastal views.

1. Normal LV size. No RWMA at rest.
2. Normal RV and RA. Mild Concentric LVH.
3. All Four valves are structurally normal.
4. Good LV systolic function. LVEF = 60%.
5. Reduced LV Compliance.
6. Trivial TR. Mild MR. No AR.
7. Mild PAH. RVSP = 38 mmHG.
8. Intact IAS and IVS.
9. No Clot, No Vegetation.
10. No pericardial effusion.

CONCLUSION

1. Normal LV size with Good LV systolic function.
2. Mild Concentric LVH . Reduced LV Compliance
3. Trivial TR with Mild PAH. Mild MR. No AR
4. No RWMA at rest.

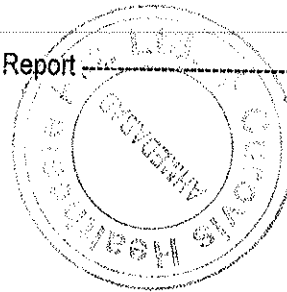
This echo doesn't rule out any kind of congenital cardiac anomalies.

----- End of Report -----


Dr Jinen M Shah
DND (Medicine) FCCS (USA)

. This is an electronically authenticated report.
Note: (LL-Very Low, L-Low, HH-Very High)

Approved On : 03/02/2022 4:53:00 PM
Generated On : 03/02/2022 17:02



Patient's name	: HEMANTKUMAR P TRIPATHI	Age/Sex	: 44 Years/Male
Referred by	: Self	Reg. No	: 7007
Date	: 03/02/2022	Mobile	: 9909007079
Patient's Id	: HT59	Ref ID.	:

X RAY CHEST PA

Both lung fields appear clear.

No evidence of any active infiltrations or consolidation.

Cardiac size appears within normal limits.

Both costo-phrenic angles appear free of fluid.

Both domes of diaphragm appear normal.


COMMENT: No significant abnormality is detected.

----- End of Report -----

Atul Patel
Dr. Atul Patel
MD Radio-Dignosis

This is an electronically authenticated report.
Note: (LL-Very Low, L-Low, HH-Very High)

Approved On : 03/02/2022 5:00:00 PM
Generated On : 03/02/2022 17:00



Patient's name	: HEMANTKUMAR P TRIPATHI	Age/Sex	: 44 Years/Male
Referred by	: Self	Reg. No	: 7007
Date	: 03/02/2022	Mobile	: 9909007079
Patient's Id	: HT59	Ref ID.	:

USG ABDOMEN

Liver appears normal in size, show homogenous parenchymal echo. No evidence of focal solid or cystic lesion seen.

No evidence of dilatation of intra-hepatic biliary or portal radicals. PV is normal in caliber.

Gall bladder is normally distended. No evidence of calculus or mass seen. Gall bladder wall thickness appears normal.

Pancreas Visualized portion appears normal in size and echopattern. No evidence of focal lesions.

Spleen appears normal in size & normal in echopattern. No evidence of focal lesions.

Both kidneys are normal in size, shape and position. C.M. differentiation on both sides is maintained. No evidence of hydronephrosis, calculus or solid mass on either side.

Urinary bladder contour is normal, No evidence of calculus or mass.

Prostate is normal in size and show homogenous echo, outline is smooth.

No evidence of para-aortic lymph adenopathy.

No evidence of dilated small bowel loops.

No evidence of free fluid in peritoneal cavity.


COMMENTS :

Fatty changes in liver.

----- End of Report -----

Atul Patel
Dr. Atul Patel

MD Radio-Dignosis



This is an electronically authenticated report.
Note: (LL-Very Low, L-Low, HH-Very High)

Approved On : 03/02/2022 5:00:00 PM
Generated On : 03/02/2022 17:00

Patient's name : HEMANTKUMAR P TRIPATHI
Referred by : Self
Date : 03/02/2022
Patient's Id : HT59
Age/Sex : 44 Years/Male
Reg. No : 7007
Mobile : 9909007079
Ref ID. :

Eye Check - Up

RIGHT EYE

SP: +0.00
CY: -0.25
AX: 14

LEFT EYE

SP: +0.50
CY: -0.75
AX: 09

	Without Glasses	With Glasses
Right Eye	6/5	N.A
Left Eye	6/5	N.A

Near Vision: Right Eye -N/6, Left Eye - N/6


Fundus Examination: Within Normal Limits.

Colour Vision: Normal

Comments: Normal

Dr.Kejal Patel
MB,DO(Ophth)

Approved On : 03/02/2022 4:07:00 PM
Generated On : 03/02/2022 17:02

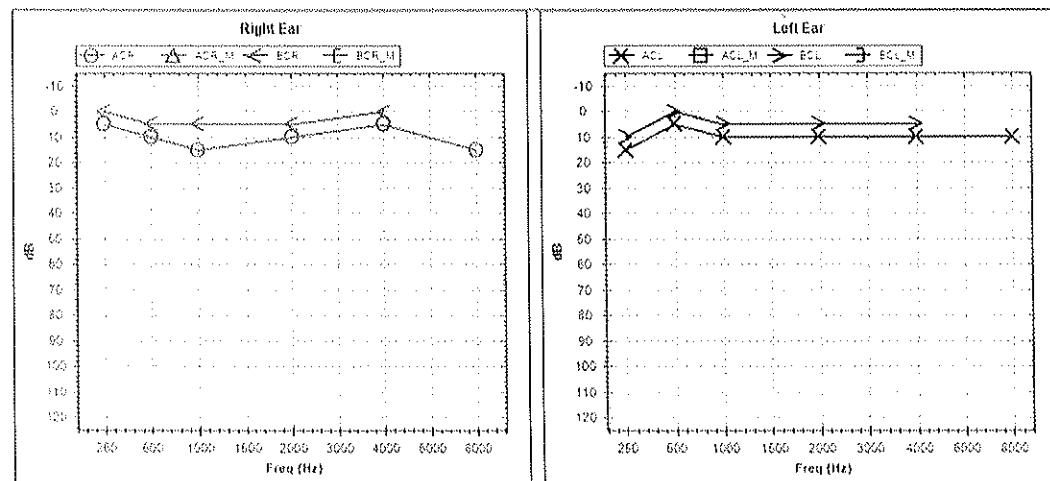


CLIENT NAME: HEMANT TRIPATHI.

AGE:- 44Y / M

DATE:- 03/02/2022.

AUDIOGRAM



EAR	MODE	Air Conduction		Bone Conduction		Colour Code	Threshold In dB	RIGHT	LEFT
		Masked	UnMasked	Masked	UnMasked				
LEFT		□	×	□	>	Blue	AIR CONDUCTION	11	11
RIGHT		△	○	□	<	Red	BONE CONDUCTION		
NO RESPONSE : Add ↓ below the respective symbols							SPEECH		

Comments:-

Bilateral Hearing Sensitivity Within Normal Limits.

