

MediWala

DR. B'S HEALTHCARE CENTRE
NATHANI HEIGHTS', B-WING,
42, MUMBAI CENTRAL (EAST)


DR. HARI CHHABLANI
M.B.B.S, P.D.C. (RESP. MEDICINE) FRCR(HA), FGDMLS
FELLOW INTENSIVE CARE
MMC REG. NO. - 91702



ഭാരത സർക്കാർ
GOVERNMENT OF INDIA



നവ്യാ മരിയ ഉമ്മൻ
Navya Maria Oommen
അച്ഛൻ : ഉമ്മൻ പി ഒ
Father : OOMMEN P O

ജനന വർഷം/Year of Birth: 1996
സ്ത്രീ / Female

8782 9063 1488



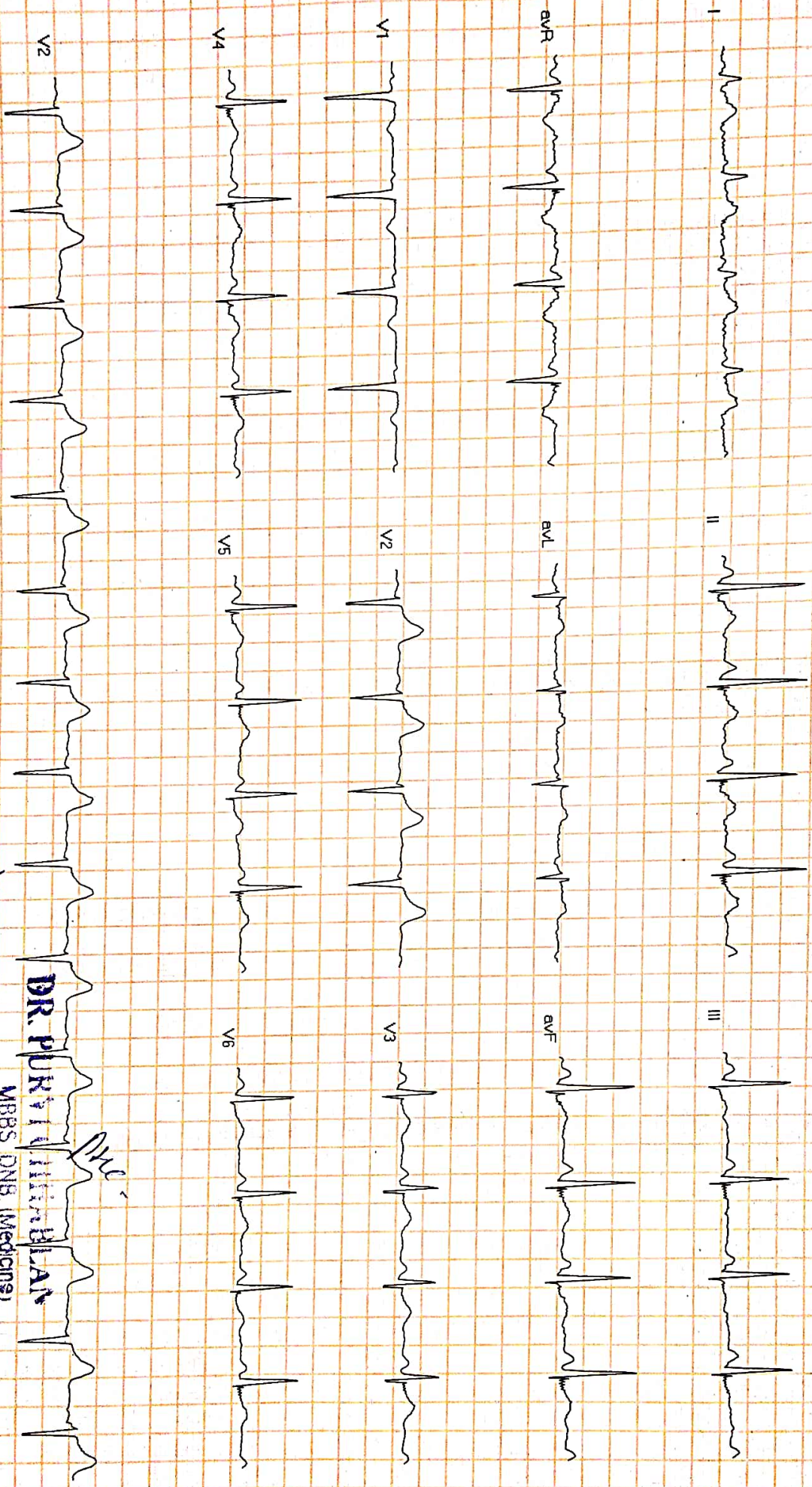
ആധാർ - സാധാരണക്കാരന്റെ അവകാശം

DR PLUS HEALTHCARE CENTRE- MUMBAI CENTRAL

ECG

1086 / NAVYA OOMMEN / 25 Yrs / F

Heart Rate : 90 bpm / Tested On : 25-Sep-21 09:12:22 / HF 0.05 Hz - LF 100 Hz / Notch 50 Hz / Sn 1.00 Cm/mV / Sw 25 - mm/s
/ Reid By: DR. HARI CHHABLANI



DR. PURVI CHHABLANI

MBBS DNB (Medicine)

Consultant Physician And Intensivist

Reg No 77696

Reported By: DR. PURVI CHHABLANI



NAME : NAVYA OOMMEN

25/F.

DATE:25/09/2021

REF BY : DR. PURVI CHHABLANI

2D-ECHO. AND COLOR DOPPLER REPORT

- NORMAL CARDIAC VALVES WITH TRIVIAL TR.
- NORMAL CARDIAC CHAMBERS
- NO E/O REGIONAL WALL MOTION ABNORMALITY. WITH NORMAL LVEF OF 64%.
- NO E/O PULMONARY HYPERTENSION. PASP 34 mmHg by TR jet.
- NO E/O LEFT VENTRICULAR HYPERTROPHY.
- NO E/O DIASTOLIC DYSFUNCTION.
- NO E/O PERICARDIAL EFFUSION.
- NO E/O INTRACARDIAC CLOT OR VEGETATIONS.
- INTACT IAS/IVS
- CONVENTIONL DOPPLER :

E TO A RATIO IS MORE THAN ONE IN LV INFLOW.


THERE IS NO GRADIENT ACROSS AV,LVOT OR RVOT

PASP FROM TR JET IS .34 mm OF Hg.

- COLOUR DOPPLER:

TRIVIAL TR

EF Slope	113	mm/sec		
Opening Amplitude	19			
Posterior leaflet				
E.P.S.S	02	mm		
Mitral valve prolapse				
Vegetations				
TRICUSPID VALVE	OBSERVED	NORMAL VALUES		
PULMONARY VALVE	OBSERVED	NORMAL VALUES		
EF Slope				
'A' Wave				
Midsystolic notch				
Flutter				
Other Findings				
AORTIC VALVE	OBSERVED	NORMAL VALUES		
Cuspal opening	16	mm		
Closure line	Central			
Eccentricity index	1			
Other Findings				
DIMENSIONS	OBSERVED	NORMAL VALUES		
1. Lvd (Diastolic)	39	26-52		
2. Lvd (Systolic)	28	24-42mm		
3. RVD (Diastolic)	16	7-23mm		
4. IVST (Diastolic)	08	6-11mm		
5. IVST (Systolic)	14			
6. LVPWT (Diastolic)	09	6-11mm		
7. LVPWT (Systolic)	15			
8. Aortic root	22	22-37mm		
9. left Atrium	28	19-40mm		
	STRUCTURE	REGURG GRADING	VELOCITY m/sec	STENOSIS GRADIENT mm/Hg
			Max mean	Peak mean
MITRAL VALVE	NORMAL	0/3	/	/
TRICUSPID VALVE	NORMAL	TRIVIAL	/	/
PULMONARY VALVE	NORMAL	0/4	/	/
AORTIC VALVE	NORMAL	0/4	/	/


DR.P.H.CHHABLANI
M.B.B.S, DNB.(MEDICINE)
CONSULTANT PHYSICIAN AND CARDIOLOGIST.

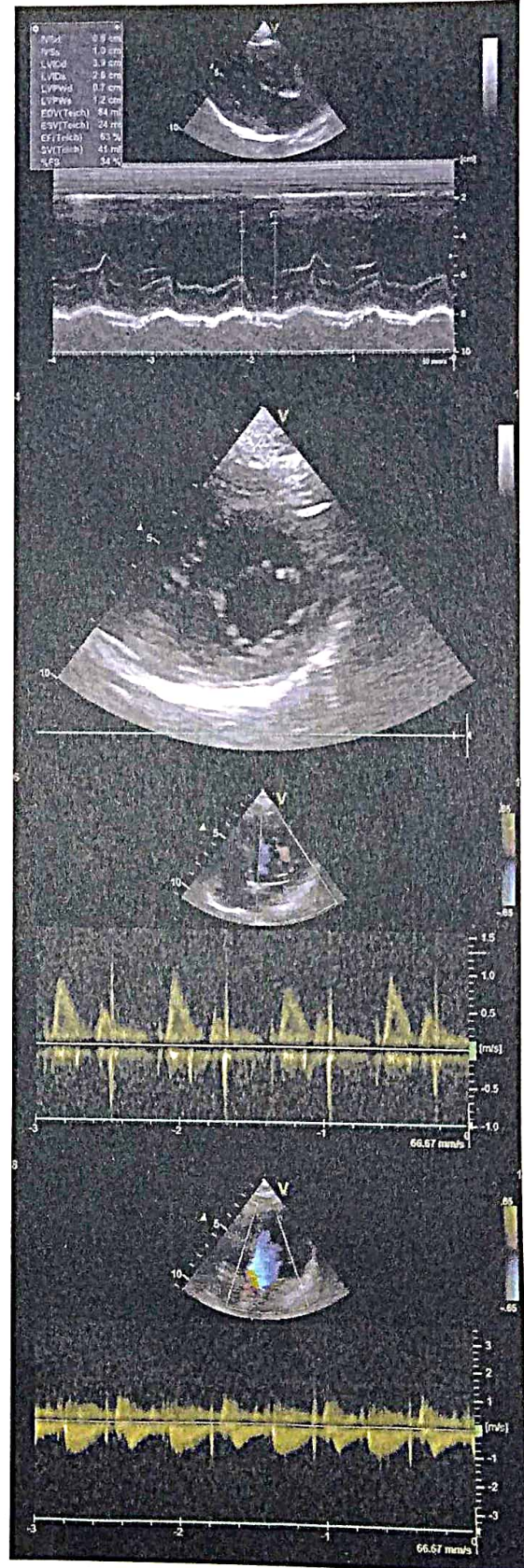
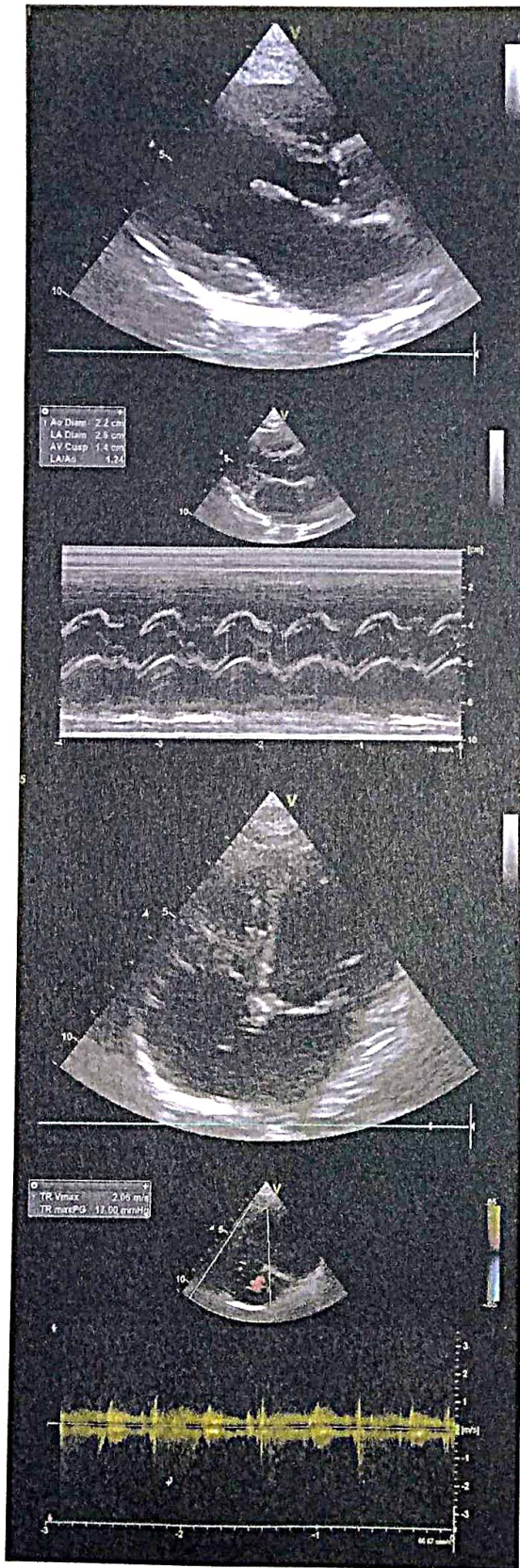
DR. PURVI CHHABLANI
MBBS, DNB. (Medicine)
Consultant Physician And Intensive
Reg No 7769F

Name NAVYA OOMMEN

Sex Female

Age 25

Date 25/09/2021





Dr-Plus Healthcare Centre

NATHANI HEIGHTS, B-Wing, Shop No. 42, Ground Floor, Opp. Mumbai Central Station (East), Mumbai - 400 008.

Patient Name	:	NAVYA OOMMEN	Sex:	FEMALE
Doctor's Name	:	DR. HARI CHHABLANI	Age:	25
Date	:	25/09/2021		

ULTRASONOGRAPHY OF THE ABDOMEN AND THE PELVIS:

The relevant sonographic findings include the following:

HEPATOBIILIARY APPARATUS

The liver is normal in size and echogenicity. No obvious focal parenchymal lesion is seen. Intrahepatic biliary radicals are not dilated.

The portal vein and the common bile duct are normal.

GALL BLADDER

The gall bladder is adequately distended. The wall thickness is normal.

No echogenic contents are noted in its lumen. There is no pericholecystic collection noted.

PANCREAS

The pancreas shows normal echogenicity and size.

No focal or diffuse lesions are noted. No evidence of calcification is noted.

SPLEEN

The spleen appears normal in size and echogenicity.

No focal or diffuse lesions are noted. No evidence of calcification is noted.

KIDNEYS

Right kidney measures : 10.6 x 4.3 cm , Left kidney measures : 10.2 x 3.9cm.

Both the kidneys appear normal in size, shape and echogenicity. Both the pelvicalyceal system is normal and

both corticomedullary differentiations are well maintained. There is no obvious focal or diffuse lesion noted.

No evidence of any calculus seen in either kidney.

URINARY BLADDER

The urinary bladder shows anechoic contents. Its wall thickness appears normal.

UTERUS

Uterus measures = 6.8 x 2.9 x 3.8 cms.

The uterus is anteverted and anteflexed and normal in size. There are no focal or diffuse lesions noted.

The endometrium appears normal (7.9 mm).

OVARIES

Both the ovaries appear normal in size.

Right ovary measures :3.9 x 4.1 Cm , Left ovary measures :3.8 x 4.0 cm

There is no obvious evidence of abdominal or pelvic lymphadenopathy or ascites noted.

No other obvious pelvic mass is seen. No probe-tenderness is noted.

IMPRESSION: No significant abnormality is detected.

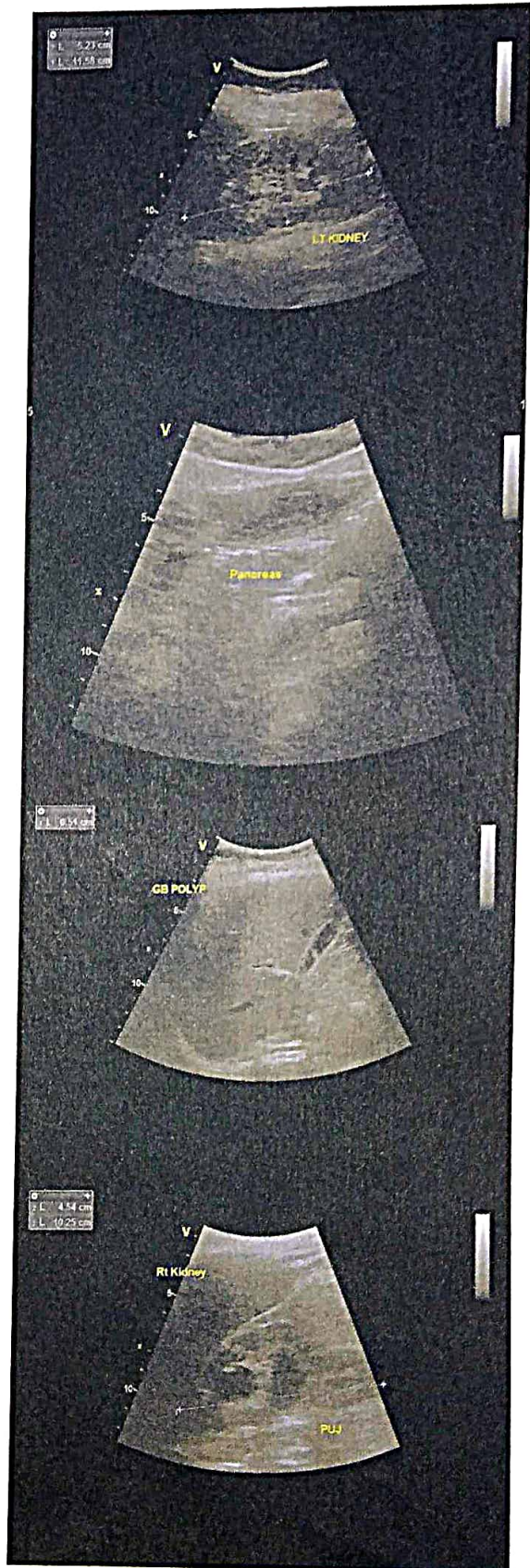
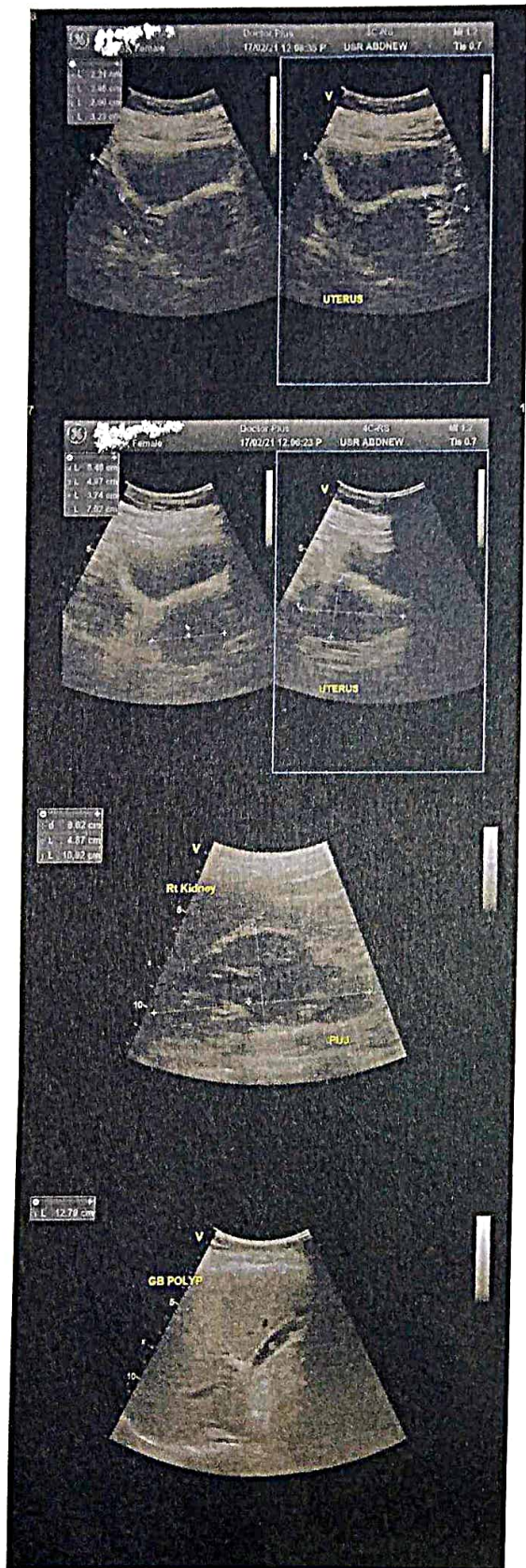Dr. Parag Jhaveri
MBBS (BOM), DMRE(BOM)
Radio-Sonologist

DR. PLUS HEALTHCARE CENTRE
NATHANI HEIGHTS', B-WING,
42, MUMBAI CENTRAL (EAST)

Name NAVYA OOMMEN

Sex Female

Age 25





Patient's Name : NAVYA OOMMEN

Report Date : 25/09/2021

Referred By Dr. : DR. HARI CHHABLANI

Age : 25 Years

Sex : FEMALE

Chest X-ray PA

- No active pulmonary lesion seen.
- Trachea and mediastinum are in midline .
- Cardiac size and configuration are within normal limits .
- Pleural cavities are clear .
- Domes of diaphragm are smooth in outline.
- Bony thorax is normal .


Radiologist

DR. A. J. MAZUMDAR

MD. DMRE, MDRD

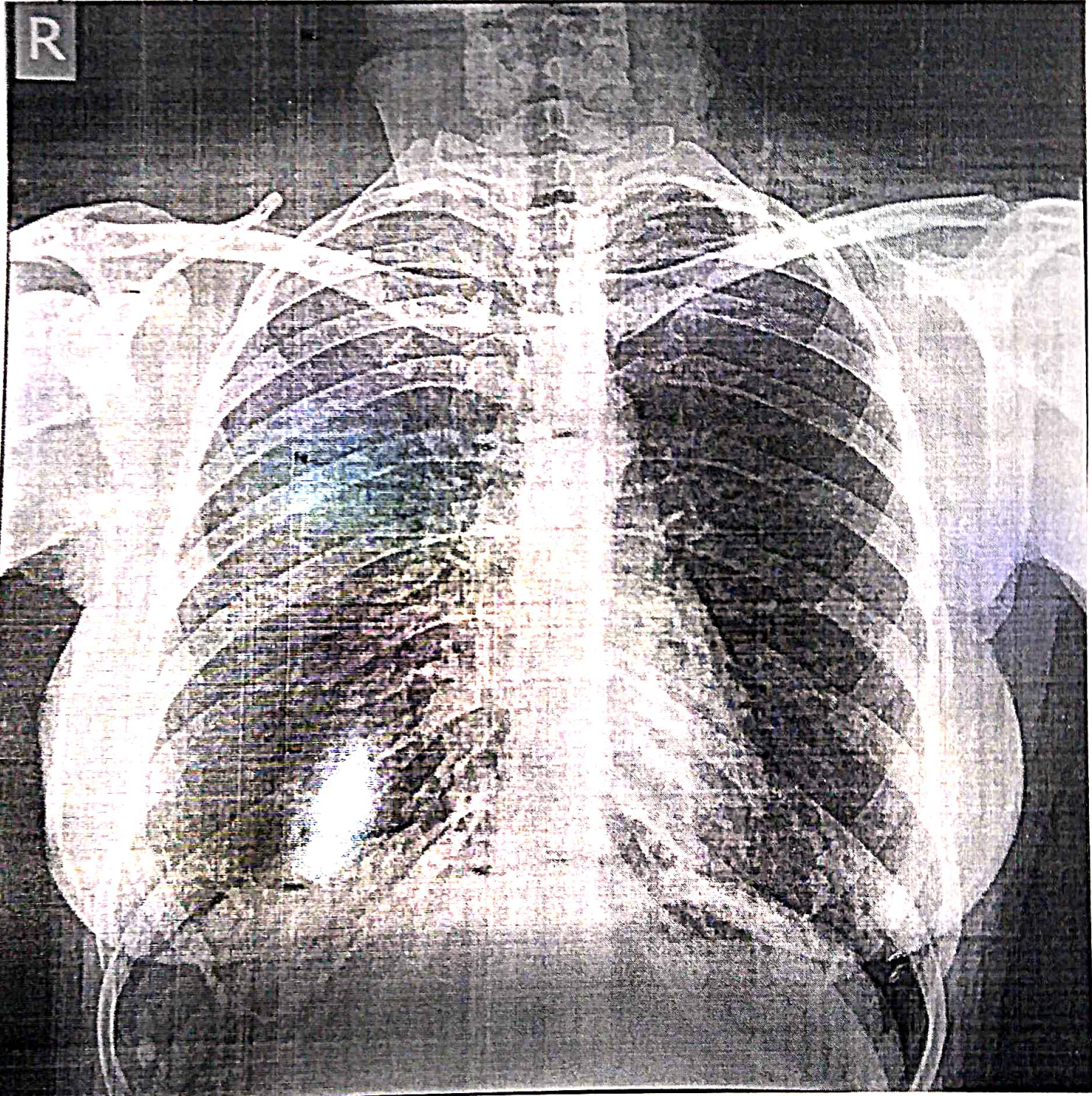
DR. PLUS HEALTHCARE CENTRE
NATHANI HEIGHTS', B-WING,
42, MUMBAI CENTRAL (EAST)

NAVYA DOMMEN

25/F

25/9/21

R





Dr-Plus Healthcare Centre

NATHANI HEIGHTS, B-Wing, Shop No. 42, Ground Floor, Opp. Mumbai Central Station (East), Mumbai - 400 008.

Full Name of life to be assured:

NAVYA OOMMEN

25/F DATE:25/09/2021

HAEMOGRAM

Normal Range

1.	Red Blood Cell Count	4.6	[M : 4.5 - 5.6/ F : 3.5 - 5.5/cu.mm]
2.	Hb%	15.5	[M: 14-18 / F : 11-16%]
3.	Hematocrit	46	[M : 40-53 / F : 30-47 %]
4.	Indices:		
(a)	MCV(Mean Corpuscular Volume)	91	[79-101 cu.mi.]
(b)	MCH(Mean Corpuscular Hb)	32	[27-32 pg]
(c)	MCHC(Mean Corpuscular Hb Concentration)	35	[32-38%]
5.	Morphology		
	Macrocytes :	--	Microcytes: -- Hypochromia: --
	Poikilocytosis:	--	Anisocytosis: --
6.	Target cells:	--	
	Spherocytes:	--	Elliptocytes: --
7.	TOTAL W.B.C.Count	7.200	{4000-11000/cu.mm}
Differential Count			
a)	Neutrophils :	60	[45 -70%] c) Eosinophils: 03 [01 - 06%]
b)	Lymphocytes :	30	[20 - 45%] d) Monocytes: 07 [00 - 08%]
e)	Basophils :	00	[00 - 01%]
8.	Platelets : 2.95	1.5-4.5 Lacks/cu.mm	
9.	Erythrocyte Sedimentation Rate:11	20 mm at end of 1 hour Method : Westergrens	

ROUTINE URINE EXAMINATION (RUA)

1. Physical Examination:

(i)	Colour:	PLAN YELLOW	(ii)	Sediment:	CLEAR
(iii)	Transparency:	ABSENT	(iv)	Reaction:	ACIDIC
(v)	Specific gravity	1.010			

2. Chemical Examination:

(i)	Protein :	ABSENT	(ii)	Sugar:	ABSENT
(iii)	Bile salt:	ABSENT	(iv)	Bile pigment:	ABSENT

3. Microscopic Examination:

(i)	Red Blood Cells:	ABSENT	(ii)	Epithelial Cells:	ABSENT
(iii)	Crystals:	ABSENT	(iv)	Pus Cells:	02 TO 03/HPF
(v)	Casts:	ABSENT	(vi)	Deposits:	ABSENT
(vii)	Bacteria's :	ABSENT			

DR. RAKESH PATKAR
M.D., D.N.B. (Pathology)
Reg. No. 2013/0011860



Dr-Plus Healthcare Centre

NATHANI HEIGHTS, B-Wing, Shop No. 42, Ground Floor, Opp. Mumbai Central Station (East), Mumbai - 400 008.

Full Name

NAVYA OOMMEN

25/F

DATE:25/09/202

	Type of Test	Actual Reading	Normal Range
1	Fasting Blood Sugar	80	70-100 mg%
2	PPBS	102	110 TO 140 mg%
3	Total Cholesterol	180	120-200 mg%
4	VERY LOW DENSINTY LEVEL(VLDL)	20	10-30 mg/dl
5	High Density Lipid (HDL)	55	40-60 mg%
6	Low Density Lipid (LDL)	110	<u>Upto 150</u>
7	S. Triglycerides	135	50-150 mg%
8	CHOL/HDL	3.2	Upto 5
9	HDL/LDL	0.5	
10	S. Creatinine	0.8	0.5-1.2 mg%
11	Blood Urea Nitrogen (BUN)	16.5	7-21 mg%
12	BUN/CREAT RATIO	20.6	
13	S. Proteins	6.5	6.0-7.9 mg%
14	(a) Albumin	3.5	3.5-5.5 mg%
15	(b) Globulin	3.0	2.0-3.5 mg%
16	A/G RATIO	1.1	
17	S. Bilirubin	0.9	0.3-1.3mg%
18	(a) Direct	0.5	0.0-0.8 mg%
19	(b) Indirect	0.4	0.0-0.5 mg%
20	SGOT (AST)	29	05-34 IU
21	SGPT (ALT)	31	05-40 IU
22	GGTP (GGT)	42	05-50 IU
23	SGOT/SGPT	0.9	
24	HBA1C	5.4	UPTO 6.5
25	S. Alkaline Phosphatase	89	30-115 IU
26	T3	142	80-180ng/dl
27	T4	7.1	4.6-12 ug/dl
28	TSH	3.5	0.4-4.0 mIU/L
29	SERUM URIC ACID	5.6	2.5-7.2mg/dl
30	URINE SUGAR PP	ABSENT	
31	URINE SUGAR FASTING	ABSENT	
32	BLOOD GROUP	"O"POSITIVE"	

DR. HAKESH PATKAR
M.D., D.N.B. (Pathology)
Reg. No. 2013/05/1660



Dr. Hari Chhablani

Cardiometabolic Physician & Intensivist
M.B.B.S., F.C.C.P. (RESP. MED.), PGDHHM,
PGDMLS, FELLOW INTENSIVE CARE MED.

ATTACHED TO: Wockhardt Hospital • Saifee Hospital • Apollo Spectra Hospital

NATHANI HEIGHTS, B-Wing, Shop No. 42, Ground Floor, Opp. Mumbai Central Station (East),
Mumbai - 400 008. • Cell : 98206 46163 • E : drharichhablani@gmail.com

PHYSICIAN REPORT

25/09/2021

NAME : NAVYA OOMMEN

AGE/SEX: 25/F

PRESENTING COMPLAINS: NIL

PAST HISTORY: H/O SEPTOPLASTY - 2017

TREATMENT HISTORY : NIL

FAMILY HISTORY: NOT SIGNIFICANT

ADDICTION: NIL

P: 90/MIN

BP: 120/76

RS: CLEAR

CVS: S1,S2 REGULAR

PA: SOFT

CNS: CLINICALLY NAD


ECG: WNL

CXR: WNL

LABS: ATTACHED

EYE EXAMINATION B/E : NEAR VISION - BL N36 DISTANT VISION - 6/24 COLOUR VISION - NORMAL

IMPRESSION : FIT ON CLINICAL MEDICAL EXAMINATION .


DR. HARI CHHABLANI
DR. HARI CHHABLANI
M.B.B.S., F.C.C.P. (RESP. MEDICINE) PGDHHM, PGDMLS
FELLOW INTENSIVE CARE
MMC REG. NO. - 91702

