



PRE – EMPLOYMENT HEALTH CHECK UP REPORT

DATE - 13/10/22

PATIENT NAME - Chandani Gupta AGE - 28 GENDER -

WEIGHT(KG) - 47.8 kg HEIGHT - 155 cm.

PHYSICAL EXAMINATION

PULSE

BP 100/70

BLOOD SUGAR(RANDOM)

FINDINGS

INVESTIGATIONS : Investigation reports are attached

FITNESS CERTIFICATE

* Consult urologist +/v/o @ renal calculi.
Patient is fit.
Sharma.

SIGNATURE



(This is only professional opinion and not the diagnosis, Please correlate clinically)

Q Block South City 11, Sohna Road, Main Sector-47, Gurgaon, Haryana
Ph.: 0124-4900000 (100 Lines) Fax : 0124-2218733 E-mail : parkmedicenters@gmail.com

PARK GROUP OF HOSPITALS : West Delhi • South Delhi • Gurgaon • Karnal • Panipat • Hodal • Ambala • Behror

the health care providers

the health care providers



DEPARTMENT OF PATHOLOGY

Patient Name : Mrs. CHANDANI GUPTA
MR No : 663873
Age/Sex : 28 Years / Female
Type : OPD
TPA/Corporate : MEDIWHEEL PVT LTD

Bill Date : 15/10/2022 / 11.40 AM
Reporting Date : 15/10/2022
Sample ID : 53398
Bill/Req. No. : 22976970
Ref Doctor : Dr.RMO

Test	Result	Bio. Ref. Interval	Units	Method
BLOOD SUGAR FASTING				
PLASMA GLUCOSE FASTING	85	60 - 100	mg/dl	GOD TRINDERS

***** END OF THE REPORT *****



Dr.NALANDA BUKTARE
MD (Pathology)

Dr.PRADIP KUMAR
Consultant (Microbiology)

Dr.NISHA TIWARI
MBBS, MD (Microbiology)
USER NM AMIT

(This is only professional opinion and not the diagnosis, Please correlate clinically)

Q Block South City 11, Sohna Road, Main Sector-47, Gurgaon, Haryana
Ph.: 0124-4900000 (100 Lines) Fax : 0124-2218733 E-mail : parkmedicenters@gmail.com

PARK GROUP OF HOSPITALS : West Delhi • South Delhi • Gurgaon • Karnal • Panipat • Hodal • Ambala • Behror

the health care providers

the health care providers





DEPARTMENT OF PATHOLOGY

Patient Name : Mrs. CHANDANI GUPTA
 MR No : 663873
 Age/Sex : 28 Years / Female
 Type : OPD
 TPA/Corporate : MEDIWHEEL PVT LTD

Bill Date : 15/10/2022 / 11.40 AM
 Reporting Date : 15/10/2022
 Sample ID : 53398
 Bill/Req. No. : 22976970
 Ref Doctor : Dr.RMO

Test	Result	Bio. Ref. Interval	Units	Method
CBC				
HAEMOGLOBIN	12.9	12 - 15	gm/dL	COLORIMETRY
TOTAL LEUCOCYTE COUNT	7500	4000 - 10000	/ μ L	ELECTRICAL IMPEDANCE
DIFFERENTIAL COUNT				
NEUTROPHILS	55	40.0 - 80.0	%	FLOW CYTOMETRY
LYMPHOCYTES	35	20.0 - 40.0	%	FLOW CYTOMETRY
MONOCYTES	07	2.0 - 10.0	%	FLOW CYTOMETRY
EOSINOPHILS	03	0.0 - 5.0	%	FLOW CYTOMETRY
BASOPHILS	00	0.0 - 2.0	%	FLOW CYTOMETRY
RED BLOOD CELL COUNT	4.0	3.5 - 5.5	millions/ μ L	ELECTRICAL IMPEDANCE
PACKED CELL VOLUME	35.4	35.0 - 50.0	%	ELECTRICAL IMPEDANCE
MEAN CORPUSCULAR VOLUME	86.7	83 - 101	fL	ELECTRICAL IMPEDANCE
MEAN CORPUSCULAR HAEMOGLOBIN	31.6	27 - 31	Picogrames	CALCULATED
MEAN CORPUSCULAR HB CONC	36.4	33 - 37	g/dl	CALCULATED
PLATELET COUNT	307	150 - 450	thou/ μ L	ELECTRICAL IMPEDANCE
RDW	12.4	11.6 - 14.5	%	CALCULATED

***** END OF THE REPORT *****



Dr.NALANDA BUKTARE
MD (Pathology)

Dr.PRADIP KUMAR
Consultant (Microbiology)

Dr.NISHA TIWARI
MBBS, MD (Microbiology)
USER NM AMIT

(This is only professional opinion and not the diagnosis, Please correlate clinically)

Q Block South City 11, Sohna Road, Main Sector-47, Gurgaon, Haryana
 Ph.: 0124-4900000 (100 Lines) Fax : 0124-2218733 E-mail : parkmedicenters@gmail.com

PARK GROUP OF HOSPITALS : West Delhi • South Delhi • Gurgaon • Karnal • Panipat • Hodal • Ambala • Behror

the **health** care providers

the **health** care providers





Cert. No. MC - 4830



Cert. No. H-2016-0369

DEPARTMENT OF PATHOLOGY

Patient Name : Mrs. CHANDANI GUPTA
MR No : 663873
Age/Sex : 28 Years / Female
Type : OPD
TPA/Corporate : MEDIWHEEL PVT LTD

Bill Date : 15/10/2022
Reporting Date : 15/10/2022
Sample ID : 53398
Bill/Req. No. : 22976970
Ref Doctor : Dr.RMO

Test	Result	Bio. Ref. Interval	Units
ESR (WESTERGREN)			
E.S.R.	25 H	0 - 15	mm at the end of 1st hr

***** END OF THE REPORT *****



Sample no.

Dr.NALANDA BUKTARE
MD (Pathology)

Dr.PRADIP KUMAR
Consultant (Microbiology)

Dr.NISHA TIWARI
MBBS, MD (Microbiology)
USER NM AMIT



(This is only professional opinion and not the diagnosis, Please correlate clinically)

Q Block South City 11, Sohna Road, Main Sector-47, Gurgaon, Haryana
Ph.: 0124-4900000 (100 Lines) Fax : 0124-2218733 E-mail : parkmedicenters@gmail.com

PARK GROUP OF HOSPITALS : West Delhi • South Delhi • Gurgaon • Karnal • Panipat • Hodal • Ambala • Behror

the **health** care providers

the **health** care providers





DEPARTMENT OF PATHOLOGY

Patient Name : Mrs. CHANDANI GUPTA
MR No : 663873
Age/Sex : 28 Years / Female
Type : OPD
TPA/Corporate : MEDIWHEEL PVT LTD

Bill Date : 15/10/2022 / 11.40 AM
Reporting Date : 15/10/2022
Sample ID : 53403
Bill/Req. No. : 22976970
Ref Doctor : Dr.RMO

Test	Result	Bio. Ref. Interval	Units	Method
THYROID PROFILE				
TRI-IODOTHYRONINE (T3)	1.01	0.60 - 1.81	ng/ml	Chemiluminescence
THYROXINE (T4)	6.3	5.01 - 12.45	µg/dL	Chemiluminescence
THYROID STIMULATING HORMONE (TSH)	5.92 H	0.5-5.50	µIU/ml	
SPECIMEN TYPE	SERUM			
Method : chemiluminescent immunoassay				

Note : Clinical Significance:

Thyroid function tests (TFTs) is a collective term for blood tests used to check the function of the thyroid. TFTs may be requested if a patient is thought to suffer from hyperthyroidism (overactive thyroid) or hypothyroidism (underactive thyroid), or to monitor the effectiveness of either thyroid-suppression or hormone replacement therapy. It is also requested routinely in conditions linked to thyroid disease, such as atrial fibrillation and anxiety disorder. A TFT panel typically includes thyroid hormones such as thyroid-stimulating hormone (TSH, thyrotropin) and thyroxine (T4), and triiodothyronine (T3) depending on local laboratory policy.

Note: Please correlate with clinical condition

***** END OF THE REPORT *****



Dr. NALANDA BUKTARE
MD (Pathology)

Dr. PRADIP KUMAR
Consultant (Microbiology)

Dr. NISHA TIWARI
MBBS, MD (Microbiology)
USER NM DINESH

(This is only professional opinion and not the diagnosis, Please correlate clinically)

Q Block South City 11, Sohna Road, Main Sector-47, Gurgaon, Haryana
Ph.: 0124-4900000 (100 Lines) Fax : 0124-2218733 E-mail : parkmedicenters@gmail.com

PARK GROUP OF HOSPITALS : West Delhi • South Delhi • Gurgaon • Karnal • Panipat • Hodal • Ambala • Behror

the health care providers the health care providers



DEPARTMENT OF PATHOLOGY

Patient Name : Mrs. CHANDANI GUPTA
MR No : 663873
Age/Sex : 28 Years / Female
Type : OPD
TPA/Corporate : MEDIWHEEL PVT LTD

Bill Date : 15/10/2022 / 11.40 AM
Reporting Date : 15/10/2022
Sample ID : 53398
Bill/Req. No. : 22976970
Ref Doctor : Dr.RMO

Test	Result	Bio. Ref. Interval	Units	Method
LFT (LIVER FUNCTION TEST)				
LFT				
TOTAL BILIRUBIN	0.6	0.1-1.2	mg/dL	DIAZO
DIRECT BILIRUBIN	0.3	0 - 0.4	mg/dL	DIAZO
INDIRECT BILIRUBIN	0.3	0.10 - 0.6	mg/dL	CALCULATED
SGOT (AST)	23	0 - 45	U/L	IFCC WITHOUT PYRIDOXAL PHOSHATE
SGPT (ALT)	11	0 - 45	U/L	IFCC WITHOUT PYRIDOXAL PHOSHATE
ALKALINE PHOSPHATASE	81	30 - 170	IU/L	MODIFIED IFCC
TOTAL PROTEINS	6.6	6.4 - 8.0	g/dL	BIURET
ALBUMIN	4.6	3.3 - 5.5	g/dL	BCG DYE
GLOBULIN	2.0	L 2.3 - 4.5	g/dL	CALCULATED
A/G RATIO	2.3	H 1.1 - 2.2		CALCULATED

***** END OF THE REPORT *****



Dr.NALANDA BUKTARE
MD (Pathology)

Dr.PRADIP KUMAR
Consultant (Microbiology)

Dr.NISHA TIWARI
MBBS, MD (Microbiology)
USER NM AMIT

(This is only professional opinion and not the diagnosis, Please correlate clinically)

Q Block South City 11, Sohna Road, Main Sector-47, Gurgaon, Haryana
Ph.: 0124-4900000 (100 Lines) Fax : 0124-2218733 E-mail : parkmedicenters@gmail.com

PARK GROUP OF HOSPITALS : West Delhi • South Delhi • Gurgaon • Karnal • Panipat • Hodal • Ambala • Behror

the **health** care providers

the **health** care providers





DEPARTMENT OF PATHOLOGY

Patient Name : Mrs. CHANDANI GUPTA
MR No : 663873
Age/Sex : 28 Years / Female
Type : OPD
TPA/Corporate : MEDIWHEEL PVT LTD

Bill Date : 15/10/2022 / 11.40 AM
Reporting Date : 15/10/2022
Sample ID : 53398
Bill/Req. No. : 22976970
Ref Doctor : Dr.RMO

Test	Result	Bio. Ref. Interval	Units	Method
KFT (RENAL PROFILE)				
KFT				
SERUM UREA	27	10 - 45	mg/dL	UREASE-GLDH
SERUM CREATININE	0.7	0.4 - 1.4	mg/dL	MODIFIED JAFFES
SERUM URIC ACID	2.8	2.5 - 7.0	mg/dL	URICASE
SERUM SODIUM	144	136 - 145	meq/l	ISE
SERUM POTASSIUM	3.8	3.5 - 5.5	meq/l	ISE
SERUM CALCIUM	8.3 L	8.5 - 10.5	mg/dL	ARSENazo III
SERUM PHOSPHORUS	4.5	2.5 - 4.5	mg/dL	AMMONIUM MOLYBDATE

***** END OF THE REPORT *****



Dr.NALANDA BUKTARE
MD (Pathology)

Dr.PRADIP KUMAR
Consultant (Microbiology)

Dr.NISHA TIWARI
MBBS, MD (Microbiology)

USER NM AMIT

(This is only professional opinion and not the diagnosis, Please correlate clinically)

Q Block South City 11, Sohna Road, Main Sector-47, Gurgaon, Haryana
Ph.: 0124-4900000 (100 Lines) Fax : 0124-2218733 E-mail : parkmedicenters@gmail.com

PARK GROUP OF HOSPITALS : West Delhi • South Delhi • Gurgaon • Karnal • Panipat • Hodal • Ambala • Behror or

the health care providers the health care providers



NAME	: MRS. CHANDANI GUPTA	DATE	: 15 / 10 / 22
Age Sex	: 26 Years / Female	Inpatient No	:
PERFORMED BY	: Dr. ELA MADAAN	BILL NO.	: 22976970

TRANS THORACIC ECHO CARDIOGRAPHY REPORT

MITRAL VALVE

Morphology AML: Normal / Thickening / Calcification / Flutter / Vegetation / Non significant Prolapse / SAM
PML: Normal / Thickening / Calcification / Prolapse / Paradoxical Motion / Fixed.
Subvalvular deformity: Present / Absent

Doppler Normal / Abnormal
Mitral Stenosis Present / Absent
Mitral Regurgitation; Absent / Normal / Mild / Trace / Moderate / Severe.

TRICUSPID VALVE

Morphology Normal / Atresia / Thickening / Calcification / Prolapse / Vegetation / Doming.
Doppler Normal / Abnormal
Tricuspid Stenosis: Present / Absent.
Tricuspid Regurgitation: Absent / Mild / Trace / Moderate

PULMONARY VALVE

Morphology Normal / Atresia / Thickening / Calcified / Doming / Vegetation.
Doppler Normal / Abnormal.
Pulmonary stenosis: Present / Absent
Pulmonary regurgitation: Present / Absent

AORTIC VALVE

Morphology Normal / Thickened / Mildly / Calcified / Flutter / Vegetation / Restricted / Opening
No. of Cusps 1 / 2 / 3 / 4
Doppler Normal / Abnormal
Aortic Stenosis : Present / Absent
Aortic regurgitation : Present / Absent / Mild / Trace



(This is only professional opinion and not the diagnosis, Please correlate clinically)

Q Block South City 11, Sohna Road, Main Sector-47, Gurgaon, Haryana
Ph.: 0124-4900000 (100 Lines) Fax : 0124-2218733 E-mail : parkmedicenters@gmail.com

PARK GROUP OF HOSPITALS : West Delhi • South Delhi • Gurgaon • Karnal • Panipat • Hodal • Ambala • Behror

the **health** care providers the **health** care providers

<u>Measurements</u>	<u>Normal Values</u>	<u>Measurements</u>	<u>Normal Value</u>
IVSD : 0.9cm	(0.6-1.1cm)	LA : 2.9cm	(1.9-4.0cm)
LVID : 4.6cm	(3.7-5.6cm)	LVOT : 1.0cm	
LVPW : 0.6cm	(0.6-1.1cm)	AORTA : 2.2cm	(2.0-3.7cm)
EF : 60%	(55% - 80%)	IVSmotion :	Normal / Flat / Paradoxical
Any Other			

CHAMBERS:-

LV Normal / Enlarged / Clear / Thrombus /
Contraction Normal LV shows concentric LVH, no gradient across LVOT / Inetic / Intra capillary
Regional wall motion abnormality: Absent / Present

LA Normal / Enlarged / Clear / Thrombus / Myxoma; LAA: Clear / Thrombus


RA Normal / Clear / Thrombus, Dilated.

RV Normal / Mildly Dilated / Enlarged / Clear / Thrombus / Hypertrophied/
PERICARDIUM Normal / Thickening / Calcification / Effusion.

COMMENTS & SUMMARY:-

- All Cardiac Chamber Dimensions are within normal limits.
- Global LVEF 60%
- No RWMA
- NORMAL LV FUNCTION
- TRACE TR
- GOOD RV FUNCTION
- IAS/IVS. No Flow seen across IAS/IVS.
- No Thrombus/Mass in any chamber.
- No Pericardial Effusion.

Please correlate clinically


Dr. ELA MADAAN
MBBS, PGDCC
Fellowship in non Invasive
Cardiology



(This is only professional opinion and not the diagnosis, Please correlate clinically)

Q Block South City 11, Sohna Road, Main Sector-47, Gurgaon, Haryana
Ph.: 0124-4900000 (100 Lines) Fax : 0124-2218733 E-mail : parkmedicenters@gmail.com

PARK GROUP OF HOSPITALS : West Delhi • South Delhi • Gurgaon • Karnal • Panipat • Hodal • Ambala • Behror

the **health** care providers

the **health** care providers



DEPARTMENT OF PATHOLOGY

Patient Name : Mrs. CHANDANI GUPTA

MR No : 063873

Age/Sex : 28 Years / Female

Type : OPD

TPA/Corporate : MEDIWHEEL PVT LTD

Bill Date : 15/10/2022

Reporting Date : 15/10/2022

Sample ID : 53398

Bill/Req. No. : 22976970

Ref Doctor : Dr.RMO

Test	Result	Bio. Ref. Interval	Units
BLOOD GROUPING AND RH FACTOR			
BLOOD GROUP	" O " RH POSITVE		

***** END OF THE REPORT *****



Sample no.



Dr.NALANDA BUKTARE
MD (Pathology)

Dr.PRADIP KUMAR
Consultant (Microbiology)

Dr.NISHA TIWARI
MBBS, MD (Microbiology)

USER NM AMIT

(This is only professional opinion and not the diagnosis, Please correlate clinically)

Q Block South City 11, Sohna Road, Main Sector-47, Gurgaon, Haryana
Ph.: 0124-4900000 (100 Lines) Fax : 0124-2218733 E-mail : parkmedicenters@gmail.com

PARK GROUP OF HOSPITALS : West Delhi • South Delhi • Gurgaon • Karnal • Panipat • Hodal • Ambala • Behror

the health care providers the health care providers





DEPARTMENT OF PATHOLOGY

Patient Name : Mrs. CHANDANI GUPTA
MR No : 663873
Age/Sex : 28 Years / Female
Type : OPD
TPA/Corporate : MEDIWHEEL PVT LTD

Cert. No. MC - 4830 Cert. No. H-2015-0389

Bill Date : 15/10/2022 / 11.40 AM
Reporting Date : 15/10/2022
Sample ID : 53398
Bill/Req. No. : 22976970
Ref Doctor : Dr.RMO

Test	Result	Bio. Ref. Interval	Units	Method
BLOOD SUGAR 2 HR. PP				
BLOOD SUGAR P.P.	160	H 80 - 150	mg/dl	

***** END OF THE REPORT *****



Dr.NALANDA BUKTARE
MD (Pathology)

Dr.PRADIP KUMAR
Consultant (Microbiology)

Dr.NISHA TIWARI
MBBS, MD (Microbiology)
USER NM AMIT

(This is only professional opinion and not the diagnosis, Please correlate clinically)

Q Block South City 11, Sohna Road, Main Sector-47, Gurgaon, Haryana
Ph.: 0124-4900000 (100 Lines) Fax : 0124-2218733 E-mail : parkmedicenters@gmail.com

PARK GROUP OF HOSPITALS : West Delhi • South Delhi • Gurgaon • Karnal • Panipat • Hodal • Ambala • Behror

the **health** care providers the **health** care providers



DEPARTMENT OF PATHOLOGY

Patient Name : Mrs. CHANDANI GUPTA
MR No : 663873
Age/Sex : 28 Years / Female
Type : OPD
TPA/Corporate : MEDIWHEEL PVT LTD

Bill Date : 15/10/2022 / 11.40 AM
Reporting Date : 16/10/2022
Sample ID : 53710
Bill/Req. No. : 22976970
Ref Doctor : Dr.RMO

Test	Result	Bio. Ref. Interval	Units	Method
LIPID PROFILE				
LIPID PROFILE				
TOTAL CHOLESTEROL	168	0 - 250	mg/dL	CHOD -Trinder
SERUM TRIGLYCERIDES	123	60 - 165	mg/dl	GPO-TRINDER
HDL-CHOLESTEROL	55	30 - 70	mg/dl	DIRECT
VLDL CHOLESTEROL	24	6 - 32	mg/dL	calculated
LDL	89	50 - 135	mg/dl	calculated
LDL CHOLESTEROL/HDL RATIO	1.6	1.0 - 3.0	mg/dL	calculated
TOTAL CHOLESTEROL/HDL RATIO	3.0	2.0 - 5.0	mg/dl	calculated
SPECIMEN TYPE	SERUM			

***** END OF THE REPORT *****



Dr.NALANDA BUKTARE
MD (Pathology)

Dr.PRADIP KUMAR
Consultant (Microbiology)

Dr.NISHA TIWARI
MBBS, MD (Microbiology)
USER NM MOHITPA159

(This is only professional opinion and not the diagnosis, Please correlate clinically)

Q-Block South City 11, Sohna Road, Main Sector-47, Gurgaon, Haryana
Ph.: 0124-4900000 (100 Lines) Fax: 0124-2218733 E-mail : parkmedicenters@gmail.com

Page of 1

PARK GROUP OF HOSPITALS : West Delhi • South Delhi • Gurgaon • Karnal • Panipat • Hodal • Ambala • Behror

the **health** care providers

the **health** care providers





Patient Name	Mrs. CHANDANI GUPTA	Billed Date	: 15/10/2022	11.40 AM
Reg No	663873	Reported Date	: 15/10/2022	
Age/Sex	28 Years / Female	Req. No.	: 22976970	
Type	OPD	Consultant Doctor	: Dr. RMO	

USG WHOLE ABDOMEN

The real time, B mode, gray scale sonography of the abdominal organs was performed.

LIVER : The liver is normal in size, 12.6cmn shape and echotexture. No evidence of any focal lesion. IHBR is not dilated.

GALL BLADDER : The gall bladder is well distended . No evidence any calculus or mass seen.

GB wall thickness with in normal limits.No evidence of pericholecystic fluid is seen.

BILE DUCT :The common bile duct is normal in caliber. No evidence of calculus is noted in common bile duct.

SPLEEN :The spleen is normal in size 9.5cm and shape.Its echotexture is homogeneous.No evidence of focal lesion is noted.

PANCREAS :The pancreas is normal in size, shape, contours and echotexture.No evidence of solid or cystic mass lesion is noted.MPD is not dilated. No evidence of peripancreatic collection.

KIDNEYS :Tiny concretion of size 3mm seen at upper pole of left kidney.

The bilateral kidneys are normal in size and echotexture. Cortico-medullary differentiation is maintained.There is no evidence of obvious hydronephrosis.

URINARY BLADDER :The urinary bladder is well distended.It shows uniformly thin walls and sharp mucosa.No evidence of calculus is seen. No evidence of mass or diverticulum is noted.

UTERUS: The uterus is anteverted. It measures _6.6x4.4x3.9__cms. in the longitudinal, anteroposterior and transverse dimensions respectivelyThe uterine margins is smooth and does not reveal any contour abnormalities.

The uterine myometrium shows homogeneous echotexture.

No evidence of leiomyoma is noted. No solid or cystic mass lesion is noted.

The endometrial echo is in the midline and measures _11_mm.

The ovaries on the either side show normal echotexture.

No adnexal mass is seen.No cyst is seen in ovaries.

Minimal free fluid is seen in POD.

No evidence of obvious retroperitoneal or mesentric lymphadenopathy is seen.

IMPRESSION- Left renal tiny concretion

To be correlated clinically.

Dr. ANSHU K. SHARMA
MBBS,MD
CONSULTANT RADIOLOGIST

Dr. MANJEET SEHRAWAT
MBBS,MD,PDCC
CONSULTANT RADIOLOGIST

Dr. NEENA SIKKA
MBBS,DNB
CONSULTANT RADIOLOGIST



(This is only professional opinion and not the diagnosis, Please correlate clinically)

Q Block South City 11, Sohna Road, Main Sector-47, Gurgaon, Haryana

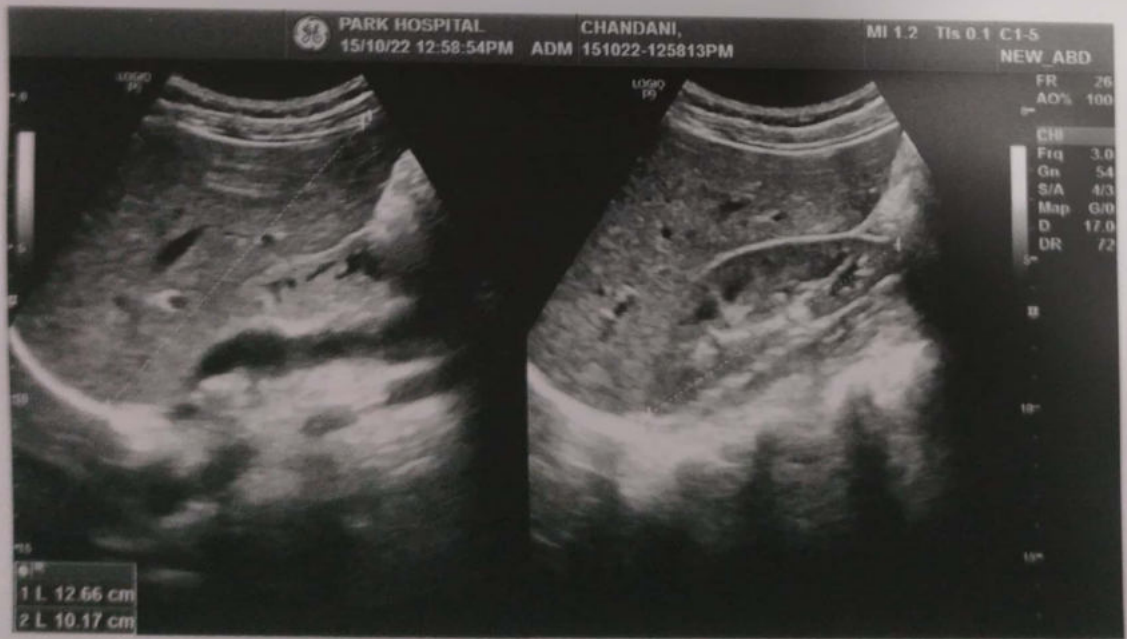
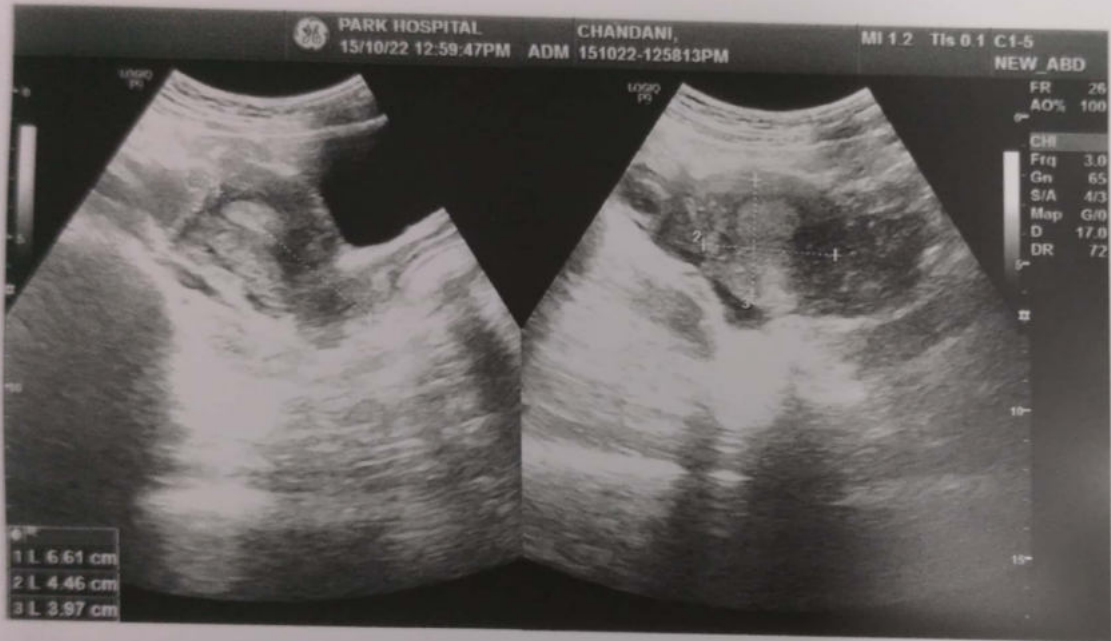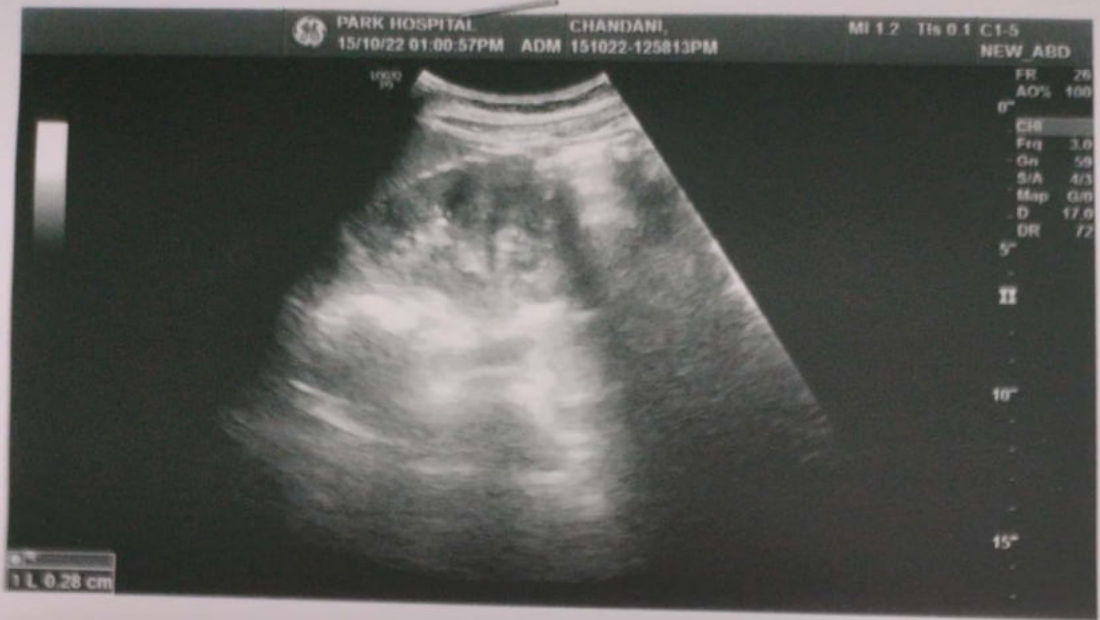Ph.: 0124-4900000 (100 Lines) Fax : 0124-2218733 E-mail : parkmedicenters@gmail.com

PARK GROUP OF HOSPITALS : West Delhi • South Delhi • Gurgaon • Karnal • Panipat • Hodal • Ambala • Behror

the health care providers

the health care providers







Patient Name	Mrs. CHANDANI GUPTA	Billed Date	: 15/10/2022 11:40 AM
Reg No	663873	Reported Date	: 15/10/2022
Age/Sex	28 Years / Female	Req. No.	: 22976970
Type	OPD	Consultant Doctor	: Dr. RMO

X-RAY CHEST AP/PA

X-RAY CHEST P.A. VIEW

Bilateral lungs appears normal.
 No focal lung lesion seen.
 No evidence of free fluid is seen.
 Both hila are normal in size, have equal density and bear normal relationship.
 The heart and trachea are central in position and no mediastinal abnormality is visible.
 The cardiac size is normal for patient age and view.
 The domes of the diaphragms are normal in position, and show smooth outline.

To be correlated clinically



Dr. ANSHU K. SHARMA
MBBS, MD
CONSULTANT RADIOLOGIST

Dr. MANJEET SEHRAWAT
MBBS, MD, PDCC
CONSULTANT RADIOLOGIST

Dr. NEENA SIKKA
MBBS, DNB
CONSULTANT RADIOLOGIST

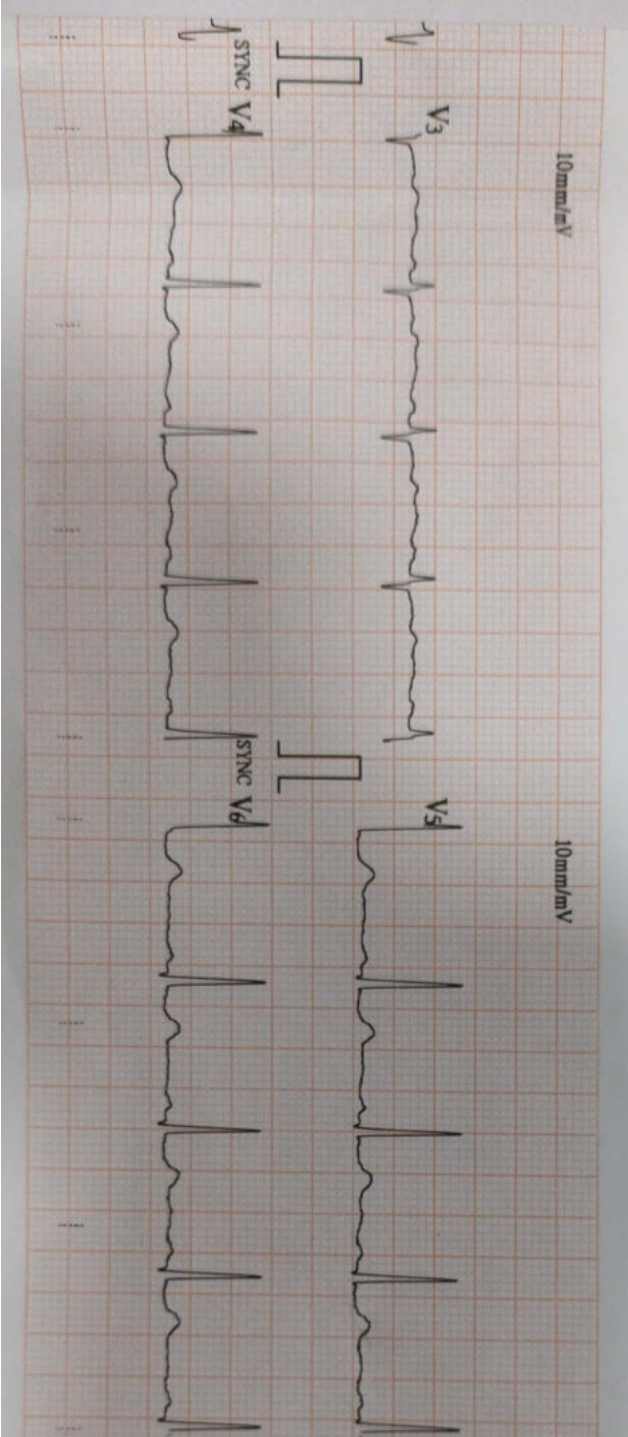
(This is only professional opinion and not the diagnosis, Please correlate clinically)

Q Block South City 11, Sohna Road, Main Sector-47, Gurgaon, Haryana
 Ph.: 0124-4900000 (100 Lines) Fax : 0124-2218733 E-mail : parkmedicenters@gmail.com

PARK GROUP OF HOSPITALS : West Delhi • South Delhi • Gurgaon • Karnal • Panipat • Hodal • Ambala • Behror

R

CHANDANI GUPTA 28Y REQ-22976970 F 10/15/2022 12:25 PM
PARK HOSPITAL, SOUTH CITY II, GURGAON, HARYANA



ID : 0001

15/10/22

HR : 81 bpm

R-R : 734 ms

P-R : 138 ms

QRS : 86 ms

QT/QTc : 350/408 ms

P/QRS/T : 66/80/69 °

RV5/SVL : 1.250/0.480 mV

RV5+SVL : 1.730 mV

Age :

28 y/f

Sex :

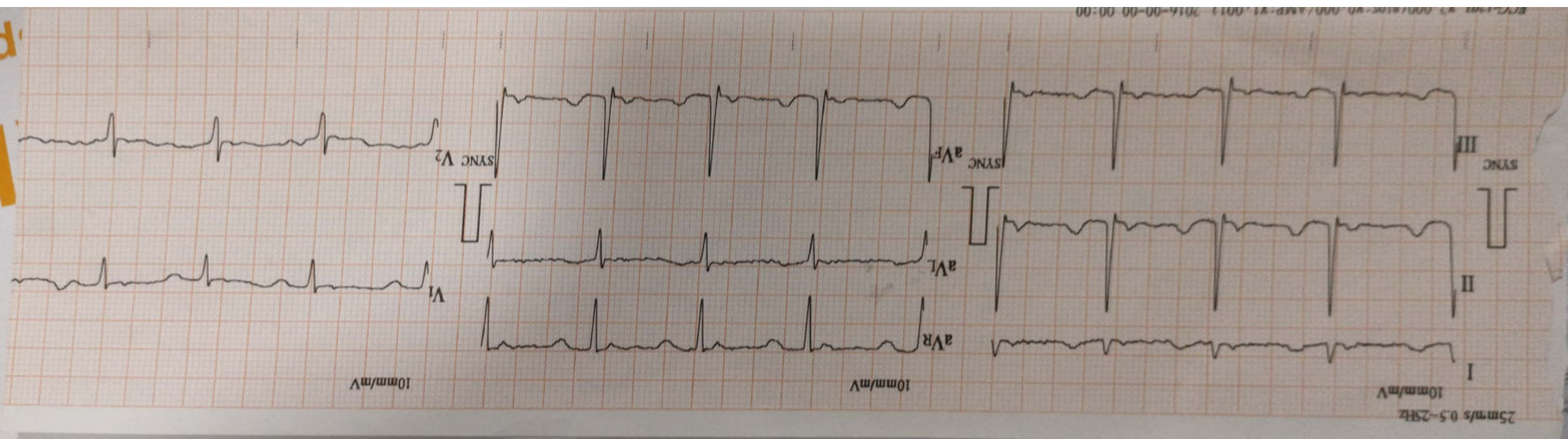
female

Name:

Chandni

Unconfirmed report Verified by:

----- Sinus Rhythm
 ----- T Abnormality (Flat T)



00:00 00-00-00 2016-00-00 00:00