



mediwheel.

भारत सरकार
GOVERNMENT OF INDIA



प्रियंका तेलंग
Priyanka Telang
जन्म तिथि/ DOB: 03/12/1990
महिला / FEMALE



2850 1964 2389

आधार-आम आदमी का अधिकार


(Signature)
DR. HARI SHARANI
M.D.B.S. & FRESH TISSUE PEDIATRIC PODIATRS
FELLOW INTENSIVE CARE
MMC REG. NO. - 91702

31/F

DR. PLUS HEALTHCARE CENTRE
NATHAN HEIGHTS, B-WING,
42, NARAI CENTRAL (EAST)

Priyanka

भारतीय विशिष्ट पहचान प्राधिकरण
UNIQUE IDENTIFICATION AUTHORITY OF INDIA



पता:
W/O अनुराग अरुण कृष्ण
तेलंग, फ्लैट न. 304, ए-1,
ब्लॉक ए, सेंट फ्रांसिस
को.एड. विद्यालय के पास,
कटरा हिल्स, हुजूर, भोपाल,
मध्य प्रदेश - 462043

Address:
W/O Anurag Arun Krishan Telang,
flat no. 304, e-1, block A sagar
golden palm, near st. francis co.ed.
school, kabra hills, Huzur, Bhopal,
Madhya Pradesh - 462043

2850 1964 2389

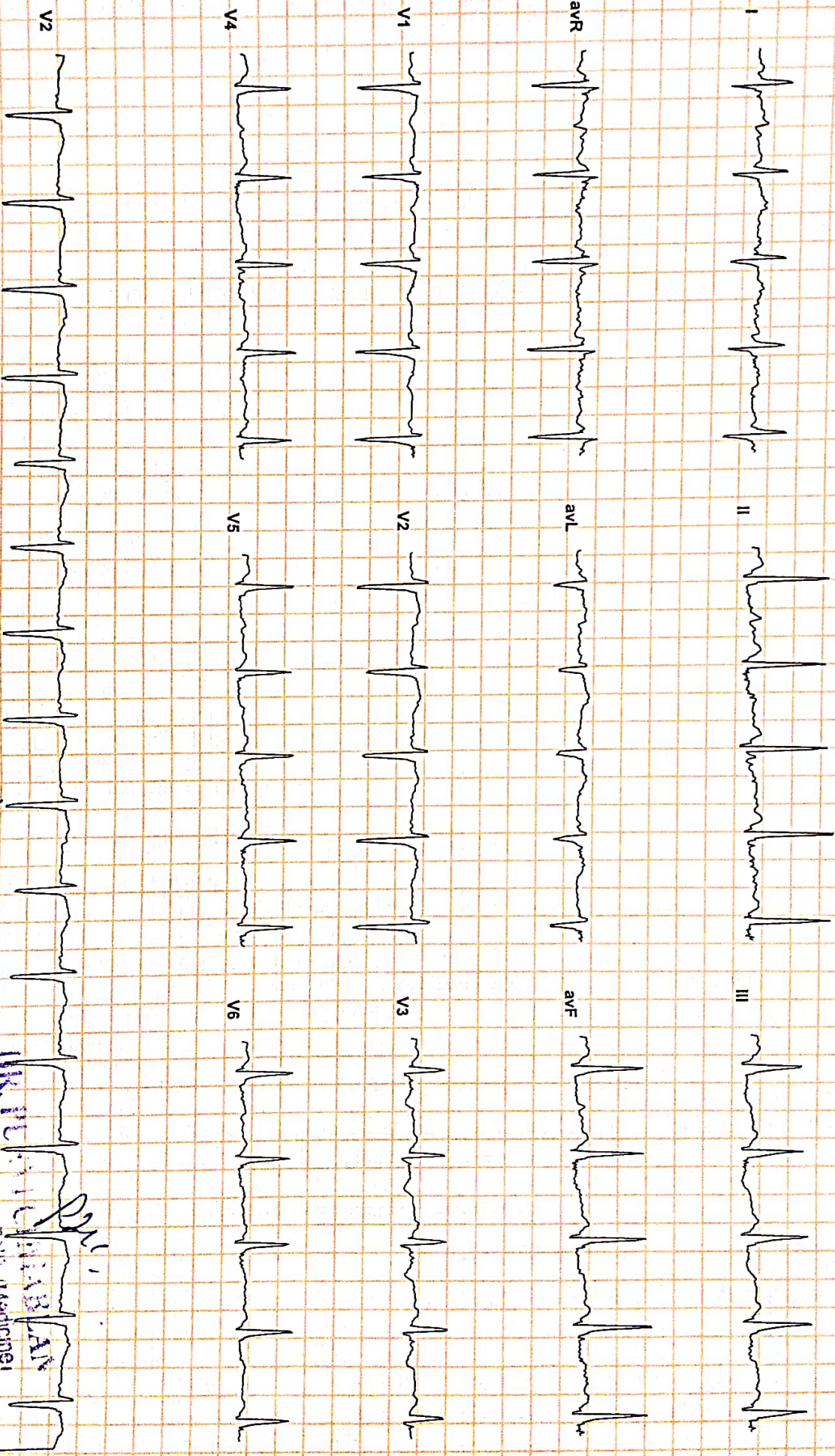
Aadhaar-Aam Admi ka Adhikar

DR PLUS HEALTHCARE CENTRE - MUMBAI CENTRAL

ECG

1305 / PRIYANKA TELANG / 31 Yrs / F

Heart Rate : 99 bpm / Tested On : 12-Dec-21 11:21:17 / HF 0.05 Hz - LF 100 Hz / Notch 50 Hz / Sn 1.00 Cm/mV / Sw 25 mm/s
/ Re/d By: DR. HARI CHHABLANI



Normal

DR. HARI CHHABLANI
CONSULTANT PHYSICIAN AND INTENSIVIST
DIPLOMA IN DRUGS AND INTENSIVE CARE (DDIC)

Reported By: DR. RAGHAV CHHABLANI



Dr-Plus Healthcare Centre

NATHANI HEIGHTS, B-Wing, Shop No. 42, Ground Floor, Opp. Mumbai Central Station (East), Mumbai - 400 008.

Patient Name	:	PRIYANKA TELANG	Sex:	FEMALE
Doctor's Name	:	DR. HARI CHHABLANI	Age:	31
Date	:	12/12/2021		

ULTRASONOGRAPHY OF THE ABDOMEN AND THE PELVIS:

The relevant sonographic findings include the following:

HEPATOBIILIARY APPARATUS

The liver is normal in size and echogenicity. No obvious focal parenchymal lesion is seen. Intrahepatic biliary radicals are not dilated.

The portal vein and the common bile duct are normal.

GALL BLADDER

The gall bladder is adequately distended. The wall thickness is normal.

No echogenic contents are noted in its lumen. There is no pericholecystic collection noted.

PANCREAS

The pancreas shows normal echogenicity and size.

No focal or diffuse lesions are noted. No evidence of calcification is noted.

SPLEEN

The spleen appears normal in size and echogenicity.

No focal or diffuse lesions are noted. No evidence of calcification is noted.

KIDNEYS

Right kidney measures : 10.0 x 4.1 cm , Left kidney measures : 10.4 x 4.6 cm.

Both the kidneys appear normal in size, shape and echogenicity. Both the pelvicalyceal system is normal and

both corticomedullary differentiations are well maintained. There is no obvious focal or diffuse lesion noted.

No evidence of any calculus seen in either kidney.

URINARY BLADDER

The urinary bladder shows anechoic contents. Its wall thickness appears normal.

UTERUS

Uterus measures = 6.0 x 2.5 x 3.4 cms.

The uterus is anteverted and anteflexed and normal in size. There are no focal or diffuse lesions noted.

The endometrium appears normal (7.9 mm).

OVARIES

Both the ovaries appear normal in size.

Right ovary measures :3.4 x 4.6 Cm , Left ovary measures :3.5 x 4.3 cm

There is no obvious evidence of abdominal or pelvic lymphadenopathy or ascites noted.

No other obvious pelvic mass is seen. No probe-tenderness is noted.

IMPRESSION: No significant abnormality is detected.

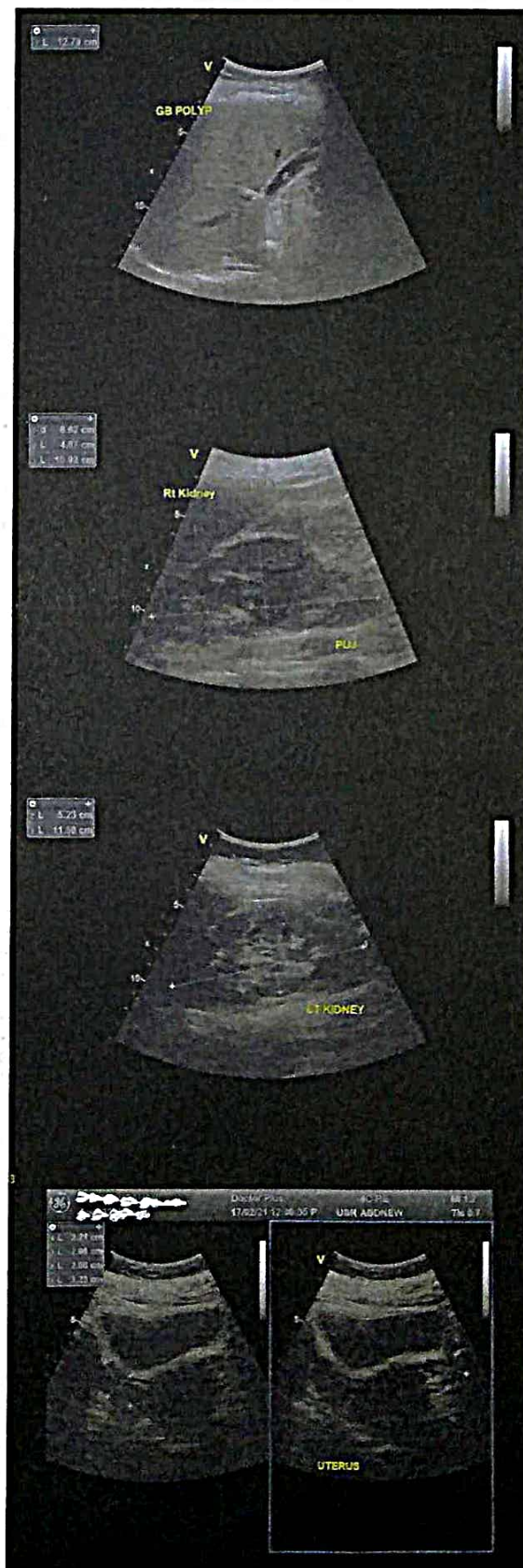
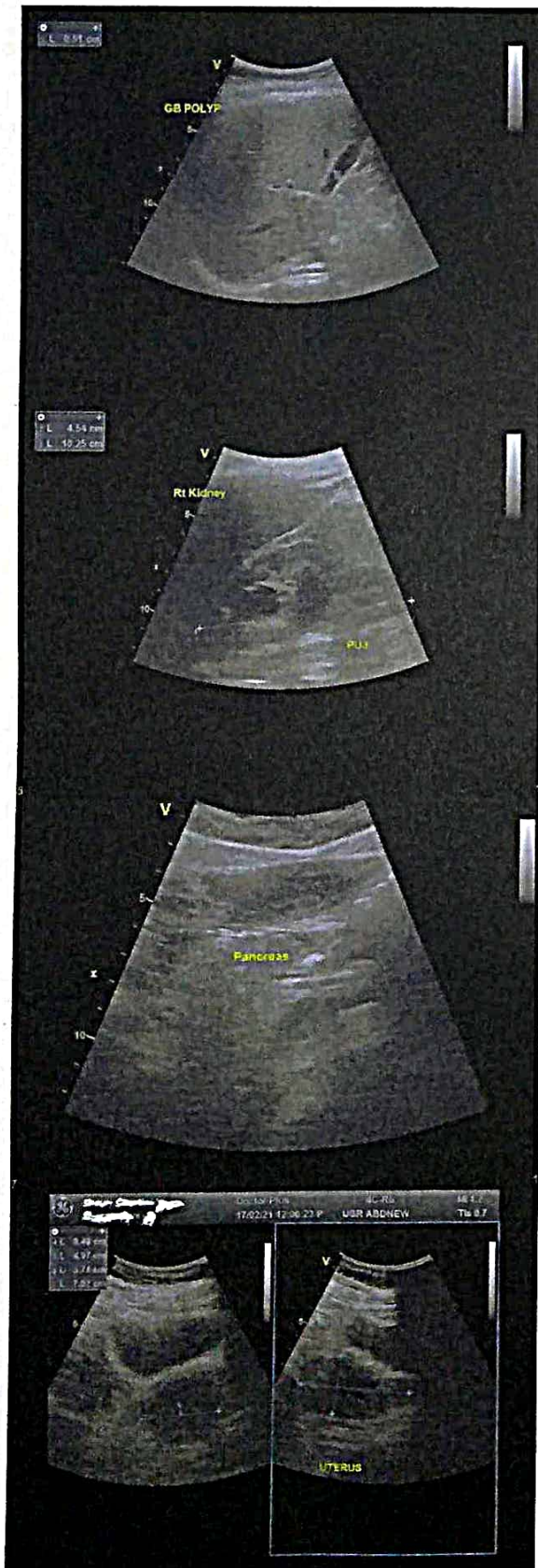Dr. Parag Jhaveri
MBBS (BOM), DMRE(BOM)
Radio-Sonologist

DR. PLUS HEALTHCARE CENTRE
NATHANI HEIGHTS', B-WING,
42, MUMBAI CENTRAL (EAST)

Name **PRIYANKA TELANG**

Sex **Female**

Age **31**





NAME : PRIYANKA TELANG

31/F

DATE:12/12/2021

REF BY : DR. HARI CHHABLANI

2D-ECHO. AND COLOR DOPPLER REPORT

- NORMAL CARDIAC VALVES WITH TRIVIAL TR.
- NORMAL CARDIAC CHAMBERS
- NO E/O REGIONAL WALL MOTION ABNORMALITY. WITH NORMAL LVEF OF 65%.
- NO E/O PULMONARY HYPERTENSION .PASP 35 mmHg by TR jet.
- NO E/O LEFT VENTRICULAR HYPERTROPHY.
- NO E/O DIASTOLIC DYSFUNCTION.
- NO E/O PERICARDIAL EFFUSION.
- NO E/O INTRACARDIAC CLOT OR VEGETATION
- INTACT IAS/IVS
- CONVENTIONL DOPPLER :

E TO A RATIO IS MORE THAN ONE IN LV INFLOW.


THERE IS NO GRADIENT ACROSS AV,LVOT OR RVOT

PASP FROM TR JET IS 35 mm OF Hg.

- COLOUR DOPPLER:

TRIVIAL TR

EF Slope	108	mm/sec		
Opening Amplitude	19			
Posterior leaflet				
E.P.S.S	02	mm		
Mitral valve prolapse				
Vegetations				
TRICUSPID VALVE	OBSERVED	NORMAL VALUES		
PULMONARY VALVE	OBSERVED	NORMAL VALUES		
EF Slope				
'A' Wave				
Midsystolic notch				
Flutter				
Other Findings				
AORTIC VALVE	OBSERVED	NORMAL VALUES		
Cuspal opening	15	mm		
Closure line	Central			
Eccentricity index	1			
Other Findings				
DIMENSIONS	OBSERVED	NORMAL VALUES		
1. Lvd (Diastolic)	47	26-52		
2. Lvd (Systolic)	25	24-42mm		
3. RVD (Diastolic)	18	7-23mm		
4. IVST (Diastolic)	09	6-11mm		
5. IVST (Systolic)	16			
6. LVPWT (Diastolic)	09	6-11mm		
7. LVPWT (Systolic)	17			
8. Aortic root	24	22-37mm		
9. left Atrium	32	19-40mm		
	STRUCTURE	REGURG GRADING	VELOCITY m/sec	STENOSIS GRADIENT mm/Hg
			Max mean	Peak mean
MITRAL VALVE	NORMAL	0/3	/	/
TRICUSPID VALVE	NORMAL	TRIVIAL	/	/
PULMONARY VALVE	NORMAL	0/4	/	/
AORTIC VALVE	NORMAL	0/4	/	/

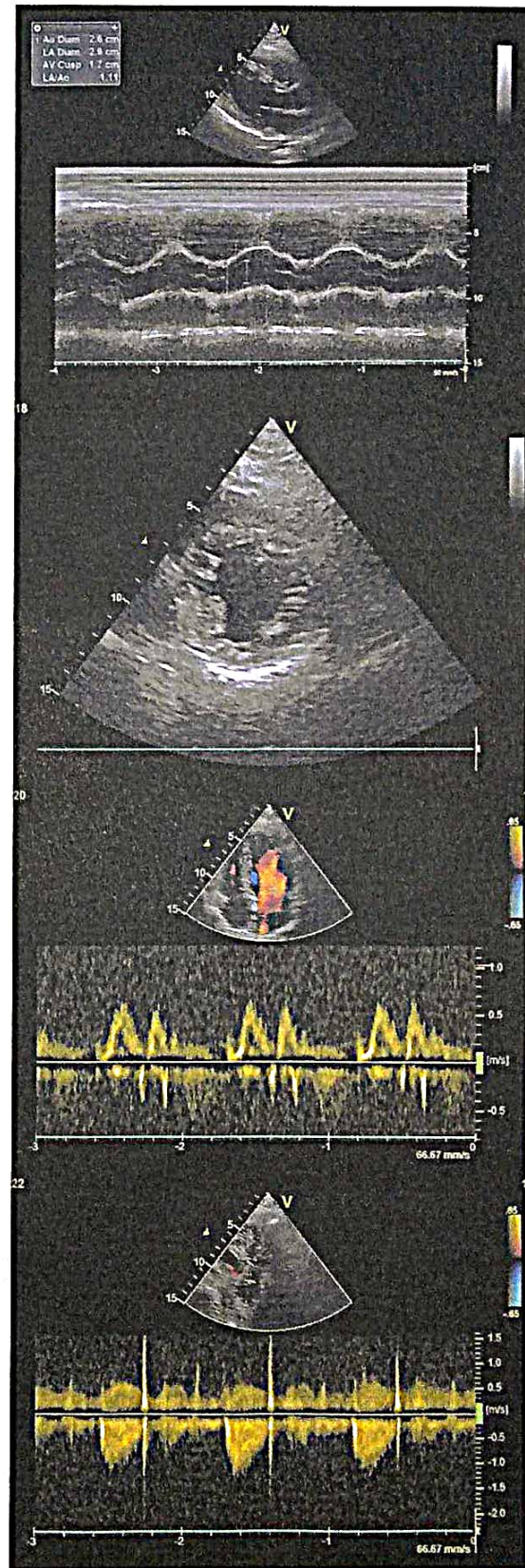
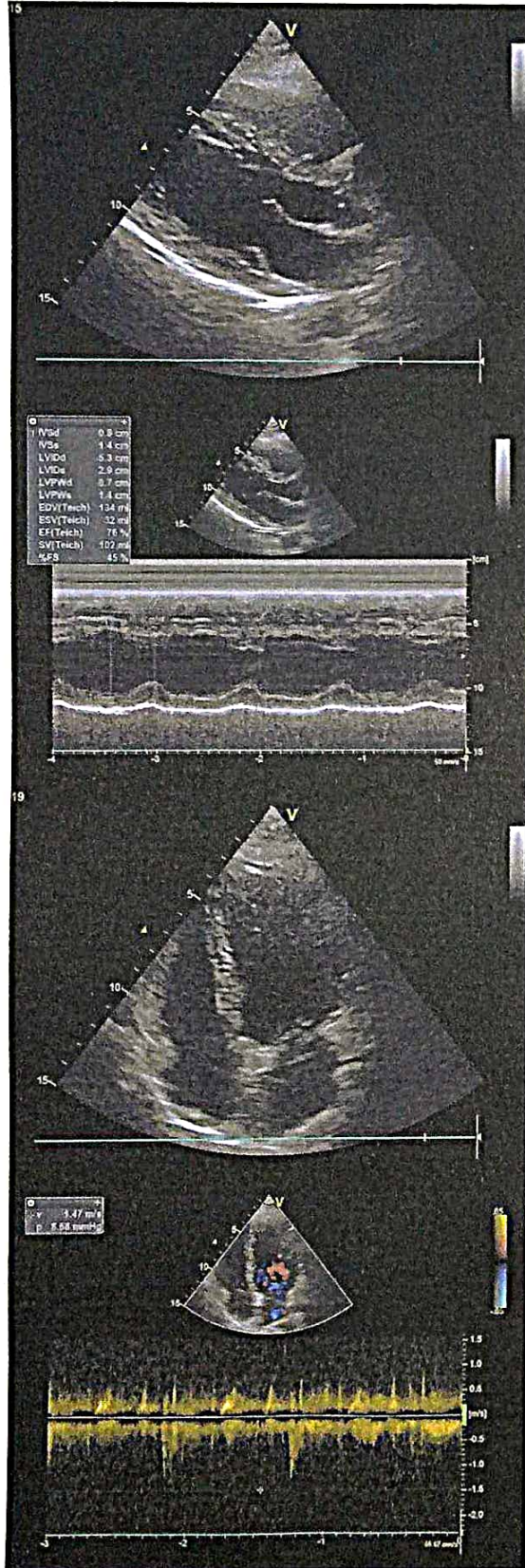

DR.P.H.CHHABLANI
 M.B.B.S, DNB.(MEDICINE)
 CONSULTANT PHYSICIAN AND CARDIOLOGIST.

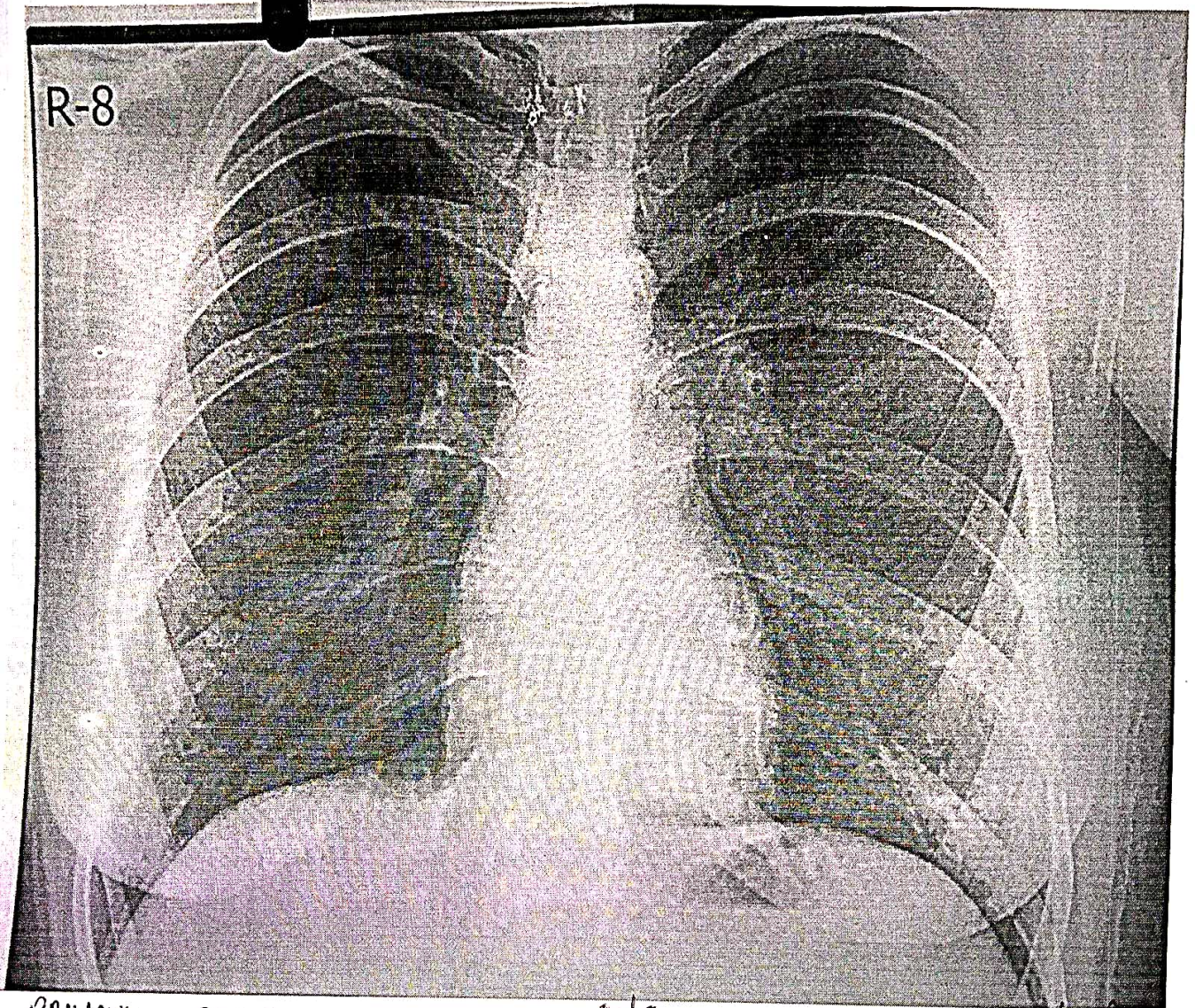
DR. PURVI CHHABLANI
 MBBS, DNB (Medicine)
 Consultant Physician And Intensive
 Reg No 7769F

Name **PRIYANKA TELANG**

Sex **Female**

Age **31**





R-8

PRIYANKA TELANI

31/F

12/12/2024



Patient's Name : PRIYANKA TELANG

Report Date : 12/12/2021

Referred By Dr. : SELF

Age : 31 Years

Sex : FEMALE

Chest X-ray PA

- No active pulmonary lesion seen.
- Trachea and mediastinum are in midline .
- Cardiac size and configuration are within normal limits .
- Pleural cavities are clear .
- Domes of diaphragm are smooth in outline.
- Bony thorax is normal .


Radiologist

DR. A. J. MAZUMDAR

MD. DMRE, MDRD

'DR. PLUS HEALTHCARE CENTRE'
NATHANI HEIGHTS', B-WING,
42, MUMBAI CENTRAL (EAST)



Dr-Plus Healthcare Centre

NATHANI HEIGHTS, B-Wing, Shop No. 42, Ground Floor, Opp. Mumbai Central Station (East), Mumbai - 400 008.

Full Name of life to be assured:

PRIYANKA TELANG 31/F

DATE:12/12/2021

HAEMOGRAM

Normal Range

1.	Red Blood Cell Count	3.9	[M : 4.5 - 5.6 / F : 3.5 - 5.5/cu.mm]
2.	Hb%	12.5	[M: 14-18 / F : 11-16%]
3.	Hematocrit	40	[M : 40-53 / F : 30-47 %]
4.	Indices:		
(a)	MCV(Mean Corpuscular Volume)	89	[79-101 cu.mi.]
(b)	MCH(Mean Corpuscular Hb)	29	[27-32 pg]
(c)	MCHC(Mean Corpuscular Hb Concentration)	32	[32-38%]
5.	Morphology		
	Macrocytes : --	Microcytes: --	Hypochromia: --
	Piokilocytosis: --	Anisocytosis: --	
6.	Target cells: --		
	Spherocytes: --	Elliptocytes: --	
7.	TOTALW.B.C.Count	6,300	{4000-11000/cu.mm}
Differential Count ⁰			
a)	Neutrophils :	65	[45 -70%] c) Eosinophils: 03 [01 - 06%]
b)	Lymphocytes :	25	[20 - 45%] d) Monocytes: 06 [00 - 08%]
e)	Basophils :	01	[00 - 01%]
8.	Platelets :3.28		1.5-4.5 Lacks/cu.mm
9.	Erythrocyte Sedimentation Rate:09	20 mm at end of 1 hour	Method : Westergrens

ROUTINE URINE EXAMINATION (RUA)

1. Physical Examination:

(i)	Colour:	PALE YELLOW	(ii)	Sediment:	CLEAR
(iii)	Transparency:	ABSENT	(iv)	Reaction:	ACIDIC
(v)	Specific gravity	1.015			

2. Chemical Examination

(i)	Protein :	ABSENT	(ii)	Sugar:	ABSENT
(iii)	Bile salt:	ABSENT	(iv)	Bile pigment:	ABSENT

3. Microscopic Examination:

(i)	Red Blood Cells:	ABSENT	(ii)	Epithelial Cells:	ABSENT
(iii)	Crystals:	ABSENT	(iv)	Pus Cells:	02 TO 03/HPF
(v)	Casts:	ABSENT	(vi)	Deposits:	ABSENT
(vii)	Bacteria's :	ABSENT			

DR. RAKESH PATKAR
M.D. (P.B.) (Pathology)
Reg. No. 2013/03/1060



Dr-Plus Healthcare Centre

NATHANI HEIGHTS, B-Wing, Shop No. 42, Ground Floor, Opp. Mumbai Central Station (East), Mumbai - 400 008.

Full Name

PRIYANKA TELANG

31/F

DATE:12/12/2021

	Type of Test	Actual Reading	Normal Range
1	Fasting Blood Sugar	82	70-100 mg%
2	PPBS	110	110 TO 140 mg%
3	Total Cholesterol	170	120-200 mg%
4	VERY LOW DENSINTY LEVEL(VLDL)	20	10-30 mg/dl
5	High Density Lipid (HDL)	50	40-60 mg%
6	Low Density Lipid (LDL)	100	Upto 150
7	S. Triglycerides	123	50-150 mg%
8	CHOL/HDL	3.4	Upto 5
9	HDL/LDL	0.5	
10	S. Creatinine	0.9	0.5-1.2 mg%
11	Blood Urea Nitrogen (BUN)	15	7-21 mg%
12	BUN/CREAT RATIO	16.6	
13	S. Proteins	6.6	6.0-7.9 mg%
14	(a) Albumin	3.6	3.5-5.5 mg%
15	(b) Globulin	3.0	2.0-3.5 mg%
16	A/G RATIO	1.2	
17	S. Bilirubin	0.8	0.3-1.3mg%
18	(a) Direct	0.4	0.0-0.8 mg%
19	(b) Indirect	0.4	0.0-0.5 mg%
20	SGOT (AST)	25	05-34 IU
21	SGPT (ALT)	32	05-40 IU
22	GGTP (GGT)	38	05-50 IU
23	SGOT/SGPT	0.7	
24	HBA1C	5.6	UPTO 6.5
25	S. Alkaline Phosphatase	85	30-115 IU
26	T3	140	80-180ng/dl
27	T4	4.8	4.6-12 ug/dl
28	TSH	3.1	0.4-4.0 mIU/L
29	SERUM URIC ACID	4.0	2.5-7.2mg/dl
30	URINE SUGAR PP	ABSENT	
31	URINE SUGAR FASTING	ABSENT	
32	BLOOD GROUP	"AB"POSITIVE"	

DR. ANKESH PATKAR
M.D., M.N.B. (Pathology)
Reg. No. 2013/95/1660



Dr. Hari Chhablani

Cardiometabolic Physician & Intensivist
M.B.B.S., F.C.C.P. (RESP. MED.), PGDHHM,
PGDMLS, FELLOW INTENSIVE CARE MED.

ATTACHED TO: Wockhardt Hospital • Saifee Hospital • Apollo Spectra Hospital

NATHANI HEIGHTS, B-Wing, Shop No. 42, Ground Floor, Opp. Mumbai Central Station (East),
Mumbai - 400 008. • Cell : 98206 46163 • E : drharichhablani@gmail.com

PHYSICIAN REPORT

12/12/2021

NAME : PRIYANKA TELANG

AGE: 31 SEX: F

PRESENTING COMPLAINS: NIL.

PAST HISTORY: LSCS - 2021 , D & C -2019 - MISCARRIAGE

TREATMENT HISTORY : NIL.

FAMILY HISTORY: NOT SIGNIFICANT

ADDICTION: NIL

P: 94/MIN

RS: CLEAR

PA: SOFT

ECG: WNL

LABS: ATTACHED

EYE EXAMINATION : NEAR VISION - B/L-N6 DISTANT VISION RT- -2.0 , LT- -3.0 COLOUR VISION -
NORMAL

IMPRESSION : FIT ON CLINICAL MEDICAL EXAMINATION..

BP: 110/70

CVS: S1,S2 REGULAR

CNS: CLINICALLY NAD

DR. HARI CHHABLANI

DR. HARI CHHABLANI
M.B.B.S., F.C.C.P. (RESP. MEDICINE), PGDHHM, F-DMLS
FELLOW INTENSIVE CARE
MMC REG. NO. - 91702

