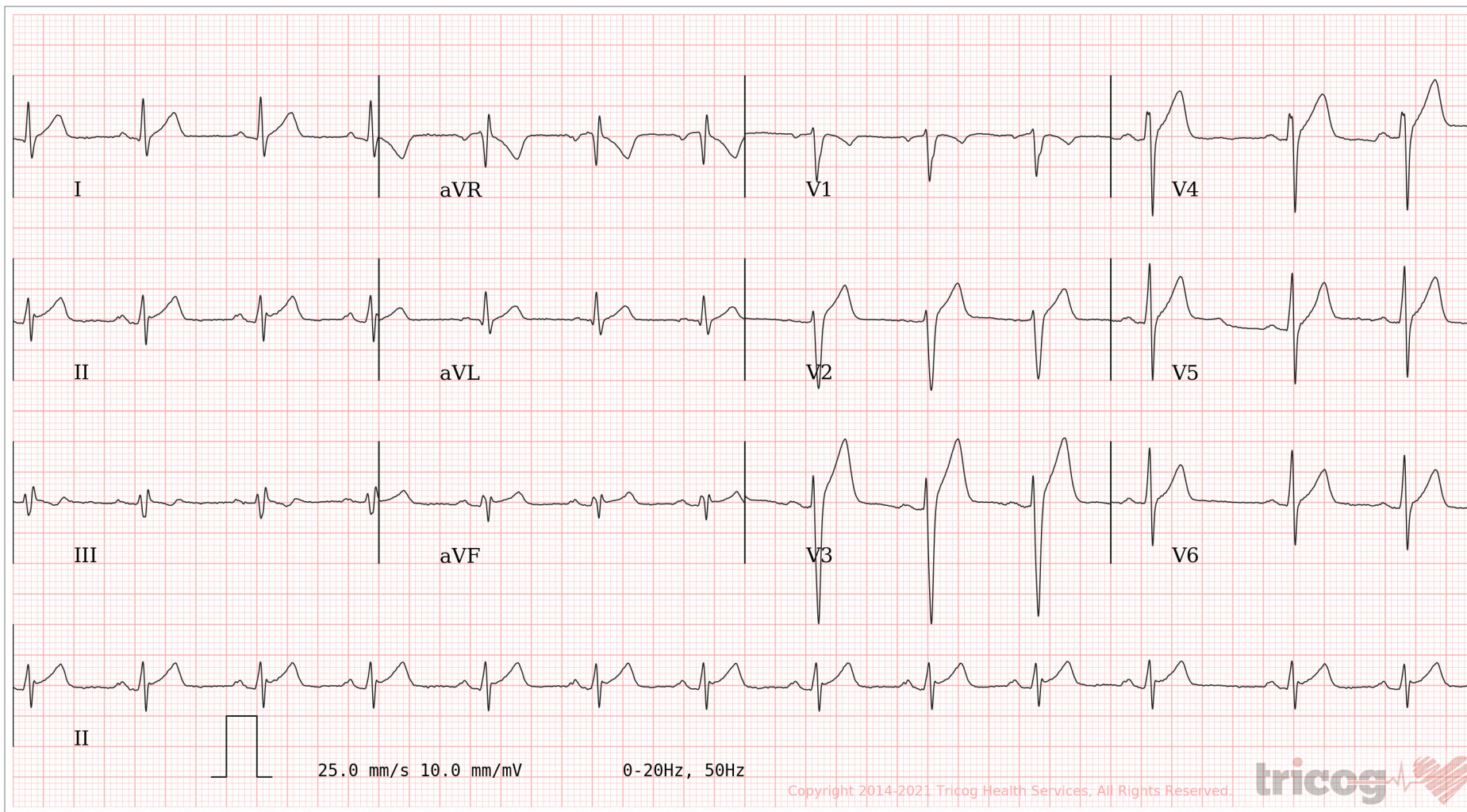




Age / Gender: 34/Male
Patient ID: CHFD0352412122
Patient Name: Mr.ANKUR KUMAR GUPTA

Date and Time: 31st Oct 21 10:24 AM



AR: 80 bpm VR: 80 bpm QRSD: 96 ms QT: 334 ms QTc: 385 ms PRI: 154 ms P-R-T: 53° 3° 32°

Sinus Rhythm, Normal Axis, with Sinus Arrhythmia, Nonspecific ST Abnormality. Please correlate clinically.

AUTHORIZED BY

Dr. Charit
MD, DM: Cardiology

REPORTED BY

Dr Sumithra L