



To,

The Coordinator,  
Mediwheel (Arcofemi Healthcare Limited)  
Helpline number: 011- 41195959

Dear Sir / Madam,

**Sub: Annual Health Checkup for the employees of Bank of Baroda**

This is to inform you that the following spouse of our employee wishes to avail the facility of Cashless Annual Health Checkup provided by you in terms of our agreement.

PARTICULARS OF HEALTH CHECK UP BENEFICIARY	
NAME	SHOBHIT SINGHAL
DATE OF BIRTH	13-03-1991
PROPOSED DATE OF HEALTH CHECKUP FOR EMPLOYEE SPOUSE	10-09-2022
BOOKING REFERENCE NO.	22S109324100024604S
SPOUSE DETAILS	
EMPLOYEE NAME	MS. VERMA BARKHA
EMPLOYEE EC NO.	109324
EMPLOYEE DESIGNATION	IT
EMPLOYEE PLACE OF WORK	NEW DELHI,ZO NEW DELHI
EMPLOYEE BIRTHDATE	02-08-1988

This letter of approval / recommendation is valid if submitted along with copy of the Bank of Baroda employee id card. This approval is valid from **31-08-2022** till **31-03-2023**.The list of medical tests to be conducted is provided in the annexure to this letter. Please note that the said health checkup is a **cashless facility** as per our tie up arrangement. We request you to attend to the health checkup requirement of our employee's spouse and accord your top priority and best resources in this regard. The EC Number and the booking reference number as given in the above table shall be mentioned in the invoice, invariably.

We solicit your co-operation in this regard.

Yours faithfully,

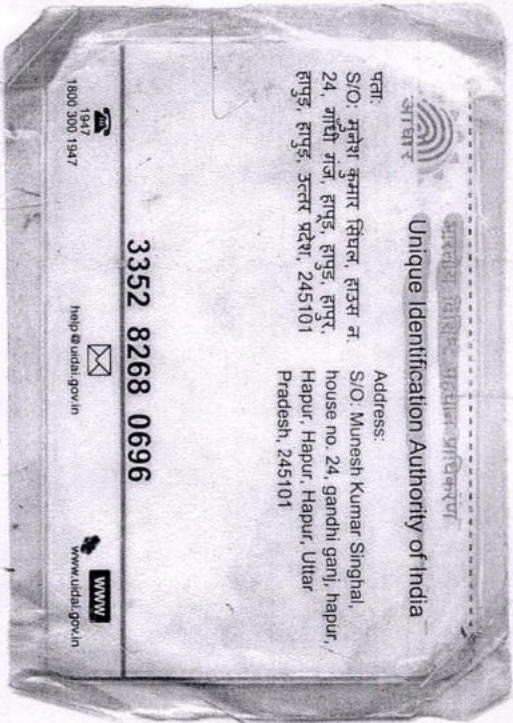
Sd/-

**Chief General Manager**  
**HRM Department**  
**Bank of Baroda**

(Note: This is a computer generated letter. No Signature required. For any clarification, please contact Mediwheel (Arcofemi Healthcare Limited))

**SUGGESTIVE LIST OF MEDICAL TESTS**

<b>FOR MALE</b>	<b>FOR FEMALE</b>
CBC	CBC
ESR	ESR
Blood Group & RH Factor	Blood Group & RH Factor
Blood and Urine Sugar Fasting	Blood and Urine Sugar Fasting
Blood and Urine Sugar PP	Blood and Urine Sugar PP
Stool Routine	Stool Routine
<b>Lipid Profile</b>	<b>Lipid Profile</b>
Total Cholesterol	Total Cholesterol
HDL	HDL
LDL	LDL
VLDL	VLDL
Triglycerides	Triglycerides
HDL / LDL ratio	HDL / LDL ratio
<b>Liver Profile</b>	<b>Liver Profile</b>
AST	AST
ALT	ALT
GGT	GGT
Bilirubin (total, direct, indirect)	Bilirubin (total, direct, indirect)
ALP	ALP
Proteins (T, Albumin, Globulin)	Proteins (T, Albumin, Globulin)
<b>Kidney Profile</b>	<b>Kidney Profile</b>
Serum creatinine	Serum creatinine
Blood Urea Nitrogen	Blood Urea Nitrogen
Uric Acid	Uric Acid
HBA1C	HBA1C
Routine urine analysis	Routine urine analysis
USG Whole Abdomen	USG Whole Abdomen
<b>General Tests</b>	<b>General Tests</b>
X Ray Chest	X Ray Chest
ECG	ECG
2D/3D ECHO / TMT	2D/3D ECHO / TMT
Stress Test	Thyroid Profile (T3, T4, TSH)
PSA Male (above 40 years)	Mammography (above 40 years) and Pap Smear (above 30 years).
Thyroid Profile (T3, T4, TSH)	Dental Check-up consultation
Dental Check-up consultation	Physician Consultation
Physician Consultation	Eye Check-up consultation
Eye Check-up consultation	Skin/ENT consultation
Skin/ENT consultation	Gynaec Consultation



भारत सरकार  
शुभित सिंघल  
Unique Identification Authority of India

पता:  
S/O. मनेश कुमार सिंघल, बी३एम नं.  
24, गान्धी गार्ज, हापुर, हापुर, हापुर,  
हापुर, हापुर, उत्तर प्रदेश, 245101

Address:  
S/O: Munesh Kumar Singhal,  
house no. 24, gandhi gari, hapur,  
Hapur, Hapur, Uttar  
Pradesh, 245101

3352 8268 0696

1947  
1800 300 1947

help@uidai.gov.in

www.uidai.gov.in

*Shubh Singh*



भारत सरकार  
Shubhit Singhal  
Government of India

शुभित सिंघल  
Shubhit Singhal  
जन्म तिथि / DOB : 13/04/1991  
पुरुष / Male

3352 8268 0696

आम आदमी का अधिकार



1947  
1800 300 1947

help@uidai.gov.in

www.uidai.gov.in

<b>Radiology No.</b>	: 5074/OPDPB22DL	<b>Date</b>	: 08-Nov-2022
<b>Patient Name</b>	: <b>Mr. SHOBHIT SINGHAL</b>	<b>Age/Sex</b>	: 31Y
<b>Guardian Name</b>	:	<b>UHID No.</b>	: 4620/UHID22DL
<b>Consultant</b>	: Dr. INSURANCE	<b>Mobile No.</b>	: <b>9453839073</b>

## X-RAY CHEST

**Indication: Routine checkup.**

**Image quality:-**

No evidence of rotation.  
PA view. Normal penetration.

**Airway:-** Trachea central.  
Carina & bronchi are normal.  
No hilar abnormality.

**Lung fields:-** Clear.

**Cardiac:-** Cardiac borders are visible.  
Normal heart size.

**Diaphragm:-** Costophrenic angles on right & left are normal.  
Cardiophrenic angles on right & left are normal.  
Diaphragm portion are normal.

**Bony cage:-** No evidence of bony lesion/fracture seen.  
No evidence of cervical ribs seen.

**Impression: No significant abnormality detected.**



Dr. Harshita Surange  
MBBS, DMRD (RADIODIAGNOSIS)  
DIPLOMA IN MSK, UCAM (Spain)  
Reg. No. MCI/16522, DMC/18402



BOOK APPOINTMENT



<b>Radiology No.</b>	: 5074/OPDPB22DL	<b>Date</b>	: 08-Nov-2022
<b>Patient Name</b>	: <b>Mr. SHOBHIT SINGHAL</b>	<b>Age/Sex</b>	: 31Y
<b>Guardian Name</b>	:	<b>UHID No.</b>	: 4620/UHID22DL
<b>Consultant</b>	: Dr. INSURANCE	<b>Mobile No.</b>	: <b>9453839073</b>

## ULTRASOUND OF WHOLE ABDOMAN

**The liver** is normal in size contour and echotexture. Intrahepatic bile ducts and CBD are not dilated. Hepatic portal veins and the IVC appear normal in caliber.

**Gall bladder** is adequately distended with normal intraluminal fluid contents. No evidence of calculus / wall thickness noted.

**Pancreas** is of normal size and contour with normal echotexture.

**Right kidney** is normal in size and position .It shows normal movements with respiration. Cortical thickness is normal .**3 calculi of 7.9 ,7 and 6.4mm are seen in mid pole of right kidney.**

No mass or hydronephrotic changes seen.

**Right kidney measures- 10.39x5.35cm**

Renal artery pulsation appear normal.

Left kidney is normal in size and position .It shows normal movements with respiration. Cortical thickness is normal .

No calculus, mass or hydronephrotic changes seen.

**Left kidney measures- 9.13x4.26cm**

Renal artery pulsation appear normal.



Dr. Harshita Surange  
MBBS, DMRD (RADIODIAGNOSIS)  
DIPLOMA IN MSK, UCAM (Spain)  
Reg. No. MCI/16522, DMC/18402



BOOK APPOINTMENT



<b>Radiology No.</b>	: 5074/OPDPB22DL	<b>Date</b>	: 08-Nov-2022
<b>Patient Name</b>	: <b>Mr. SHOBHIT SINGHAL</b>	<b>Age/Sex</b>	: 31Y
<b>Guardian Name</b>	:	<b>UHID No.</b>	: 4620/UHID22DL
<b>Consultant</b>	: Dr. INSURANCE	<b>Mobile No.</b>	: <b>9453839073</b>

**Spleen** is of normal size and shape. Echotexture is normal. No focal lesion is seen.

No evidence of retro-peritoneal lymphadenopathy/ ascites/ pleural effusion noted.

Urinary bladder does not show any calculus or mass lesion. No significant wall thickening noted.

**Prostate** is of normal size for age with regular contours and normal echo-texture. It measures 27x29x27mm which is equal to 11.94gms.

**Impression : Right Renal Calculi**

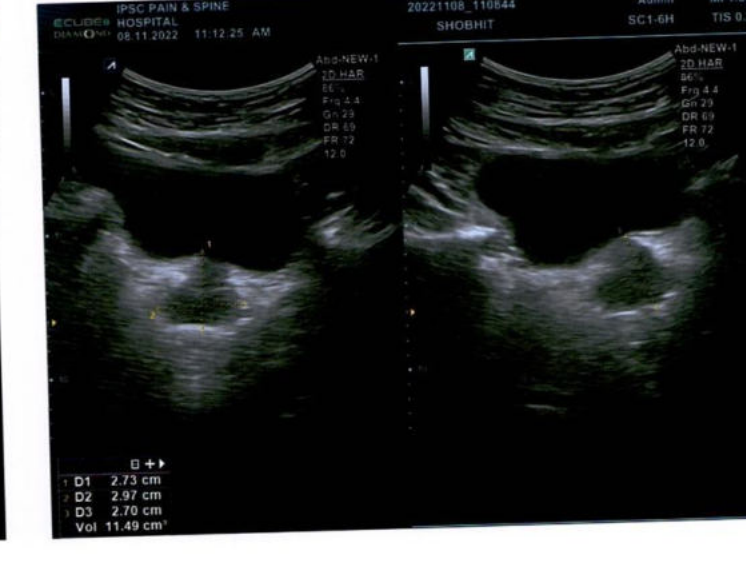
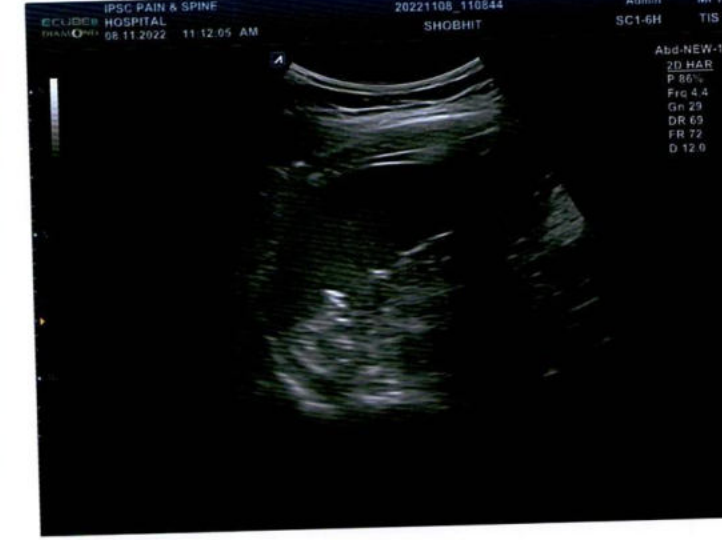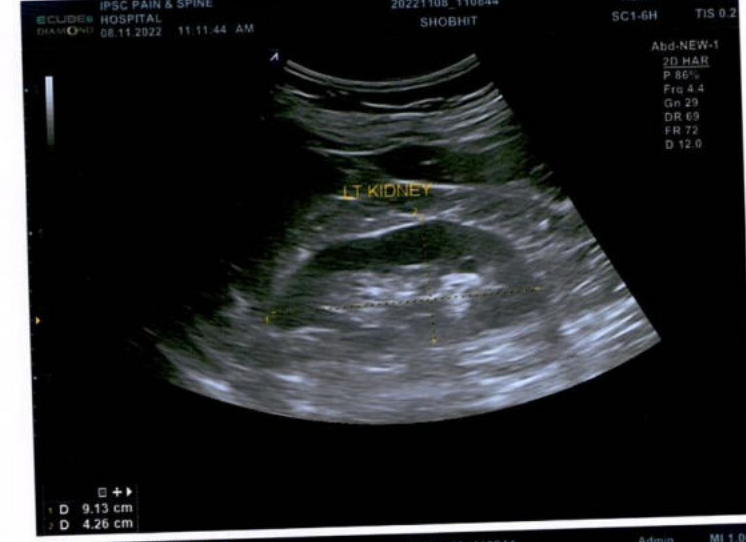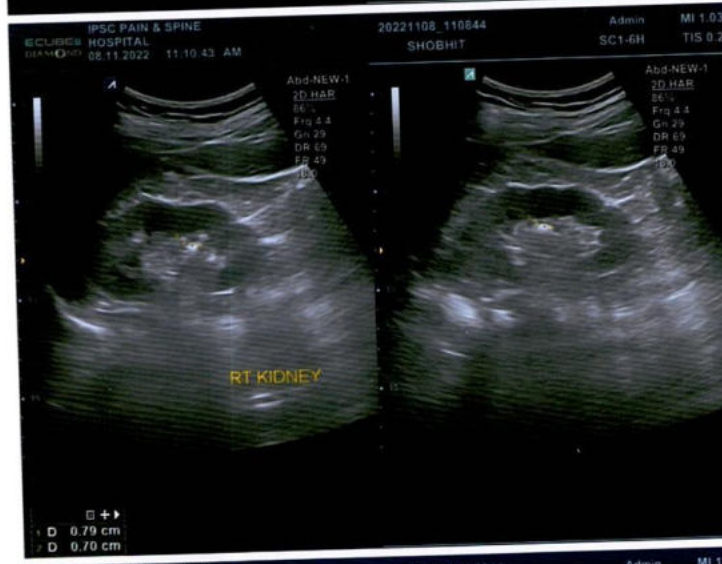
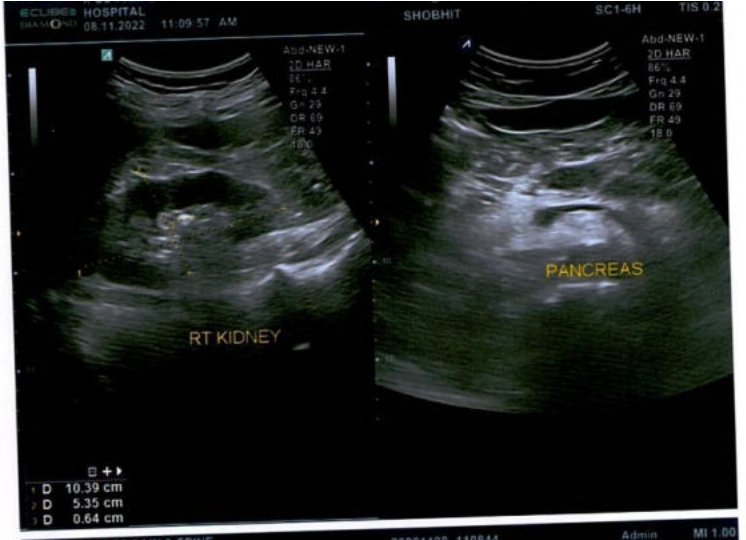
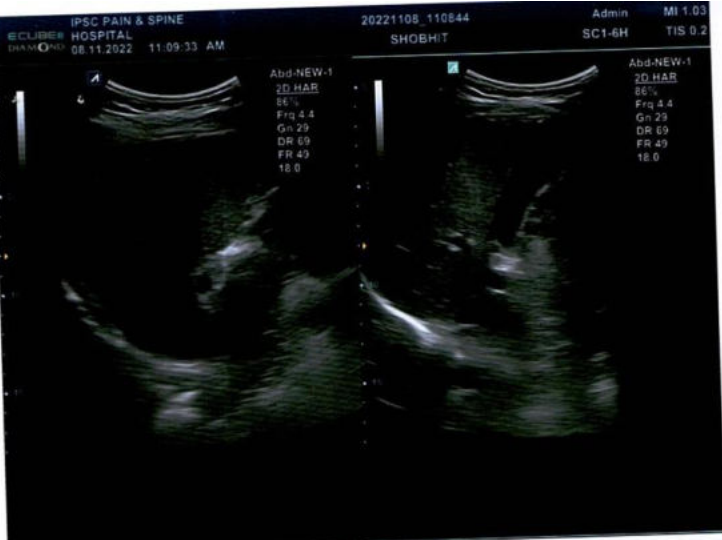


Dr. Harshita Surange  
MBBS, DMRD (RADIODIAGNOSIS)  
DIPLOMA IN MSK, UCAM (Spain)  
Reg. No. MCI/16522, DMC/18402



BOOK APPOINTMENT





# THE DIAGNOSTIC & IMAGING CENTRE

Plot No. 147, 2nd Floor, Main Road, Sec. 7,  
Dwarka, New Delhi-110078 Ph. 011-49078567

**SHOBHIT SINGHAL**

ID : 3504

DATE : 08-11-2022

AGE/SEX : 31 / M

HT/WT : 0 / 0

REF. BY :

**TREADMILL TEST REPORT**

PROTOCOL : Bruce  
HISTORY : Checkup/Physical fitness,  
INDICATION :  
MEDICATION :

PHASE	TOTAL TIME	STAGE TIME	SPEED Km/Hr	GRADE %	H.R. bpm	B.P. mmHg	RPP x100	ST LEVEL (MM)			METRS
								II	V1	V5	
SUPINE					67	120 / 80	80	0.9	-0.1	1.1	
STANDING					84	120 / 80	100	0.9	-0.5	1.1	
HYPERVENT					80	120 / 80	96	1.1	-0.3	1.5	
Stage 1	2:55	0:26	2.7	10	89	130 / 80	115	0.6	-0.7	0.9	4.67
Stage 2	5:55	2:55	4	12	96	140 / 80	134	0.7	-0.4	0.9	7.04
Stage 3	8:55	2:55	5.4	14	113	150 / 80	169	0.7	-0.6	0.9	9.92
Stage 4	11:55	2:55	6.7	16	116	160 / 80	185	0	-0.1	1.5	13.89
Stage 5	14:55	2:55	8	18	126	170 / 80	214	0.6	-0.2	1.8	19.83
PK-EXERCISE	15:40	0:40	8.8	20	132	170 / 80	224	0.2	-0.6	1.3	
RECOVERY	17:2	0:55			96	160 / 80	153	0.6	-0.5	1.3	
RECOVERY	18:2	1:55			83	150 / 80	124	0.5	-0.3	0.7	
RECOVERY	19:2	2:55			76	140 / 80	106	0.4	-0.1	0.8	
RECOVERY	19:45	3:38			78	120 / 80	93	0.5	-0.2	0.8	

**RESULTS**

EXERCISE DURATION : 15:40  
 MAX HEART RATE : 139 bpm  
 MAX BLOOD PRESSURE : 170 / 80 mm Hg  
 REASON OF TERMINATION : Fatigue,  
 BP RESPONSE : Normal,  
 ARRYTHMIA : None,  
 H.R. RESPONSE : Normal Chronotropic Response,  
**IMPRESSIONS**  
 :  
**Inconclusive**

MAX WORK LOAD : 20.00 METS

Dr. Karan Singh (Cardiology)  
 MRES (M.D. in Cardiology)  
 02848

Technician :

UNIT-EM, Indore, Tel.: +91-731-493035, Fax: +91-731-403180, E-Mail: em@electromedical.com, www.em.com



# THE DIAGNOSTIC & IMAGING CENTRE

SHOBIIT SINGHAL  
I.D. 3504  
Age 31/M  
Date 08-11-2022

RATE 67bpm  
B.P. 120/80

PRETEST  
SUPINE

ST @ 10mm/mV  
80ms PostJ

LINKED MEDIAN

Mag. X 2

III

I  
1.0  
0.7

aVR  
-1.0  
-0.8

V1  
-0.1  
-0.2

V4  
1.3  
1.1

II  
0.9  
0.8

aVL  
0.5  
0.3

V2  
2.6  
1.8

V5  
1.1  
1.1

III  
-0.1  
0.1

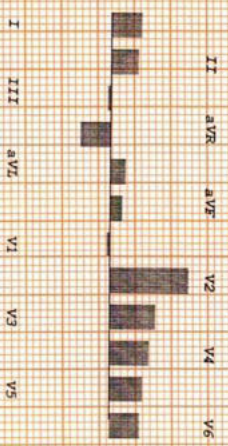
aVF  
0.4  
0.4

V3  
1.5  
1.3

V6  
1.0  
0.9

-0.1  
0.1

II



*Dr. N. M. S. S.*

SHOBHIT SINGHAL  
I.D. 3504  
Age 31/M

Date 08-11-2022

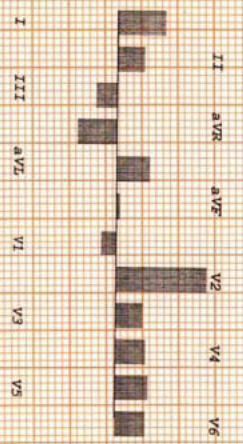
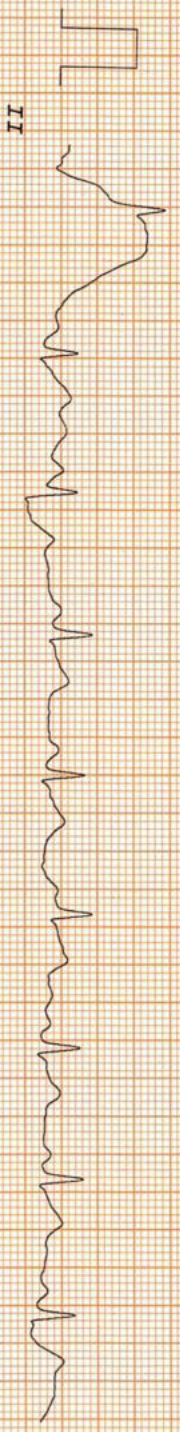
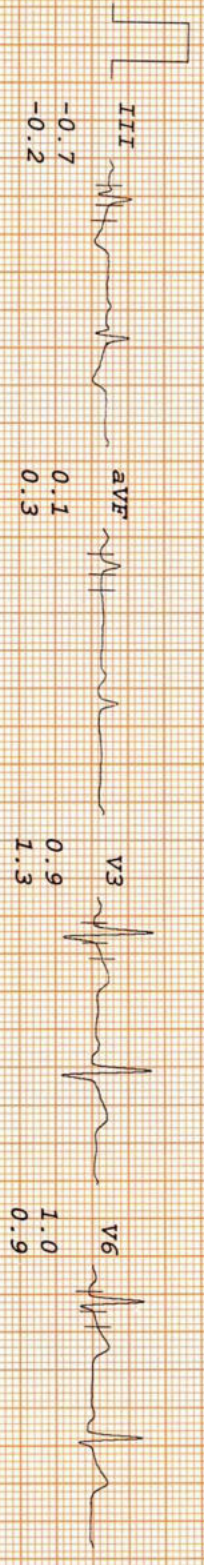
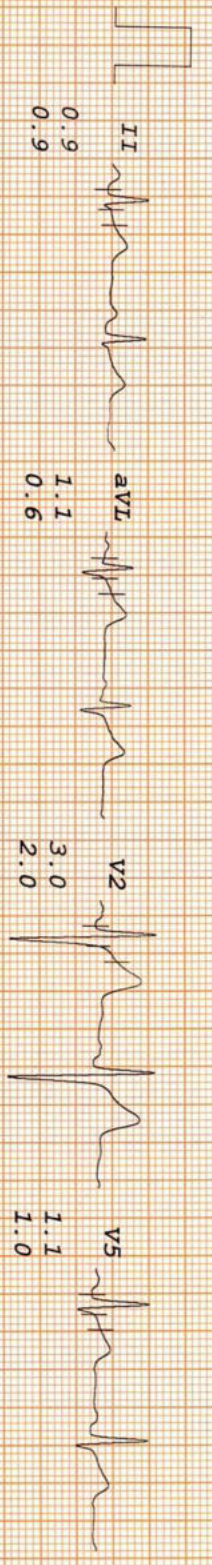
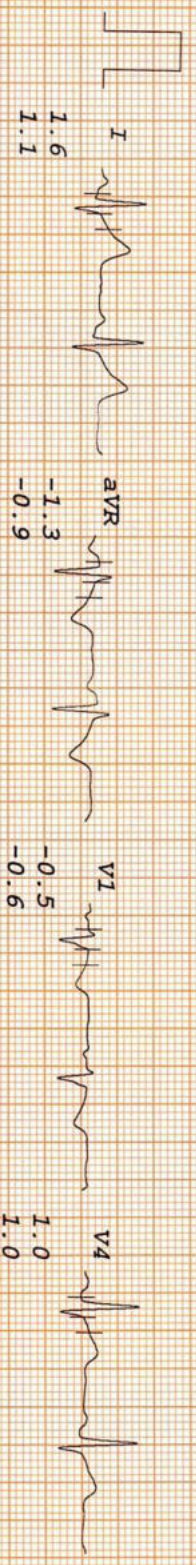
THE DIAGNOSTIC & IMAGING CENTRE

RATE 84bpm  
B.P. 120/80

PRETEST  
STANDING

ST @ 10mm/mV  
80ms PostJ

LINKED MEDIAN



Mag. X 2

III

THE DIAGNOSTIC & IMAGING CENTRE

SHOHLI SINGHAL

I.D. 3504

Age 31/M

Date 08-11-2022

RATE 80bpm

B.P. 120/80

PRETEST  
HYPERVENT

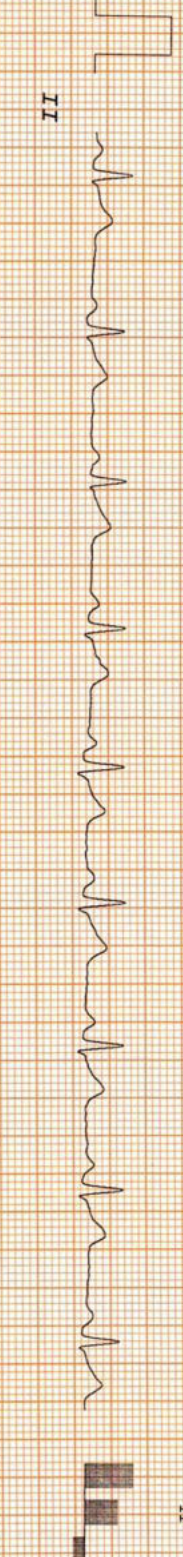
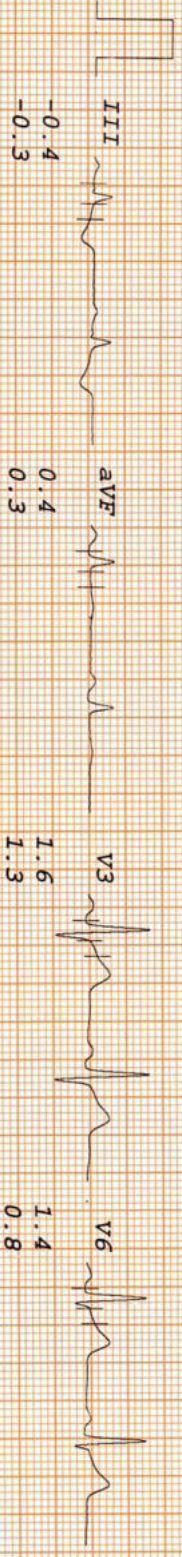
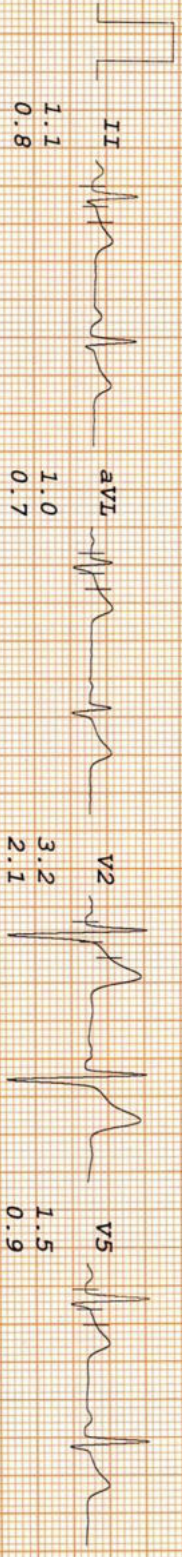
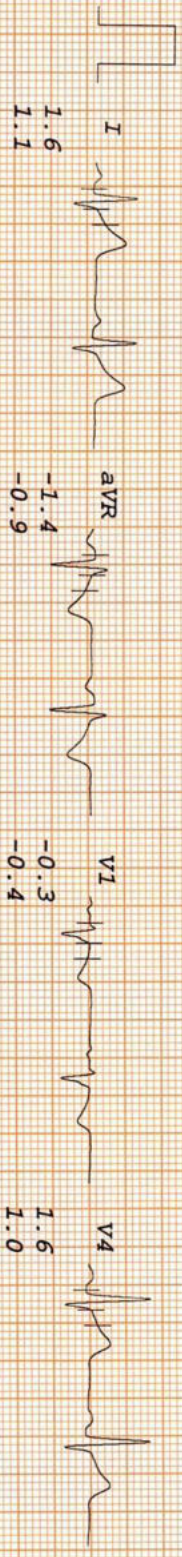
PHASE TIME 0:26

ST @ 10mm/mv  
80ms PostJ


LINKED MEDIAN

Mag. X 2

III



-0.4  
-0.3



# THE DIAGNOSTIC & IMAGING CENTRE

SHOBHIT SINGHAL  
 I.D. 3504  
 Age 31/M  
 Date 08-11-2022

Rate 89bpm  
 B.P. 130/80

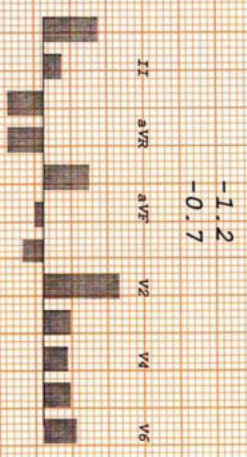
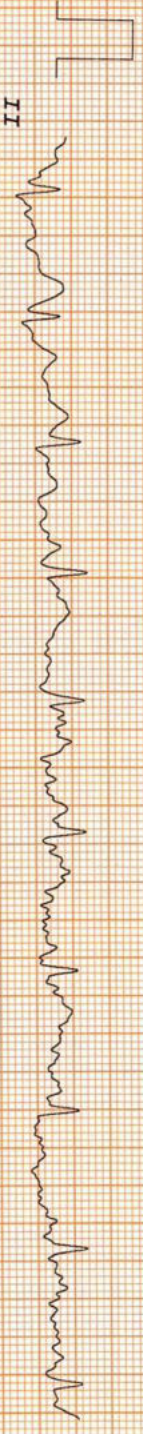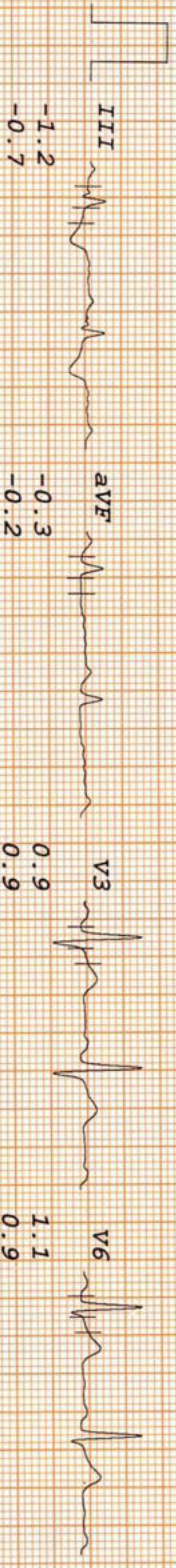
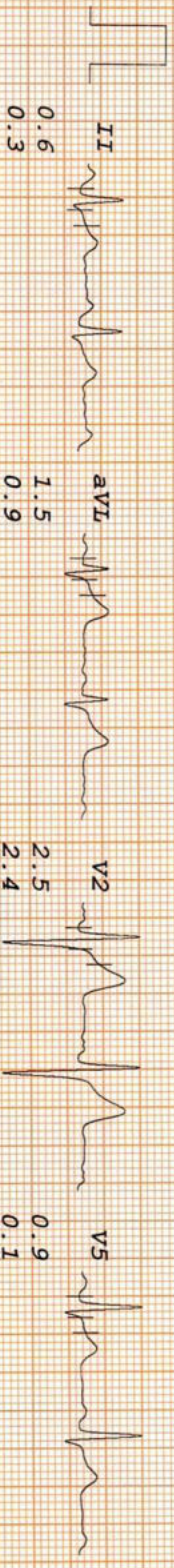
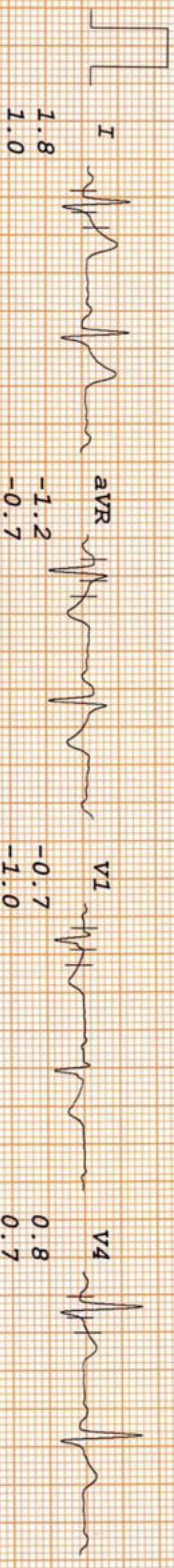
Bruce  
 Stage 1  
 TOTAL TIME 2:55  
 PHASE TIME 2:55

ST @ 10mm/mV  
 80ms PostJ  
 Speed 2.7 km/hr  
 SLOPE 10 %

LINKED MEDIAN

Mag. X 2

III



# THE DIAGNOSTIC & IMAGING CENTRE

SHOBHIT SINGHAL  
I.D. 3504  
Age 31/M  
Date 08-11-2022

RATE 96bpm  
B.P. 140/80

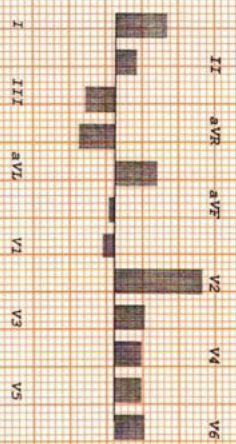
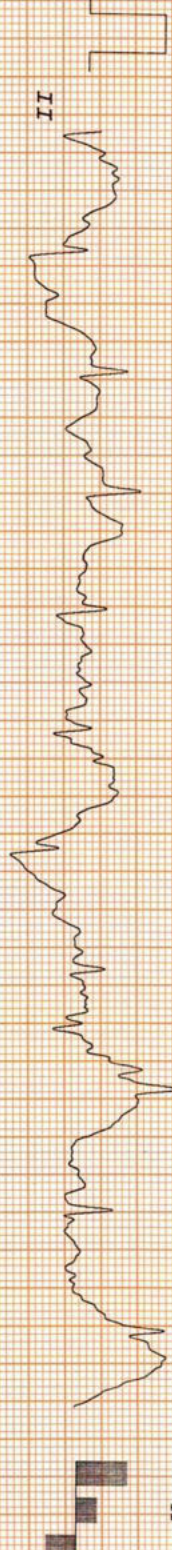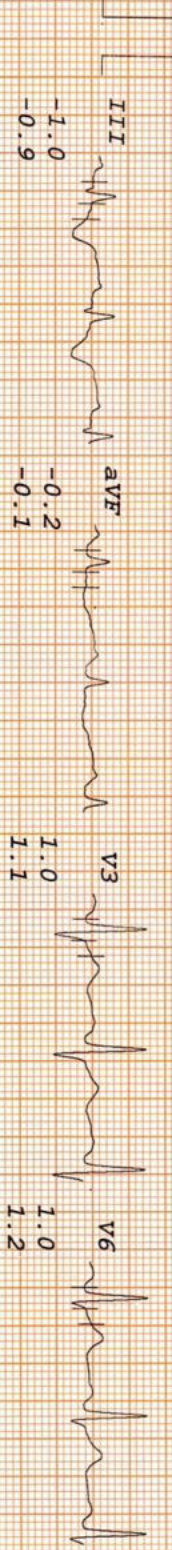
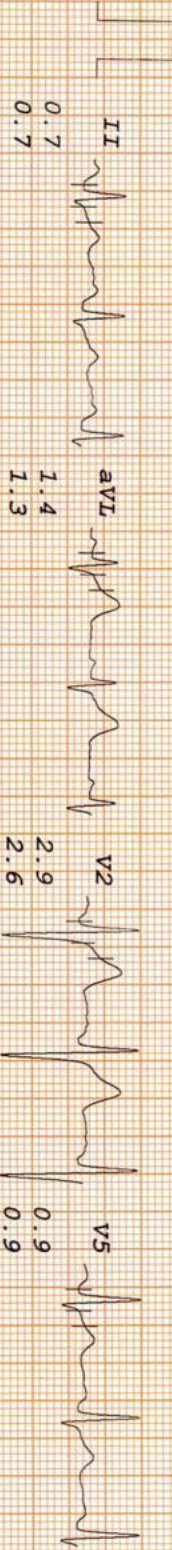
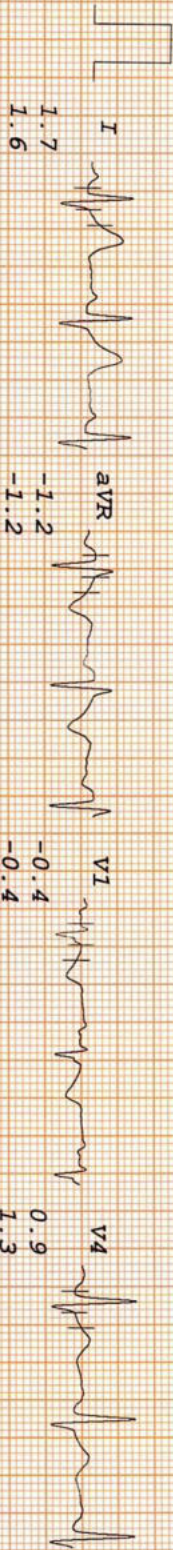
Bruce  
Stage 2  
TOTAL TIME 5:55  
PHASE TIME 2:55

ST @ 10mm/mV  
80ms PostJ  
Speed 4 km/hr  
SLOPE 12 &

LINKED MEDIAN

Mag. X 2

III



# THE DIAGNOSTIC & IMAGING CENTRE

SHOBHIT SINGHAL  
 I.D. 3504  
 Age 31/M  
 Date 08-11-2022

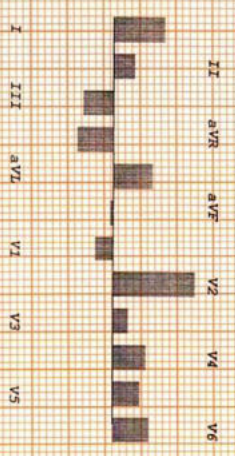
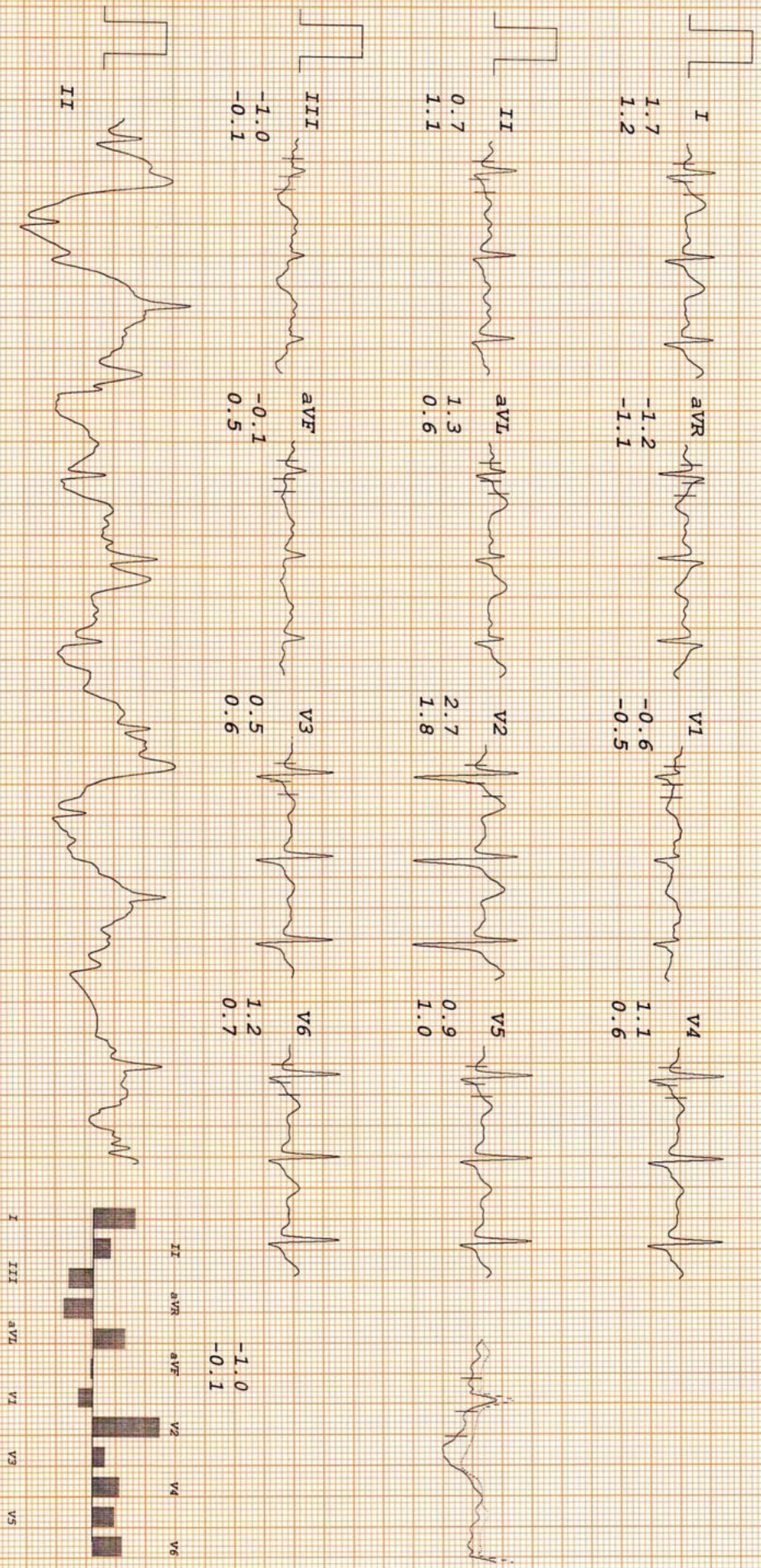
RATE 113bpm  
 B.P. 150/80  
 Bruce  
 Stage 3  
 TOTAL TIME 8:55  
 PHASE TIME 2:55

ST @ 10mm/mv  
 80ms PostJ  
 Speed 5.4 km/hr  
 SLOPE 14 8

LINKED MEDIAN

Mag. X 2

III



# THE DIAGNOSTIC & IMAGING CENTRE

SHOBIIT SINGHAL  
 I. D. 3504  
 Age 31/M  
 Date 08-11-2022

RATE 116bpm  
 B.P. 160/80


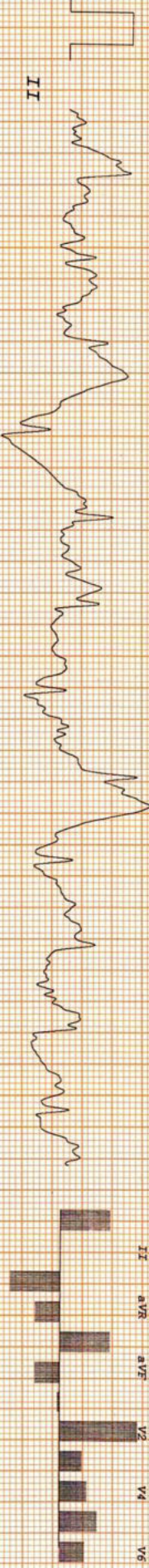
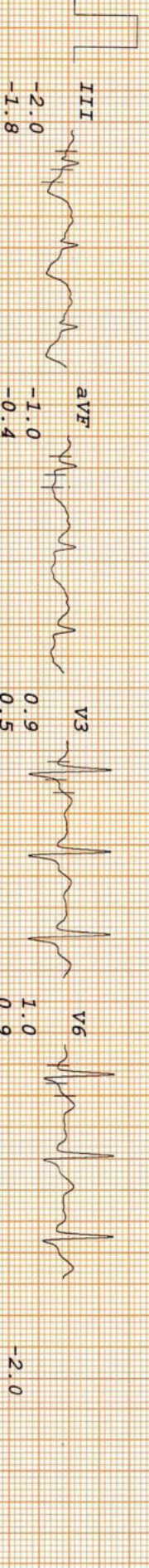
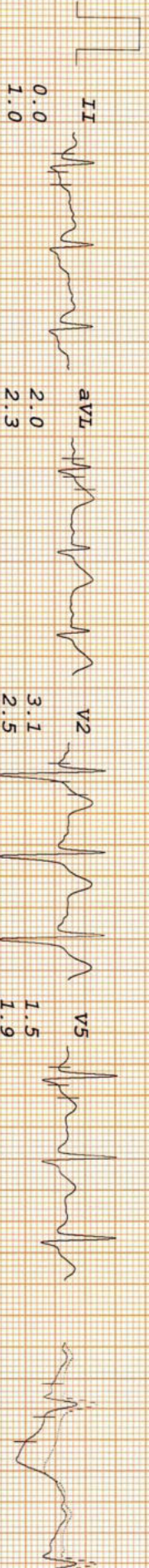
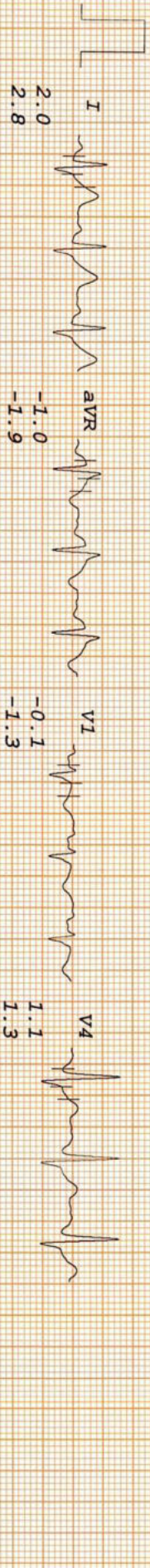
Bruce  
 Stage 4  
 TOTAL TIME 11:55  
 PHASE TIME 2:55

ST @ 10mm/mV  
 80ms PostJ  
 Speed 6.7 km/hr  
 SLOPE 16 %

LINKED MEDIAN

Mag. X 2

III



# THE DIAGNOSTIC & IMAGING CENTRE

SHOBHIT SINGHAL  
 I.D. 3504  
 Age 31/M  
 Date 08-11-2022

RATE 126bpm  
 B.P. 170/80


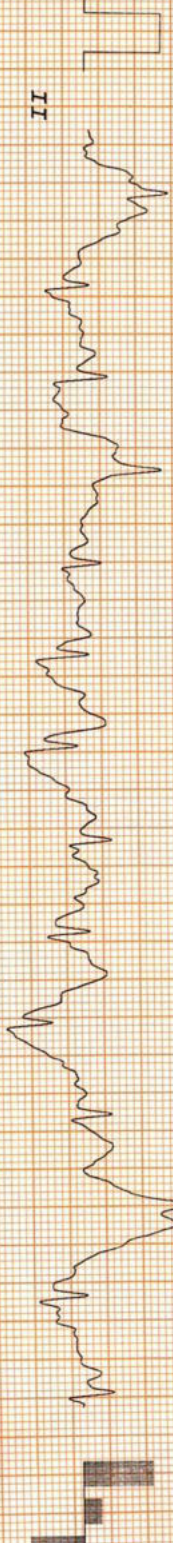
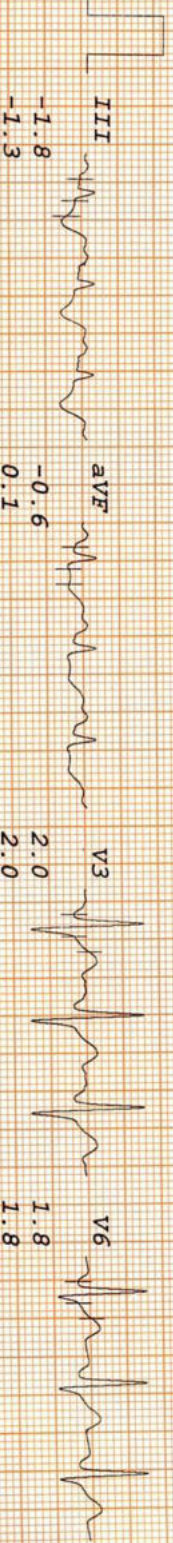
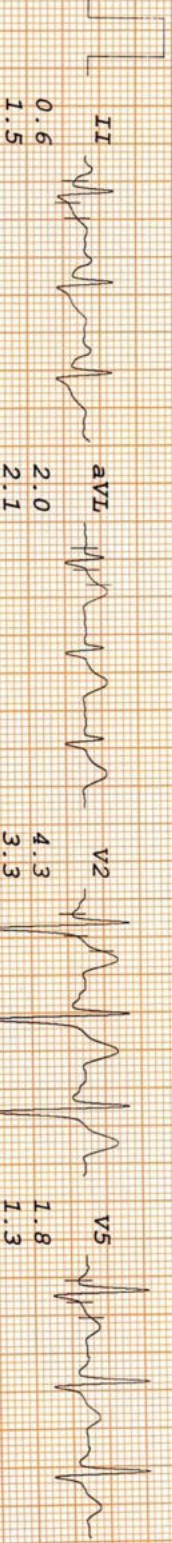
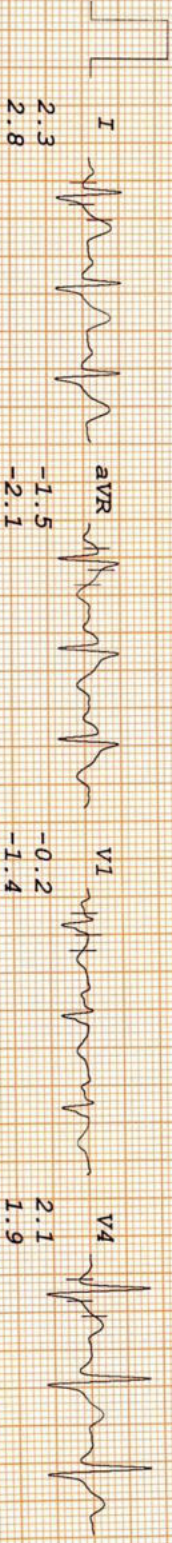
Bruce  
 Stage 5  
 TOTAL TIME 14:55  
 PHASE TIME 2:55

ST @ 10mm/mV  
 80ms PostJ  
 Speed 8 km/hr  
 SLOPE 18 &

LINKED MEDIAN

Mag. X 2

III





# THE DIAGNOSTIC & IMAGING CENTRE

SHOHIT SINGHAL  
I.D. 3504  
Age 31/M  
Date 08-11-2022

RATE 132bpm  
B.P. 170/80

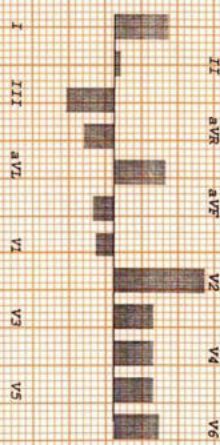
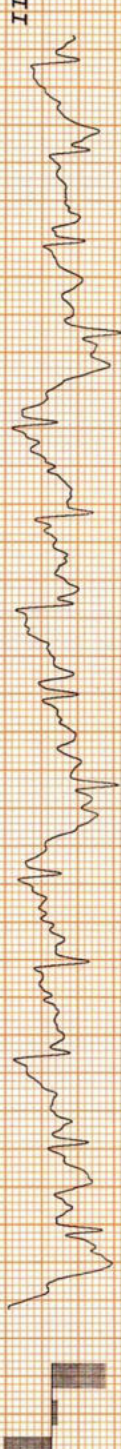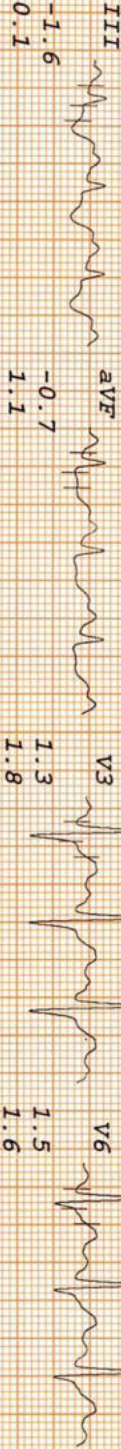


Bruce  
PK-EXERCISE  
TOTAL TIME 15:40  
PHASE TIME 0:40

ST @ 10mm/mV  
80ms PostJ  
Speed 8.8 km/hr  
SLOPE 20 %

LINKED MEDIAN

Mag. X 2

III



# THE DIAGNOSTIC & IMAGING CENTRE

SHOBHIT SINGHAL  
I.D. 3504  
Age 31/M  
Date 08-11-2022

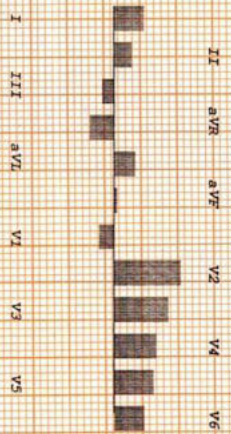
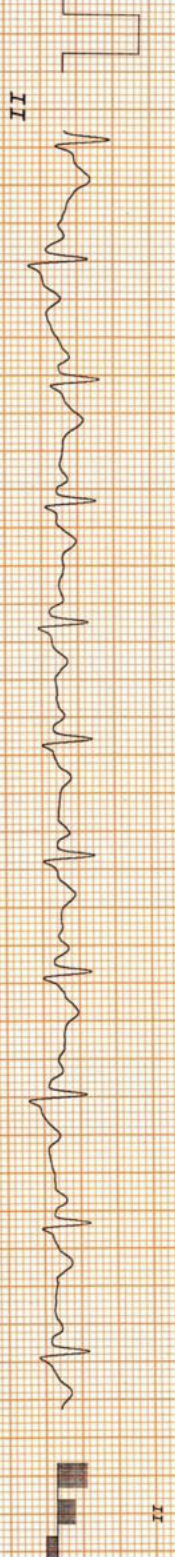
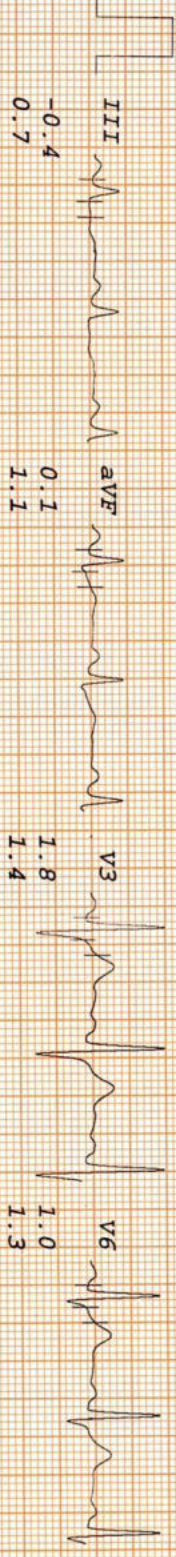
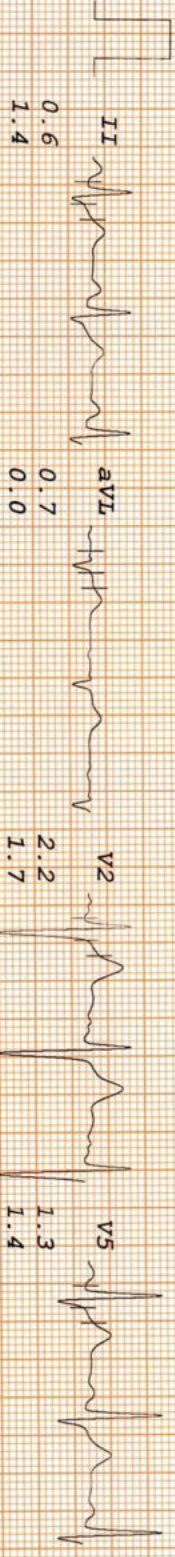
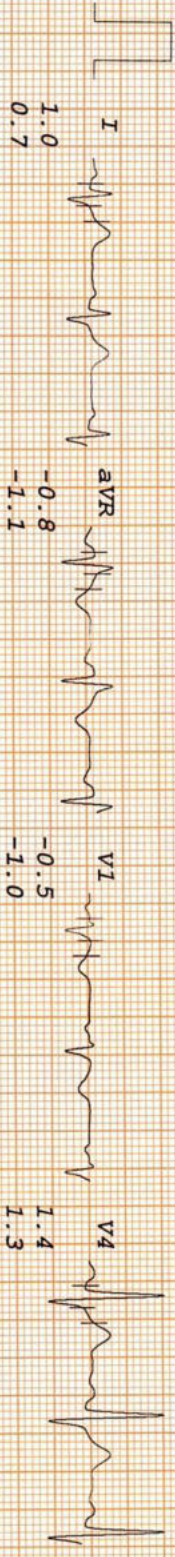
Rate 96bpm  
B.P. 160/80  
Bruce  
RECOVERY  
TOTAL TIME 17:02  
PHASE TIME 0:55

ST @ 10mm/mV  
80ms PostJ

LINKED MEDIAN

Mag. X 2

III



SHOBHIT SINGHAL  
 I.D. 3504  
 Age 31/M  
 Date 08-11-2022

RATE 83bpm  
 B.P. 150/80

**THE DIAGNOSTIC & IMAGING CENTRE**

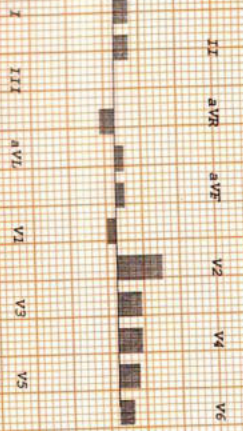
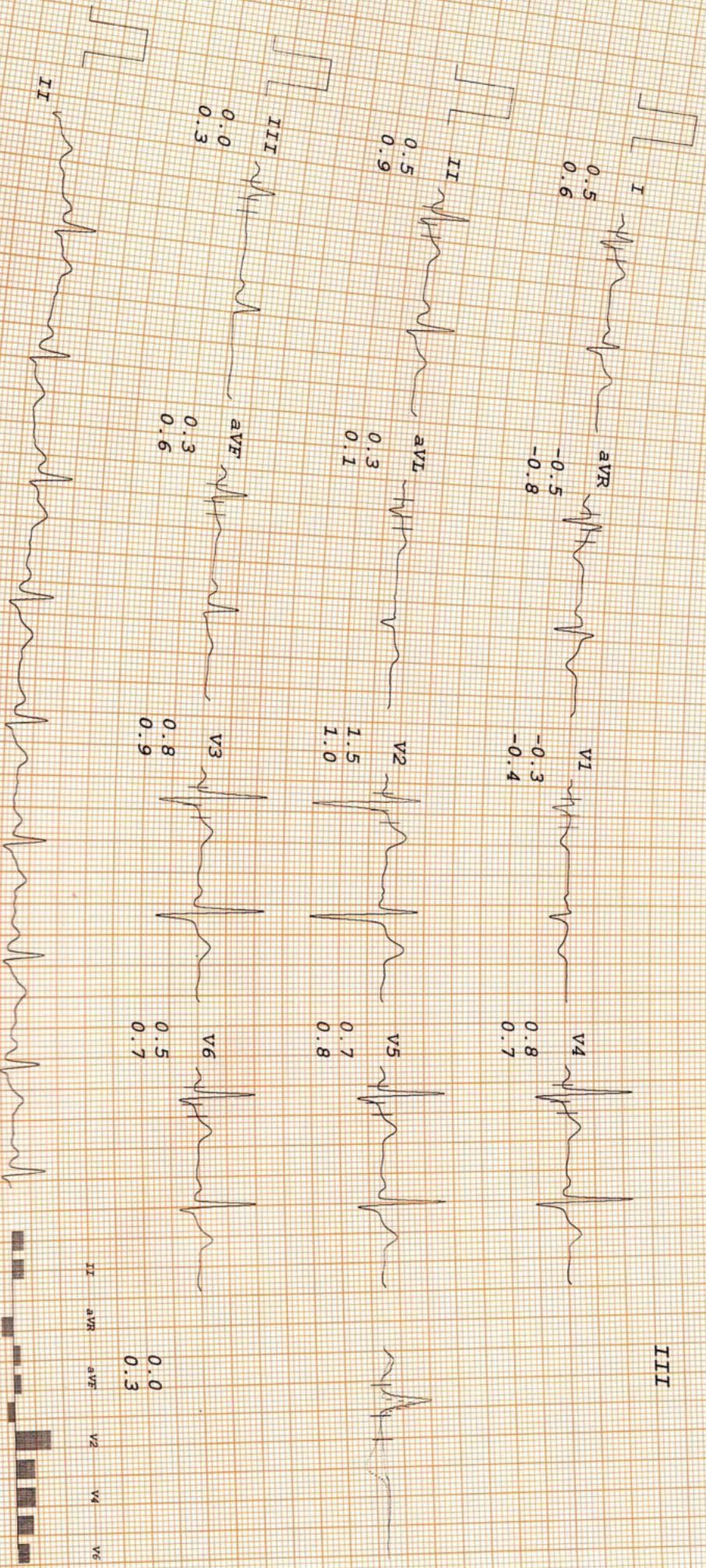
Bruce  
 RECOVERY  
 TOTAL TIME 18:02  
 PHASE TIME 1:55

ST @ 10mm/mV  
 80ms PostJ

LINKED MEDIAN

Mag. X 2

III



# THE DIAGNOSTIC & IMAGING CENTRE

SHOBHIT SINGHAL  
I.D. 3504  
Age 31/M  
Date 08-11-2022

RATE 76bpm  
B.P. 140/80

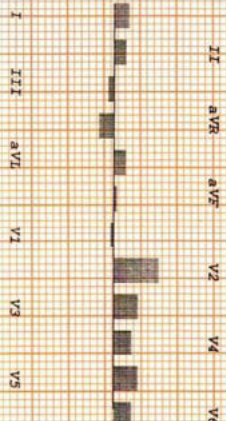
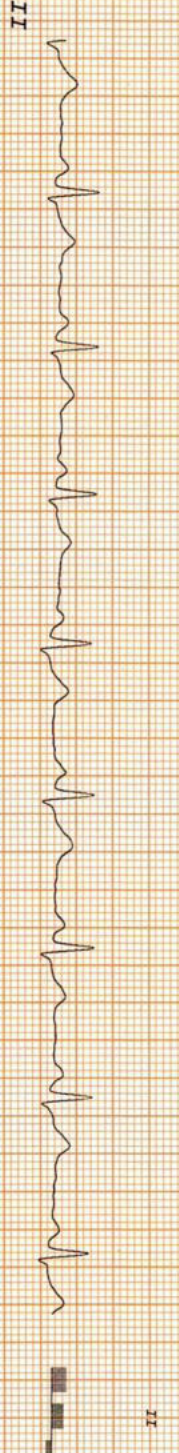
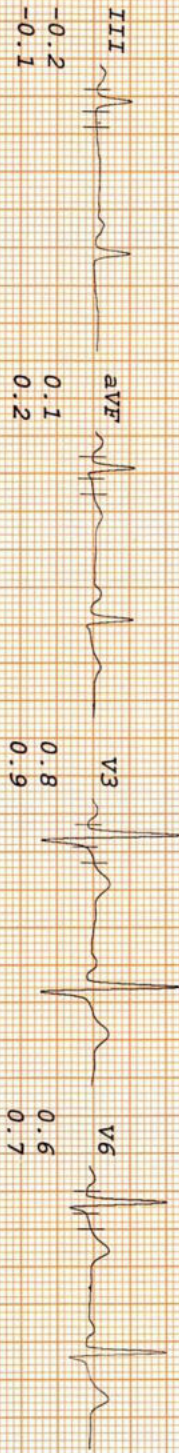
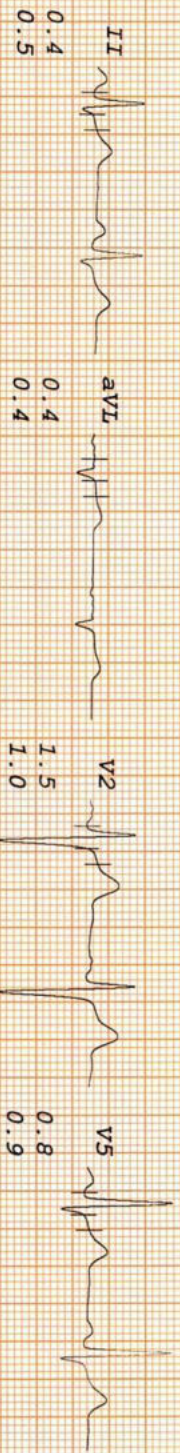
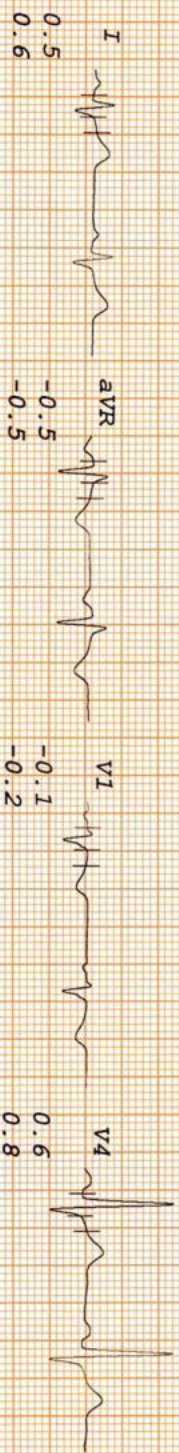
Bruce  
RECOVERY  
TOTAL TIME 19:02  
PHASE TIME 2:55

ST @ 10mm/mV  
80ms PostJ

LINKED MEDIAN

Mag. X 2

III



# THE DIAGNOSTIC & IMAGING CENTRE

SHOBHIT SINGHAL

I.D. 3504

Age 31/M

Date 08-11-2022

RATE 78bpm  
B.P. 120/80

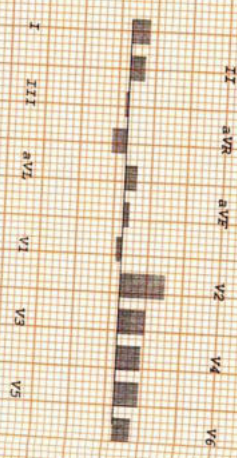
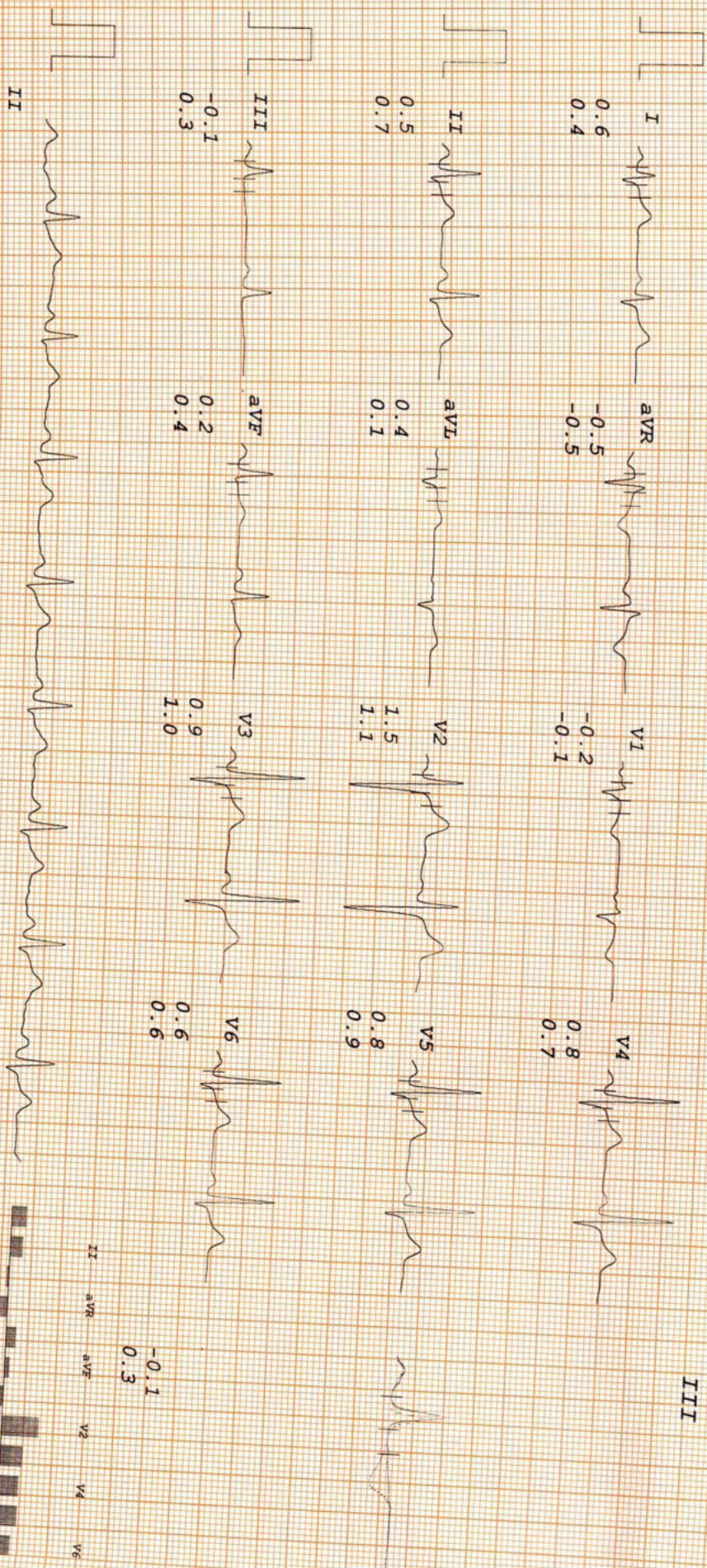
Bruce  
RECOVERY  
TOTAL TIME 19:45  
PHASE TIME 3:38

ST @ 10mm/mV  
80ms PostJ

LINKED MEDIAN

Mag. X 2

III



ID: 17

shobhit singhat

Male, 31 Years

Req. No. :

08-11-2022 09:43:21 AM

HR : 70 bpm

P : 106 ms

PR : 150 ms

QRS : 88 ms

QT/QTcBz : 372/402 ms

P/QRS/T : 35/28/-1 °

RV5/SV1 : 1.103/0.497 mV

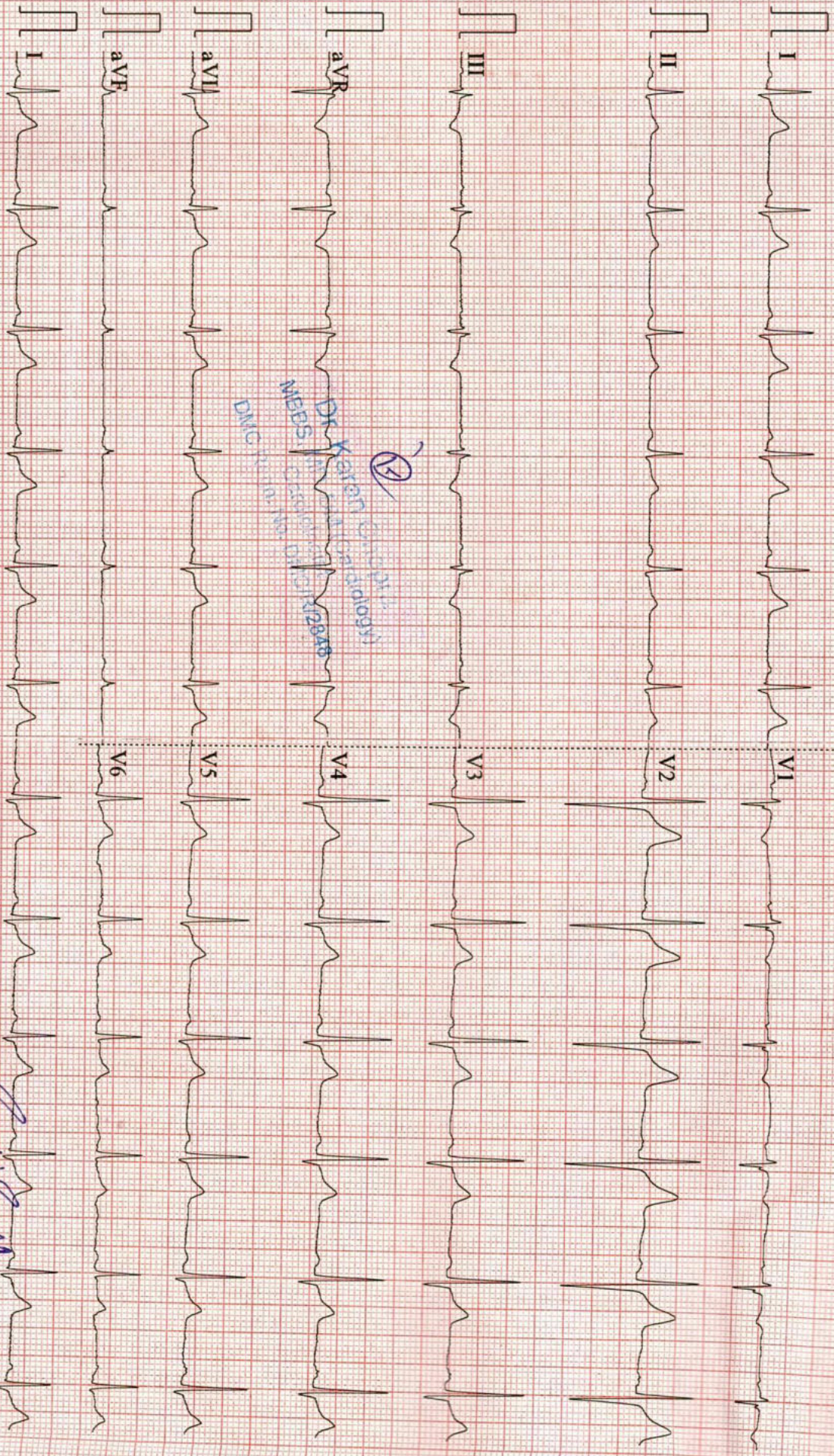
Diagnosis Information:

Sinus rhythm

Inferior T wave abnormality is nonspecific

Borderline ECG

Report Confirmed by:



0.67-45Hz AC50 25mm/s 10mm/mV 2\*5.0s+1r CARDIART 9

V1.44 Glasgow V28.6.7

Signature