

भारत सरकार
Government of India

सोनली बंद्योपाध्याय
Sonali Bandyopadhyay

जन्म तिथि / DOB : 03/11/1985
महिला / Female

3956 3286 9397

मेरा आधार, मेरी पहचान



Sonali



भारतीय विशिष्ट पहचान अधिकरण
Unique Identification Authority of India



पता: अंधागिरी, अनिर्बाण बंद्योपाध्याय, फ्लैट नं-248
,, संस्कृति अपार्टमेंट, ओपेस्टि ओपीजी वर्ल्ड स्कूल,
,, सेक्टर-19बी द्वारका, द्वारका सेक्टर 19, द्वारका
सेक्टर - 6, दक्षिण पश्चिमी दिल्ली, दिल्ली, 110075
Address: W/O: Anirban Bandyopadhyay, FLAT
NO-248 ,, SANSKRITI APRTMENT, OPPOSITE
OPG WORLD SCHOOL, SECTOR-19B
DWARAKA, Dwarka Sector 19, Dwarka Sec-6,
South West Delhi, Delhi, 110075

3956 3286 9397




1947



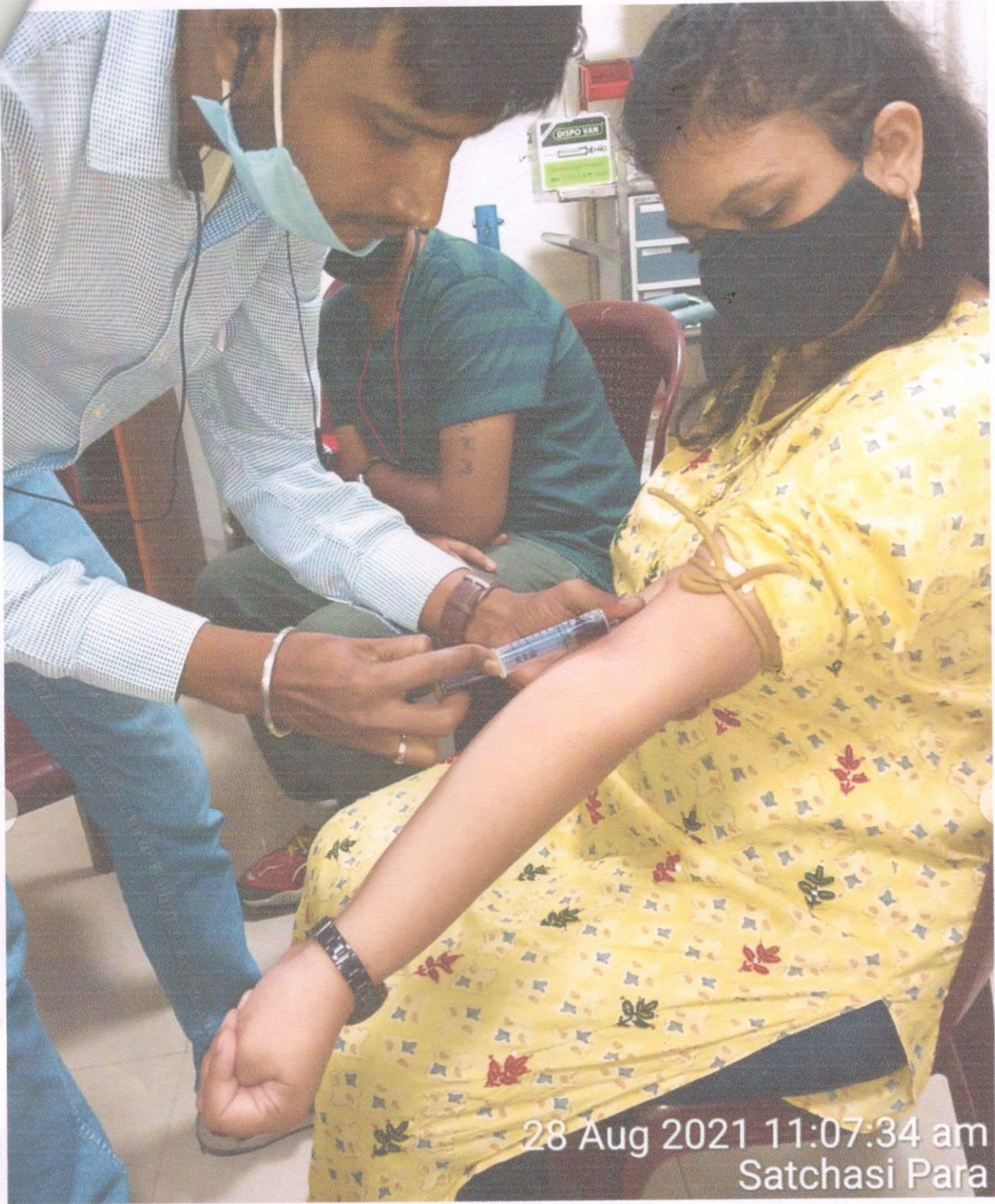help@uidai.gov.in

WWW


www.uidai.gov.in



28 Aug 2021 10:23:10 am



28 Aug 2021 11:07:34 am
Satchasi Para



REDMI NOTE 6 PRO
MI DUAL CAMERA

2021/8/28 14:48

NAME:MRS. SONALI BANDYOPADHYAY	AGE: 35YRS	SEX:FEMALE
REF BY : SELF(CORPORATE)	MR NO:FSIN-0000	DATE:28/08/2021

ULTRASOUND OF WHOLE ABDOMEN

LIVER: Liver is **Enlarged** in size (**16.38cm**) shape, outline and echotexture. The intrahepatic tubular structures are normal. No focal area of alterea echogenicity is noted. The porta hepatis is normal. The common bile duct measures **4mm** in diameter .The portal vein measures **9mm** at porta.

GALL BLADDER: Gall bladder is normal .Wall is normal limits. No calculus or mass is seen within the gall bladder.

PANCREAS: It is normal in size, Shape, Outline and echotexture. Pancreatic duct is not dilated.

SPLEEN: It is normal in size **11.55cm**, Shape, Outline and echotexture. No parenchymal lesion is noted.

RIGHT KIDNEY: kidney are normal in position, size, shape, outline and echotexture .The cortico medullary differentiation is maintained. No calculus or hydronephrosis is seen.

RIGHT KIDNEY: measures – **9.40cm**.

LEFT KIDNEY: kidney are normal in position, size, shape, outline and echotexture. The cortico medullary differentiation is maintained. No calculus or hydronephrosis is seen.

LEFT KIDNEY: measures –**9.45cm**.

URINARY BLADDER: It is well distended with normal wall thickness. No calculus or mass is seen within the urinary bladder.

UTERUS: It is **Bulky** size, shape and echotexture. It is anteverted. No sol is seen in the myometrium. Uterine cavity is empty. Uterus measures- (**11.45cmX5.24cmX4.56cm**). Endometrial thickness is normal measures- **0.77cm**.

RIGHT OVARIES- They are **enlarged** in size, shape ,outline and echotexture. measures-(**3.90cmX3.07cmX2.50cm**) Vol- 15ml

LEFT OVARIES- They are **enlarged** in size, shape ,outline and echotexture. measures-(**3.41cmX3.37cmX2.31cm**) Vol- 14ml

NAME:MRS. SONALI BANDYOPADHYAY	AGE: 35YRS	SEX:FEMALE
REF BY : SELF(CORPORATE)	MR NO:FSIN-0000	DATE:28/08/2021

* Both ovaries enlarged & polycystic changes.

IMPRESSION:

- HEPATOMEGALY.
- BILATERAL POLYCYSTIC OVARY.



DR.A.K.ROY

M.B.B.S, Dip BMSc, DTM&H (Cal)

Certificate on CEBT Abdomino Pelvic, USG(WBHSU)

APOLLO CLINIC @ OM TOWER
Opp. of Rabindra Bharati University
Licensee : Satyam Credit Pvt. Ltd.

36C, B.T. Road, Kolkata - 700 002

E-mail : sinthimor@theapolloclinic.com
satyamcreditpvtltd@gmail.com

 **033 2556 3333**

 **033 2556 5555**

 **+91 98521 66666**

 **+91 74392 97827**

DEPARTMENT OF RADIOLOGY X-RAY REPORT OF CHEST-PA

MR. NO- FSIN.00000000

SEX- FEMALE

NAME- SONALI BANDYOPADHYAY

EXAMINATION DATE- 28/08/21


AGE- 35 YRS

REPORT DATE- 28/08/21

REF DR- SELF

FINDINGS:

- Bilateral lung fields are clear.
- Tracheal shadow is in the midline.
- Bilateral CP angle are clear.
- Both hila appear unremarkable.
- CTR within normal limit.
- No definite bone fracture is noted.


DR. ARNAB MANDAL


MD, Physician, PGDUS (Delhi) CEFT-USG (WBUHS KOLKATA)
Fellow of Jefferson Ultrasound Radiology and Education Institute
Philadelphia Ex-Radiology Resident (S.E. Railway)
Regd.No:72022(WBMC)

APOLLO CLINIC @ OM TOWER
Opp. of Rabindra Bharati University

Licensee : Satyam Credit Pvt. Ltd.

36C, B. T. Road, Kolkata - 700 002

E-mail : sinthimor@theapolloclinic.com
satyamcreditpvtltd@gmail.com

 **033 2556 3333**

 **033 2556 5555**

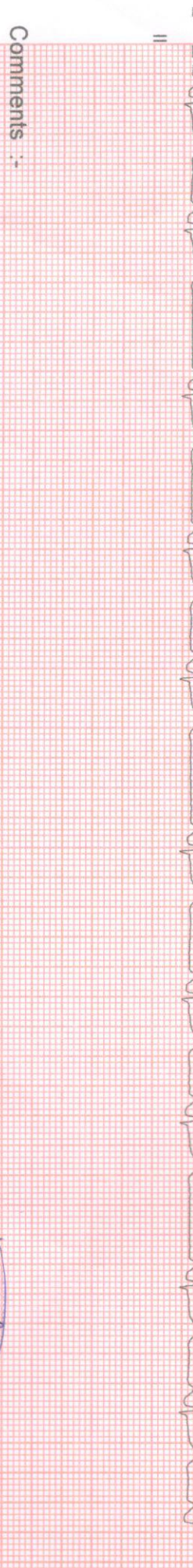
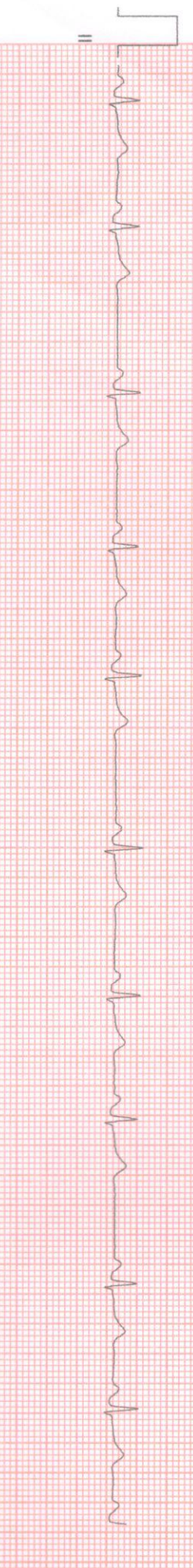
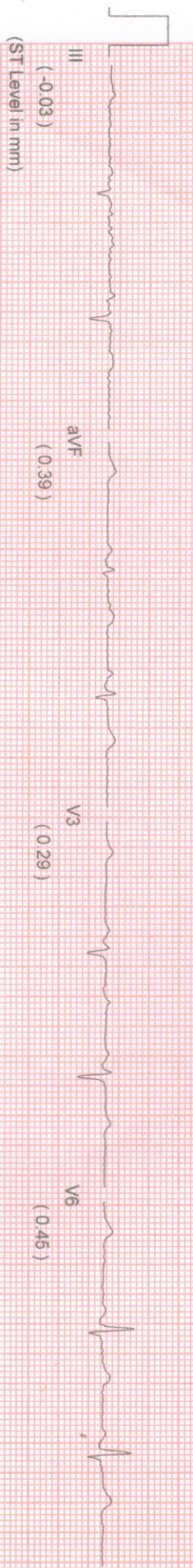
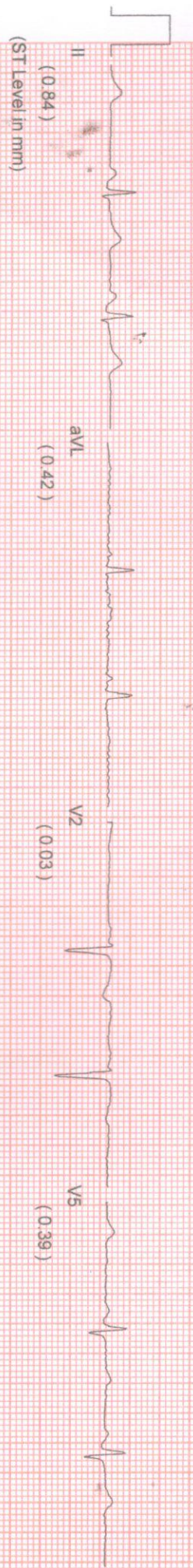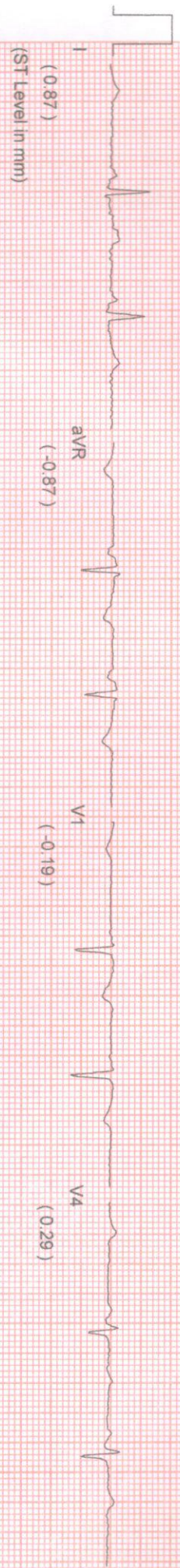
 **+91 98521 66666**

 **+91 74392 97827**

Patient Name: Mrs. SONALI BANDYOPADHYAY 35/F

Resting ECG Report

August 28, 2021
Time: 13:43:52
QT / QTc : 0.460 / 0.462 Sec
P-R-QRS-T Axis (26)-(20)-(30) deg
PR Interval: 0.12 sec
QRS Duration: 0.060 Sec
RR Interval: 0.99 sec
HR : 60 bpm
BP : 110 / 80 mmHg



Comments :-

Sonali

NAME: MRS. SONALI BANDYOPADHYAY	MR NO: FSIN-0000	DATE : 28.08.2021
AGE: 35YRS.	SEX:FEMALE	REF BY: SELF(CORPORATE)

ECG REPORT

HR : 60 b/min
AXIS : NORMAL
RHYTHM : SINUS
PR INTERVAL : 0.12 sec
QT INTERVAL : 0.462 sec
QRS DURATION : 0.060 sec
T-WAVE : NORMAL

IMPRESSION:

- RESTING ECG IS WITHIN NORMAL LIMITS.



Dr. SIDDHARTHA KUNDU
MBBS (Cal), PGDCC, CCEBDM
Clinical Cardiologist
Ex Sr Resident, Cardiology Dept
B.R Singh Hospital, Eastern Railway

