





Signature

Signature

Dr. POOJA GARG
M.B.B.S., D.M.R.D
Reg No. DMC/R/03388
Radiologist

ONEPLUS ULTRASCUND LAB
47, Hareh Vihar, Pitam Pura,
Delhi-110034
Ph. 011-42480101, 9599913051
E-mail: oneplusul@gmail.com


 भारत सरकार
 Government of India


 कन्हैया रत्नाकर सक्सेना
 Kanhayia Ratnakar Saxena
 जन्म तिथि/DOB: 10/02/1988
 पुरुष/ MALE

6130 0407 1176
 VID : 9113 0228 5681 2703

मेरा आधार, मेरी पहचान

Saxena


QR Code with Photograph
 6130 0407 1176
 VID : 9113 0228 5681 2703

Address:
 C/O Jagdish Prasad, DDA Flat no-50 3rd
 Floor, Block-B2 Pocket-3 sec-G-8
 Opposite CRPF Camp, Narela, North
 West Delhi
 Delhi - 110040

रतः
 C/O सक्सेना रत्नाकर, डीडीए फ्लॉट नं-50 तीसरी फ्लॉर,
 ब्लॉक-बी2 पॉकेट-3 सेक-जी-8
 सामने, एनएफएल कैंप, नरेला,
 पश्चिम दिल्ली
 दिल्ली - 110040

भारत सरकार
 Government of India

ONEPLUS ULTRASOUND LAB
 47, Harsh Vihar, Pitam Pura,
 Delhi-110034
 Ph. 011-42480101, 9599913051
 E-mail: oneplusul@gmail.com


 Dr. POOJA GARG
 M.B.B.S., D.M.R.D
 Reg No. DMC/R/03398
 Radiologist

To

One Plus Ultrasound Lab
Harsh Vihar

Sir, I Kanhaiya Ratnakar Saxena EC- No- 169457.
Due to some reason I cannot able to to
Stool test. Please Consider it.

Kanhaiya Ratnakar Saxena
EC- 169457
Mob:- 7678137667


DR. POOJA GARG
M.B.B.S., D.M.R.D
Reg No. DMCR/03398
Radiologist

ONEPLUS ULTRASOUND LAB
47, Harsh Vihar, Pitam Pura,
Delhi-110034
Ph. 011-42480101, 9599913051
E-mail. oneplusul@gmail.com

ONE PLUS ULTRASOUND LAB

47, HARSH VIHAR, PITAMPURA

Mr. KANHAYIA RATNAKAR SAXENA
 Age : 33M
 Ref. by : MEDIWHEEL
 Indication1 :
 Indication2 :
 Indication3 :
 COMMENTS :

ID : 9
 HWT : 162/81
 Recorded : 28-12-2021 12:42
 Medication1 :
 Medication2 :
 Medication3 :

BPM : 109
 BP : 130/82
 P Axis : 0 deg
 QRS Axis : 0 deg
 T Axis : 0 deg

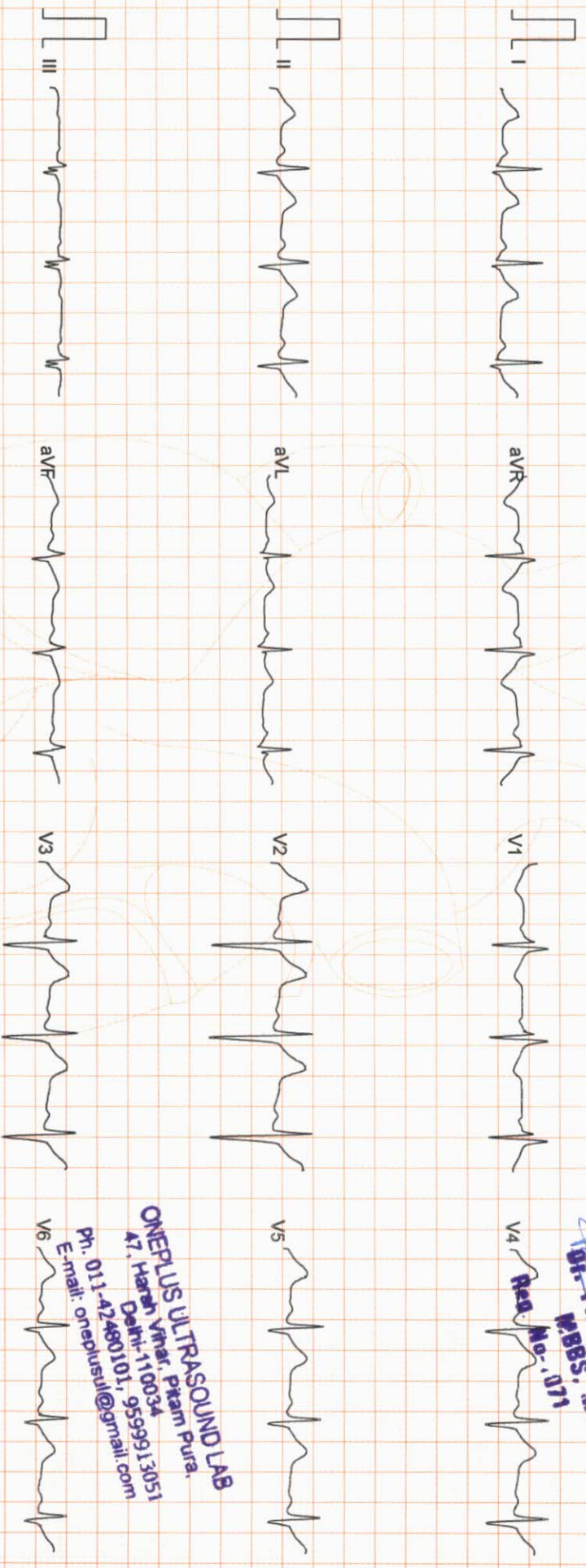
P duration : 0 msec
 PR duration : 0 msec
 QRS duration : 0 msec
 QT Interval : 0 msec
 QTc Interval : 0 msec

RAW E.C.G.

Unconfirmed Report Reviewed By:

Cardiologist

Dr. R.K. Gupta
Dr. R.K. GUPTA
M.B.B.S., MD
 Regd. No. 071



Filtered

25mm/sec 10mm/mV

CardiCom, INDIA

ONEPLUS ULTRASOUND LAB
 47, Harsh Vihar, Pitampura,
 Delhi-110034
 Ph. 011-42480101, 9599913051
 E-mail: oneplusul@gmail.com

ONE PLUS ULTRASOUND LAB

47, HARSH VIHAR, PITTAMPURA

Mr. KANHAYIA RATNAKAR SAXENA

Age/Sex : 33/M

Ref. by : MEDIWHEEL

ID : 22
 HWt : 162/81
 Recorded : 28-12-2021 12:55

TREADMILL TEST SUMMARY REPORT

Protocol: BRUCE

History:

Medication1 :
 Medication2 :
 Medication3 :

Indication1 :
 Indication2 :
 Indication3 :

PHASE	PHASE TIME	STAGE TIME	SPEED (Km/Hr.)	GRADE (%)	H.R. (BPM)	B.P. (mmHg)	RPP X100	II	ST LEVEL (mm) V2	V5	METS
SUPINE					122	130/82	158	1.7	2.5	2.0	
STANDING					130	130/82	169	1.7	2.9	1.9	
STAGE 1	2:59	2:59	2.70	10.00	143	142/86	203	1.6	3.1	2.2	4.80
STAGE 2	5:59	2:59	4.00	12.00	170	142/86	241	2.2	3.7	2.8	7.10
STAGE 3	7:29	1:29	5.40	14.00	197	170/94	334	2.4	3.4	3.4	8.54
PEAK EXER	7:30	1:30			196	170/94	333	2.4	3.4	3.4	
RECOVERY	2:59	2:59	0.00	0.00	140	134/82	187	2.7	3.6	2.8	8.56

RESULTS

Exercise Duration : 7:30 Minutes
 Max Heart Rate : 197 bpm 105 % of target heart rate 187 bpm
 Max Blood Pressure : 170/94 mmHg
 Max Work Load : 8.56 METS
 Reason of Termination :

IMPRESSIONS

Negative for ischaemic changes.



Dr. P.K. GUPTA
 Cardiologist
 Reg. No-1071

ONEPLUS ULTRASOUND LAB
 47, Harsh Vihar, Pham Pura,
 Delhi-110034
 Ph. 011-42480101, 9599513051
 E-mail: oneplusul@gmail.com

Mr. KANHAYIA RATNAKAR SAXENA
I.D. : 22
AGE/SEX : 33/M
RECORDED : 28-12-2021 12:55

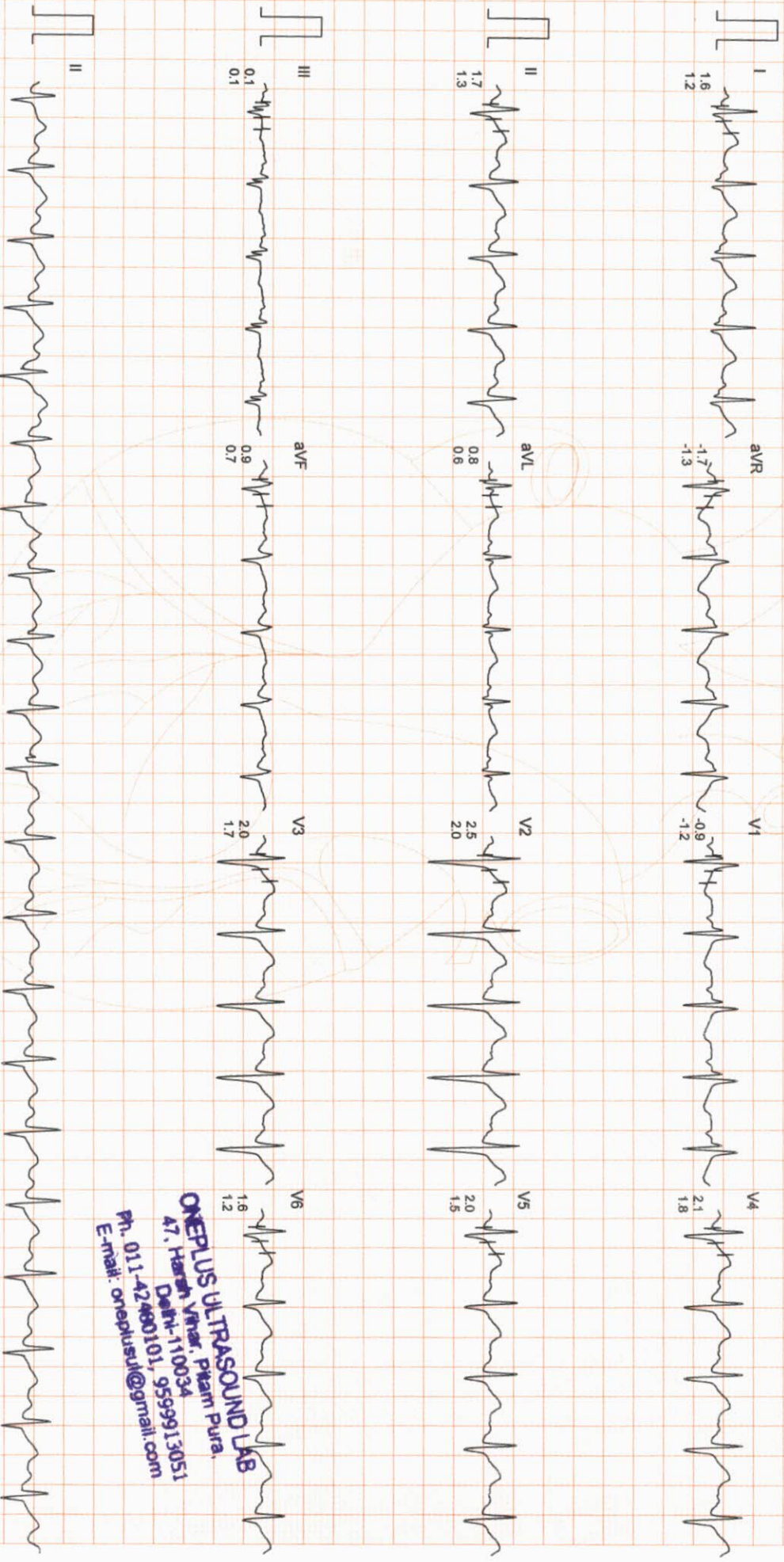
RATE : 122 BPM
B.P. : 130/82 mmHg

ONE PLUS ULTRASOUND LAB

SUPINE
PRETEST

ST @ 10mm/mV
80ms PostJ

LINKED MEDIAN



ONEPLUS ULTRASOUND LAB
47, Harsh Vihar, Pitam Pura,
Delhi-110034
Ph. 011-42460101, 9599913051
E-mail: onepusul@gmail.com

Filtered

Computer Corrected Baseline

25mm/sec 10mm/mV

CardiCom, INDIA

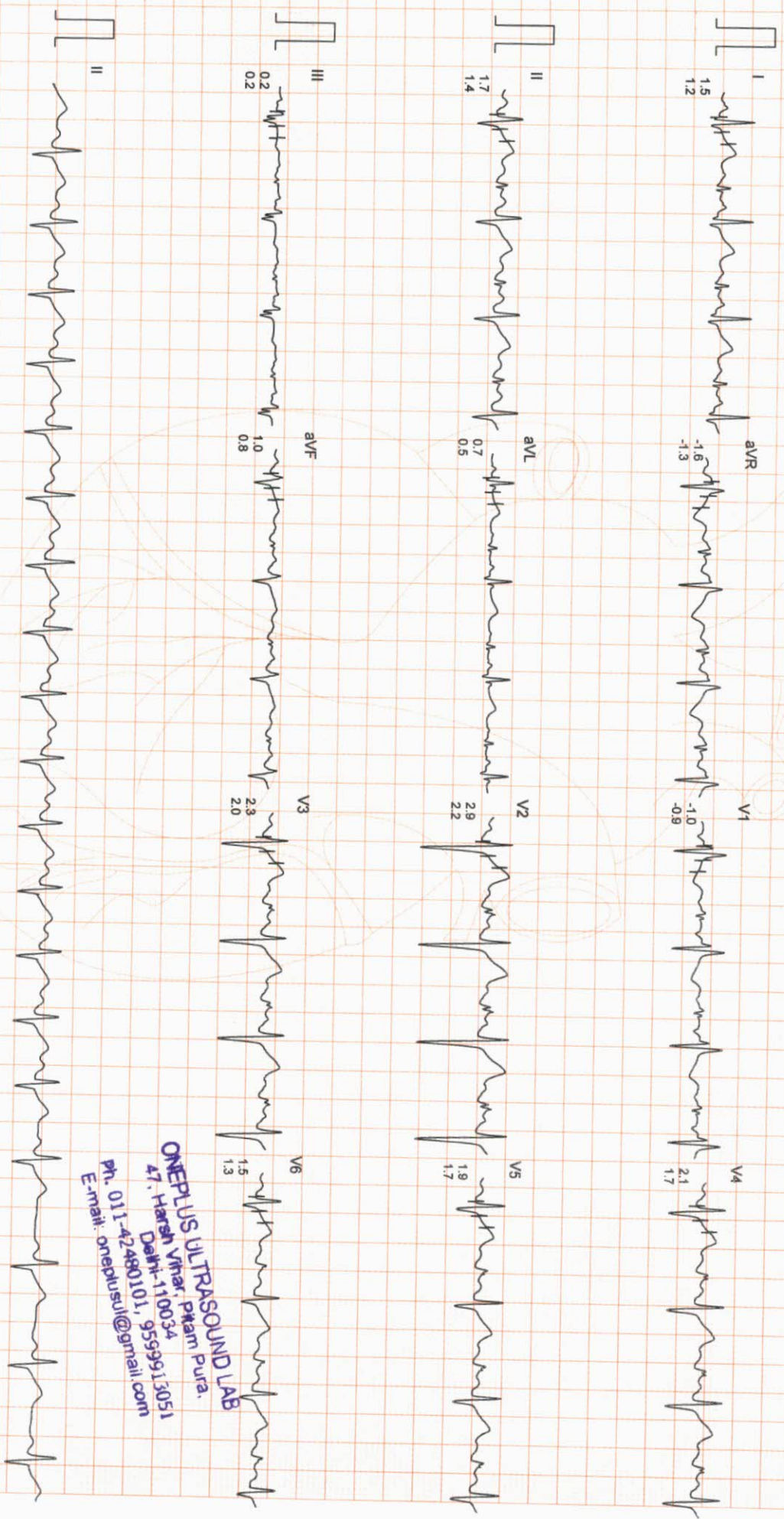
ONE PLUS ULTRASOUND LAB

STANDING
PRETEST

ST @ 10mm/mV
80ms PostJ

Mr. KANHAYIA RATNAKAR SAXENA
I.D. : 22
AGE/SEX : 33/M
RECORDED : 28-12-2021 12:55
RATE : 130 BPM
B.P. : 130/82 mmHg

LINKED MEDIAN



ONEPLUS ULTRASOUND LAB
47, Harsh Vihar, Pitam Pura,
Delhi-110034
Ph. 011-42480101, 9559913051
Email: oneplusul@gmail.com

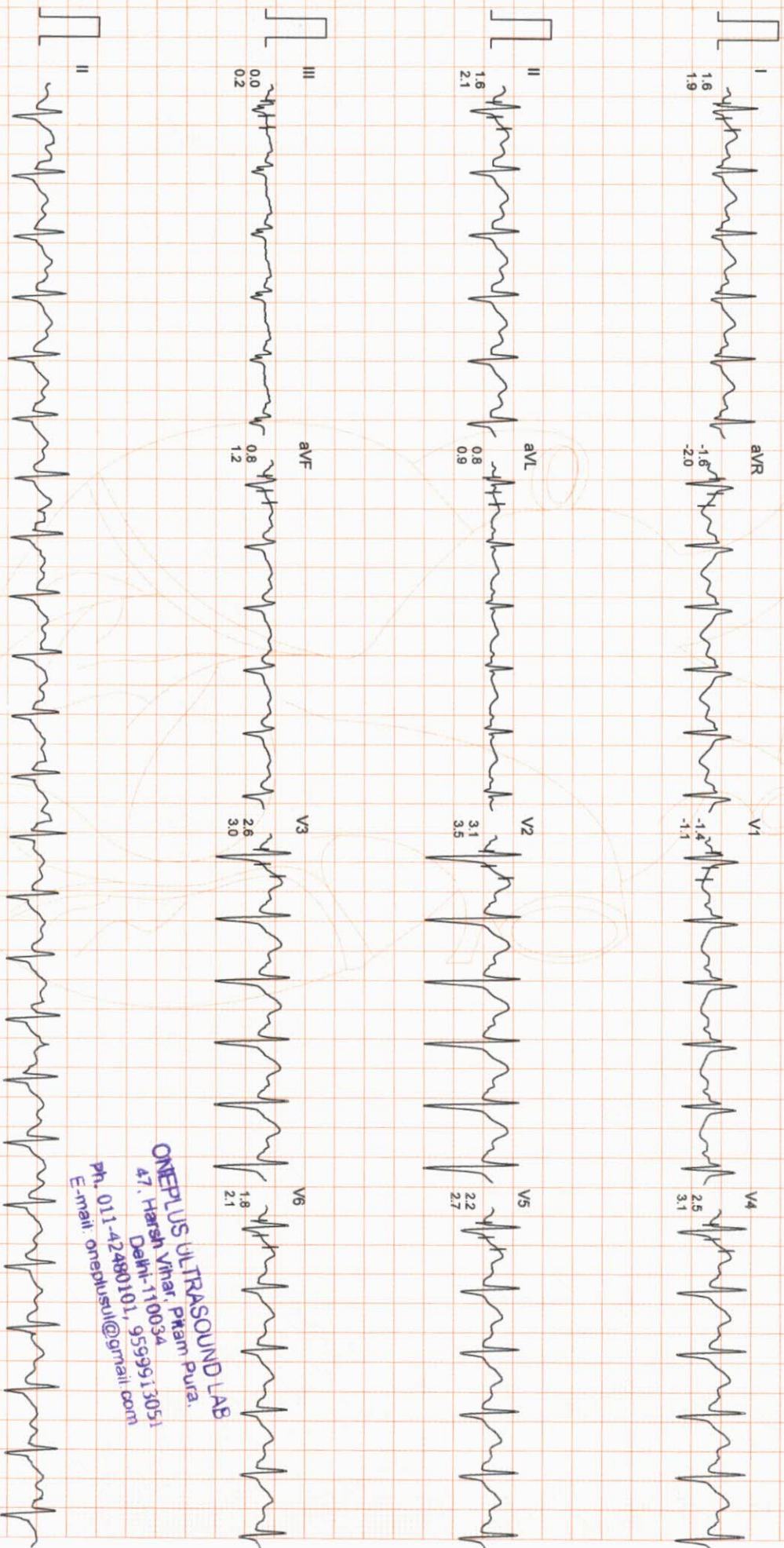
ONE PLUS ULTRASOUND LAB

Mr. KANHAYIA RATNAKAR SAXENA
I.D. : 22
AGE/SEX : 33/M
RECORDED : 28-12-2021 12:55

BRUCE
EXERCISE 1
PHASE TIME : 2:59
STAGE TIME : 2:55

ST @ 10mm/mV
80ms PostJ
SPEED : 2.7 Km./hr.
GRADE : 10.0 %

LINKED MEDIAN



ONEPLUS ULTRASOUND LAB
47, Harsh Vihar, Ptam Pura,
Delhi-110034
Ph. 011-42480101, 9559913051
E-mail: oneplusul@gmail.com

Filtered

Computer Corrected Baseline

25mm/sec 10mm/mV


CardiCom, INDIA

Mr. KANHAYIA RATNAKAR SAXENA
I.D. : 22
AGE/SEX : 33/M
RECORDED : 28-12-2021 12:55

BRUCE
EXERCISE 2
PHASE TIME : 5:59
STAGE TIME : 2:59

ST @ 10mm/mV
80ms PostJ
SPEED : 4.0 Km./Hr.
GRADE : 12.0 %

LINKED MEDIAN



ONEPLUS ULTRASOUND LAB
47, Hansh Vihar, Pitam Pura,
Delhi-110034
Ph. 011-42490101, 9599913051
E-mail: oneplusul@gmail.com


ONE PLUS ULTRASOUND LAB

MR. KANHAYIA RATNAKAR SAXENA
I.D. : 22
AGE/SEX : 33/M
RECORDED : 28-12-2021 12:55

BRUCE
EXERCISE 3
PHASE TIME : 7:29
STAGE TIME : 1:29

ST @ 10mm/mV
80ms PostU
SPEED : 5.4 Km./Hr.
GRADE : 14.0 %

LINKED MEDIAN



ONEPLUS ULTRASOUND LAB
47, Harsh Vihar, Pram Pura,
Delhi-110034
Ph. 011-42480101, 9559913051
E-mail: oneplusul@gmail.com


ONE PLUS ULTRASOUND LAB

Mr. KANHAYIA RATNAKAR SAXENA
I.D. : 22
AGE/SEX : 33/M
RECORDED : 28-12-2021 12:55

BRUCE
PEAK EXER
PHASE TIME : 7:30
STAGE TIME : 1:30

ST @ 10mm/mV
80ms PostJ
SPEED : 5.4 Km./Hr.
GRADE : 14.0 %

LINKED MEDIAN



ONEPLUS ULTRASOUND LAB
47, Harsh Vihar, Pitam Pura,
Delhi-110034
Ph. 011-42480101, 9599913051
E-mail: oneplusul@gmail.com

Filtered Computer Corrected Baseline

25mm/sec 10mm/mV

CardiCom, INDIA

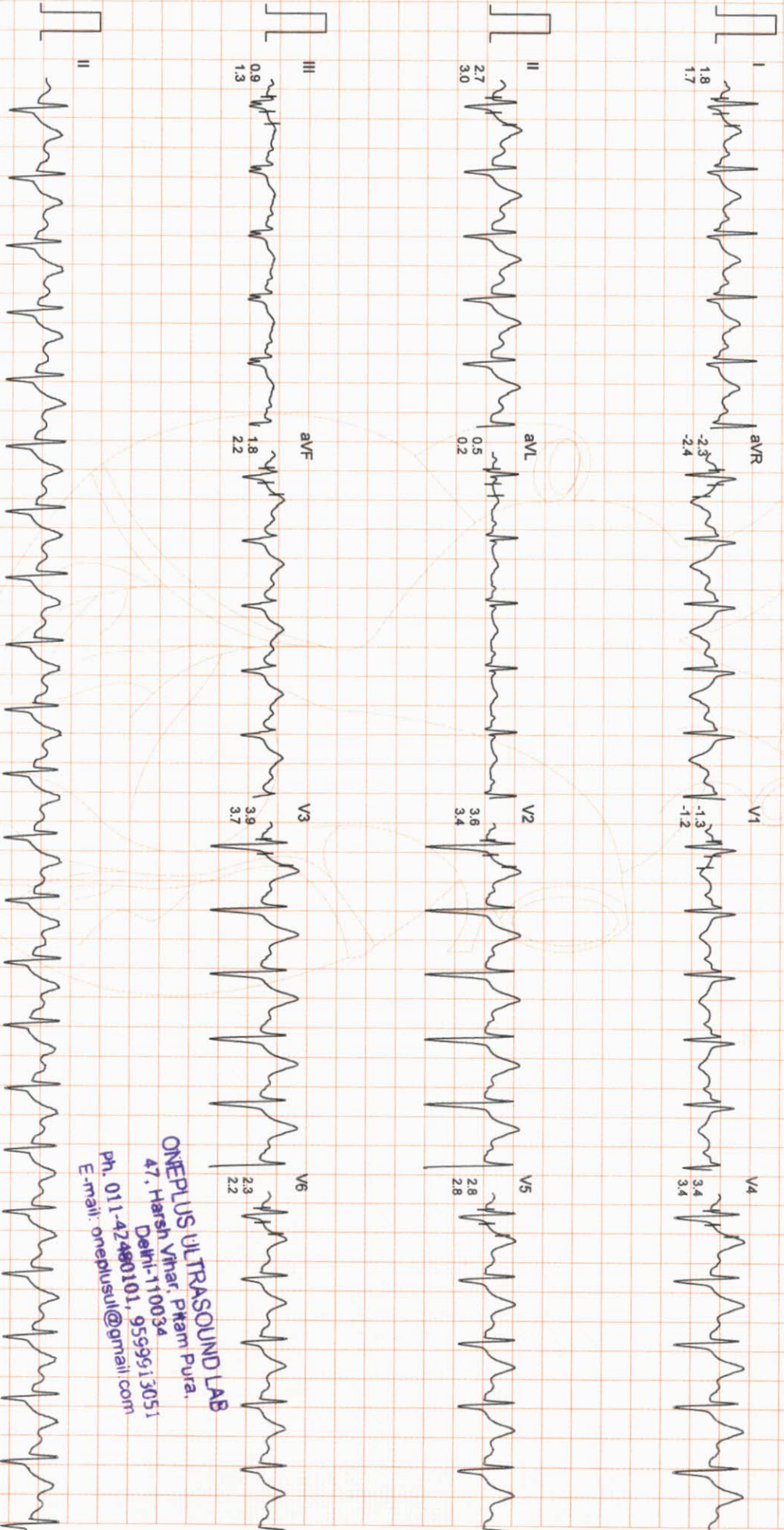
ONE PLUS ULTRASOUND LAB

MR. KANHAYIA RATNAKAR SAXENA
I.D. : 22
AGE/SEX : 33/M
RECORDED : 28-12-2021 12:55

BRUCE
RECOVERY
PHASE TIME : 2:59

ST @ 10mm/mV
80ms PostJ
SPEED : 0.0 Km./hr.
GRADE : 0.0 %

LINKED MEDIAN



ONEPLUS ULTRASOUND LAB
47, Harsh Vihar, Ptam Pura,
Delhi-110034
Ph. 011-42480101, 9599913051
E-mail: oneplusul@gmail.com


Filtered

Computer Corrected Baseline

25mm/sec 10mm/mV

CardiCom, INDIA

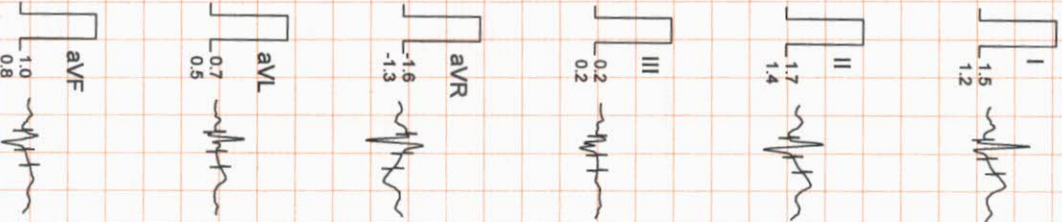
STAGE	HR	BP	SpO2
SUPINE	80ms Post	130/82	100%
STANDING	80ms Post	130/82	100%
STAGE 1	2:59	142/86	100%
STAGE 2	5:59	142/86	100%
PEAK EXERCISE	7:30	170/94	100%
RECOVERY	2:59	134/82	100%



ONEPLUS ULTRASOUND LAB
 47, Harsh Vihar, Pitam Pura,
 Delhi-110034
 ph: 011-42480101, 9559513051
 Email: oneplusul@gmail.com

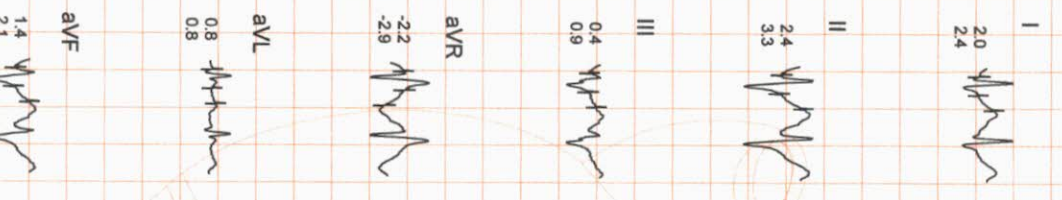
STANDING

0.0kmph
0.0%
130 bpm
B.P. 130/82
80ms PostU



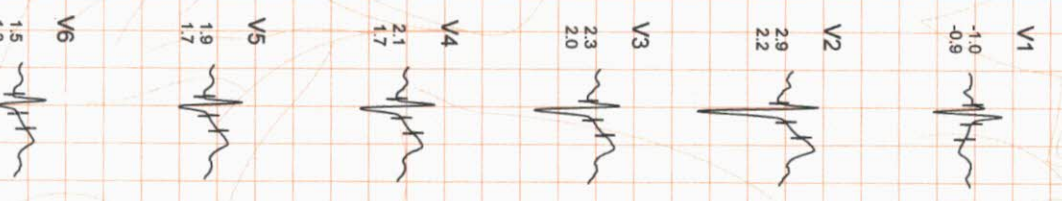
PEAK EXERCISE

7:30
5.4kmph
14.0%
198 bpm
B.P. 170/94
80ms PostU



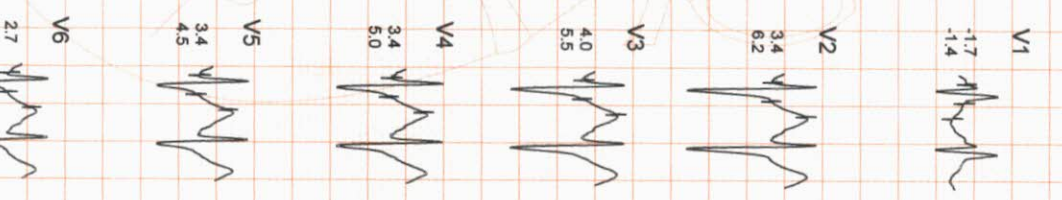
STANDING

0.0kmph
0.0%
130 bpm
B.P. 130/82
80ms PostU



PEAK EXERCISE

7:30
130
5.4kmph
14.0%
198 bpm
B.P. 170/94
80ms PostU



ONE LIFE ULTRASOUND LAB
Dr. Harshvardhan Prasad
D-11, Sector 11, Connaught Place
Delhi-110054
Phone: 011-4242880101, 65535315051
Email: one.life.ultrasound@one.life.com



OnePLUS Ultrasound Lab

Dr. Nitin Agarwal
Pathologist & Director
Ex. Sr. Res. MAMC
& Lok Nayak Hospital
Ex. Chief of Lab Dr. Lal Path Labs.

Dr. Pooja (Garg) Agarwal
Radiologist & Director
MAMC & Lok Nayak Hospital



ITD&E-INFO&SYSTEMS-2021-11-10

QUALITY FIRST... ALWAYS!			
NAME	Mr. KANHAIYA RATNAKAR SAXENA	Barcode No	:10110848
AGE/GENDER	:33 YRS/Male	SPECIMEN DATE	:28/Dec/2021 10:25AM
PATIENT ID	:89208	SPECIMEN RECEIVED	:28/Dec/2021 10:39AM
REFERRED BY	:Dr. MEDIWHEEL	REPORT DATE	:28/Dec/2021 04:13PM
CENTRE NAME	:ONEPLUS ULTRASOUND LAB	LAB NO.	:012112280019

HAEMATOLOGY

Health checkup 2 Male

Glycosylated Hemoglobin (HbA1c) **9.9** % Non Diabetic adults <5.7
 Prediabetic (at risk) 5.7-6.4
 Diabetes >6.4

Estimated average blood glucose (eag) 237

Reference range (mg/dl):

90 - 120:Excellent control, 121 - 150:Good Control, 151 - 180:Average Control, 181 - 210:Action Suggested

>211:Panic value

BLOOD GROUP (ABO) O
Rh typing POSITIVE

NOTE :

- * Apart from major A,B,H antigens which are used for ABO grouping and Rh typing, many minor blood group antigens exist. Agglutination may also vary according to titre of antigen and antibody.
- * So before transfusion, reconfirmation of blood group as well as cross-matching is needed.
- * Presence of maternal antibodies in newborns, may interfere with blood grouping.
- * Auto agglutination (due to cold antibody, falciparum malaria, sepsis, internal malignancy etc.) may also cause erroneous result.

CBC

Haemoglobin	13.6	g/dl	13.0-17.0
Total Leucocyte Count	8100	/cumm	4000-10000
Differential leucocyte count			
Neutrophils	62.8	%	40-80
Lymphocyte	27.70	%	20-40
Monocytes	4.40	%	2-10
Eosinophils	4.3	%	1-6
Basophils	0.8	%	0-2
RBC Count	5.34	million/cumm	4.5 - 5.5

Checked By.

DR. NITIN AGARWAL
MBBS,MD(PATHOLOGIST)

Dr NITIN AGARWAL
M B B S , MD (Path)
DMC/R/01436 Page 1 of 5

47, Harsh Vihar, Pitampura, New Delhi-110034 | Ph.: 011-42480101, 9599913051
E-mail: oneplusul@gmail.com | Web.: www.oneplusul.in



OnePLUS Ultrasound Lab

Dr. Nitin Agarwal
Pathologist & Director
Ex. Sr. Res. MAMC
& Lok Nayak Hospital
Ex. Chief of Lab Dr. Lal Path Labs.

Dr. Pooja (Garg) Agarwal
Radiologist & Director
MAMC & Lok Nayak Hospital



QUALITY FIRST... ALWAYS			
NAME	Mr. KANHAIYA RATNAKAR	Barcode No	:10110848
AGE/GENDER	SAXENA	SPECIMEN DATE	:28/Dec/2021 10:25AM
PATIENT ID	:33 YRS/Male	SPECIMEN RECEIVED	:28/Dec/2021 10:39AM
REFERRED BY	:89208	REPORT DATE	:28/Dec/2021 04:13PM
REFERRER	:Dr. MEDIWHEEL	LAB NO.	:012112280019
CENTRE NAME	:ONEPLUS ULTRASOUND LAB		

PCV(Hematocrit)	43.3	%	40-50
MCV	81.1	fL	83-101
MCH	25.4	Pg	27-32
MCHC	31.3	G/dL	32-35
Platelet count	186000	/cumm	150000-450000
RDW-CV	14.2	%	11.4-14.0
ESR(WESTEGRENS METHOD)	12	mm in 1st hr	0-20

BIOCHEMISTRY

Blood sugar fasting	243	mg/dL	70-110
Blood sugar pp	279	mg/dL	70.0-140.0
Bun (blood urea nitrogen)	12.60	mg/dl	8.9-21.6
Uric acid, serum	4.6	mg/dl	3.4-7.0
Creatinine, serum	0.9	mg/dl	0.60-1.1

LFT(LIVER FUNCTION TEST)

Bilirubin Total	0.65	mg/dl	0.1-1.2
Bilirubin Conjugated	0.32	mg/dl	0-0.4
Bilirubin Unconjugated	0.33	mg/dl	up to 0.7
SGOT (AST)	86	U/L	0-35
SGPT (ALT)	117	U/L	<45.0
Alkaline phosphatase	85	U/L	40-129
Gamma glutamyl transpeptidase	26	U/L	<66
Total Protein	6.9	gm/dl	6.60 - 8.70
Albumin	3.9	g/dL	3.8-5.1
Globulin	3.00	gm/dl	1.8-3.4
Albumin/Globulin Ratio	1.30		1.10 - 2.50

LIPID PROFILE

Cholesterol	246	mg/dl	50-200
Triglycerides	113	mg/dL	25-150

Checked By.

DR. NITIN AGARWAL
MBBS,MD(PATHOLOGIST)

DR NITIN AGARWAL
MBBS, MD
DMC/R/O
Page 2 of 5

47, Harsh Vihar, Pitampura, New Delhi-110034 | Ph.: 011-42480101, 9599913051
E-mail: oneplusul@gmail.com | Web.: www.oneplusul.in



OnePLUS Ultrasound Lab

Dr. Nitin Agarwal
Pathologist & Director
Ex. Sr. Res. MAMC
& Lok Nayak Hospital
Ex. Chief of Lab Dr. Lal Path Labs.

Dr. Pooja (Garg) Agarwal
Radiologist & Director
MAMC & Lok Nayak Hospital



QUALITY FIRST... ALWAYS!			
NAME	Mr. KANHAIYA RATNAKAR	Barcode No	:10110848
	SAXENA		
AGE/GENDER	:33 YRS/Male	SPECIMEN DATE	:28/Dec/2021 10:25AM
PATIENT ID	:89208	SPECIMEN RECEIVED	:28/Dec/2021 10:39AM
REFERRED BY	:Dr. MEDIWHEEL	REPORT DATE	:28/Dec/2021 04:13PM
CENTRE NAME	:ONEPLUS ULTRASOUND LAB	LAB NO.	:012112280019

HDL Cholesterol	45	mg/dL	30-70
LDL cholesterol	178	mg/dL	<130
VLDL cholesterol	22.6	mg/dL	5-40
Cholesterol/HDL Ratio	5.5		Low Risk 3.3-4.97 Average Risk 4.4-7.1 Moderate Risk 7.1-11.0 High Risk >11.0
LDL/HDL Ratio	4.0		0 - 3.55

According to ATP III and NCEP guidelines

Parameter	Normal	Desirable	Borderline	High
Total cholesterol	<200		200-239	240
Triglycerides	<150	150-199	200-499	500
LDL	Optimal <100 Near Optimal 100-129	130-159	160-180	190
HDL	<40 : LOW 60 : HIGH			

ENDOCRINOLOGY

PSA TOTAL

Prostatic specific antigen, Total 0.40 ng/ml <4.0

< 40 years	0.21 to 1.72 ng/ml
40 - 49	0.27 to 2.19 ng/ml
50 - 59	0.27 to 3.42 ng/ml
60 - 69	0.22 to 6.16 ng/ml
> 69	0.21 to 6.77 ng/ml

Notes:

PSA is principally produced by the glandular epithelium of the prostate, and is secreted in the seminal fluid. PSA is also present in

Checked By.

DR. NITIN AGARWAL
MBBS, MD (PATHOLOGIST)

Dr NITIN AGARWAL
M B B S , MD (Path)
DMC/R/01436

Page 3 of 5

47, Harsh Vihar, Pitampura, New Delhi-110034 | Ph.: 011-42480101, 9599913051
E-mail: oneplusul@gmail.com | Web.: www.oneplusul.in



OnePLUS Ultrasound Lab

Dr. Nitin Agarwal
Pathologist & Director
Ex. Sr. Res. MAMC
& Lok Nayak Hospital
Ex. Chief of Lab Dr. Lal Path Labs.

Dr. Pooja (Garg) Agarwal
Radiologist & Director
MAMC & Lok Nayak Hospital



QUALITY FIRST... ALWAYS!	Mr. KANHAIYA RATNAKAR	Barcode No	:10110848
NAME	SAXENA	SPECIMEN DATE	:28/Dec/2021 10:25AM
AGE/GENDER	:33 YRS/Male	SPECIMEN RECEIVED	:28/Dec/2021 10:39AM
PATIENT ID	:89208	REPORT DATE	:28/Dec/2021 04:13PM
REFERRED BY	:Dr. MEDIWHEEL	LAB NO.	:012112280019
CENTRE NAME	:ONEPLUS ULTRASOUND LAB		

urine and blood. PSA acts on seminal fluid to fluidify and increase sperm mobility. PSA levels rise in prostatic pathologies such as benign prostatic hyperplasia (BPH) or prostate cancer.

THYROID PROFILE(T3,T4,TSH)

Triiodothyronine total [t3]	0.86	ng/dl	0.52-1.9
Thyroxine total [t4]	8.90	µg/dl	4.4 - 10.8
TSH (Thyroid Stimulating Hormone)	3.30	µIU/ml	0.25-5.0

AGE WISE VARIATION IN TSH

AGE	TSH(µIU/ml)	AGE	TSH(µIU/ml)
1-4 weeks	1.00 - 19.0	16-20 yrs	0.25 - 5.0
1-12 mths	1.70 - 9.1	21 - 80 yrs	0.25 - 5.0
1-5 yrs	0.80 - 8.2	I st trimester	0.25 - 5.0
6-10 yrs	0.25 - 5.0	II nd trimester	0.50 - 5.0
11-15 yrs	0.25 - 5.0	III rd trimester	0.4 - 6.0

Reference ranges - Interpretation of Diagnostic tests - (Jacques Wallach)

1. Primary hypothyroidism is accompanied by depressed serum T3 and T4 values and elevated serum TSH level.
2. Primary hyperthyroidism is accompanied by elevated serum T3 and T4 levels along with depressed TSH values.
3. Slightly elevated T3 levels may be found in pregnancy and estrogen therapy, while depressed levels may be encountered in severe illness, renal failure and during therapy with drugs like propranolol and propyl thiouracil.
4. Although elevated TSH levels are nearly always indicative of primary hypothyroidism, and may be seen in secondary thyrotoxicosis

CLINICAL PATHOLOGY

URINE ROUTINE

Physical examination

Quantity	20	ML
Colour	PALE YELLOW	
Transparency	CLEAR	CLEAR
Sp.gravity	1.015	1.010-1.030
pH	6.00	
Reaction	ACIDIC	ACIDIC

Checked By.

DR. NITIN AGARWAL
MBBS,MD(PATHOLOGIST)

Dr NITIN AGARWAL
MBBS, M
DMC/R/011730
Page 4 of 5

47, Harsh Vihar, Pitampura, New Delhi-110034 | Ph.: 011-42480101, 9599913051
E-mail: oneplusul@gmail.com | Web.: www.oneplusul.in



OnePLUS Ultrasound Lab

Dr. Nitin Agarwal
Pathologist & Director
Ex. Sr. Res. MAMC
& Lok Nayak Hospital
Ex. Chief of Lab Dr. Lal Path Labs.

Dr. Pooja (Garg) Agarwal
Radiologist & Director
MAMC & Lok Nayak Hospital



QUALITY FIRST... ALWAYS	Mr. KANHAIYA RATNAKAR	Barcode No	:10110848
NAME	SAXENA	SPECIMEN DATE	:28/Dec/2021 10:25AM
AGE/GENDER	:33 YRS/Male	SPECIMEN RECEIVED	:28/Dec/2021 10:39AM
PATIENT ID	:89208	REPORT DATE	:28/Dec/2021 04:13PM
REFERRED BY	:Dr. MEDIWHEEL	LAB NO.	:012112280019
CENTRE NAME	:ONEPLUS ULTRASOUND LAB		

Chemical examination


Urine protein	NIL	NIL
Urine sugar	+	NIL
Bilirubin, urine	NEGATIVE	NEGATIVE
Urobilinogen	NORMAL	NORMAL
Ketones	NEGATIVE	NEGATIVE

Microscopic examination

Pus cells.	2-3	/HPF	0-2
Epithelial cells	1-2	/HPF	NIL
R.B.C.	NIL	/HPF	NIL
Casts	NIL	/HPF	NIL
Crystals	NIL	/HPF	NIL
Bacteria	NIL	/HPF	NIL
Others.	NIL	NIL	NIL

*** End Of Report ***

Checked By.


DR. NITIN AGARWAL
MBBS,MD(PATHOLOGIST)

DR NITIN AGARWAL
MBBS MD. Page 5 of 5
DMC/R/02/136

47, Harsh Vihar, Pitampura, New Delhi-110034 | Ph.: 011-42480101, 9599913051
E-mail: oneplusul@gmail.com | Web.: www.oneplusul.in



OnePLUS
Ultrasound Lab

— QUALITY FIRST... ALWAYS! —

Dr. Nitin Agarwal

Pathologist & Director
Ex. Sr. Res. MAMC
& Lok Nayak Hospital
Ex. Chief of Lab Dr. Lal Path Labs.

Dr. Pooja (Garg) Agarwal

Radiologist & Director
MAMC & Lok Nayak Hospital

Name	: Mr. KANHAIYA RATNAKAR	Age/Sex	: 33 YRS/Male
	SAXENA		
Ref. By	: Dr. MEDIWHEEL	Lab No	: 012112280019
Date	: 28-Dec-2021	Patient ID	: LSHHI89208

ULTRASOUND EXAMINATION----WHOLE ABDOMEN

Liver is borderline enlarged in size (15.2 cm) and normal in outline with altered echopattern. Diffuse increase in echogenicity of liver parenchyma is noted, suggestive of fatty infiltration (grade II). Intrahepatic biliary radicles are not dilated. No abscess or mass lesion seen. Hepatic veins, portal vein, IVC and aorta are normal. CBD is normal in caliber.

Gall bladder is well distended with anechoic lumen. Wall thickness is normal.

Both kidneys are normal in size, shape, position, outline and echopattern. Corticomedullary differentiation is maintained. No pelvicalyceal dilation or mass lesion is seen.

Spleen is normal in size and echotexture. No mass lesion seen.

Pancreas is normal in size, outline and echotexture.

Urinary bladder is normal in shape and position. No evidence of intravesical stone or mass seen.


Prostate is normal in size, shape and echopattern.

Prostate measures 2.5 x 2.5 x 2.9 cm. **Weight of prostate is 9 grams.**

No abnormal bowel wall thickening seen in right iliac fossa.
No free fluid seen anywhere in abdomen.


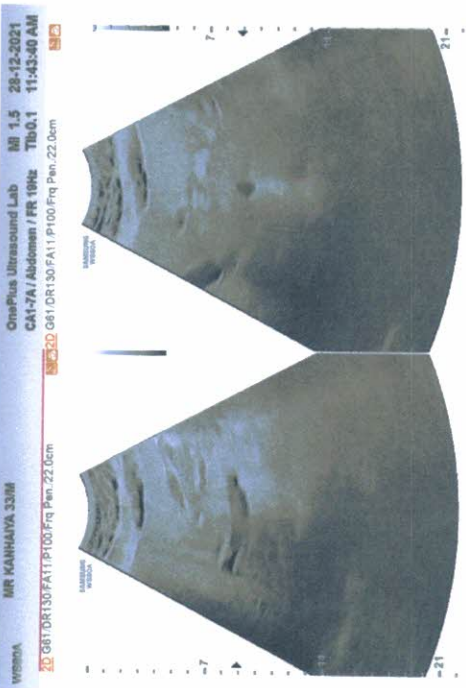
IMPRESSION:

- Fatty infiltration of liver (grade II) with borderline hepatomegaly.



DR. POOJA GARG
RADIOLOGIST
REG NO- DMC/R/03398
DR. POOJA GARG
M.B.B.S.D.M.R.D
Reg. No. DMC/R/03398
Radiologist

Type By : darshita

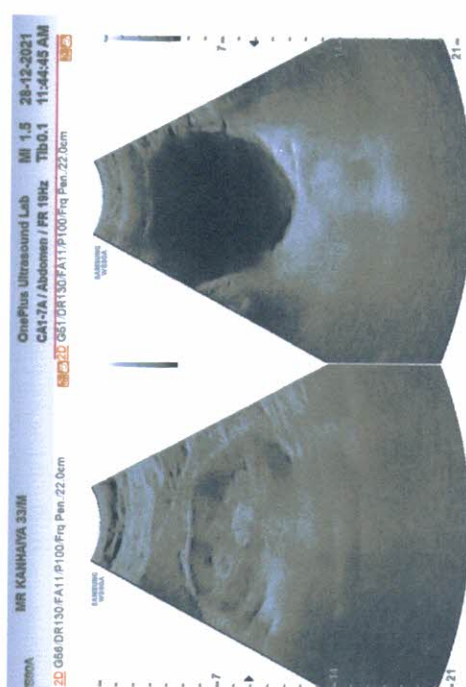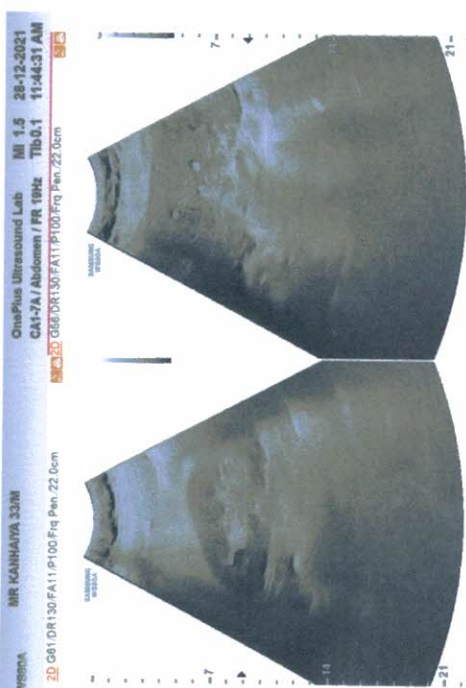47, Harsh Vihar, Pitampura, New Delhi-110034 | Ph.: 011-42480101, 9599913051
E-mail: oneplusul@gmail.com | Web.: www.oneplusul.in



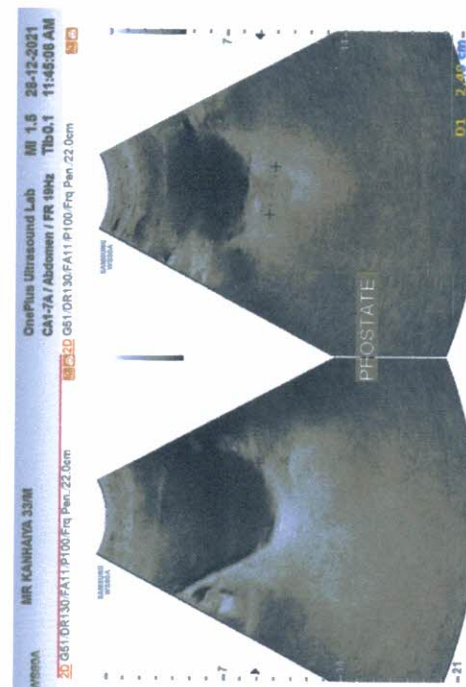
D1 3.8, 3.6 cm



FATTY LIVER



D1 2.49 cm
D2 2.90 cm



PROSTATE

D1 2.60 cm
D2 2.90 cm
D3 2.87 cm
Vol. 9.31 ml

Ultrasound Image Report

1000 10:00 10:00 10:00 10:00




1000 10:00 10:00 10:00 10:00

1000 10:00 10:00 10:00 10:00

1000 10:00 10:00 10:00 10:00

1000 10:00 10:00 10:00 10:00

1000 10:00 10:00 10:00 10:00



1000 10:00 10:00 10:00 10:00




1000 10:00 10:00 10:00 10:00

1000 10:00 10:00 10:00 10:00

1000 10:00 10:00 10:00 10:00

1000 10:00 10:00 10:00 10:00

1000 10:00 10:00 10:00 10:00





OnePLUS
Ultrasound Lab

— QUALITY FIRST... ALWAYS! —

Dr. Nitin Agarwal
Pathologist & Director
Ex. Sr. Res. MAMC
& Lok Nayak Hospital
Ex. Chief of Lab Dr. Lal Path Labs.


Dr. Pooja (Garg) Agarwal
Radiologist & Director
MAMC & Lok Nayak Hospital

Name	: Mr. KANHAIYA RATNAKAR SAXENA	Age/Sex	: 33 YRS/Male
Ref. By	: Dr. MEDIWHEEL	Lab No	: 012112280019
Date	: 28-Dec-2021	Patient ID	: LSHHI89208

X-ray-Chest PA view

Bony cage and soft tissues are normal.
Cardiothoracic ratio is normal.
Mediastinum is normal.
Both hila are normal.
Both costophrenic angles are clear.
Both domes of diaphragm are normal.
Lung fields are clear. No parenchymal lesion seen.

IMPRESSION: Normal Study.

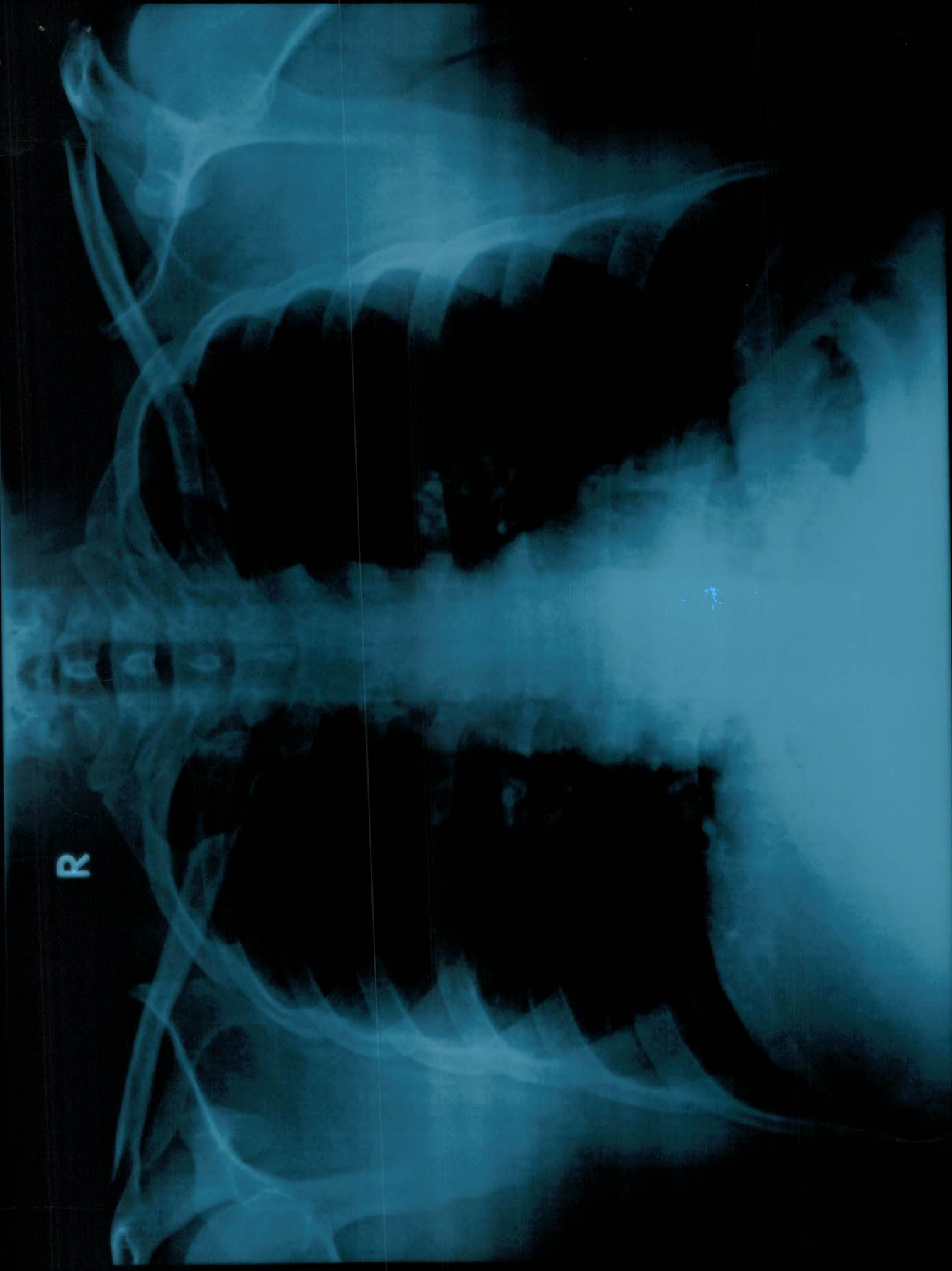

DR. POOJA GARG
RADIOLOGIST
REG NO- DMC/R/03398
DR. POOJA GARG
M.B.B.S., D.M.R.D.
Reg. No. DMC/R/03398
Radiologist

Type By : darshita

47, Harsh Vihar, Pitampura, New Delhi-110034 | Ph.: 011-42480101, 9599913051
E-mail: oneplusul@gmail.com | Web.: www.oneplusul.in

Clinical correlation is essential for final diagnosis. • If test results are unsatisfactory please contact personally or on phone. • This report is for perusal of doctors only.
• All disputes Subject to Delhi Jurisdiction only. • Not for medicolegal purposes. • All congenital anomalies in a foetus may not be diagnosed in routine obstetric ultrasound.

R



MR KANHAYIA RATNAKAR SAXENA AGE 33 YRS 28-12-2021 M CHEST PA VIEW
ONEPLUS ULTRASOUND LAB, 47-HARSH VIHAR, PITAMPURA

ONEPLUS ULTRASOUND LAB, 41-HARSH NIHAR, PILTAMPURA
MR KANHAIYA RATNAKAR SAKHENA AGE 33 YRS 58-15-5051 M CHEST PA VIEW

R

