

Health Check up Booking Request(bobS9687),Package Code(PKG1000241),Beneficiary Code(9629)

1 message

Mediwheel <santosh@policywheel.com>

9 March 2022 at 16:46

To: "vidhidiagnostics@gmail.com" <vidhidiagnostics@gmail.com>

Cc: Mediwheel CC <customercare@mediwheel.in>, Mediwheel CC <mediwheelwellness@gmail.com>



Mediwheel
...Your wellness partner



011-41195959

Email:wellness@mediwheel.in

Dear Vidhi Diagnostics,
City : Ahmedabad . Location : .New Wadaj,

We have received the following request for Health Check up from

- Name** : Sandhya Lal
- Age** : 35
- Gender** : Female
- Member Relations** : Spouse
- Package Name** : Metro Full Body Health Checkup Female Below 40
- Package Code** : PKG1000241
- User Location** : Gujarat,NAVSARI,396445
- Contact Details** : 9909335515
- Booking Date** : 09-03-2022
- Appointment Date** : 12-03-2022

Member Information			
Booked Member Name	Age	Gender	Cost(In INR)
Sandhya Lal	35	Female	Cashless
Total amount to be paid			Cashless

Please login to your account to confirm the same. Also you mail us for confirmation

Package Name : Metro Full Body Health Checkup Female Below 40 - Includes (37)Tests

Tests included in this Package :

Ecg, TSH, X-ray Chest, Stress Test (tmt)/ 2d Echo, Blood Sugar Postprandial, A:g Ratio, Blood Group, Total Cholesterol, Triglycerides, Fasting Blood Sugar, Ultrasound Whole Abdomen , Glycosylated Haemoglobin (hba1c), Hdl, Vldl, Urine Analysis, LDL, Total Protine, General Consultation, HDL/ LDL ratio, GGT(Gamma-glutamyl Transferase), Eye Check-up consultation, ALP (ALKALINE PHOSPHATASE), Uric Acid, AST/ALT Ratio, Serum Protein, CBC with ESR, Stool Analysis, Urine Sugar Fasting, Urine Sugar PP, T3, T4, Cholesterol Total / HDL Ratio, BUN, BUN/Creatinine Ratio, Bilirubin Total & Direct and Indirect, Albumin, Globulin

To,

The Coordinator,
Mediwheel (Arcofemi Healthcare Limited)
Helpline number: 011- 41195959

Dear Sir / Madam,

Sub: Annual Health Checkup for the employees of Bank of Baroda

This is to inform you that the following spouse of our employee wishes to avail the facility of Cashless Annual Health Checkup provided by you in terms of our agreement.

PARTICULARS OF HEALTH CHECK UP BENEFICIARY	
NAME	SANDHYA LAL
DATE OF BIRTH	13-11-1989
PROPOSED DATE OF HEALTH CHECKUP FOR EMPLOYEE SPOUSE	12-03-2022
BOOKING REFERENCE NO.	21M77886100014548S
SPOUSE DETAILS	
EMPLOYEE NAME	MR. LAL CHANDAN
EMPLOYEE EC NO.	77886
EMPLOYEE DESIGNATION	DIGITAL LENDING
EMPLOYEE PLACE OF WORK	AHMEDABAD,ZO AHMEDABAD
EMPLOYEE BIRTHDATE	26-06-1980

This letter of approval / recommendation is valid if submitted along with copy of the Bank of Baroda employee id card. This approval is valid from **09-03-2022** till **31-03-2022**. The list of medical tests to be conducted is provided in the annexure to this letter. Please note that the said health checkup is a **cashless facility** as per our tie up arrangement. We request you to attend to the health checkup requirement of our employee's spouse and accord your top priority and best resources in this regard. The EC Number and the booking reference number as given in the above table shall be mentioned in the invoice, invariably.

We solicit your co-operation in this regard.

Yours faithfully,

Sd/-

Chief General Manager
HRM Department
Bank of Baroda

(Note: This is a computer generated letter. No Signature required. For any clarification, please contact Mediwheel (Arcofemi Healthcare Limited))

PRE EMPLOYMENT HEALTH SCREENING

Date : 12/3/2022

1. Personal Particulars

Name : Sandhya Lall NRIC No : _____
Age : 34 years Gender : Male / Female
Marital Status : married

Past & Present Medical History : ? no

Family Medical History : Husband - DM
Mother - Thyroid

Allergy : ? no

2. Clinical Medical Examination

Height : 153 cm Weight : 70 kg
Blood Pressure : 130/86mmHg mmHg Pulse : 90 p/min
Vision : Uncorrected : (R) (N) (L) Corrected : (R) (N) (L)
Colour Vision : Normal / Colour Blind
General Condition : Normal Skin : _____
Central Nervous System : ? Normal Head & Neck : ? Normal
Cardiovascular System : _____ Chest : _____
Abdomen : _____ Limbs : _____
Last menstrual period : 25-2-2022

3. Investigations

Chest X-Ray : As per Attached report

I, the undersigned hereby authorize the doctor to release my medical check-up

(S) Sam
Signature of applicant

Remarks : Fit / Unfit for employment

She is fit

Dr. Vidhi D. Modh
MBBS

Dr's name, signature & chop
Reg. No. G-74540

Dr. Dinesh S. Modh

M.D., D.M.R.E. (Radiodiagnosis)

Consultant Radiologist & Sonologist

Ex. Junior Lecturer, B.J. Medical College, Civil Hospital, A'bad.

Panel Doctor of L.I.C.



Patient's name : SANDHYA LAL
Reg. ID : R-12293-21
Referred by : Dr. MEDIWHEEL

Age/Sex : 34 Years/Female
Accession : 9839
Date : 12/03/2022

Report of ECG

Conclusion

- Normal sinus rhythm.
- HR - 90/per minute.
- Normal PR interval.
- Normal QRS interval.
- Normal QT interval.

Dr. Avinash Bhaskar

MBBS, D Cardio

Reg. No : G-45946
DR. AVINASH BHASKAR

ISO 9001:2015 Certified Diagnostics Center

Vidhi Imaging Center

L-86, Swatantra Senani Nagar, Opp. Akhbarnagar Petrol Pump, Nr. Akhbarnagar Circle, Nava-Vadaj, Ahmedabad - 380 013.

Phone : 079-2762 1406, Mobile : 98799 29406, 98250 09406, E-mail : vidhidiagnostics@gmail.com, Website : www.vidhidiagnostics.com

Time : Mon. to Sat. 9.00 am to 2.00 pm, 5.00 pm to 9.00 pm, Sunday 9.00 am to 12.00 Noon

FACILITIES : Live 3D-4D Sonography | Colour Doppler | Echo Cardiography | Interventional Radiology | Fetal Medicine | Digital X-Ray
Digital Mammography | Digital OPG / TMJ | ECG / TMT / PFT / EEG / EMG | Pathology Laboratory | Health Check Up Plans | Pre Employment Check Up

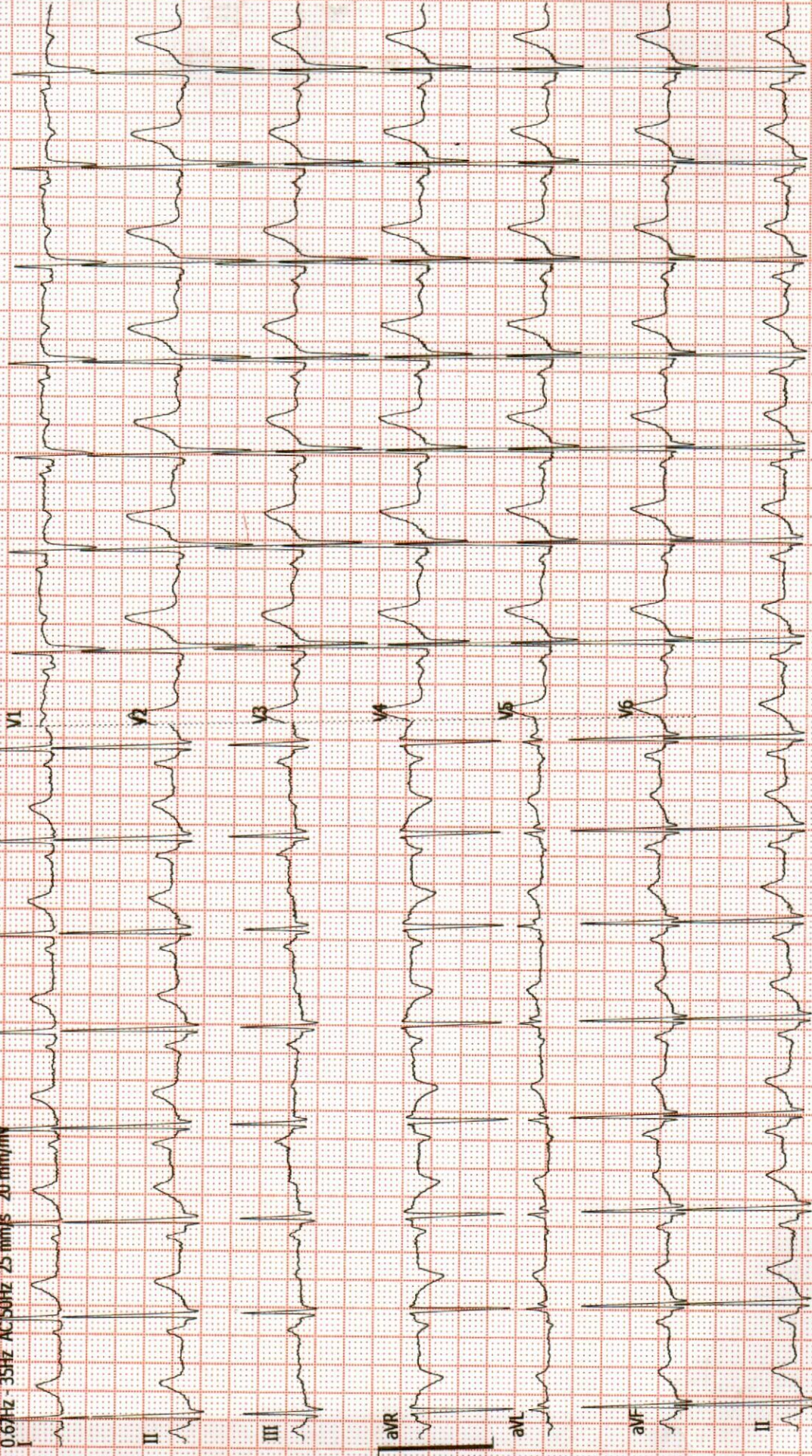
HR : 90 bpm
 PR : 128 ms
 QRS : 86 ms
 QT/QTc : 344/420 ms
 P/QRS/T : 65/50/44 deg.
 RV5/SV1 : 1.404/-0.432 mv
 RV5+SV1 : 1.836 mv

ID: 4124
 Name: sandhya lal
 Age: 34yrs
 Sex: Female

Hospital:
 Department:

Need to be confirmed by doctor. Doctor Name:

0.6 Hz - 35 Hz AC 50 Hz 25 mm/s 20 mm/mv



Dr. Avirash Bhaskar
 M.B.B.S. D Cardio
 Reg. No: 0-45946

Dr. Dinesh S. Modh

M.D., D.M.R.E. (Radiodiagnosis)

Consultant Radiologist & Sonologist

Ex. Junior Lecturer, B.J. Medical College, Civil Hospital, A'bad.

Panel Doctor of L.I.C.



Patient's name : SANDHYA LAL
Reg. ID : R-12293-21
Referred by : Dr. MEDIWHEEL

Age/Sex : 34 Years/Female
Accession : 9839
Date : 12/03/2022

X-RAY CHEST (PA VIEW)

Both lung fields appear normal.
No e/o consolidation or cavitations is seen.
Both costo-phrenic angles appear clear.
Cardiac size is with in normal limits.
Both domes of diaphragm appear normal.
Bony thoracic cage appears normal.

Thanks for reference.

Dr. Dinesh S. Modh

(M.D. D.M.R.E. (Radiodiagnosis))

G-23825
M.D. DMRE (RADIO DIAGNOSIS)

ISO 9001:2015 Certified Diagnostics Center

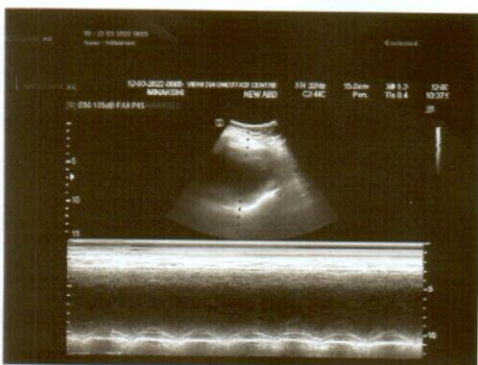
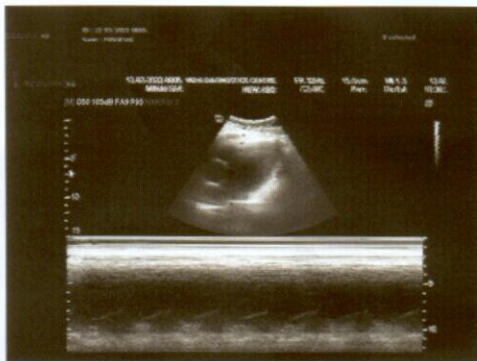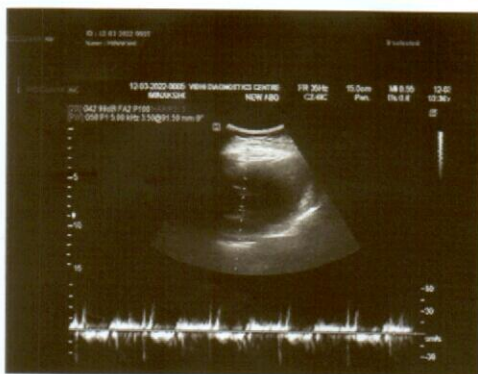
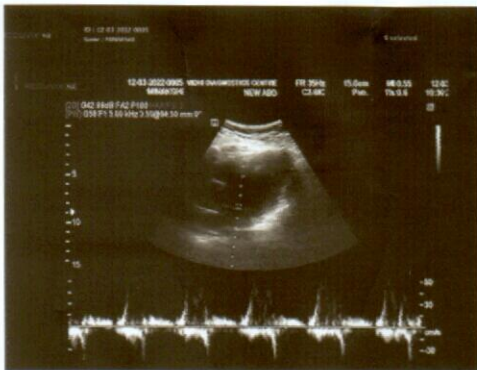
Vidhi Imaging Center

L-86, Swatantra Senani Nagar, Opp. Akhbarnagar Petrol Pump, Nr. Akhbarnagar Circle, Nava-Vadaj, Ahmedabad - 380 013.

Phone : 079-2762 1406, Mobile : 98799 29406, 98250 09406, E-mail : vidhidiagnostics@gmail.com, Website : www.vidhidiagnostics.com

Time : Mon. to Sat. 9.00 am to 2.00 pm, 5.00 pm to 9.00 pm, Sunday 9.00 am to 12.00 Noon

FACILITIES : Live 3D-4D Sonography | Colour Doppler | Echo Cardiography | Interventional Radiology | Fetal Medicine | Digital X-Ray
Digital Mammography | Digital OPG / TMJ | ECG / TMT / PFT / EEG / EMG | Pathology Laboratory | Health Check Up Plans | Pre Employment Check Up



Dr. Dinesh S. Modh

M.D., D.M.R.E. (Radiodiagnosis)
Consultant Radiologist & Sonologist
Ex. Junior Lecturer, B.J. Medical College, Civil Hospital, A'bad.
Panel Doctor of L.I.C.



Patient's name: SANDHYA LAL
Reg. ID : R-12293-21
Referred by : Dr. MEDIWHEEL

Age/Sex : 34 Years/Female
Accession : 9839
Date : 12/03/2022

2D- ECHO REPORT

FINAL CONCLUSION:

LV IS NORMAL SIZE. GOOD LV SYSTOLIC FUNCTION NO RWMA.
LVEF - 60%. NO CONCENTRIC LVH.
NORMAL LV COMPLANCE.
LA IS NORMAL SIZE. NO LA CLOT.
RV IS NORMAL SIZE. GOOD RV SYSTOLIC FUNCTION.
RA IS NORMAL SIZE.
MITRAL VALVE IS NORMAL. NO MS. NO MR. NO MVP.
AORTIC VALVE IS NORMAL. NO AS. NO AR.
TRICUSPID VALVE IS NORMAL. NO TR. RVSP-26 mmHg. NO PAH.

NO CLOT, NO VEGETATION, NO PERICARDIAL EFFUSION.

DIMENSIONS:

AORTA	2.6 C.M
LEFT ATRIUM	2.7 C.M
LVDD	4.1 C.M.
IVSD	1.0 C.M
PWD	1.0 C.M
LVDS	2.6 C.M.

COLOUR DOPPLER FINDING:

STRUCTURE	VELOCITY m/sec
	Max
PULMONARY VALVE	0.7
MITRAL VALVE	E : 0.7 A: 0.4
AORTIC VALVE	1.0

Dr. Avinash Bhaskar

Reg. No.: G-45946

DR AVINASH BHASKAR

ISO 9001:2015 Certified Diagnostics Center

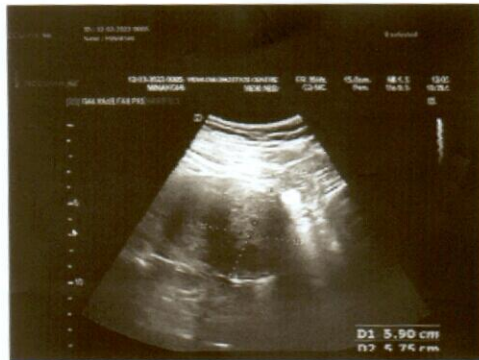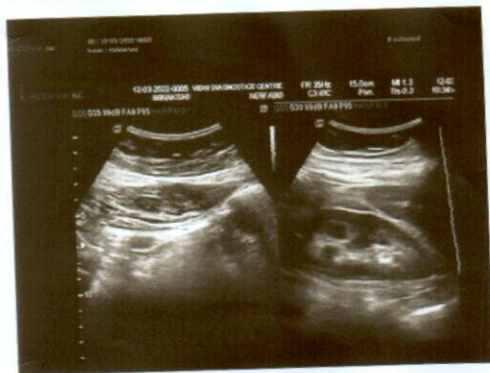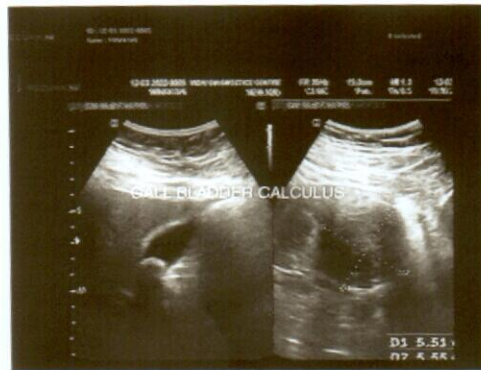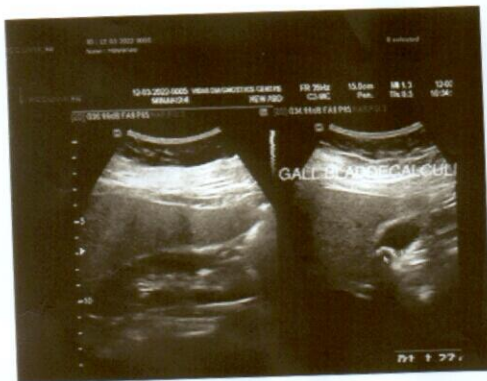Vidhi Imaging Center

L-86, Swatantra Senani Nagar, Opp. Akhbarnagar Petrol Pump, Nr. Akhbarnagar Circle, Nava-Vadaj, Ahmedabad - 380 013.

Phone : 079-2762 1406, Mobile : 98799 29406, 98250 09406, E-mail : vidhidiagnostics@gmail.com, Website : www.vidhidiagnostics.com

Time : Mon. to Sat. 9.00 am to 2.00 pm, 5.00 pm to 9.00 pm, Sunday 9.00 am to 12.00 Noon

FACILITIES : Live 3D-4D Sonography | Colour Doppler | Echo Cardiography | Interventional Radiology | Fetal Medicine | Digital X-Ray
Digital Mammography | Digital OPG / TMJ | ECG / TMT / PFT / EEG / EMG | Pathology Laboratory | Health Check Up Plans | Pre Employment Check Up



Dr. Dinesh S. Modh

M.D., D.M.R.E. (Radiodiagnosis)

Consultant Radiologist & Sonologist

Ex. Junior Lecturer, B.J. Medical College, Civil Hospital, A'bad.

Panel Doctor of L.I.C.



Patient's name : SANDHYA LAL
Reg. ID : R-12293-21
Referred by : Dr. MEDIWHEEL

Age/Sex : 34 Years/Female
Accession : 9839
Date : 12/03/2022

USG ABDOMEN

LIVER: - Liver appears normal in size & show normal echotexture. No evidence of diffuse or focal lesion is seen. Intrahepatic biliary radicals appear normal. Portal vein and CBD appear normal. No e/o calculus is seen in bile duct.

GALL BLADDER: - Gall bladder is distended & appears normal. No evidence of calculus or cholecystitis is seen. No evidence of pericholecystic fluid is seen.

SPLEEN: - Spleen appears normal in size & shows normal echotexture. No evidence of diffuse or focal lesion is seen.

PANCREAS: - Pancreas appears normal size and echopattern. No e/o diffuse or focal lesion is seen. Main pancreatic duct appears normal.

KIDNEY: - Both Kidneys appear normal in size & echotexture.

No e/o calculus or hydronephrosis or hydroureter is seen in either side.

Cortico-medullary differentiation is maintained on either side.

Both suprarenal regions appear normal.

RIF & BOWEL LOOPS (By high frequency probe): - Normal.

No evidence of pre & para aortic lymphadenopathy is seen.

No evidence of free fluid is seen in abdomen.

No evidence of dilated or thickened bowel loops is seen.

Urinary bladder: - appears normal. No e/o calculus or mass lesion is seen in bladder.

Uterus appears normal in size and echopattern.

No evidence of diffuse or focal lesion is seen.

Cervical region appears normal.

Endometrial thickness is 6.4mm. Cu-T is seen in situ.

Both ovaries and adnexal regions appear normal.

No e/o free fluid is seen in pouch of Douglas.

Thanks for reference.

Dr. Dinesh S. Modh
MD DMRE (Radiodiagnosis)
DR DINESH S. MODH
M.D. DMRE (RADIO DIAGNOSIS)

ISO 9001:2015 Certified Diagnostics Center

Vidhi Imaging Center

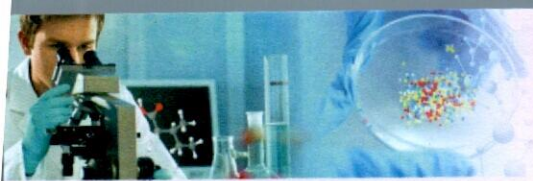L-86, Swatantra Senani Nagar, Opp. Indian Oil Petrol Pump, Akhbarnagar Circle, Nava Vadaj, Ahmedabad - 380 013.

Phone : (Radiology) 079-2762 1406 | M. 98799 29406, 98250 09406 | Time (Radiology) : Mon. to Sat. 9 am to 2 pm, 5 to 9 pm, Sunday 9 am to 12 Noon

E-mail : vidhidiagnostics@gmail.com, Website : www.vidhidiagnostics.com

Multislice CT Scan | CBCT-Dental Scan | Live 3D-4D Sonography | Colour Doppler | Echo Cardiography | Interventional Radiology | Maxillofacial Radiology | Fetal Medicine
Digital X-Ray | Digital Mammography | Digital OPG/TMJ | ECG/TMT/PFT/EEG/EMG | Audiometry | Pathology Laboratory | Health Check Up Plans | Pre Employment Check Up

CT SCAN & CBCT FACILITY NOW AVAILABLE



Pathology Department



Patient's name : SANDHYA LAL
Age/Sex : 34 Years/Female
Referred by : -
Collection Time : 09:29

Reg. ID : P-8410-21
Accession : 9825
Order Dt/time : 12/03/2022 09:29

Complete Blood Count

Sample Type: EDTA

Test Name	Result	Units	Biological Reference Interval
<u>Blood Counts</u>			
Haemoglobin :	12.3	Gms%	12.5 - 16.0
Total R.B.C. :	4.19	mill/c.mm	4.2 - 5.4
Total W. B. C. :	10,420	/cu mm	4000 - 10500
Platelet Count :	2,03,000	/cu.mm	1,50,000 - 4,50,000
<u>Differential Count</u>			
Neutrophils :	69	%	40 - 70
Lymphocytes :	26	%	20 - 40
Eosinophils :	02	%	1 - 4
Monocytes :	03	%	2 - 6
Basophils :	00	%	0 - 01
<u>Blood Indices</u>			
P. C. V :	37.5	%	37 - 47
M. C. V. :	89.5	fl	78 - 100
M.C.H :	29.4	pg	27 - 31
M. C. H. C :	32.9	%	32 - 36
R.D.W :	14.1	%	11.5 - 14.0
<u>E.S.R.(Westergren Method)</u>			
After one hour :	06	mm/hr	3 - 12

TESTS DONE ON FULLY AUTOMATED HEMATOLOGY ANALYZER.

Dr. Gayatri M. Mehta

M. D. (Patho)

Reg. No. G-32215

DR GAYATRI MEHTA
MD(PATHOLOGY)

DR. ANAND D. PARIKH
MD(PATHOLOGY)

LAB USE ONLY (Entered by :GM Enter Date/Time:12/03/2022 12:19:00) (Verify by :GM Verify Date/Time:12/03/2022 12:19:00)

ISO 9001:2015 Certified Diagnostics Center

Vidhi Imaging Center | Pathology Department

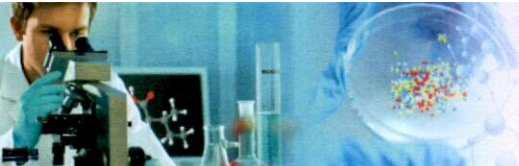L-86, Swatantra Senani Nagar, Opp. Akhbarnagar Petrol Pump, Nr. Akhbarnagar Circle, Nava-Vadaj, Ahmedabad - 380 013.

Ph. (Pathology) : 079-2764 5405, 8849893954 M. 98799 29406, 98250 09406, E-mail : vidhidiagnostics@gmail.com, Web. : www.vidhidiagnostics.com

Time (Pathology) : Mon. to Sat. 8.30 am to 8.00 pm, Sunday 9 am to 12 Noon

Pathology means science behind medicine

CT SCAN & CBCT FACILITY NOW AVAILABLE



Patient's name : SANDHYA LAL
Age/Sex : 34 Years/Female
Referred by : -
Collection Time : 09:29

Reg. ID : P-8410-21
Accession : 9825
Order Dt/time : 12/03/2022 09:29

Blood Group

Sample Type: EDTA sample.

Test Name	Result
BG :	" B "
RH :	POSITIVE
Remarks	Done by forward grouping method.

Dr. Gayatri M. Mehta

M. D. (Patho)

Reg. No. G-32215
DR. GAYATRI MEHTA
MD(PATHOLOGY)

DR. ANAND D. PARIKH
MD(PATHOLOGY)

LAB USE ONLY (Entered by :GM Enter Date/Time:12/03/2022 16:38:00) (Verify by :GM Verify Date/Time:12/03/2022 16:38:00)

ISO 9001:2015 Certified Diagnostics Center

Vidhi Imaging Center | Pathology Department

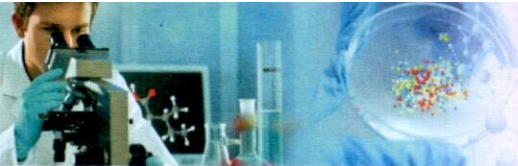L-86, Swatantra Senani Nagar, Opp. Akhbarnagar Petrol Pump, Nr. Akhbarnagar Circle, Nava-Vadaj, Ahmedabad - 380 013.

Ph. (Pathology) : 079-2764 5405, 8849893954 M. 98799 29406, 98250 09406, E-mail : vidhidiagnostics@gmail.com, Web. : www.vidhidiagnostics.com

Time (Pathology) : Mon. to Sat. 8.30 am to 8.00 pm, Sunday 9 am to 12 Noon

Pathology means science behind medicine

CT SCAN & CBCT FACILITY NOW AVAILABLE



Patient's name	: SANDHYA LAL	Reg. ID	: P-8410-21
Age/Sex	: 34 Years/Female	Accession	: 9825
Referred by	: -	Order Dt/time	: 12/03/2022 09:29
Collection Time	: 09:29		

Blood Glucose

Sample Type: Serum

Test Name	Result	Units	Biological Reference Interval
Fasting Blood Glucose :	90.7	mg/dl	70 - 110
<i>GOD-POD Method.</i>			

Blood Glucose

Sample Type: Serum

Test Name	Result	Units	Biological Reference Interval
Post Prandial Blood Glucose After 2hr. :	<u>151.8</u>	mg/dl	80 - 140
<i>GOD-POD Method.</i>			

Dr. Gayatri M. Mehta

M. D. (Patho)

Reg. No. G-32215

DR GAYATRI MEHTA
MD(PATHOLOGY)

DR. ANAND D. PARIKH
MD(PATHOLOGY)

LAB USE ONLY (Entered by :GM Enter Date/Time:12/03/2022 16:39:00) (Verify by :GM Verify Date/Time:12/03/2022 16:39:00)

ISO 9001:2015 Certified Diagnostics Center

Vidhi Imaging Center | Pathology Department

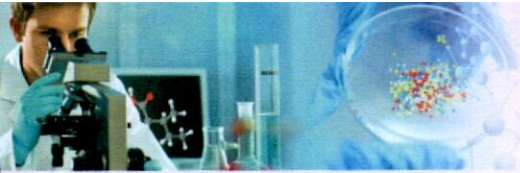L-86, Swatantra Senani Nagar, Opp. Akhbar Nagar Petrol Pump, Nr. Akhbar Nagar Circle, Nava-Vadaj, Ahmedabad - 380 013.

Ph. (Pathology) : 079-2764 5405, 8849893954 M. 98799 29406, 98250 09406, E-mail : vidhidiagnostics@gmail.com, Web. : www.vidhidiagnostics.com

Time (Pathology) : Mon. to Sat. 8.30 am to 8.00 pm, Sunday 9 am to 12 Noon

Pathology means science behind medicine

CT SCAN & CBCT FACILITY NOW AVAILABLE



Patient's name : SANDHYA LAL
Age/Sex : 34 Years/Female
Referred by : -
Collection Time : 09:29

Reg. ID : P-8410-21
Accession : 9825
Order Dt/time : 12/03/2022 09:29

HbA1C

Sample Type: Serum

Test Name	Result	Units	Biological Reference Interval
HbA1C :	5.0	%	Non-diabetic: 4.2-6.2 Pre-diabetic : 6.3-7.2 Diabetic : 7.3-8.2
Mean Blood Glucose of Last 03 months.	96.8	mg/dl	

Comment

NOTE:

*As per the new 2009 update of American Diabetes Association regarding HbA1C & Mean Blood Glucose relationship.
This test is used to monitor diabetic patients compliance with the therapeutic regimen and logo It's level is proportional to both the average blood glucose concentration and the life span of the red blood cells (RBC) in circulation. HbA1c values are free of day to day glucose fluctuations and are unaffected by exercise or recent food intake.

Dr. Gayatri M. Mehta

M. D. (Patho)

Reg. No. G-32215
DR GAYATRI MEHTA
MD(PATHOLOGY)

DR. ANAND D. PARIKH
MD(PATHOLOGY)

LAB USE ONLY (Entered by :GM Enter Date/Time:12/03/2022 16:09:00) (Verify by :GM Verify Date/Time:12/03/2022 16:09:00)

ISO 9001:2015 Certified Diagnostics Center

Vidhi Imaging Center | Pathology Department

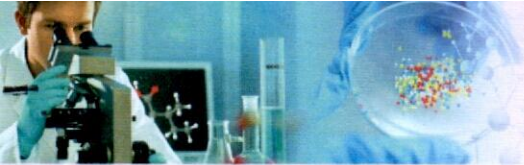L-86, Swatantra Senani Nagar, Opp. Akhbarnagar Petrol Pump, Nr. Akhbarnagar Circle, Nava-Vadaj, Ahmedabad - 380 013.

Ph. (Pathology) : 079-2764 5405, 8849893954 M. 98799 29406, 98250 09406, E-mail : vidhidiagnostics@gmail.com, Web. : www.vidhidiagnostics.com

Time (Pathology) : Mon. to Sat. 8.30 am to 8.00 pm, Sunday 9 am to 12 Noon

Pathology means science behind medicine

CT SCAN & CBCT FACILITY NOW AVAILABLE



Pathology Department

Patient's name : SANDHYA LAL
Age/Sex : 34 Years/Female
Referred by : -
Collection Time : 09:29

Reg. ID : P-8410-21
Accession : 9825
Order Dt/time : 12/03/2022 09:29

Lipid Profile

Sample Type: Serum

Test Name	Result	Units	Biological Reference Interval
S. Cholesterol : Oxidase-esterase method.	187.0	mg/dl	0 - 200
S. Triglyceride : Enzymatic Colorimetry method	141.7	mg/dL	0 - 200
S. HDL - Cholesterol : Serum by Enzymatic method.	54.5	mg/dL	35 - 65
S. LDL - Cholesterol : Serum by Enzymatic method	104.16	mg/dL	0 - 130
S. VLDL - Cholesterol :	28.34	mg/dL	0 - 30
S. Chole/HDL Ratio :	3.43		1 - 6
S. LDL / HDL Cholesterol Ratio :	1.91		0 - 3.5

Dr. Gayatri M. Mehta

M. D. (Patho)

Reg. No. G-32215

DR GAYATRI MEHTA
MD(PATHOLOGY)

DR. ANAND D. PARIKH
MD(PATHOLOGY)

LAB USE ONLY (Entered by :GM Enter Date/Time:12/03/2022 16:09:00) (Verify by :GM Verify Date/Time:12/03/2022 16:09:00)

ISO 9001:2015 Certified Diagnostics Center

Vidhi Imaging Center | Pathology Department

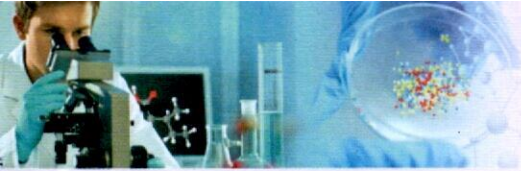L-86, Swatantra Senani Nagar, Opp. Akhbarnagar Petrol Pump, Nr. Akhbarnagar Circle, Nava-Vadaj, Ahmedabad - 380 013.

Ph. (Pathology) : 079-2764 5405, 8849893954 M. 98799 29406, 98250 09406, E-mail : vidhidiagnostics@gmail.com, Web. : www.vidhidiagnostics.com

Time (Pathology) : Mon. to Sat. 8.30 am to 8.00 pm, Sunday 9 am to 12 Noon

Pathology means science behind medicine

CT SCAN & CBCT FACILITY NOW AVAILABLE



Patient's name : SANDHYA LAL
Age/Sex : 34 Years/Female
Referred by : -
Collection Time : 09:29

Reg. ID : P-8410-21
Accession : 9825
Order Dt/time : 12/03/2022 09:29

BIOCHEMISTRY

Sample type : Serum

Test Name	Result	Units	Biological Reference Interval
Urea, (Serum by GLDH method) :	16.0	mg/dl	10 - 50
S.Uric acid, (Serum by Uricase method) :	5.0	mg/dl	2.4-5.7
Bun :	7.5	mg/dl	6-20
Creatinine, (Serum by Enzymatic reaction) :	0.55	mg/dl	0.5-1.2
S.G.P.T (ALT) : (Serum by IFCC method)	12.5	U/L	0 - 40
S.G.O.T (AST) : (Serum by IFCC method)	23.5	U/L	0 - 37
ALK.PHOSPHATASE : (Serum by PNP method)	70.0	U/L	35-104
G.G.T :	10.2	U/L	8 - 78
<u>BILIRUBIN</u>			
Total :	0.68	mg/dl	Up to 1.2
Direct :	0.28	mg/dl	0-0.7
Indirect :	0.4	mg/dl	0 - 0.5
<u>SERUM PROTEINS</u>			
Total Protein (Serum by Biuret method) :	7.24	gms/dl	
Albumin (Serum by BCG method) :	3.98	gms/dl	3.97-4.94
Globulins :	3.26	gms/dl	2.3 - 3.5
A/G Ratio :	1.221		0.9 - 2.9

Dr. Gayatri M. Mehta

M. D. (Patho)

Reg. No. G-32215
DR GAYATRI MEHTA
MD(PATHOLOGY)

DR. ANAND D. PARIKH
MD(PATHOLOGY)

LAB USE ONLY (Entered by : GM Enter Date/Time: 12/03/2022 16:09:00) (Verify by : GM Verify Date/Time: 12/03/2022 16:09:00)

ISO 9001:2015 Certified Diagnostics Center

Vidhi Imaging Center | Pathology Department

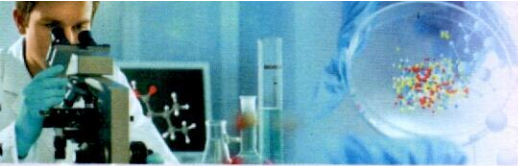L-86, Swatantra Senani Nagar, Opp. Akhbarnagar Petrol Pump, Nr. Akhbarnagar Circle, Nava-Vadaj, Ahmedabad - 380 013.

Ph. (Pathology) : 079-2764 5405, 8849893954 M. 98799 29406, 98250 09406, E-mail : vidhidiagnostics@gmail.com, Web. : www.vidhidiagnostics.com

Time (Pathology) : Mon. to Sat. 8.30 am to 8.00 pm, Sunday 9 am to 12 Noon

Pathology means science behind medicine

CT SCAN & CBCT FACILITY NOW AVAILABLE



Pathology Department

Patient's name : SANDHYA LAL
 Age/Sex : 34 Years/Female
 Referred by : -
 Collection Time : 09:29

Reg. ID : P-8410-21
 Accession : 9825
 Order Dt/time : 12/03/2022 09:29

Thyroid Function Test

Sample Type: Serum

Test Name	Result	Units	Biological Reference Interval
TOTAL T3 :	1.23	ng/ml	0.84 - 2.0
TOTAL T4 :	7.8	ug/dl	5.1 - 14.0
TSH(Ultra sensitive) :	2.140	mIU/L	0.27 - 4.2
Method	Electrochemiluminescence Immunoassay "ECLIA"		

Test done on Roche Cobas e411 Immunoassay Analyser

Dr. Gayatri M. Mehta

M. D. (Patho)

Reg. No. G-32215

DR GAYATRI MEHTA
MD(PATHOLOGY)

DR. ANAND D. PARIKH
MD(PATHOLOGY)

LAB USE ONLY (Entered by :GM Enter Date/Time:12/03/2022 16:09:00) (Verify by :GM Verify Date/Time:12/03/2022 16:09:00)

ISO 9001:2015 Certified Diagnostics Center

Vidhi Imaging Center | Pathology Department

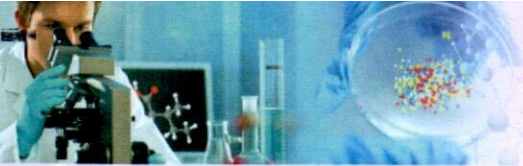L-86, Swatantra Senani Nagar, Opp. Akhbarnagar Petrol Pump, Nr. Akhbarnagar Circle, Nava-Vadaj, Ahmedabad - 380 013.

Ph. (Pathology) : 079-2764 5405, 8849893954 M. 98799 29406, 98250 09406, E-mail : vidhidiagnostics@gmail.com, Web : www.vidhidiagnostics.com

Time (Pathology) : Mon. to Sat. 8.30 am to 8.00 pm, Sunday 9 am to 12 Noon

Pathology means science behind medicine

CT SCAN & CBCT FACILITY NOW AVAILABLE



Pathology Department

Patient's name : SANDHYA LAL
Age/Sex : 34 Years/Female
Referred by : -
Collection Time : 09:29

Reg. ID : P-8410-21
Accession : 9825
Order Dt/time : 12/03/2022 09:29

Urine Analysis

Sample Type: Urine

Test Name	Result	Units	Biological Reference Interval
<u>Physical Examination</u>			
Quantity :	20	ml	0 - 500 ml
Colour :	Pale Yellow		Pale Yellow
Transparency :	Slight Turbid.		Clear
Reaction :	Acidic		4.6 - 8.0
Specific Gravity :	1.015		1.016 - 1.022
Sediment :	Present		
<u>Chemical Examination</u>			
Albumin :	Present (Faint Trace)		Absent
Sugar :	NIL		Absent
Acetone :	Absent		Absent
Bile Salts :	Absent		Absent
Bile Pigments :	Absent		Absent
Urobilogen :	Absent		Absent
Nitrites :	Absent		Absent
<u>Microscopic Examination</u>			
Red blood Cells :	1-2	/h.p.f	Absent
Pus Cells :	2-3	/h.p.f	Absent
Epithelial Cells :	1-2	/h.p.f	< 10.0
Amorphous :	Absent	/h.p.f	Absent
Bacteria :	Absent	/h.p.f	Absent
Crystals :	Absent	/h.p.f	Absent
Casts :	Absent	/h.p.f	Absent
Fungus :	Not seen	/h.p.f	Absent

Dr. Gayatri M. Mehta

M. D. (Patho)

Reg. No. G-32215

DR GAYATRI MEHTA
MD(PATHOLOGY)

DR. ANAND D. PARIKH
MD(PATHOLOGY)

ISO 9001:2015 Certified Diagnostics Center

Vidhi Imaging Center | Pathology Department

L-86, Swatantra Nagar, Akhbarnagar Petrol Pump, Nr. Akhbarnagar Circle, Nava-Vadaj, Ahmedabad - 380 013.

Ph. (Pathology) : 079-2764 5405, 8849893954 M. 98799 29406, 98250 09406, E-mail : vidhidiagnostics@gmail.com, Web : www.vidhidiagnostics.com

Time (Pathology) : Mon. to Sat. 8.30 am to 8.00 pm, Sunday 9 am to 12 Noon

Pathology means science behind medicine

CT SCAN & CBCT FACILITY NOW AVAILABLE



Vidhi Diagnostics

L-86, Swatantra-Senani Nagar,
Opp. Akhbarnagar Bus Terminals,
Nr. Akhbarnagar Circle,
New Wadaj, Ahmedabad-13.

Dr. Vidhi D. Modh
MBBS
Reg. No. G-74540

AIL ID
#HIDIAGNOSTICS@
MAIL.COM

Vidhi Diagnostics
L-86, Swatantra-Senani Nagar,
Opp. Akhbarnagar Bus Terminals,
Nr. Akhbarnagar Circle,
New Wadaj, Ahmedabad-13.

Dr. Vidhi D. Modh
MBBS
Reg. No. G-74540

Saturday, 12 March 2022 9:57:40 am

Index number: 33