

To,
DDRC agilus

Dear Sir / Madam,

We hereby declare that we are not going
for doctor consultation.

Regards,

Akhila - S

Dilip - S

Akhila
Dilip



To,
DDRC agilus .
Tirandrum

We hereby declare that we are not undergoing
stool examination.

Yours faithfully.

Akhila. S

Dilip. S

Akhila




ECHO REPORT

Name:AKHILA.S	Age/Sex:31Y/F	Date:23/12/2023
---------------	---------------	-----------------

Left Ventricle:-

	Diastole	Systole
IVS	1.11cm	1.24cm
LV	4.42cm	2.86cm
LVPW	1.16cm	1.27cm

EF - 68% FS - 35%

AO	LA
3.33cm	3.70cm

PV - 1.28m/s
AV - 1.36m/s
MVE - 0.97m/s
MVA - 0.55m/s
E/A - 1.78

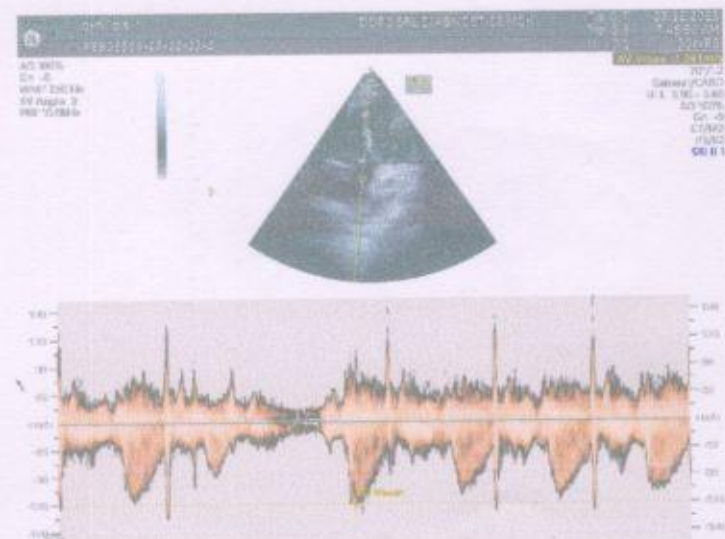
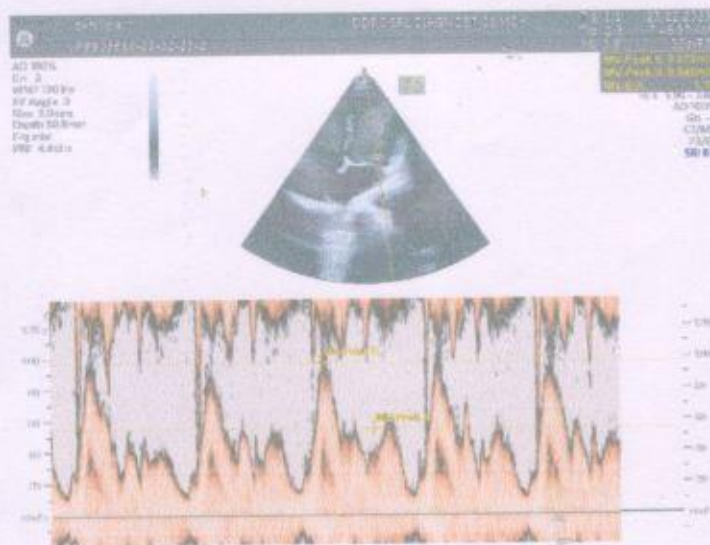
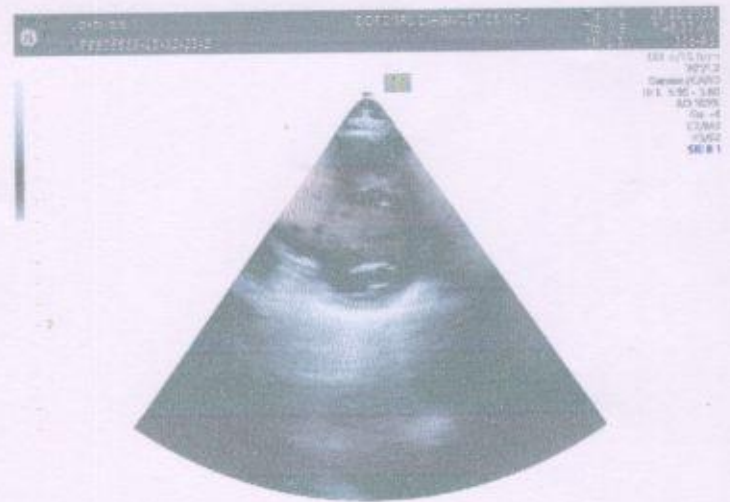
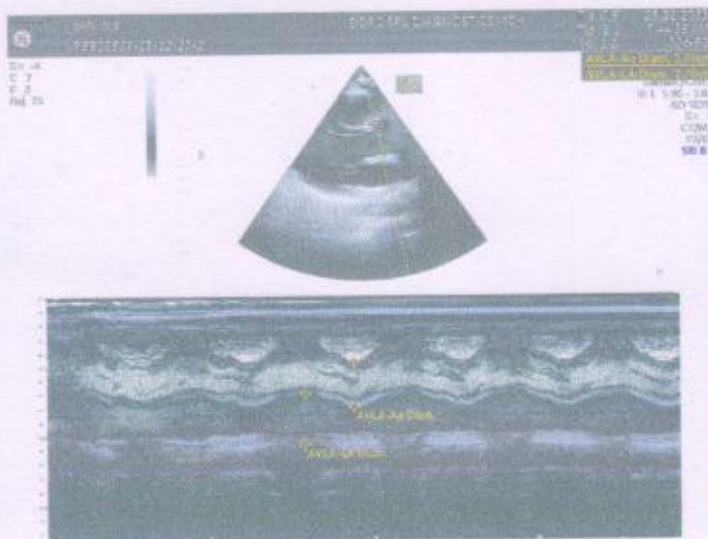
IMPRESSION:-

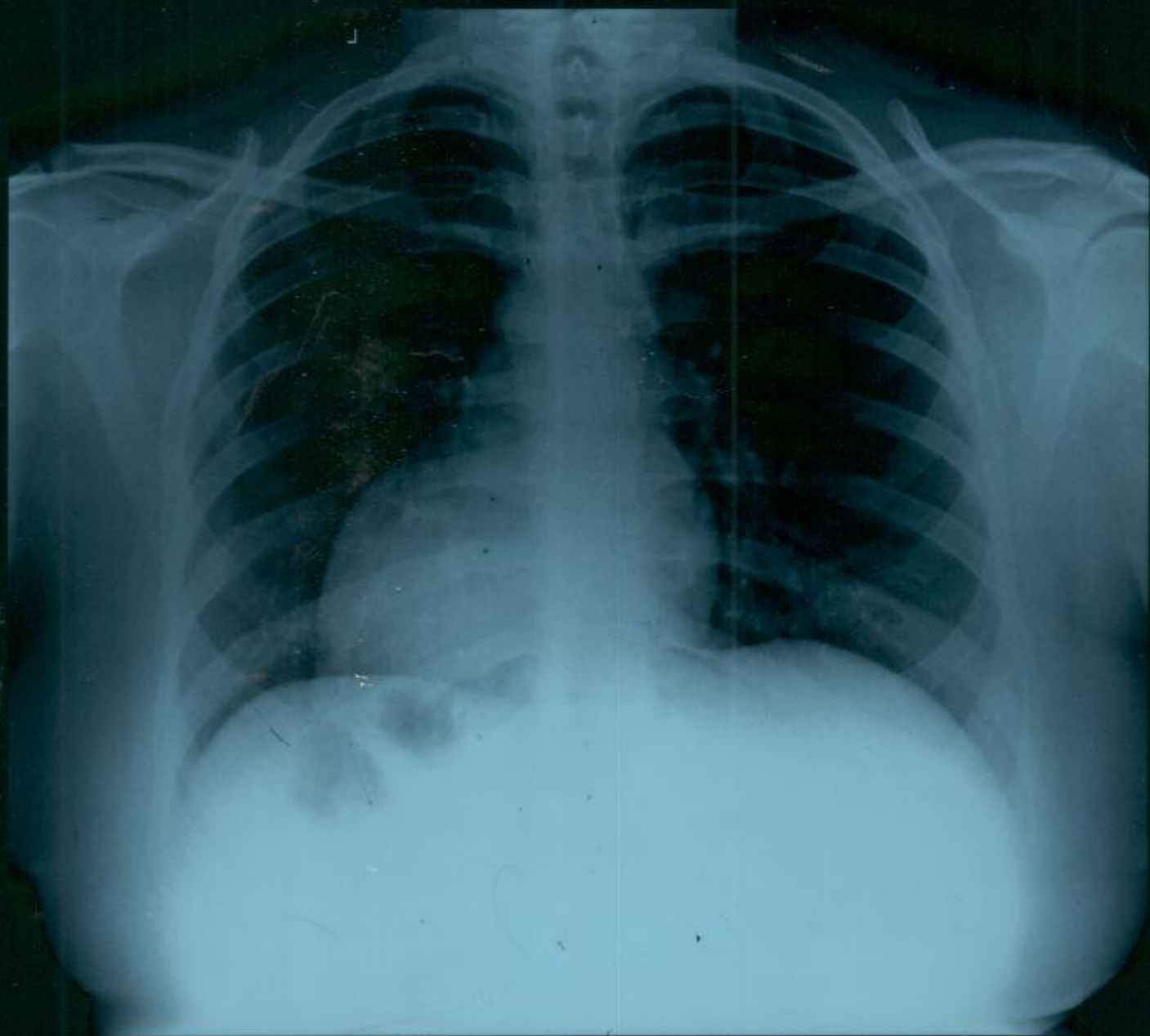
- Normal chambers dimensions
- No RWMA
- Good LV systolic function
- Good RV function
- No diastolic dysfunction
- No AS,AR,MR,MS,TR,PAH
- No Vegetation/clot/effusion
- IAS/IVS intact




 **Consultant Cardiologist**
Dr SHASHIKANTH Y.S
MBBS,MD,DM(Cardiology)
Consultant Cardiologist
TMC Reg No: 73538

DDRC agilus Pathlabs Limited.





MRS AKHILA S. 31Y F 1252312023 CHEST - PA WL009103 V
DRCR AGILUS

V1

V2

V3

V4

ID: 009103

Diagnosis Information:

Female

31 Years

mmHg

kg

Mr. Mohd S

HR

: 72

bpm

P

: 92

ms

PR

: 124

ms

QRS

: 90

ms

QT/QTc

: 376/411

ms

P/QRST

: 12/43/9

°

RV5/SV1

: 0.800/0.685

mV

Report Confirmed by:



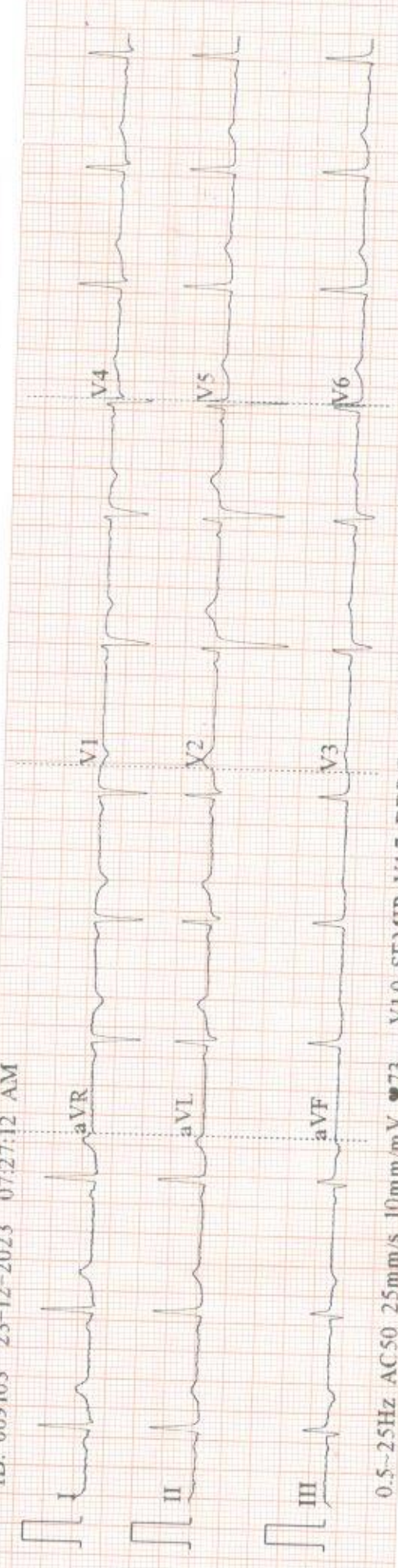
A. W. C

V6

Standard

Standard	L I	L II	L III	L III Inspiration

ID: 009103 23-12-2023 07:27:12 AM



0.5~25Hz ACS50 25mm/s 10mm/mV ♡73 V1.0 SEMIP V1.7 DDRG-AGILUS
A→W CE

NAME : MRS AKHILA S	AGE:31/F	DATE: 23/12/2023
---------------------	----------	------------------

CHEST X-RAY REPORT

CHEST X-RAY PA VIEW : Trachea central
 No cardiomegaly
 Normal vascularity
 No parenchymal lesion.
 Costophrenic and cardiophrenic angles clear

➤ **IMPRESSION** : Normal Chest Xray

ELECTRO CARDIOGRAM : NSR: 72/minute
 No evidence of ischaemia

➤ **IMPRESSION** : Normal Ecg.

Company name: BOB



[Signature]
Dr. SERIN LOPEZ. MBBS
 Reg. No. 77656
 MEDICAL OFFICER
 DDRC AGILUS PATHLABS LTD.
 Aster Square, Medical College, PO, TVM

DR SERIN LOPEZ MBBS

Reg No 77656

DDRC AGILUS PATHLABS LTD

RADIOLOGY DIVISION				
Acc no:4182WL009103	Name: Mrs. Akhila S	Age: 31 y	Sex: Female	Date:23.12.23

US SCAN WHOLE ABDOMEN (TAS + TVS)

LIVER is normal in size (13.6 cm). Margins are regular. **Hepatic parenchyma shows mildly increased echogenicity.** No focal lesions seen. No dilatation of intrahepatic biliary radicles. CBD is not dilated. Portal vein is normal in caliber (10.1 mm).

GALL BLADDER is partially distended and grossly normal. No pericholecystic fluid seen.

SPLEEN is normal in size (8.1 cm) and parenchymal echotexture. No focal lesion seen.

PANCREAS Head and body visualized, appears normal in size and parenchymal echotexture. Pancreatic duct is not dilated.

RIGHT KIDNEY is normal in size (11.8 x 4.1 cm) and shows normal parenchymal echotexture. Cortico medullary differentiation is maintained. Parenchymal thickness is normal. No echogenic focus with shadowing suggestive of renal calculi seen. No dilatation of pelvicalyceal system seen. Ureter is not dilated. Perinephric spaces are normal.

LEFT KIDNEY is normal in size (9.4 x 4.4 cm) and shows normal parenchymal echotexture. Cortico medullary differentiation is maintained. Parenchymal thickness is normal. No echogenic focus with shadowing suggestive of renal calculi seen. No dilatation of pelvicalyceal system seen. Ureter is not dilated. Perinephric spaces are normal.

PARAAORTIC AREA No retroperitoneal lymphadenopathy or mass seen.

URINARY BLADDER is distended, normal in wall thickness, lumen clear.

UTERUS measures 7.9 x 4.3 x 5.5 cm, **myometrial echopattern is mildly inhomogeneous.** No focal lesions seen. Endometrial thickness is 10.4 mm. *Intrauterine device noted in situ towards the lower endometrial cavity - H/o mirena insertion.* **Nabothian cyst noted in cervix measuring 6.2 mm.** Both ovaries are normal. Right ovary measures 2.9 x 1.8 cm. Left ovary measures 3.3 x 1.6 cm and shows corpus luteum measuring 1.7 x 1.5 cm. No adnexal mass seen. No fluid in pouch of Douglas. No ascites or pleural effusion.

Gaseous distension of bowel loops noted. No obvious bowel wall thickening seen sonologically.

CONCLUSION:-

- **Grade I fatty liver.**

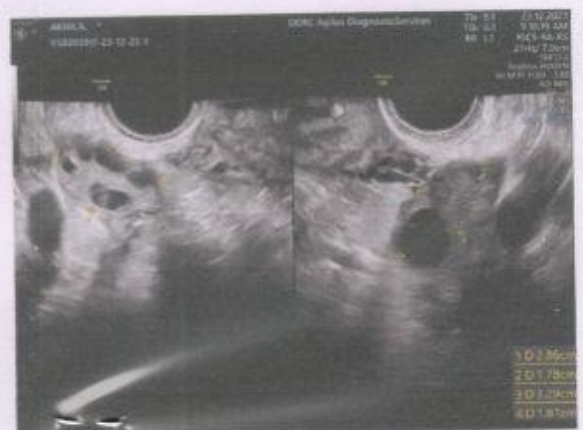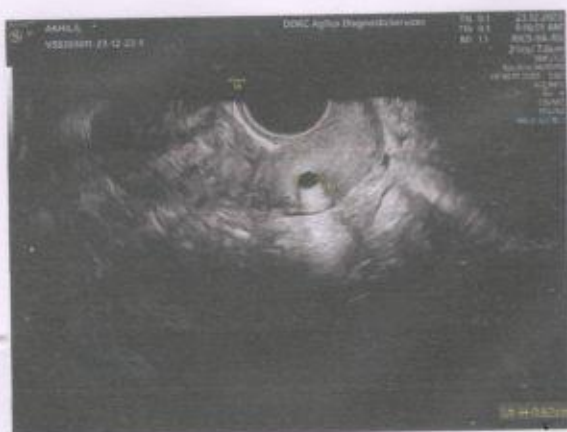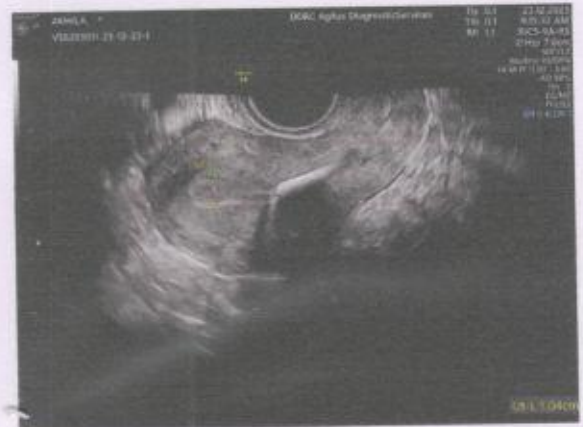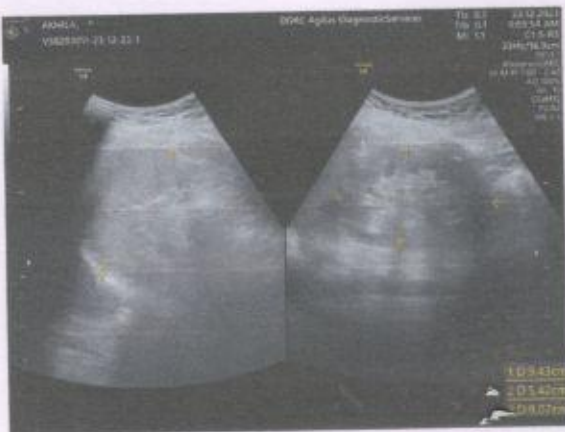
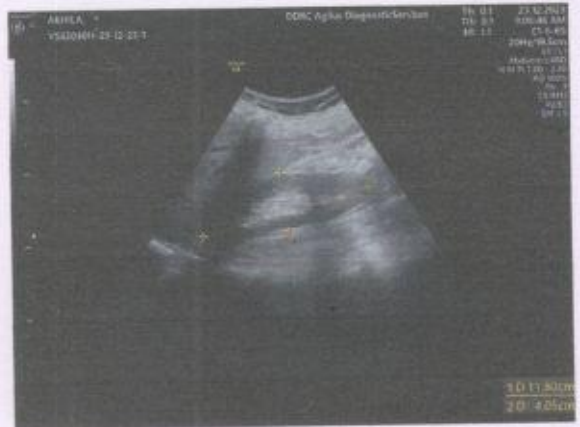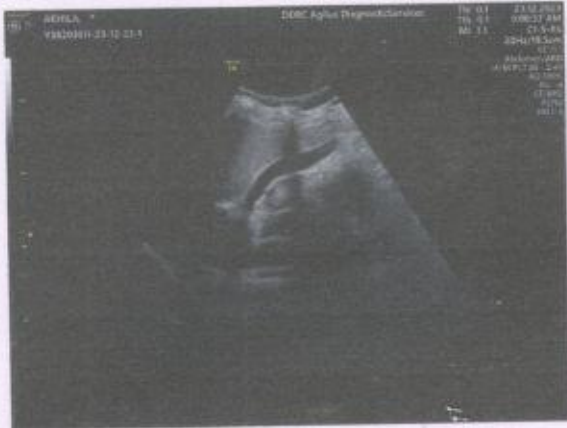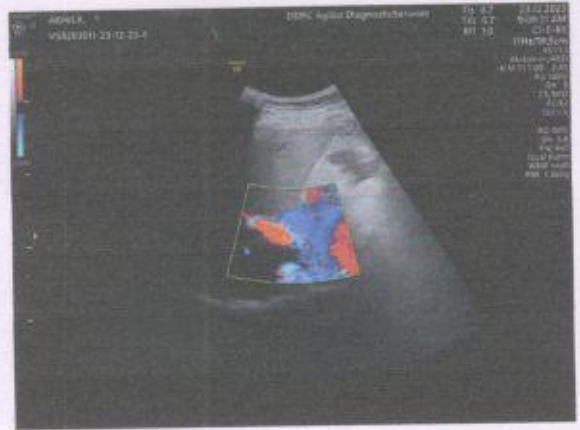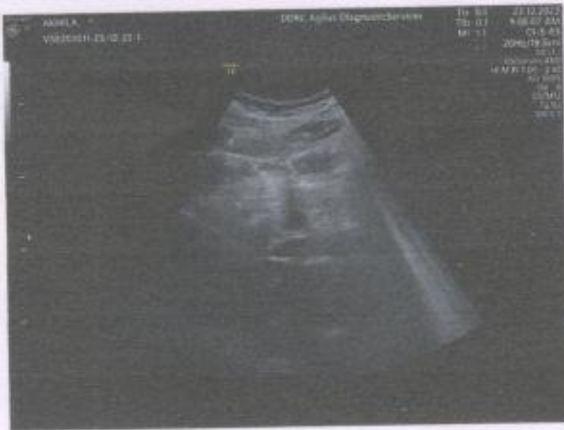Dr. Nisha Unni MD , DNB (RD)
Consultant radiologist.

*Thanks for referral. Your feedback will be appreciated.
(Please bring relevant investigation reports during all visits)
Because of technical and technological limitations complete accuracy cannot be assured on imaging.
Suggested correlation with clinical findings and other relevant investigations consultations, and if required repeat imaging recommended in the event of controversies. AR*

(For appointments / any clarification of report please contact 9496005190 between 9 am – 5.30 pm).

DDRC agilus Pathlabs Limited.

Corp. Office : Express House, Second Floor, Opp. Pothys Silks, Banerjee Road, Kaloor -682017
Contact :- 93334 93334, Web :- www.ddrcagilus.com Email :- info.ddrc@agilus.in



PATIENT NAME : MRS. AKHILA S
REF. DOCTOR : SELF
CODE/NAME & ADDRESS : CA00010147 -

 MEDIWHEEL ARCOFEMI HEALTHCARE LIMITED
 F701A, LADO SARAI, NEW DELHI, SOUTH DELHI,
 DELHI,
 SOUTH DELHI 110030
 8800465156

ACCESSION NO : 4182WL009103
PATIENT ID : AKHIF1711934182
CLIENT PATIENT ID:
ABHA NO :
AGE/SEX : 31 Years Female
DRAWN :
RECEIVED : 23/12/2023 06:57:58
REPORTED : 23/12/2023 15:52:38

Test Report Status	<u>Preliminary</u>	Results	Biological Reference Interval	Units
--------------------	--------------------	---------	-------------------------------	-------


MEDIWHEEL HEALTH CHECKUP BELOW 40(F)2DECHO
PHYSICAL EXAMINATION

PHYSICAL EXAMINATION

REPORT GIVEN


DR NISHA UNNI, MBBS,MD
(RD),DNB (Reg.No:50162)
Consultant Radiologist

Page 1 Of 11


[View Details](#)
[View Report](#)
PERFORMED AT :

 DDRC AGILUS PATHLABS LIMITED
 ASTER SQUARE BUILDING, ULLOOR,
 MEDICAL COLLEGE P.O
 TRIVANDRUM, 695011
 KERALA, INDIA
 Tel : 93334 93334, Fax : CIN - U85190MH2006PTC161480
 Email : customercare.ddrc@agilus.in

Patient Ref. No. 66600007221128

PATIENT NAME : MRS. AKHILA S		REF. DOCTOR : SELF	
CODE/NAME & ADDRESS : CA00010147 - MEDIWHEEL ARCOFEMI HEALTHCARE LIMITED F701A, LADO SARAI, NEW DELHI,SOUTH DELHI, DELHI, SOUTH DELHI 110030 8800465156		ACCESSION NO : 4182WL009103	AGE/SEX : 31 Years Female
		PATIENT ID : AKHIF1711934182	DRAWN :
		CLIENT PATIENT ID:	RECEIVED : 23/12/2023 06:57:58
		ABHA NO :	REPORTED : 23/12/2023 15:52:38

Test Report Status	Preliminary	Results	Units
--------------------	-------------	---------	-------

MEDIWHEEL HEALTH CHECKUP BELOW 40(F)2DECHO

ECG WITH REPORT

REPORT

REPORT GIVEN

USG ABDOMEN AND PELVIS

REPORT

REPORT GIVEN

CHEST X-RAY WITH REPORT

REPORT

REPORT GIVEN

2D - ECHO WITH COLOR DOPPLER

REPORT

REPORT GIVEN

HAEMATOLOGY

MEDIWHEEL HEALTH CHECKUP BELOW 40(F)2DECHO


GLYCOSYLATED HEMOGLOBIN(HBA1C), EDTA WHOLE BLOOD

HBA1C	5.6	Non-diabetic Adult < 5.7 Pre-diabetes 5.7 - 6.4 Diabetes diagnosis: > or = 6.5 Therapeutic goals: < 7.0 Action suggested : > 8.0 (ADA Guideline 2021)	%
MEAN PLASMA GLUCOSE	114.0	< 116.0	mg/dL

DR NISHA UNNI, MBBS,MD
(RD),DNB (Reg.No:50162)
Consultant Radiologist

DR.HARI SHANKAR, MBBS MD
(Reg No - TCMC:62092)
HEAD - Biochemistry & Immunology

DR.VAISHALI RAJAN, MBBS DCP
(Pathology)
(Reg No - TCC 27150)
HOD - HAEMATOLOGY



[View Details](#) [View Report](#)

PERFORMED AT :

DDRC AGILUS PATHLABS LIMITED
ASTER SQUARE BUILDING, ULLOOR,
MEDICAL COLLEGE P.O
TRIVANDRUM, 695011
KERALA, INDIA
Tel : 93334 93334, Fax : CIN - U85190MH2006PTC161480
Email : customercare.ddrc@agilus.in



Patient Ref. No. 66600007221128

PATIENT NAME : MRS. AKHILA S

REF. DOCTOR : SELF

CODE/NAME & ADDRESS : CA00010147 -
MEDIWHEEL ARCOFEMI HEALTHCARE LIMITED
F701A, LADO SARAI, NEW DELHI,SOUTH DELHI,
DELHI,
SOUTH DELHI 110030
8800465156

ACCESSION NO : 4182WL009103
PATIENT ID : AKHIF1711934182
CLIENT PATIENT ID:
ABHA NO :

AGE/SEX : 31 Years Female
DRAWN :
RECEIVED : 23/12/2023 06:57:58
REPORTED : 23/12/2023 15:52:38

Test Report Status	Preliminary	Results	Units
--------------------	-------------	---------	-------

BLOOD COUNTS,EDTA WHOLE BLOOD

HEMOGLOBIN	12.6	12.0 - 15.0	g/dL
RED BLOOD CELL COUNT	4.59	3.80 - 4.80	mil/ μ L
WHITE BLOOD CELL COUNT	7.19	4.0 - 10.0	thou/ μ L
PLATELET COUNT	237	150 - 410	thou/ μ L

RBC AND PLATELET INDICES


HEMATOCRIT	37.6	36.0 - 46.0	%
MEAN CORPUSCULAR VOL	81.9 Low	83.0 - 101	fL
MEAN CORPUSCULAR HGB.	27.5	27.0 - 32.0	pg
MEAN CORPUSCULAR HEMOGLOBIN CONCENTRATION	33.5	31.50 - 34.50	g/dL
RED CELL DISTRIBUTION WIDTH	13.4	11.60 - 14.0	%
MENTZER INDEX	17.8		
MEAN PLATELET VOLUME	9.1	6.80 - 10.90	fL

WBC DIFFERENTIAL COUNT

SEGMENTED NEUTROPHILS	57	40.0 - 80.0	%
LYMPHOCYTES	33	20.0 - 40.0	%
MONOCYTES	5	2.0 - 10.0	%
EOSINOPHILS	5	1.0 - 6.0	%
BASOPHILS	0	0.0 - 1.0	%
ABSOLUTE NEUTROPHIL COUNT	4.10	2.0 - 7.0	thou/ μ L
ABSOLUTE LYMPHOCYTE COUNT	2.37	1.0 - 3.0	thou/ μ L
ABSOLUTE MONOCYTE COUNT	0.34	0.20 - 1.0	thou/ μ L
ABSOLUTE EOSINOPHIL COUNT	0.34	0.02 - 0.50	thou/ μ L
ABSOLUTE BASOPHIL COUNT	0		thou/ μ L
NEUTROPHIL LYMPHOCYTE RATIO (NLR)	1.7		

DR.HARI SHANKAR, MBBS MD
(Reg No - TCMC:62092)
HEAD - Biochemistry & Immunology

DR.VAISHALI RAJAN, MBBS DCP
(Pathology)
(Reg No - TCC 27150)
HOD - HAEMATOLOGY



PERFORMED AT :

DDRC AGILUS PATHLABS LIMITED
ASTER SQUARE BUILDING, ULLOOR,
MEDICAL COLLEGE P.O
TRIVANDRUM, 695011
KERALA, INDIA
Tel : 93334 93334, Fax : CIN - U85190MH2006PTC161480
Email : customercare.ddrc@agilus.in



PATIENT NAME : MRS. AKHILA S

REF. DOCTOR : SELF

CODE/NAME & ADDRESS : CA00010147 -

MEDIWHEEL ARCOFEMI HEALTHCARE LIMITED
F701A, LADO SARAI, NEW DELHI, SOUTH DELHI,
DELHI,
SOUTH DELHI 110030
8800465156ACCESSION NO : **4182WL009103**

PATIENT ID : AKHIF1711934182

CLIENT PATIENT ID:

ABHA NO :

AGE/SEX : 31 Years Female

DRAWN :

RECEIVED : 23/12/2023 06:57:58

REPORTED : 23/12/2023 15:52:38

Test Report Status	Preliminary	Results	Units
--------------------	-------------	---------	-------

ERYTHROCYTE SEDIMENTATION RATE (ESR), EDTA BLOOD

SEDIMENTATION RATE (ESR)	15	0 - 20	mm at 1 hr
--------------------------	----	--------	------------

SUGAR URINE - POST PRANDIAL

SUGAR URINE - POST PRANDIAL	NOT DETECTED	NOT DETECTED
-----------------------------	--------------	--------------

SUGAR URINE - FASTING

SUGAR URINE - FASTING	NOT DETECTED	NOT DETECTED
-----------------------	--------------	--------------

IMMUNOHAEMATOLOGY**MEDIWHEEL HEALTH CHECKUP BELOW 40(F)2DECHO****ABO GROUP & RH TYPE, EDTA WHOLE BLOOD**

ABO GROUP	TYPE B
RH TYPE	POSITIVE

METHOD : COLUMN AGGLUTINATION TECHNOLOGY

Interpretation(s)

ABO GROUP & RH TYPE, EDTA WHOLE BLOOD-Blood group is identified by antigens and antibodies present in the blood. Antigens are protein molecules found on the surface of red blood cells. Antibodies are found in plasma. To determine blood group, red cells are mixed with different antibody solutions to give A,B,O or AB.

Disclaimer: "Please note, as the results of previous ABO and Rh group (Blood Group) for pregnant women are not available, please check with the patient records for availability of the same."

The test is performed by both forward as well as reverse grouping methods.




DR. HARI SHANKAR, MBBS MD
(Reg No - TCMC:62092)
HEAD - Biochemistry &
Immunology



DR. VAISHALI RAJAN, MBBS DCP
(Pathology)
(Reg No - TCC 27150)
HOD - HAEMATOLOGY

Page 4 Of 11



View Details

View Report

PERFORMED AT :

DDRC AGILUS PATHLABS LIMITED
ASTER SQUARE BUILDING, ULLOOR,
MEDICAL COLLEGE P.O
TRIVANDRUM, 695011
KERALA, INDIA
Tel : 93334 93334, Fax : CIN - U85190MH2006PTC161480
Email : customercare.ddrc@agilus.in



Patient Ref. No. 66600007221128

PATIENT NAME : MRS. AKHILA S

REF. DOCTOR : SELF

CODE/NAME & ADDRESS : CA00010147 -
 MEDIWHEEL ARCOFEMI HEALTHCARE LIMITED
 F701A, LADO SARAI, NEW DELHI, SOUTH DELHI,
 DELHI,
 SOUTH DELHI 110030
 8800465156

ACCESSION NO : 4182WL009103
PATIENT ID : AKHIF1711934182
CLIENT PATIENT ID:
ABHA NO :

AGE/SEX : 31 Years Female
DRAWN :
RECEIVED : 23/12/2023 06:57:58
REPORTED : 23/12/2023 15:52:38

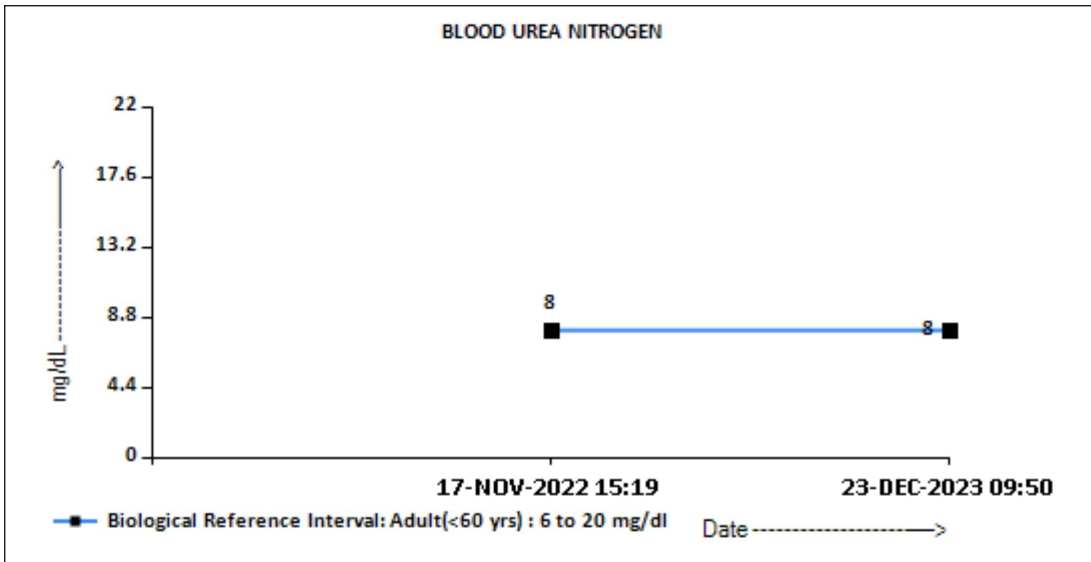
Test Report Status	Preliminary	Results	Units
--------------------	-------------	---------	-------

BIO CHEMISTRY

MEDIWHEEL HEALTH CHECKUP BELOW 40(F)2DECHO

BLOOD UREA NITROGEN (BUN), SERUM

BLOOD UREA NITROGEN 8 Adult(<60 yrs) : 6 to 20 mg/dL




BUN/CREAT RATIO

BUN/CREAT RATIO 11.4

CREATININE, SERUM

CREATININE 0.70 18 - 60 yrs : 0.6 - 1.1 mg/dL

DR.HARI SHANKAR, MBBS MD
 (Reg No - TCMC:62092)
HEAD - Biochemistry & Immunology



PERFORMED AT :

DDRC AGILUS PATHLABS LIMITED
 ASTER SQUARE BUILDING, ULLOOR,
 MEDICAL COLLEGE P.O
 TRIVANDRUM, 695011
 KERALA, INDIA
 Tel : 93334 93334, Fax : CIN - U85190MH2006PTC161480
 Email : customercare.ddrc@agilus.in



PATIENT NAME : MRS. AKHILA S

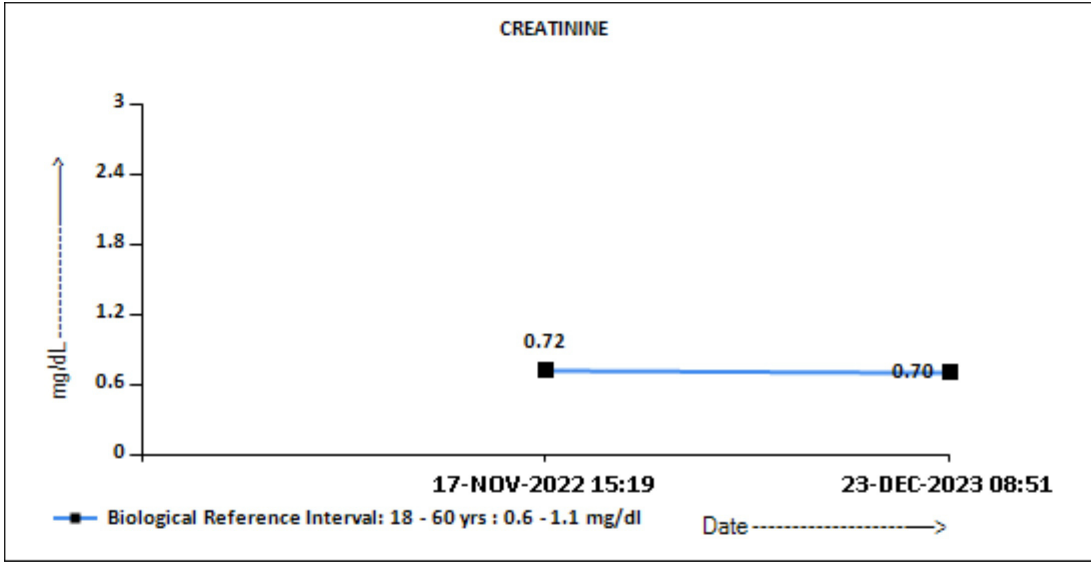
REF. DOCTOR : SELF

CODE/NAME & ADDRESS : CA00010147 -
 MEDIWHEEL ARCOFEMI HEALTHCARE LIMITED
 F701A, LADO SARAI, NEW DELHI,SOUTH DELHI,
 DELHI,
 SOUTH DELHI 110030
 8800465156

ACCESSION NO : **4182WL009103**
PATIENT ID : AKHIF1711934182
CLIENT PATIENT ID:
ABHA NO :

AGE/SEX : 31 Years Female
DRAWN :
RECEIVED : 23/12/2023 06:57:58
REPORTED : 23/12/2023 15:52:38


Test Report Status	Preliminary	Results	Units
--------------------	-------------	---------	-------



GLUCOSE, POST-PRANDIAL, PLASMA

GLUCOSE, POST-PRANDIAL, PLASMA	101	Diabetes Mellitus : > or = 200. mg/dL Impaired Glucose tolerance/ Prediabetes : 140 - 199. Hypoglycemia : < 55.
--------------------------------	-----	--

DR.HARI SHANKAR, MBBS MD
 (Reg No - TCMC:62092)
HEAD - Biochemistry & Immunology



PERFORMED AT :

DDRC AGILUS PATHLABS LIMITED
 ASTER SQUARE BUILDING, ULLOOR,
 MEDICAL COLLEGE P.O
 TRIVANDRUM, 695011
 KERALA, INDIA
 Tel : 93334 93334, Fax : CIN - U85190MH2006PTC161480
 Email : customercare.ddrc@agilus.in



PATIENT NAME : MRS. AKHILA S


REF. DOCTOR : SELF

CODE/NAME & ADDRESS : CA00010147 -
 MEDIWHEEL ARCOFEMI HEALTHCARE LIMITED
 F701A, LADO SARAI, NEW DELHI,SOUTH DELHI,
 DELHI,
 SOUTH DELHI 110030
 8800465156

ACCESSION NO : 4182WL009103
PATIENT ID : AKHIF1711934182
CLIENT PATIENT ID:
ABHA NO :

AGE/SEX : 31 Years Female
DRAWN :
RECEIVED : 23/12/2023 06:57:58
REPORTED : 23/12/2023 15:52:38


Test Report Status	Preliminary	Results	Units
--------------------	-------------	---------	-------



GLUCOSE FASTING,FLUORIDE PLASMA

FBS (FASTING BLOOD SUGAR)	99	Diabetes Mellitus : > or = 126. mg/dL Impaired fasting Glucose/ Prediabetes : 101 - 125. Hypoglycemia : < 55.
---------------------------	----	--

DR.HARI SHANKAR, MBBS MD
 (Reg No - TCMC:62092)
HEAD - Biochemistry & Immunology



[View Details](#) [View Report](#)

PERFORMED AT :

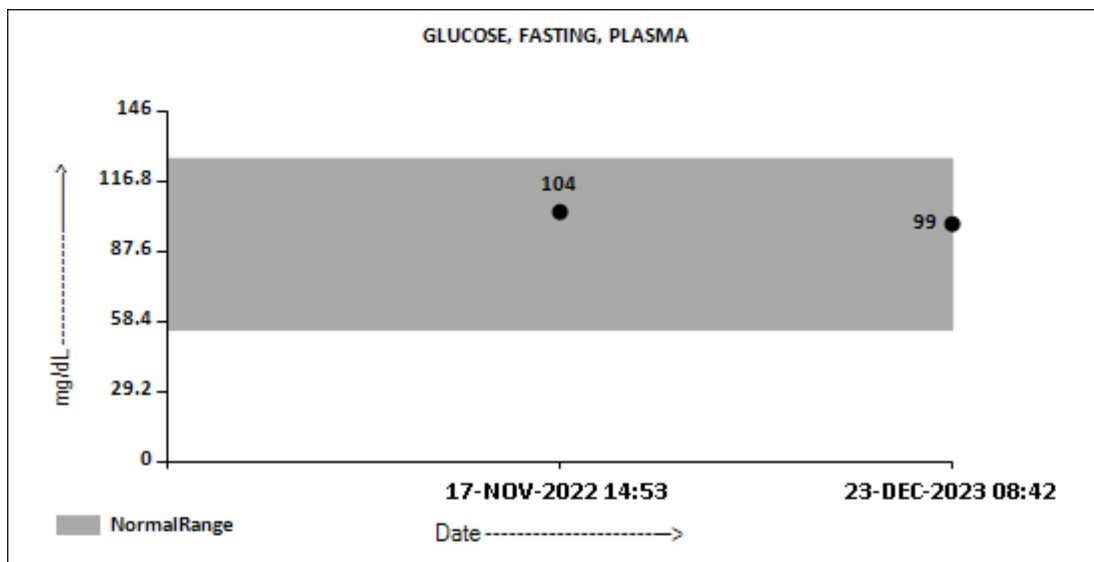
DDRC AGILUS PATHLABS LIMITED
 ASTER SQUARE BUILDING, ULLOOR,
 MEDICAL COLLEGE P.O
 TRIVANDRUM, 695011
 KERALA, INDIA
 Tel : 93334 93334, Fax : CIN - U85190MH2006PTC161480
 Email : customercare.ddrc@agilus.in



Patient Ref. No. 66600007221128

PATIENT NAME : MRS. AKHILA S	REF. DOCTOR : SELF	
CODE/NAME & ADDRESS : CA00010147 - MEDIWHEEL ARCOFEMI HEALTHCARE LIMITED F701A, LADO SARAI, NEW DELHI,SOUTH DELHI, DELHI, SOUTH DELHI 110030 8800465156	ACCESSION NO : 4182WL009103 PATIENT ID : AKHIF1711934182 CLIENT PATIENT ID: ABHA NO :	AGE/SEX : 31 Years Female DRAWN : RECEIVED : 23/12/2023 06:57:58 REPORTED : 23/12/2023 15:52:38

Test Report Status	Preliminary	Results	Units
--------------------	-------------	---------	-------




LIVER FUNCTION TEST WITH GGT

BILIRUBIN, TOTAL	0.78	General Range : < 1.1	mg/dL
BILIRUBIN, DIRECT	0.32	General Range : < 0.3	mg/dL
BILIRUBIN, INDIRECT	0.46	General Range : <0.85	mg/dL
TOTAL PROTEIN	7.0	Ambulatory : 6.4 - 8.3 Recumbant : 6 - 7.8	g/dL
ALBUMIN	4.2	20-60yrs : 3.5 - 5.2	g/dL
GLOBULIN	2.8	General Range : 2 - 3.5 Premature Neonates : 0.29 - 1.04	g/dL
ALBUMIN/GLOBULIN RATIO	1.5	General Range : 1.1 - 2.5	RATIO
ASPARTATE AMINOTRANSFERASE (AST/SGOT)	12	Adults : < 33	U/L
ALANINE AMINOTRANSFERASE (ALT/SGPT)	17	Adults : < 34	U/L
ALKALINE PHOSPHATASE	51	Adult (<60yrs) : 35 - 105	U/L
GAMMA GLUTAMYL TRANSFERASE (GGT)	13	Adult (female) : < 40	U/L

TOTAL PROTEIN, SERUM

DR.HARI SHANKAR, MBBS MD
(Reg No - TCMC:62092)
HEAD - Biochemistry & Immunology



PERFORMED AT :

DDRC AGILUS PATHLABS LIMITED
ASTER SQUARE BUILDING, ULLOOR,
MEDICAL COLLEGE P.O
TRIVANDRUM, 695011
KERALA, INDIA
Tel : 93334 93334, Fax : CIN - U85190MH2006PTC161480
Email : customercare.ddrc@agilus.in



PATIENT NAME : MRS. AKHILA S **REF. DOCTOR : SELF**

CODE/NAME & ADDRESS : CA00010147 - MEDIWHEEL ARCOFEMI HEALTHCARE LIMITED F701A, LADO SARAI, NEW DELHI,SOUTH DELHI, DELHI, SOUTH DELHI 110030 8800465156	ACCESSION NO : 4182WL009103	AGE/SEX : 31 Years Female
	PATIENT ID : AKHIF1711934182	DRAWN :
	CLIENT PATIENT ID:	RECEIVED : 23/12/2023 06:57:58
	ABHA NO :	REPORTED : 23/12/2023 15:52:38

Test Report Status	Preliminary	Results	Units
TOTAL PROTEIN		7.0	Ambulatory : 6.4 - 8.3 Recumbant : 6 - 7.8 g/dL
URIC ACID, SERUM			
URIC ACID		5.1	Adults : 2.4-5.7 mg/dL


BIOCHEMISTRY - LIPID

MEDIWHEEL HEALTH CHECKUP BELOW 40(F)2DECHO

LIPID PROFILE, SERUM

CHOLESTEROL	167	Desirable : < 200 Borderline : 200-239 High : >or= 240	mg/dL
TRIGLYCERIDES	101	Normal : < 150 High : 150-199 Hypertriglyceridemia : 200-499 Very High : > 499	mg/dL
HDL CHOLESTEROL	44	General range : 40-60	mg/dL
LDL CHOLESTEROL, DIRECT	119	Optimum : < 100 Above Optimum : 100-129 Borderline High : 130-159 High : 160-189 Very High : >or= 190	mg/dL
NON HDL CHOLESTEROL	123	Desirable : < 130 Above Desirable : 130 -159 Borderline High : 160 - 189 High : 190 - 219 Very high : > / = 220	mg/dL
VERY LOW DENSITY LIPOPROTEIN CHOL/HDL RATIO	20.2	</= 30.0	mg/dL
LDL/HDL RATIO	3.8	Low Risk : 3.3 - 4.4 Average Risk : 4.5 - 7.0 Moderate Risk : 7.1 - 11.0 High Risk : > 11.0	
	2.7	Desirable/Low Risk - 0.5-3	

DR.HARI SHANKAR, MBBS MD
(Reg No - TCMC:62092)
HEAD - Biochemistry & Immunology



PERFORMED AT :

DDRC AGILUS PATHLABS LIMITED
ASTER SQUARE BUILDING, ULLOOR,
MEDICAL COLLEGE P.O
TRIVANDRUM, 695011
KERALA, INDIA
Tel : 93334 93334, Fax : CIN - U85190MH2006PTC161480
Email : customercare.ddrc@agilus.in



PATIENT NAME : MRS. AKHILA S		REF. DOCTOR : SELF	
CODE/NAME & ADDRESS : CA00010147 - MEDIWHEEL ARCOFEMI HEALTHCARE LIMITED F701A, LADO SARAI, NEW DELHI, SOUTH DELHI, DELHI, SOUTH DELHI 110030 8800465156		ACCESSION NO : 4182WL009103	AGE/SEX : 31 Years Female
		PATIENT ID : AKHIF1711934182	DRAWN :
		CLIENT PATIENT ID:	RECEIVED : 23/12/2023 06:57:58
		ABHA NO :	REPORTED : 23/12/2023 15:52:38

Test Report Status	Preliminary	Results	Units
--------------------	-------------	---------	-------

Borderline/Moderate Risk- 3.1-6
High Risk- >6.0

SPECIALISED CHEMISTRY - HORMONE

MEDIWHEEL HEALTH CHECKUP BELOW 40(F)2DECHO

THYROID PANEL, SERUM

T3	131.00	Non-Pregnant : 80-200	ng/dL
		Pregnant Trimester-wise	
		1st : 81-190	
		2nd : 100-260	
		3rd : 100-260	
T4	8.86	Adults : 4.5-12.1	µg/dl
TSH 3RD GENERATION	3.710	Non-Pregnant : 0.4-4.2	µIU/mL
		Pregnant Trimester-wise :	
		1st : 0.1 - 2.5	
		2nd : 0.2 - 3	
		3rd : 0.3 - 3	

CLINICAL PATH - URINALYSIS

MEDIWHEEL HEALTH CHECKUP BELOW 40(F)2DECHO


PHYSICAL EXAMINATION, URINE

COLOR	YELLOW
APPEARANCE	CLEAR

CHEMICAL EXAMINATION, URINE

DR. HARI SHANKAR, MBBS MD
(Reg No - TCMC:62092)
HEAD - Biochemistry & Immunology

DR. VAISHALI RAJAN, MBBS DCP
(Pathology)
(Reg No - TCC 27150)
HOD - HAEMATOLOGY



[View Details](#) [View Report](#)

PERFORMED AT :
DDRC AGILUS PATHLABS LIMITED
ASTER SQUARE BUILDING, ULLOOR,
MEDICAL COLLEGE P.O
TRIVANDRUM, 695011
KERALA, INDIA
Tel : 93334 93334, Fax : CIN - U85190MH2006PTC161480
Email : customercare.ddrc@agilus.in



Patient Ref. No. 66600007221128

PATIENT NAME : MRS. AKHILA S		REF. DOCTOR : SELF	
CODE/NAME & ADDRESS : CA00010147 - MEDIWHEEL ARCOFEMI HEALTHCARE LIMITED F701A, LADO SARAI, NEW DELHI,SOUTH DELHI, DELHI, SOUTH DELHI 110030 8800465156		ACCESSION NO : 4182WL009103	AGE/SEX : 31 Years Female
		PATIENT ID : AKHIF1711934182	DRAWN :
		CLIENT PATIENT ID:	RECEIVED : 23/12/2023 06:57:58
		ABHA NO :	REPORTED : 23/12/2023 15:52:38

Test Report Status	Preliminary	Results	Units
PH		5.0	4.7 - 7.5
SPECIFIC GRAVITY		1.023	1.003 - 1.035
PROTEIN		NEGATIVE	NOT DETECTED
GLUCOSE		NEGATIVE	NOT DETECTED
KETONES		NEGATIVE	NOT DETECTED
BLOOD		NOT DETECTED	NOT DETECTED
BILIRUBIN		NEGATIVE	NOT DETECTED
UROBILINOGEN		NORMAL	NORMAL
METHOD : DIPSTICK			
NITRITE		NEGATIVE	NOT DETECTED


MICROSCOPIC EXAMINATION, URINE

RED BLOOD CELLS	NOT DETECTED	NOT DETECTED	/HPF
WBC	3-5	0-5	/HPF
EPITHELIAL CELLS	0-1	0-5	/HPF
CASTS	NEGATIVE		
CRYSTALS	NEGATIVE		
REMARKS	NIL		

METHOD : AUTOMATED ANALYSER, MICROSCOPY

CLINICAL PATH - STOOL ANALYSIS

MEDIWHEEL HEALTH CHECKUP BELOW 40(F)2DECR06	RESULT PENDING
PHYSICAL EXAMINATION,STOOL	RESULT PENDING
CHEMICAL EXAMINATION,STOOL	RESULT PENDING
MICROSCOPIC EXAMINATION,STOOL	RESULT PENDING



View Details

View Report

PERFORMED AT :

DDRC AGILUS PATHLABS LIMITED
 ASTER SQUARE BUILDING, ULLLOOR,
 MEDICAL COLLEGE P.O
 TRIVANDRUM, 695011
 KERALA, INDIA
 Tel : 93334 93334, Fax : CIN - U85190MH2006PTC161480
 Email : customercare.ddrc@agilus.in



Patient Ref. No. 66600007221128