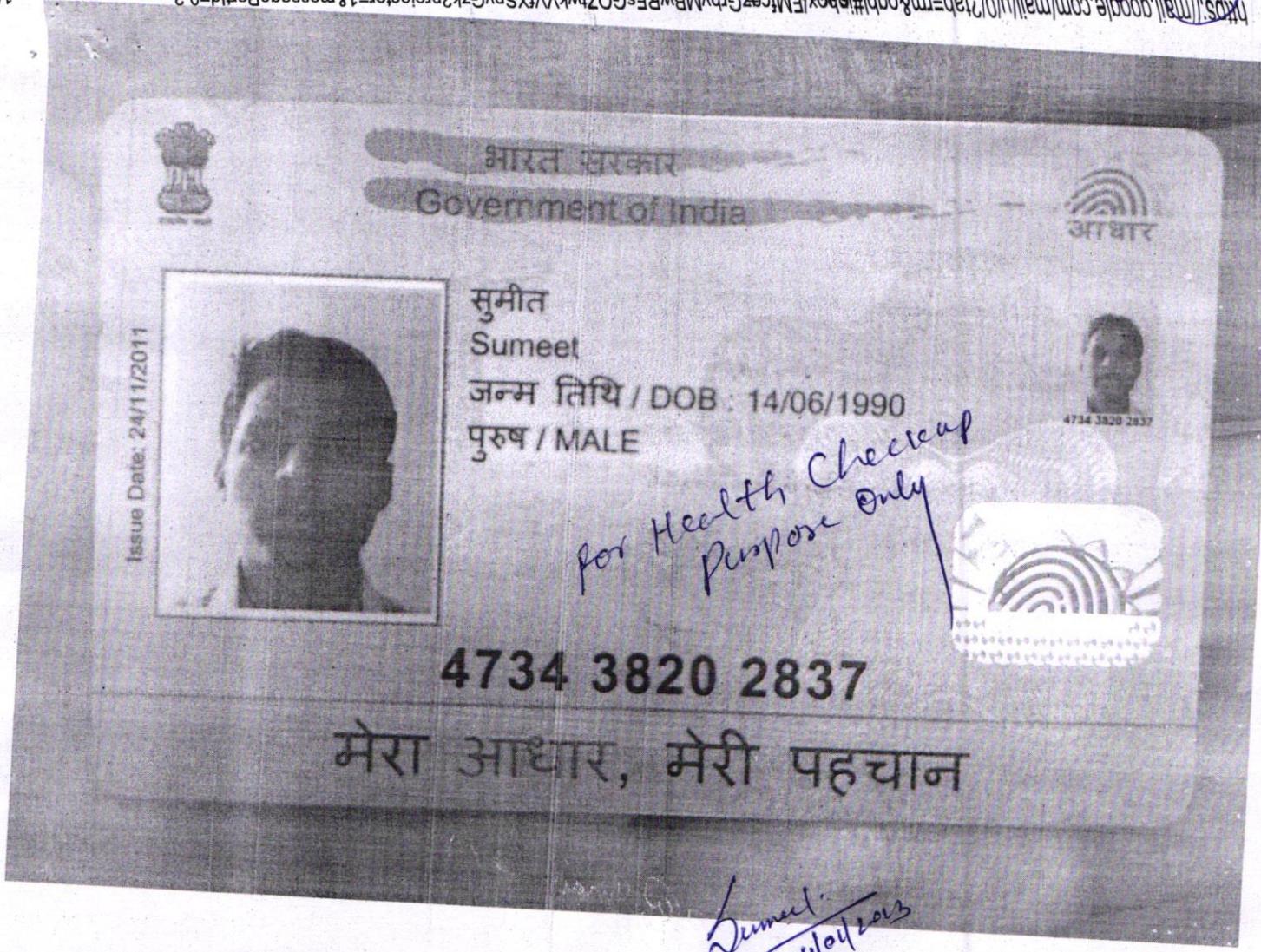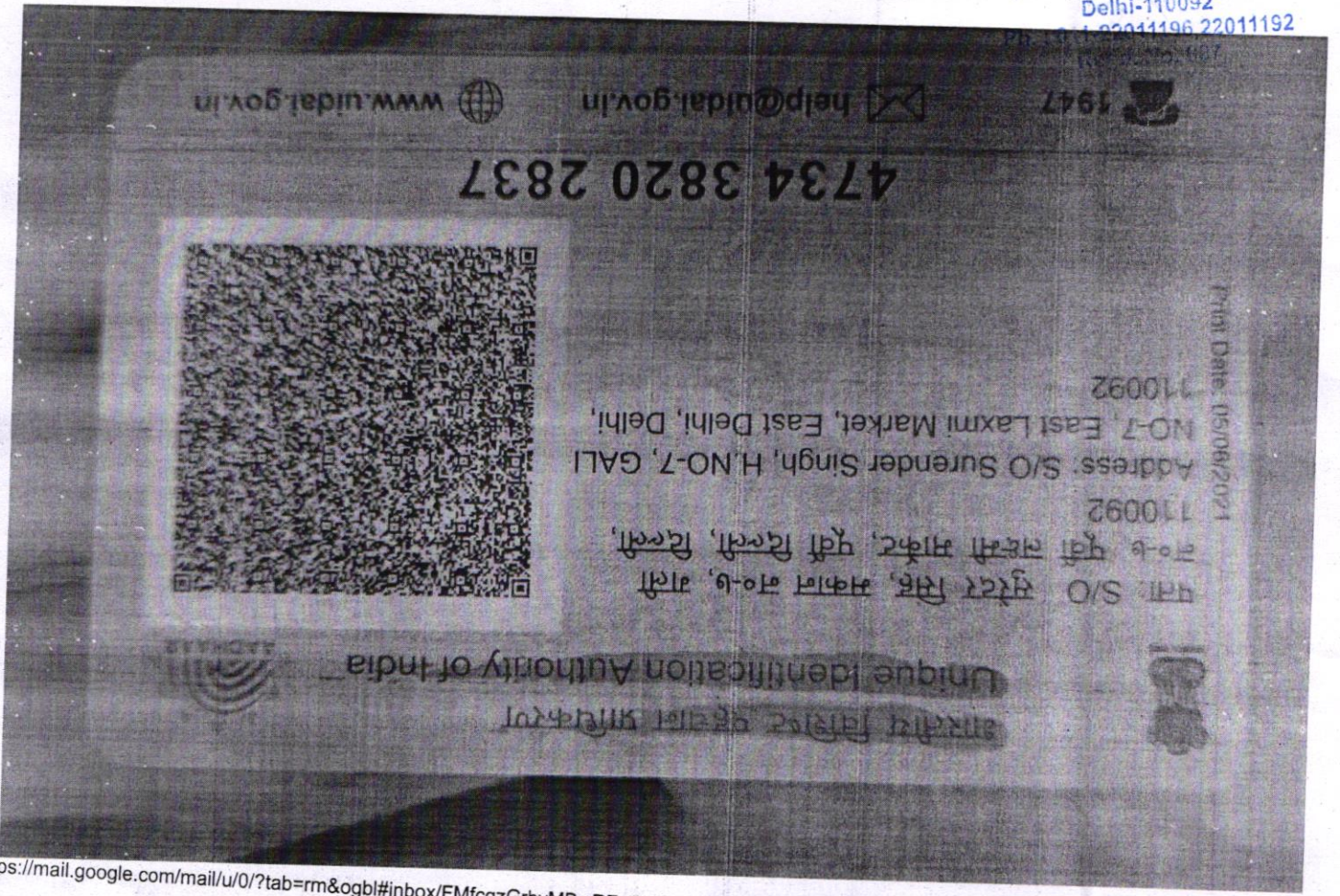


32



Malik Radix Health Care Pvt. Ltd.
 C-217, C-218, Nirman Vihar
 Delhi-110092
 011-22041196 22011192





MALIK RADIX HEALTH CARE

(UNIT OF MALIK RADIX HEALTHCARE PVT. LTD.)
C-217, 218, Nirman Vihar, Vikas Marg, New Delhi - 110092
Tel.: 011-22011192, 22011196 • Fax : 22011208
E-mail : radixhealthcare@yahoo.co.in
Website : www.radixhealthcare.org



Safety at WEI now accredited by NABH

Name - Sameet
Age - 32yrs/M

14/01/23

Burning Eyes

Vision 6/6
6/6

CS

No
No

Nothing
K 20yo

Colour: WNL

As: (N)

End: WNL

Adx

9 Sybsoft (Hyper) /
Linnor Pres

o o o (28)

Dr. Nidhi Gupta
MBBS, MS, DNB
Casualty Ophthalmologist
Malik Radix Healthcare Pvt. Ltd.
DMC No. 1111

MRHC / GEN / FR / 15

Facilities Available :

- ★ Multispeciality Hospital
- ★ 24 Hours Emergency
- ★ X-Ray/ECG/ Ultrasound
- ★ Fully Equipped Operation Theatre
- ★ Fully Functional Lab
- ★ Casualty/ICU
- ★ Nursery
- ★ Labour Room
- ★ All Speciality OPD
- ★ Laparoscopic Surgery
- ★ ECHO
- ★ Plastic Surgery

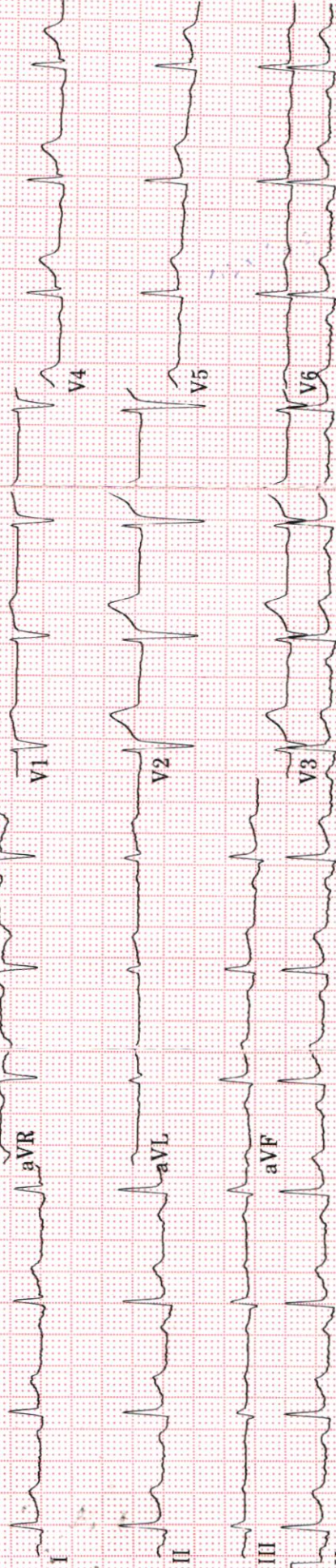
Home Collection Facility Available Contact : 9999254739

MAC600 1.02

ID: 9716979561

4-Jan-2023 10:09:24

Sumeet



ID: 9716979561

32years Male

Vent. rate 83 bpm
 QRS duration 88 ms
 QT/QTc 342/401 ms
 PR interval 162 ms
 P duration 94 ms
 RR interval 722 ms
 P-R-T axes 54 47 46

Auto gain applied
 0.16-20Hz 25.0 mm/s 10.0][5.0 mm/mV

83 bpm

50Hz

4 by 2.5s + 1 rhythm ld

II

MAC600 1.02

12SL™ v239

Sumel
14/1/2023

Malik Radix HealthCare.

ELECTROCARDIOGRAM

Name: MR. SUMEET Age & Sex: 32YR/MALE Ref by: MEDIWHEEL Date: 14/01/2023

EKG FINDINGS:

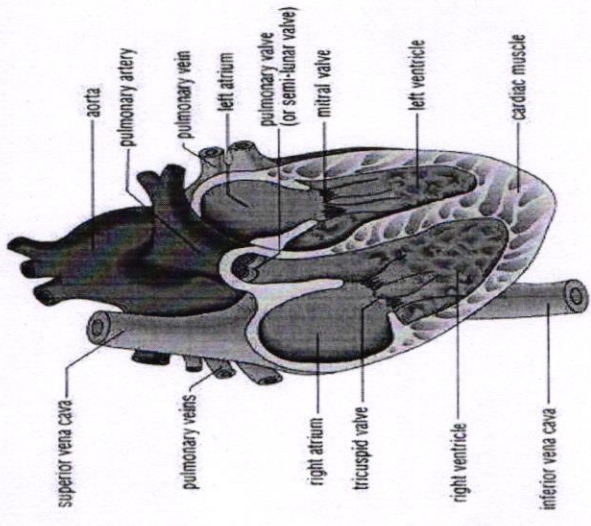
Rate 83bpm Rhythm Sinus Mechanism Normal

Axis Normal P Wave Normal PR Interval 0.16/Sec

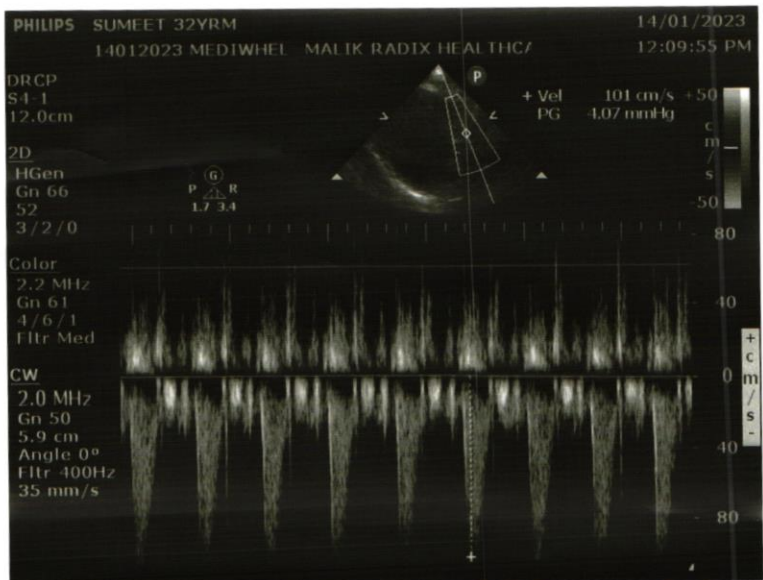
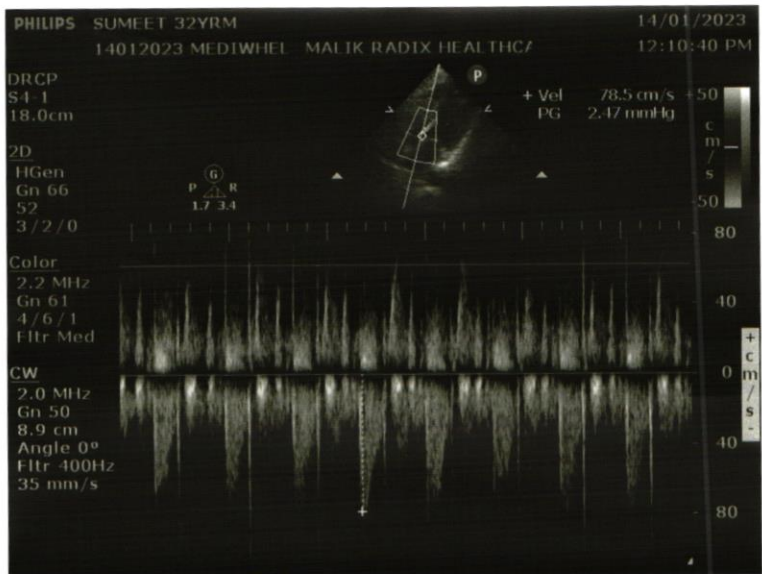
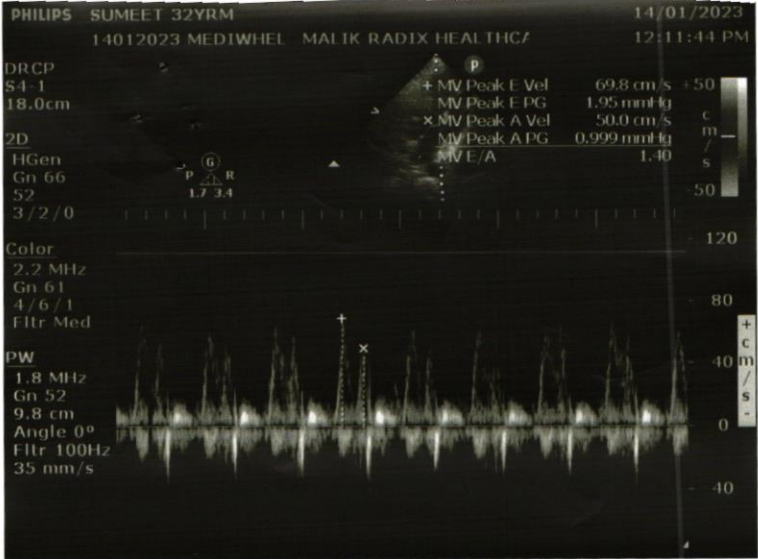
QRS Complex Normal QT Interval Normal Q Wave Normal

ST Segment Normal T Wave Normal

Conclusion Sinus Rhythm, Normal Axis, TWNL.



Doctors Signature Dr. SHEIKH MAZIR AHMED
M.D. "Physician"
PGDCC
DMC-48499



Echocardiogram Report

Patient Name	MR. SUMEET
Date of Test	14/01/2023
Age	32 YRS/ MALE
Ref. by	MEDI WHEEL

Dimensions	Result	Normal Range
AO (ed)	2.6 cm	(2.1 -3.7cm)
LA (es)	2.7 cm	(2.1 - 4.0cm)
RVID (ed)	2.0 cm	(1.1-3.0cm)
LVID (ed)	4.0 cm	(3.6 – 5.5 cm)
LVID (es)	2.7 cm	(2.3-3.9cm)
IVS (ed)	1.1 cm	(0.6 – 1-2 cm)
LVPW (ed)	1.0 cm	(0.6 – 1-2 cm)
EF	62 %	
FS	32 %	(28 % - 42 %)

Impression

NO REGIONAL WALL MOTION ABNORMALITY SEEN.

LVEF= 62%

NORMAL CHAMBERS DIMENSION.

NORMAL MIP.

NORMAL COLOR FLOW.

NO INTRA CARDIAC CLOT/MASS/ VEGETATION/PERICARDIAL EFFUSION SEEN.

Dr. Nishant Tyagi

(M.D. Medicine. DNB Cardiology)

(Senior Consultant, Cardiology)

Dr. Sheikh Nazir Ahmed

M.D. "Physician" PGDCC

(Consultant Non – Invasive Cardiologist)

Facilities Available :

MRHC / GEN / FR / 15

- ★ Multispeciality Hospital ★ 24 Hours Emergency ★ X-Ray/ECG/ Ultrasound ★ Dental
- ★ Fully Equipped Operation Theatre ★ Fully Functional Lab ★ Casualty/ICU ★ Nursery
- ★ Labour Room ★ All Speciality OPD ★ Laparoscopic Surgery ★ ECHO ★ Plastic Surgery

Home Collection Facility Available Contact : 9999254739



LAB REPORT

Reg. Date	14/01/2023	Patient Id	2301140001	DOB.	14/06/1990
Name	MR. SUMEET			Perm. ID	
Age	32 Yrs. 7 Mn. 1 Day	Gender	M	Reported	14/01/2023 16:53:29
Ref. By	MEDIWHEEL	Panel	MEDIWHEEL		

Test Name	Result	Units	Ref. Range
CHEMICAL EXAMINATION			
ALBUMIN	Nil		
SUGAR	Nil		
MICROSCOPIC EXAMINATION			
PUS CELLS	1-2	/HPF	
RBC'S	Nil	/HPF	
CASTS	Nil		
CRYSTALS	NIL		
EPITHELIAL CELLS	1-2	/HPF	
BACTERIA	Nil		
OTHERS	Nil		
Stool Examination Report			
PHYSICAL EXAMINATION			
COLOUR/APPEARANCE	YELLOWISH		
CONSISTENCY	SEMILOOSE		
PUS	NIL		
MUCUS	ABSENT		
BLOOD	ABSENT		
MICROSCOPIC EXAMINATION			
PUS CELLS	2-3	/HPF	
RBC'S	NIL	/HPF	
OVA	NIL		
CYSTS	NIL		
OTHERS	NIL		
BLOOD GROUP ABO	" O "		
RH TYPING	Positive		

Checked by : _____
Page 2 Contd...3

If test results are alarming or unexpected, patient is advised to contact the laboratory immediately for possible remedial action.

Facilities Available

- Multispeciality Hospital - 24 Hours Emergency - X-Ray/ ECG/ Ultrasound/ CT Scan - Dental - Fully Equiped Operation Theatre
- Fully Functional Lab - Casualty/ ICU-Nursery - Labour Room - All Speciality OPD - Laproscopic Surgery - ECHO - Plastic Surgery

**LAB REPORT**

Reg. Date	14/01/2023	Patient Id	2301140001	DOB.	14/06/1990
Name	MR. SUMEET			Perm. ID	
Age	32 Yrs. 7 Mn. 1 Day	Gender	M	Reported	14/01/2023 16:53:29
Ref. By	MEDIWHEEL	Panel	MEDIWHEEL		

Test Name	Result	Units	Ref. Range
BLOOD SUGAR FASTING	207.84	mg/dl	70 - 100
BLOOD SUGAR PP	242.97	mg/dl	90 - 140
HBA1C	9.70	%	

Interpretation

Non Diabetic	: 4-6%
Good Diabetic Control	: 6-8%
Fair Control	: 8-10%
Poor Control	: >10%

The Glycosylated haemoglobin assay has been validated as a reliable indicator Of mean blood glucose levels for a period of 8-12 week period. ADA recommended the testing twice a year in patients with stable blood glucose and quarterly. If treatment change, or if blood glucose levels are unstable.

TO BE CORRELATED CLINICALLY.

THYROID PROFILE

Free T3 ELFA	1.62	ng/ml	02 - 04
Free T4 ELFA	1.12	ug/dl	0.8 - 2.7
TSH Serum/ELFA	2.120	uIU/ml	0.25 - 5.50 uIU/ml

Interpretation**Clinical Use**

Checked by : _____
Page 3 Contd...4

If test results are alarming or unexpected, patient is advised to contact the laboratory immediately for possible remedial action.

Facilities Available

- Multispeciality Hospital - 24 Hours Emergency - X-Ray/ ECG/ Ultrasound/ CT Scan - Dental - Fully Equiped Operation Theatre
- Fully Functional Lab - Casualty/ ICU-Nursery - Labour Room - All Speciality OPD - Laproscopic Surgery - ECHO - Plastic Surgery

**LAB REPORT**

Reg. Date	14/01/2023	Patient Id	2301140001	DOB.	14/06/1990
Name	MR. SUMEET			Perm. ID	
Age	32 Yrs. 7 Mn. 1 Day	Gender	M	Reported	14/01/2023 16:53:29
Ref. By	MEDIWHEEL	Panel	MEDIWHEEL		

Test Name	Result	Units	Ref. Range
SGOT / AST	67.42	IU/L	0 - 35
SGPT / ALT	49.31	IU/L	0 - 35
ALKALINE PHOSPHATASE	83.30	U/L	64 - 306
TOTAL PROTEIN	7.20	gm/dl	6.0 - 8.3
ALBUMIN	4.79	gm/dl	3.2 - 5.0
GLOBULIN	2.41	gm/dl	2.5 - 5.6
A/G RATIO	1.99		0.9 - 2.0
GAMMA GT	28.56	IU/L	0.0 - 45.0

Dr. REEMA DAHIYA
M.B.B.S, MD (Path.)
Checked by
Malik Radix Healthcare Pvt. Ltd.
C-217, C-218, Nirman Vihar,
Delhi-92
Page 5 of 5

DR. MEENU AGGARWAL
M.B.B.S, MD (Path.)

If test results are alarming or unexpected, patient is advised to contact the laboratory immediately for possible remedial action.

Facilities Available

- Multispeciality Hospital - 24 Hours Emergency - X-Ray/ ECG/ Ultrasound/ CT Scan - Dental - Fully Equiped Operation Theatre
- Fully Functional Lab - Casualty/ ICU-Nursery - Labour Room - All Speciality OPD - Laproscopic Surgery - ECHO - Plastic Surgery

R

SIMEET 32 Y/M F1178852 CHEST PA 11 Jun 2024 10:05



MALIK RADIX HEALTH CARE

(UNIT OF MALIK RADIX HEALTHCARE PVT. LTD.)

C-217, 218, Nirman Vihar, Vikas Marg, New Delhi - 110092


Tel.: 011-22011192, 22011196, 47060150 • Fax : 22011208

E-mail : radixhealthcare@yahoo.co.in

Website : www.radixhealthcare.org



UHID	PT178857	LAB No.	XRY2208622
Name	Mr. SUMEET	Regn. No.	GEN2235375
Age / Sex	32 Yrs / M	Receiving Dt/Time	14/Jan/2023 10:05
		Reporting Dt/Time	14/Jan/2023 10:28 AM



XRAY

CHEST (PA)
Both lung fields are normal.

Cp angles are clear.

Hila are normal...

Heart size appears within normal limits.

Soft tissue shadows and bony thorax are normal.

Advised....please correlate clinically.

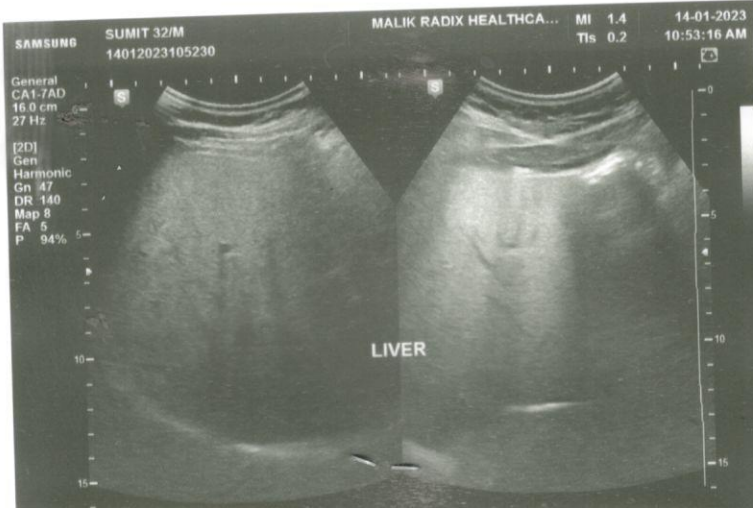
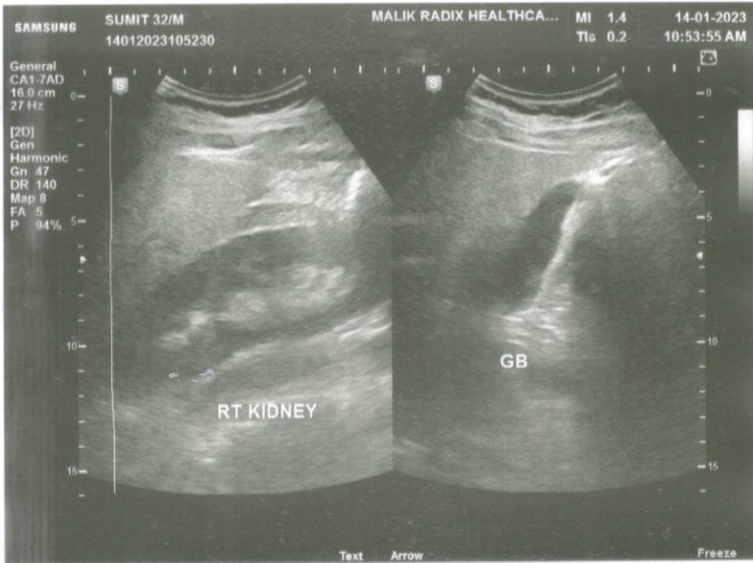
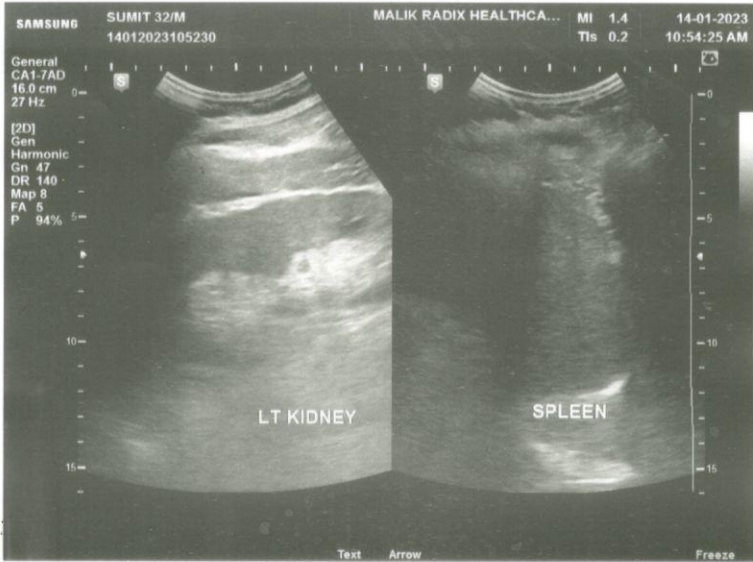
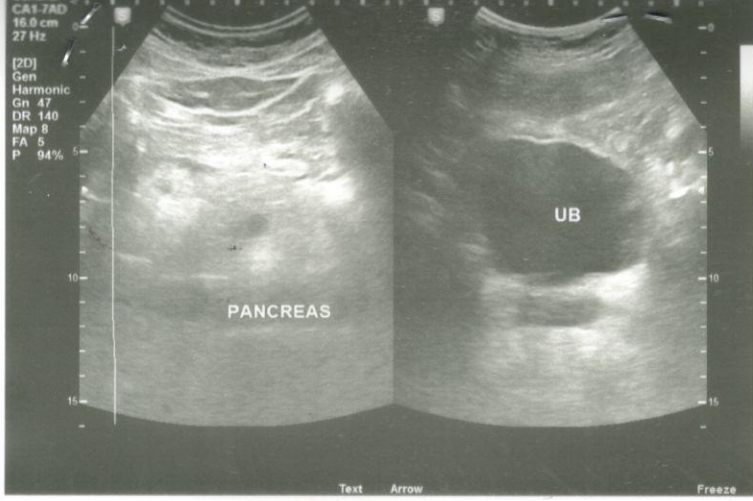
***** END OF REPORT *****

DR. K.K. SINHA
M.B.B.S, D.M.R.D.
SENIOR CONSULTANT
Reg. No. 25437 (DMC)

DR. RAJESH MALHOTRA
MBBS, MD (RADIOLOGY)
CONSULTANT RADIOLOGY
Reg.No.DMC9299

DR. T. K VOHRA
MD (RADIODIAGNOSIS)
SENIOR CONSULTANT
Reg. No. 3272 (DMC)

DR. MUKESH KOSHAL
MBBS, MD (RADIOLOGY)
CONSULTANT RADIOLOGY
Reg.No.DMC10407



NAME	MR SUMEET	AGE	32/M
REFD. BY.	HEALTH CHECK UP	DATE	14.01.23

Ultrasound Examination of Whole Abdomen:

Liver: Liver shows grade 1 fatty change . No focal SOL is seen in liver. IHBR & portal radicles are normal.

Gallbladder: Gallbladder shows normal anechoic pattern. No evidence of cholecystitis or cholelithiasis seen. Common bile duct is normal in course & caliber.

Pancreas: Pancreas shows normal size & echotexture.

Spleen: Spleen shows normal size, outline & echotexture.

Kidneys: Kidneys show normal size, shape, position & echotexture. No calculus, hydronephrosis or SOL is seen in kidneys. Cortico- medullary differentiation and cortical thickness is normal on both sides.

No supra- renal mass seen.

Great abdominal vessels are normal.

Domes of diaphragm are seen to move normally & synchronously in respiration. No infra- or supradiaphragmatic collection seen.

No ascites or pericardial effusion seen.

No para aortic lymph nodes seen.

Urinary bladder: Urinary bladder shows normal anechoic pattern. No calculus, SOL or diverticulum seen.

Prostate: Prostate and seminal vesicles are sonographically normal.

IMP—GRADE 1 FATTY LIVER

Regards.


Dr Mukesh Koshal MD (Rad- diag)
Regn. No. DMC 10407