

Mediwheel - Bob

37/m

Amish

This is for health checkup
purpose only.

3/12/1984

भारत सरकार
GOVERNMENT OF INDIA

अमिश सतिश दोलास
Amish Satish Dolas

जन्म वर्ष / Year of Birth : 1984
पुरुष / Male

7192 9119 5552

आधार - सामान्य माणवाचा अधिकार

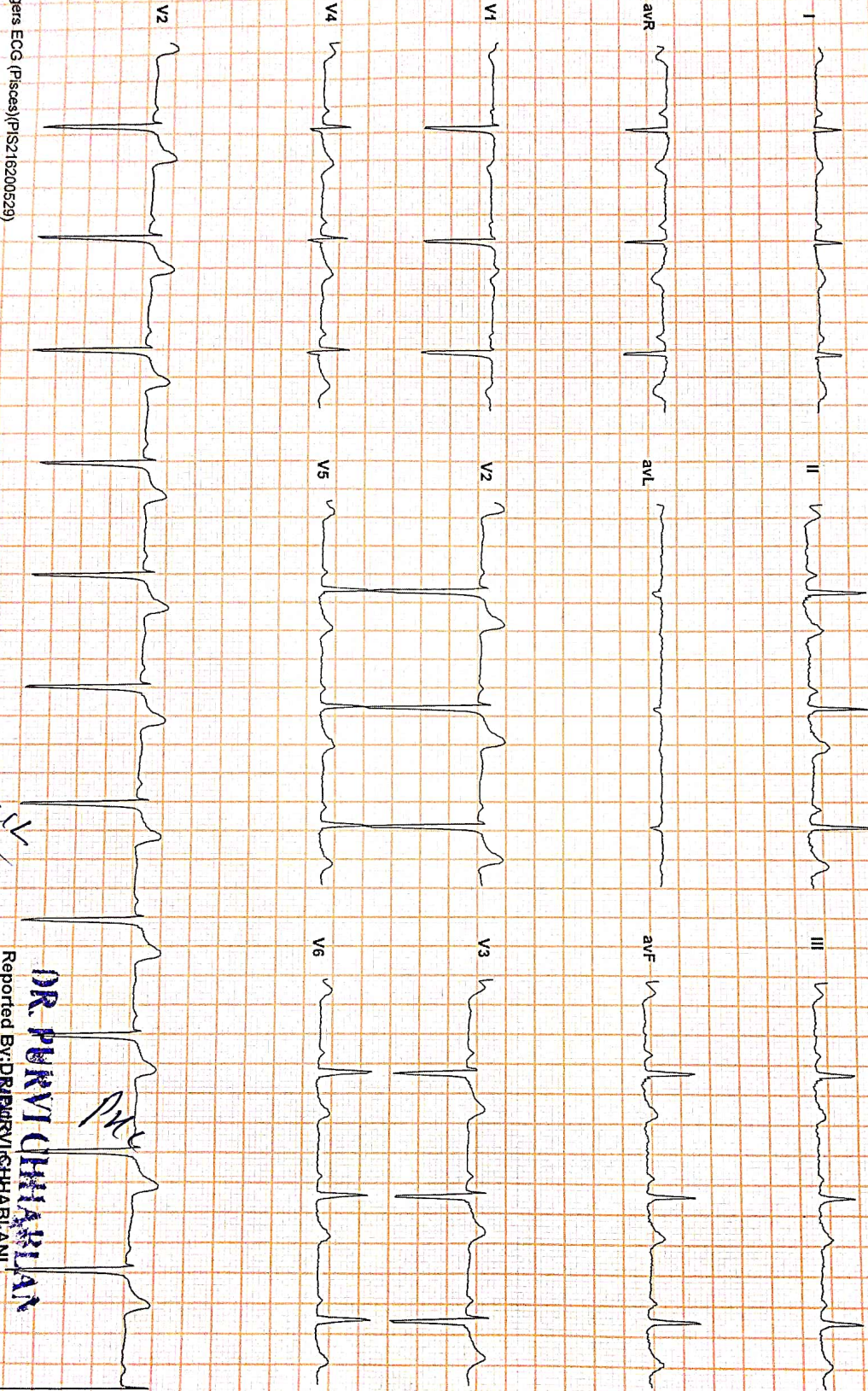
DR. HARI CHNABLANI
M.D. (GEN. (RESP. MEDICINE) PGDIPM, FRCMLO
LOW INTENSIVE CARE
MMC REG. NO. - 91792

DR. PLUS HEALTHCARE CENTRE
KATHANI HEIGHTS, B-WING
42, MUMBAI CENTRAL (E. 100)

DR PLUS HEALTHCARE CENTRE - MUMBAI CENTRAL

ECG

1569 / AMRISH S DOLAS / 37 Yrs / M
Heart Rate : 72 bpm / Tested On : 20-Mar-22 11:10:06 / HF 0.05 Hz - LF 100 Hz / Notch 50 Hz / Sn 1.00 Cm/mV / Sw 25 mm/s
/ Reid By: DR. HARI CHHABLANI



Allergens ECG (Pscas)(PIS216200529)

Handwritten mark

Handwritten mark

DR. PARI CHHABLANI

Reported By: DR. PARI CHHABLANI

Consultant Physician And Intensivist

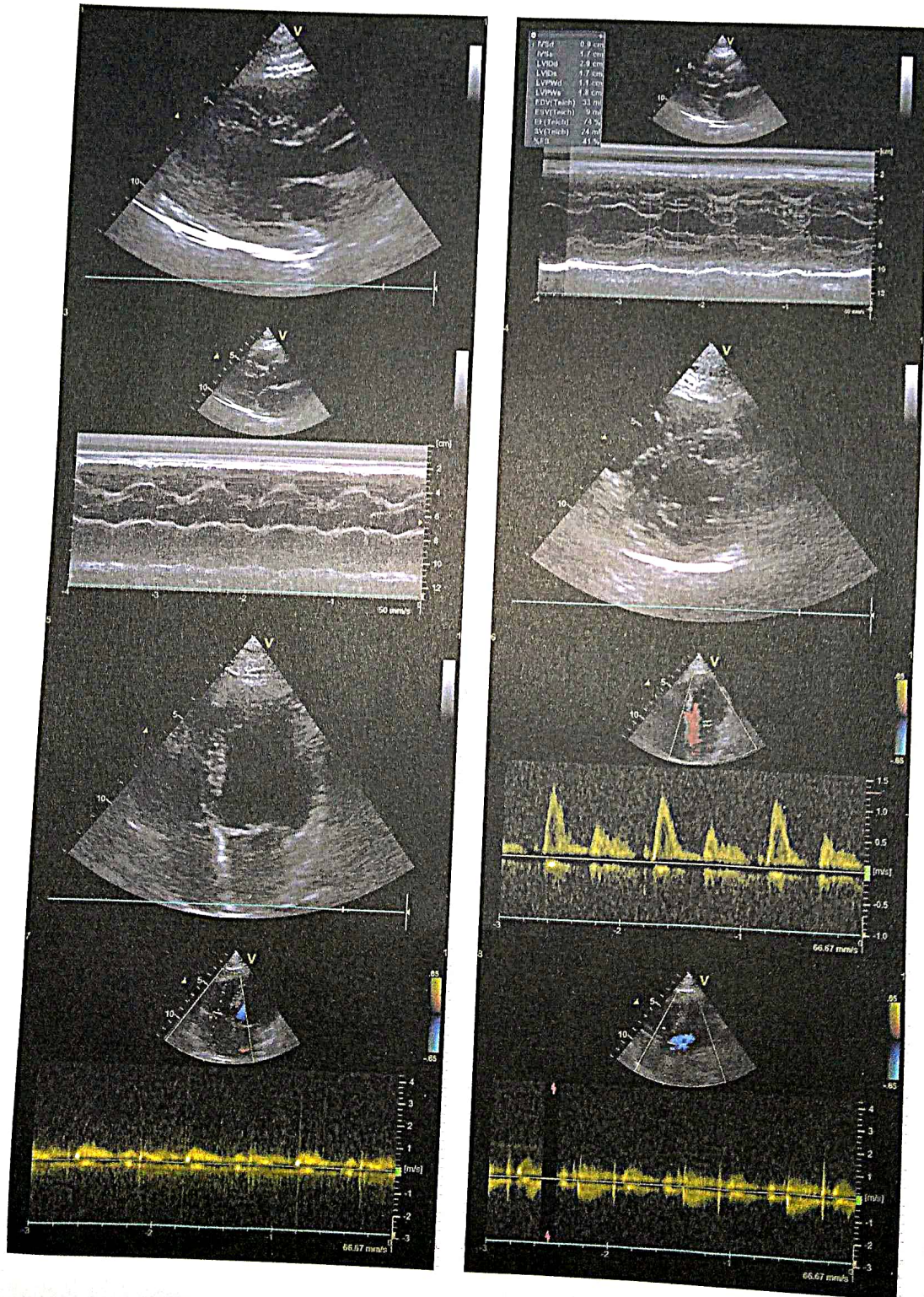
Reg No 77692

Name **AMRISH S DOLAS**

Sex **Male**

Age **37**

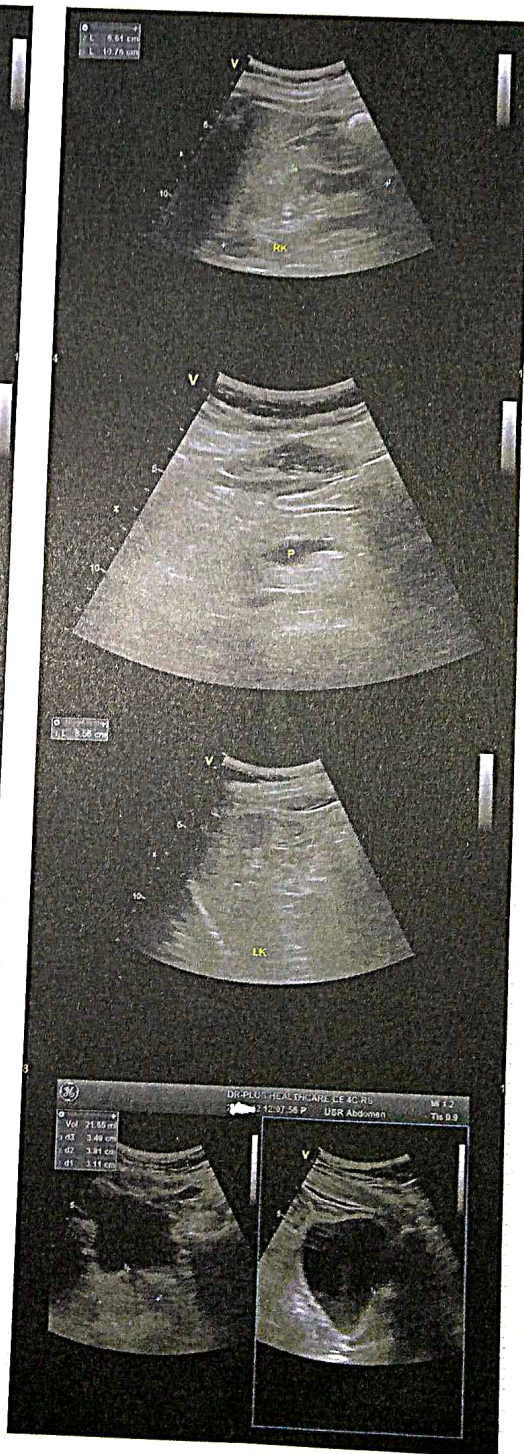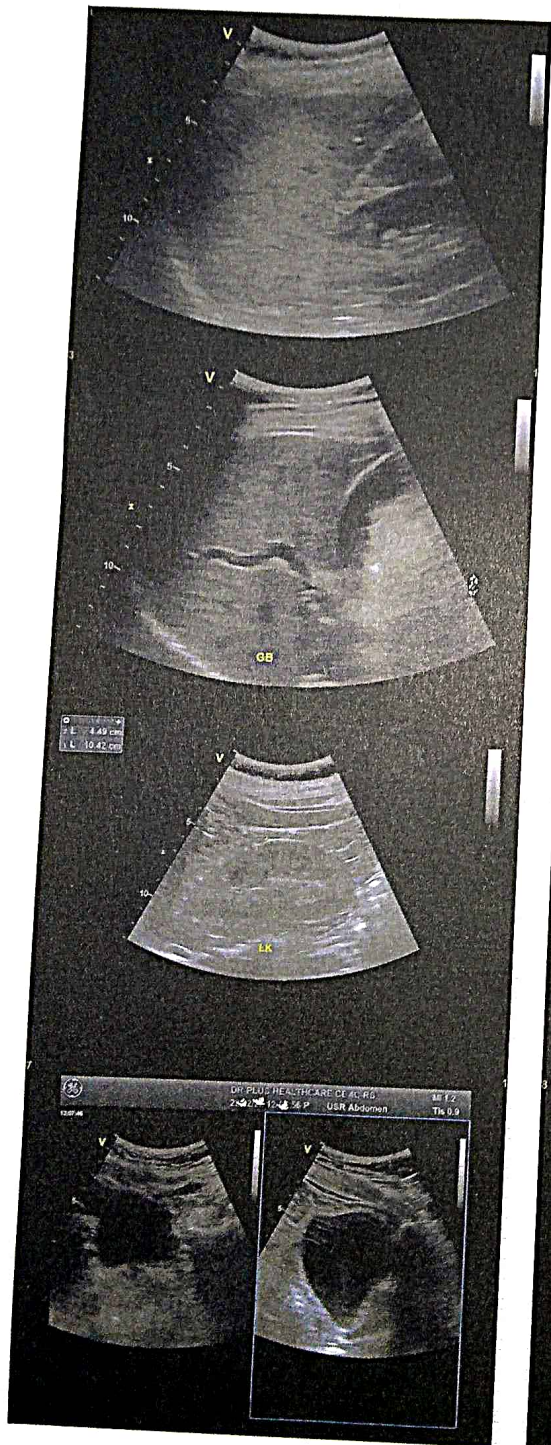Date **20/03/2022**



Name **AMRISH DOLAS**

Sex **Male**

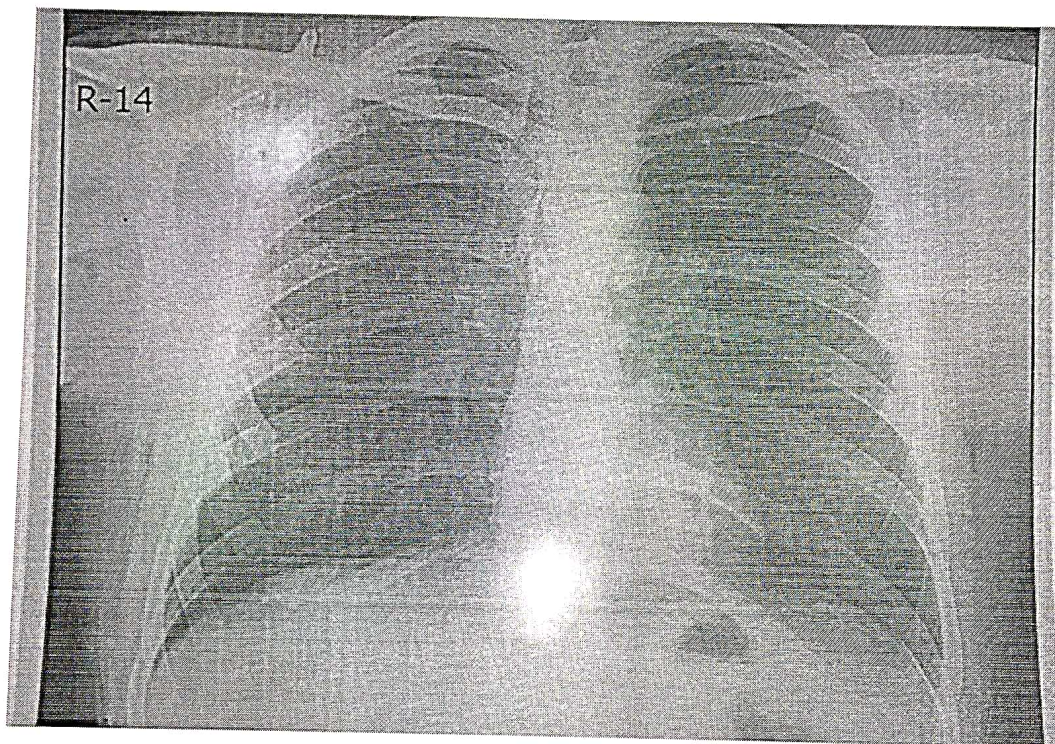
Age **37**



NAME : AMRISH DOLAS

37/M

20/03/2022





Dr-Plus Healthcare Centre

NATHANI HEIGHTS, B-Wing, Shop No. 42, Ground Floor, Opp. Mumbai Central Station (East), Mumbai - 400 008.

Patient's Name : AMRISH DOLAS

Report : 20/03/2022


Referred By Dr. : SELF

Age : 37 Years

Sex : MALE

Chest X-ray PA

- No active pulmonary lesion seen.
- Trachea and mediastinum are in midline .
- Cardiac size and configuration are within normal limits .
- Pleural cavities are clear .
- Domes of diaphragm are smooth in outline.
- Bony thorax is normal .


Radiologist

DR. A. J. MAZUMDAR

MD. DMRE, MDRD

**'DR. PLUS HEALTHCARE CENTRE'
NATHANI HEIGHTS', B-WING,
42, MUMBAI CENTRAL (EAST)**



NAME : AMRISH DOLAS

37/M

DATE:20/03/2022

REF BY : DR. HARI CHHABLANI

2D-ECHO. AND COLOR DOPPLER REPORT

- NORMAL CARDIAC VALVES WITH TRIVIAL TR.
- NORMAL CARDIAC CHAMBERS
- NO E/O REGIONAL WALL MOTION ABNORMALITY. WITH NORMAL LVEF OF 64 %.
- NO E/O PULMONARY HYPERTENSION .PASP 30 mmHg by TR jet.
- NO E/O LEFT VENTRICULAR HYPERTROPHY.
- NO E/O DIASTOLIC DYSFUNCTION.
- NO E/O PERICARDIAL EFFUSION.
- NO E/O INTRACARDIAC CLOT OR VEGETATION
- INTACT IAS / IVS

- CONVENTIONL DOPPLER :

E TO A RATIO IS MORE THAN ONE IN LV INFLOW.

THERE IS NO GRADIENT ACROSS AV, LVOT OR RVOT

PASP FROM TR JET IS 30 mm OF Hg.

- COLOUR DOPPLER:

TRIVIAL TR

EF Slope	108	mm/sec		
Opening Amplitude	21			
Posterior leaflet				
E.P.S.S	02	mm		
Mitral valve prolapse				
Vegetations				
TRICUSPID VALVE	OBSERVED	NORMAL VALUES		
PULMONARY VALVE	OBSERVED	NORMAL VALUES		
EF Slope				
'A' Wave				
Midsystolic notch				
Flutter				
Other Findings				
AORTIC VALVE	OBSERVED	NORMAL VALUES		
Cuspal opening	17	mm		
Closure line	Central			
Eccentricity index	1			
Other Findings				
DIMENSIONS	OBSERVED	NORMAL VALUES		
1. Lvd (Diastolic)	47	26-52		
2. Lvd (Systolic)	32	24-42mm		
3. RVD (Diastolic)	19	7-23mm		
4. IVST (Diastolic)	09	6-11mm		
5. IVST (Systolic)	16			
6. LVPWT (Diastolic)	08	6-11mm		
7. LVPWT (Systolic)	15			
8. Aortic root	31	22-37mm		
9. left Atrium	34	19-40mm		
	STRUCTURE	REGURG GRADING	VELOCITY m/sec	STENOSIS GRADIENT mm/Hg
			Max mean	Peak mean
MITRAL VALVE	NORMAL	0/3	/	/
TRICUSPID VELVE	NORMAL	TRIVIAL	/	/
PULMONARY VELVE	NORMAL	0/4	/	/
AORTIV VALVE	NORMAL	0/4	/	/

"DR. FLUS HEALTHCARE CENTRE"
NATHANI HEIGHTS', B-WING,
42, MUMBAI CENTRAL (EAST)

DR. P.H. CHHABLANI
M.B.B.S, DNB.(MEDICINE)
CONSULTANT PHYSICIAN AND CARDIOLOGIST.

DR. PURVI CHHABLANI

M.B.B.S, DNB. (Medicine)
Consultant Physician And Intensivist

Reg No 77096



Dr-Plus Healthcare Centre

NATHANI HEIGHTS, B-Wing, Shop No. 42, Ground Floor, Opp. Mumbai Central Station (East), Mumbai - 400 008.

Patient Name	:	AMRISH DOLAS	Sex:	MALE
Doctor's Name	:	SELF	Age:	37 Years
Date	:	20/03/2022		

SONOGRAPHY OF ABDOMEN

The liver is normal in size, Outline and echotexture.

There is no vascular, biliary or focal lesions.

The gallbladder shows no calculus or wall abnormality.

The pancreas and spleen are normal in outline, Echotexture and shows no focal lesions.

The great vessels are normal.

There is no ascites or lymphadenopathy.

The kidneys are normal in size outline and position.

The cortical echotexture is normal.

The right kidney is 10.6 mm And the left kidney is 10.9 mm in length.

There is no evidence of calculus hydronephrosis or focal lesion.

The ureters are not dilated.

The urinary bladder is normal in outline and capacity .

there is no calculus or wall lesion.

no significant post-void residue is noted.

The prostate is normal in size shape and echotexture.

it measures 42.6 x 32.4 x 26.9 mm .

IMPRESSION : NORMAL SONOGRAPHY OF ABDOMEN.


DR.VICTOR X.COUTINNO
(MBBS,DMRE)

MMC REGD NO 847325

**'DR. PLUS HEALTHCARE CENTRE'
NATHANI HEIGHTS', B-WING,
42, MUMBAI CENTRAL (EAST)**



Dr-Plus Healthcare Centre

NATHANI HEIGHTS, B-Wing, Shop No. 42, Ground Floor, Opp. Mumbai Central Station (East), Mumbai - 400 008.

Full Name

NAVINA SHETTY

51/F

20/03/2022

Life to be assured:

	Type of Test	Actual Reading	Normal Range
1	Fasting Blood Sugar	89	70-100 mg%
2	PPBS	118	110 TO 140 mg%
3	Total Cholesterol	180.2	120-200 mg%
4	VERY LOW DENSINTY LEVEL(VLDL)	20	10-30 mg/dl
5	High Density Lipid (HDL)	51.2	40-60 mg%
6	Low Density Lipid (LDL)	109	Upto 150
7	S. Triglycerides	119.6	50-150 mg%
8	CHOL/HDL	3.5	Upto 5
9	HDL/LDL	0.4	
10	S. Creatinine	1.0	0.5-1.2 mg%
11	Blood Urea Nitrogen (BUN)	15.4	7-21 mg%
12	BUN/CREAT RATIO	15.4	
13	S. Proteins	6.8	6.0-7.9 mg%
14	(a) Albumin	3.6	3.5-5.5 mg%
15	(b) Globulin	3.2	2.0-3.5 mg%
16	A/G RATIO	1.1	
17	S. Bilirubin	0.8	0.3-1.3mg%
18	(a) Direct	0.5	0.0-0.8 mg%
19	(b) Indirect	0.3	0.0-0.5 mg%
20	SGOT (AST)	25.4	05-34 IU
21	SGPT (ALT)	34.6	05-40 IU
22	GGTP (GGT)	38.5	05-50 IU
23	SGOT/SGPT	0.7	
24	HBA1C	5.5	UPTO 6.5
25	S. Alkaline Phosphatase	99.6	30-115 IU
26	T3	151.5	80-180ng/dl
27	T4	5.7	4.6-12 ug/dl
28	TSH	2.78	0.4-4.0 mIU/L
29	SERUM URIC ACID	5.5	2.5-7.2mg/dl
30	URINE SUGAR PP	ABSENT	
31	URINE SUGAR FASTING	ABSENT	
32	BLOOD GROUP	" A POSITIVE "	

DR. RAKESH PATKAR
M.D., D.N.B. (Pathology)
Reg. 2018/1060



Dr-Plus Healthcare Centre

NATHANI HEIGHTS, B-Wing, Shop No. 42, Ground Floor, Opp. Mumbai Central Station (East), Mumbai - 400 008.

PHYSICIAN REPORT

DATE : 20/03/2022

NAME : AMRISH DOLAS 37/M

PRESENTING COMPLAINS : NIL

PAST HISTORY : H/O PULMONARY COCH'S --TREATED COMPLETELY

FAMILY HISTORY: NOT SIGNIFICANT.

HABITS: ALCOHOL +

HT.- 167 CM. WT.- 70 Kg. BMI.-25.1

P: 72/MIN ., REGULAR BP: 110/70

EYE EXAMINATION : NEAR VISION -B/E - N6 , DISTANT VISION -B/E -6/6

COLOR VISION : NORMAL

RS: CLEAR

CVS: S1,S2 REGULAR

PA: SOFT

CNS: CLINICALLY NAD

LABS: ATTACHED


USG - WNL

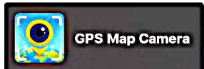
2D-ECHO : WNL

ECG: WNL

X-RAY - WNL

IMPRESSION : : FIT ON CLINICAL MEDICAL EXAMINATION .


DR. HARI CHHABLANI
M.B.B.S. (RESPIRATORY MEDICINE) PGDIPLOMA, PGDIPLOMA
FELLOW INTENSIVE CARE
MMC REG. NO. - 91702



Mumbai, Maharashtra, India

Shop No 65, Nathani Heights, Marzban Parsi Colony, Dalal Estate, Mumbai Central, Mumbai, Maharashtra 400008, India

Lat 18.968763°

Long 72.819999°

20/03/22 09:54 AM

