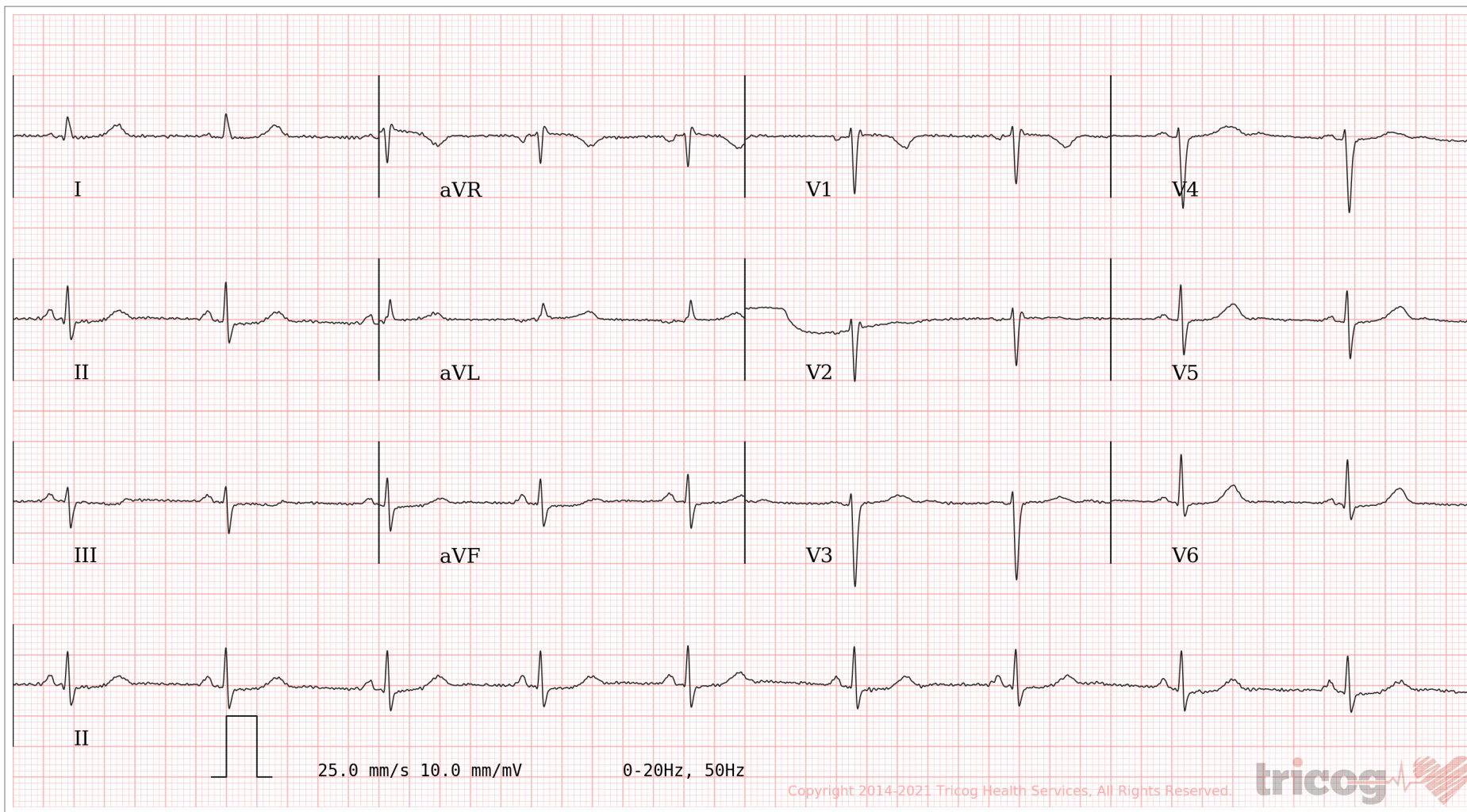




Age / Gender: 39/Female
Patient ID: IDUN0194132122
Patient Name: Mrs.SWATI DEVI-ACP

Date and Time: 15th Aug 21 10:09 AM



AR: 57 bpm VR: 57 bpm QRSD: 84 ms QT: 474 ms QTc: 461 ms PRI: 136 ms P-R-T: 66° 2° 13°

Sinus Bradycardia. Poor "R" wave progression in anterior leads. Please correlate clinically.

AUTHORIZED BY

Dr. Charit
MD, DM: Cardiology

REPORTED BY

Dr Prathima S.K