

DAKSH HOSPITAL

396 - 397, Gandhi Nagar, Scheme No. 8, ALWAR -301001

Ref. No.

Date.....

MEDICAL EXAMINATION REPORT
Mediwheel (BOB)

Name: Mrs Lalita

Age: 30 yrs Sex: Female

Date: 08/04/2023

General Physical Examination

Height : 160 CM

Weight 60 kg :

Pulse : 72/mnt

BP 120/80 :

Temp. : Afebr

Respiration 16/mnt :

BMI : 23.4

Systemic Exam:- NADDental Check up :- NORMALEve check-up :- NORMALSkin Check up:- NORMALENT Check up:- NORMALGynae Check up:- - NORMALI/S Cx Erosion P
Plu Cx 2 ut AVAF NIS FIM Jhu
ptsImpression:- NormalRecommendation:-Life style modification
COLPOSCOPY

Dr. Mukesh Kumar Gupta

MD Gen. Medicine

Reg. No 5423/16262

डॉ० मुकेश गुप्ता

M.D. F.C.C.S.

फिजिशियन एवं मधुमेह रोग विशेषज्ञ

दक्ष हॉस्पिटल, अलवर

रजि. नं.- 5423/16262

Results

Run Date 08/04/2023 10:44:20 AM

Operator DAKSH

Last Name

Sample ID 3

First Name MRS LALITA MEENA

Department

Gender Female Age

Physician DR. MUKESH GUPTA M.D

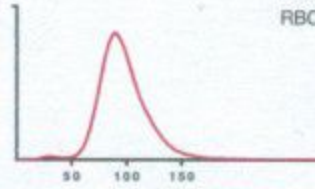
Patient ID AUTO_PID12890

Type Woman

Date of birth

Sample comments

				Range
RBC	4.09	*	10 ⁶ /μL	3.80 - 5.50
HGB	12.9		g/dL	11.5 - 15.2
HCT	41.5	*	%	35.0 - 46.0
MCV	101.6	h*	μm ³	77.0 - 97.0
MCH	31.6		pg	26.0 - 34.0
MCHC	31.1	L	g/dL	32.0 - 35.0
RDW-CV	20.1	H	%	11.0 - 17.0
RDW-SD	75.0	H	μm ³	37.0 - 49.0



Recommended actions

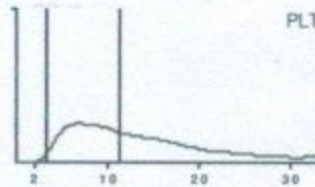
Slide review

Susp. Pathologies

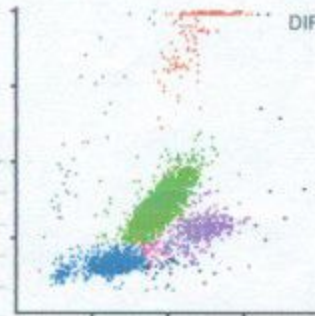
Anisocytosis

Macroplatelets

				Range
PLT	220	*	10 ³ /μL	150 - 450
PCT	0.29	*	%	0.15 - 0.40
MPV	13.0	H*	μm ³	8.0 - 11.0
PDW	27.1	H*	μm ³	11.0 - 22.0
P-LCC	113		10 ³ /μL	44 - 140
P-LCR	51.6	h	%	18.0 - 50.0



			Range		Range
WBC	7.99		10 ³ /μL	3.50 - 10.00	
	#		Range	%	Range
NEU	4.16		1.60 - 7.00	52.5	40.0 - 75.0
LYM	3.19	h	1.00 - 3.00	40.0	20.0 - 45.0
MON	0.23		0.20 - 0.80	2.9	2.0 - 10.0
EOS	0.26		0.00 - 0.50	3.2	1.0 - 6.0
BAS	0.12		0.00 - 0.15	1.4	0.0 - 1.0
LIC	0.03		0.00 - 0.10	0.3	0.0 - 1.0



डॉ० मुकेश गुप्ता

M.D. F.C.C.S.

फिजिशियन एवं मधुमेह रोग विशेषज्ञ

दक्ष हॉस्पिटल, अलवर

रजि. नं.-5423/16702

08/04/2023 10:45:33 AM

Doctor

Printed by : DAKSH

S/N107YOXH041

TECHNOLOGIST

All investigation have their own limitations regarding the sensitivity & specificity of individual assay procedures, isolated laboratory investigations never confirm the final diagnosis of the disease. They only help in arriving at a diagnosis in conjunction with clinical presentation and other related investigations. Report is not valid for medico-legal purpose subject to ALWAR jurisdiction only.

Date :- 08/04/2023

Name :- MR. LALITA MEENA

Age & Sex :- 30Yrs/ Female

Refd. :- Dr Mukesh Gupta M.D.

	TEST NAME	RESULT	REFERENCE RANGE
	ESR	18	00 - 20 mm/hrs
	Blood Group & Rh Factor	B * POSITIVE	
	HbA1C	3.95	4 - 5.6%
	Blood Sugar (F)	80.1	< 70 - 100 mg/dl
	Blood Sugar (PP)	101.2	< 140 mg/dl
	Urine Sugar (F)	NIL	-
	Urine Sugar (PP)	NIL	-
LIVER	S.Bilirubin Total	0.90	0.30 - 1.20 mg/dl
	S.Bilirubin Direct	0.20	0.10 - 0.30 mg/dl
	S.Bilirubin Indirect	0.70	0.30 - 0.90 mg/dl
	S.G.O.T.	37	u/l
	S.G.P.T.	46	u/l
	S.Alk. Phosp.	186	u/l
	G.G.T.	24	5 - 40 u/l
	Total Protein	6.9	6.5 - 8.5 gm/dl
	Albumin	3.9	3.8 - 5.4 gm/dl
	Globulin	3.0	2.3 - 3.5 gm/dl
	A/G Ratio	1.3	-
	AST/ALT Ratio	0.8	-
KIDNEY	Blood Urea	29.1	15 - 45 mg/dl
	S.Creatinine	0.73	0.60 - 1.30 mg/dl
	BUN	17.0	6 - 24 mg/dl
	S.Uric Acid -	4.9	M 3.1 - 7.0, F 2.5 - 5.6 mg/dl
	BUN/Creatinine Ratio	23.2	-
LIPID PROFILE	Total Cholesterol	180.1	Up to 200 mg/dl
	S.HDL	42.1	30 - 70 mg/dl
	S.LDL	112.1	Up to 170 mg/dl
	S.VLDL	26.1	5.0 - 40 mg/dl
	S. Triglycerides	130.1	Up to 170 mg/dl
	LDL/HDL Ratio	2.6	-
	Total Cholesterol/ HDL Ratio	4.2	-
THYROID	T3	102.1	1.2 - 2.8 nmol/L
	T4	8.5	77 - 155 nmol/L
	TSH	3.2	0.30 - 5.0 mU/L

URINE EXAMINATION
Microscopic Examination :

General/Chemical Examination:			RBC	Absent
	Colour	Pale Yellow	WBC	1 - 2
	Reaction	Acidic	Epithelial Cells	0- 1
	Specific Gravity	QNS	Cast	Absent
	Appearance	Clear	Crystal	Absent
	Albumin	Nil	Spermatozoa	Absent
	Sugar	Nil	Amorphous Sediments	Absent
			Other	Absent

X-RAY CHEST

NORMAL STUDY

STOOL EXAMINATION
Microscopic Examination :

General/ Chemical Examination:			RBC	-
	Colour	-	WBC	-
	Consistency	-	Ova & Parasites	-
	PH	-		
	Reducing Substances	-		

 Doctor मुकेश गुप्ता
M.D. F.C.C.S.

TECHNOLOGIST

All investigations have their own limitations regarding the sensitivity & specificity of individual assay procedures, isolated laboratory investigations never confirm the final diagnosis of the disease. They only help in arriving at a diagnosis in conjunction with clinical presentation and other related investigations. Report is not valid for medico-legal purpose subject to ALWAR jurisdiction only.



दक्ष हॉस्पिटल

396, गाँधी नगर स्कीम नं.8, अलवर (राज०) ☎ 0144-2703340

Sonography / 2D Echo Cardiography / Doppler Report

2D/ ECHO REPORT

Name: - Smt. LALITA Age: - 30 Yrs Date: - 8-Apr-23

Reg. No.: - Alw/2009/04

Clinical Diagnosis: - Chest Pain

PROCEDURES: M-MODE/2D/DOPPLER/COLOR/CONTRAST B.A.S. M²

MEASUREMENT:		DOPPLER:				
AOD	22	NORMAL (20- 37mm)	MV 0.54	NORMAL (cm/sec.) (0.8- 1.3)	MR	No
LA	25	(19- 40mm)	AV 1.3	(1.2- 1.8)	AR	No
AVO	18	(12- 25mm)	TV 0.6	(0.3- 0.8)	TR	No
RVDd.	10	(03- 09mm)	PV 0.8	(0.7- 1.1)	PR	No
LVDd	45	(37- 56mm)	MITRAL VALVE-			
LVDs	25	(22- 40mm)	AML Normal			
IVS d	11	(06- 12mm)	PML Normal			
IVS s	10		AORTIC VALVE Normal			
PWd	6	(05- 10mm)	TV & PV are normal.			
LV FUNCTION						
M- E- S Separation		<0.9cm				
Minor		24.42%				
LV Ejection Fraction	72%	65 +/- 12%				

LV WALL MOTION: NO RWMA
ALL CARDIAC CHAMBERS ARE NORMAL
ALL VALVES ARE NORMAL
NO CLOT, VEGETATION, PERICARDIAL EFFUSION

FINAL DIAGNOSIS: NORMAL STUDY

Adv: - Follow up/ review at higher center for confirmation

Note: - Please Correlate clinically. Due to technical limitations as well as inaccuracies inherent in the laboratory and statistical analysis of biological process. Diagnostic accuracy of ECHO is up to 95% only.
Report is not valid for medico-legal purpose.


Dr. Mukesh Kumar Gupta
DR. MUKESH GUPTA
Physician & Sonologist
PHYSICIAN
RM 5423/16262



“भ्रूण लिंग परीक्षण की शिकायत
104 टोल फ्री सेवा पर भी की
जा सकती है।”

“भ्रूण लिंग परीक्षण की शिकायत 104 टोल फ्री सेवा पर भी की जा सकती है।”



दक्ष हॉस्पिटल

396, गाँधी नगर स्कीम नं.8, अलवर (राज०) ☎ 0144-2703340

Sonography / 2D Echo Cardiography / Doppler Report

NAME :- MRS LALITA/F/30 YRS

8-Apr-23

BOB HEALTH CHECKUP

U.S.G. OF ABDOMEN & PELVIS

LIVER

Liver is normal in size shape with normal echo-texture. Intra hepatic biliary radicals Are not dilated. No evidence of focal or diffuse lesion.

GALL BLADDER

Gall bladder is normal.

PANCREAS

Pancreas is normal in size, shape & echo-texture. No evidence of focal or diffuse lesion. MPD not dilated.

SPLEEN

Normal in size with normal shape & echo- texture. Spleen vein is normal. No evidence of focal or diffuse lesion

KIDNEY

Both kidneys are normal.

URINARY BLADDER

UB is normally **distended**, lumen appear clear.

UTERUS:

Uterus is normal in size (8.2x3.1x4.7cm) with homogenous echo-texture.

Endometrial 9 mm in thickness & echo genicity

Cervix has neobothelium cyst of about 1.9 cm

OVARIES:

Both ovaries appear normal.

Advice- follow up/ hormonal study review at higher center for confirmation

Please correlate clinically. USG accuracy is 95 % due to technical limitations as well as inaccuracies inherent in the laboratory and statistical analysis biological process. This report is not valid for medico-legal cases

DR. MUKESH GUPTA
Dr. Mukesh Kumar Gupta
Physician & Sonologist
RM 5423/16252



"भ्रूण लिंग परीक्षण की शिकायत
104 टोल फ्री सेवा पर भी की
जा सकती है"

भ्रूण लिंग परीक्षण की शिकायत 104 टोल फ्री सेवा पर भी की जा सकती है।

Date :- 08/04/2023

Name :- Mrs Lalita

Age & Sex :- 30Yrs/ Female

Refd. :- Dr Mukesh Gupta MD

CYTO-PATHOLOGY

PAP SMEAR

1. Specimen type	Received two conventional smears.
2. Specimen adequacy	Smears are satisfactory for evaluation.
3. Microscopic finding	Smears are moderately cellular comprises of predominantly intermediate with mature superficial squamous epithelial cells arranged in clusters & scattered singly.
4. Inflammation	Not seen
5. Bacilli	Not seen
6. Endocervical cells	Not seen
7. Koilocytic changes	Not seen
8. Trichomonas	Not seen
9. Dysplasia	Nil
10. Neoplasia	Nil
11. Endometrial cells	Nil

Impression:- Negative for intraepithelial lesion or malignancy

डॉ० मुकेश गुप्ता

M.D. F.C.C.S.

फिजिशियन एवं मधुमेह रोग विशेषज्ञ

दक्ष हॉस्पिटल, अलवर

रजि. नं. 5423/16262

Doctor**TECHNOLOGIST**

All investigation have their own limitations regarding the sensitivity & specificity of individual assay procedures, isolated laboratory investigations never confirm the final diagnosis of the disease. They only help in arriving at a diagnosis in conjunction with clinical presentation and other related investigations. Report is not valid for medico-legal purpose subject to ALWAR jurisdiction only.

ID: 583

BPL - 02

08-04-2023 12:12:37

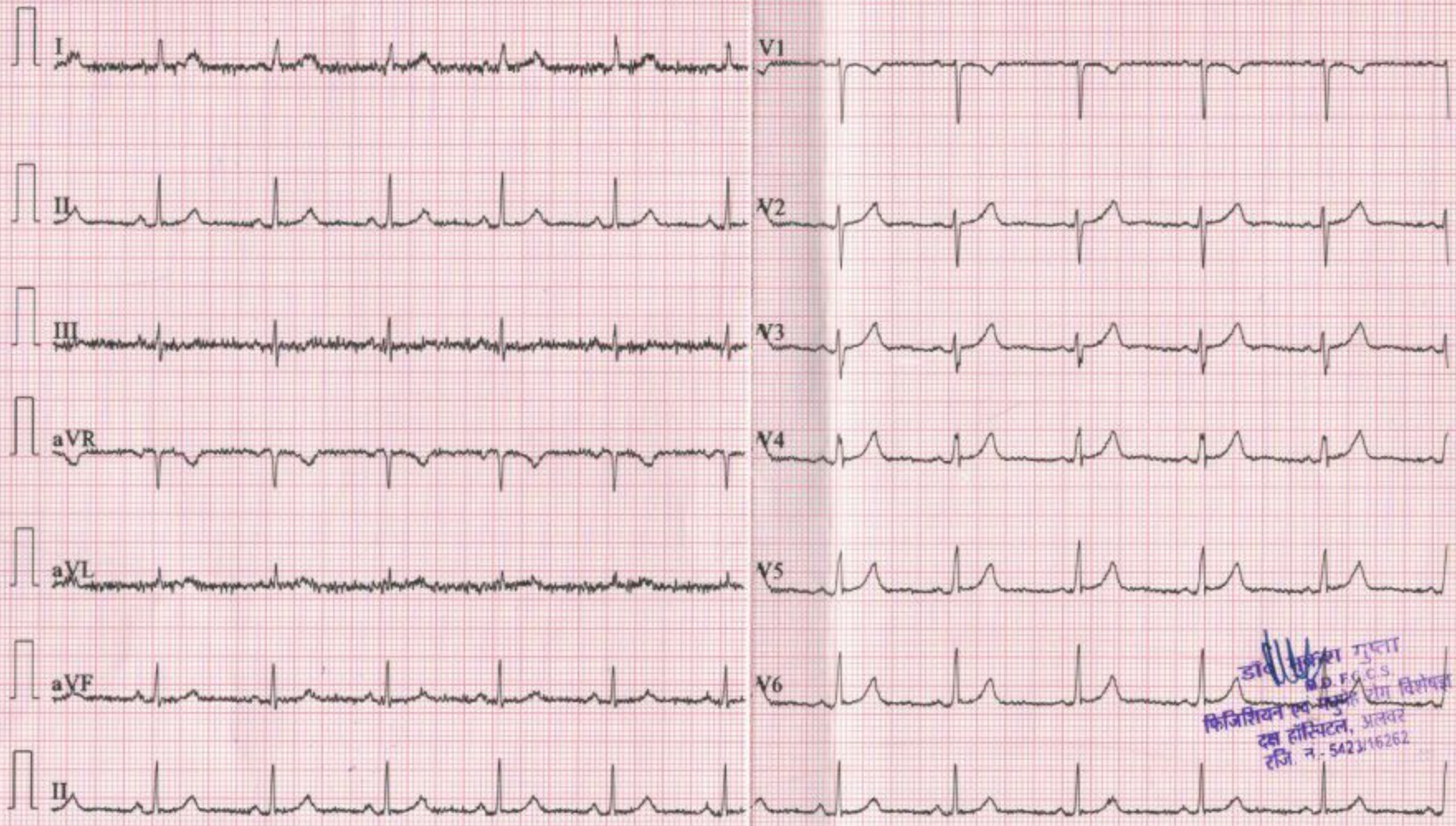Female Years
Req. No. :

HR : 71 bpm
 P : 96 ms
 PR : 140 ms
 QRS : 70 ms
 QT/QTcBz : 368/400 ms
 P/QRS/T : 65/45/38 °
 RV5/SV1 : 0.795/0.982 mV

Diagnosis Information:

Sinus rhythm
Normal ECG

Report Confirmed by:



डा. मनिषा गुप्ता
 M.D. F.C.C.S
 कर्जिसियन एन. एम. सी. एम. विशेषज्ञ
 दक्ष हॉस्पिटल, अलवर
 रजि. नं. 5423/16202

55

R

