

Patient Name : Mrs.Reshma Hegde

Patient ID : 2015000000974

Age : 39Years

Sex : Female

Referring Doctor : EHP

Date : 02.08.2023

**ULTRASOUND ABDOMEN AND PELVIS**

**FINDINGS:**

**Liver** is normal in size and shows **Increased** echopattern. No intra or extra hepatic biliary duct dilatation. No focal lesions.

**Portal vein** is normal in course and caliber. **CBD** is not dilated.

**Gallbladder** is without evidence of calculi, pericholecystic fluid. **shows a Polyp measuring 3-4mm**

**Pancreas** to the extent visualized, appears normal in size, contour and echogenicity

**Spleen** is normal in size, shape, contour and echopattern. No evidence of mass or focal lesions.

**Right Kidney** is normal in size (measures 9.6 cm in length & 1.3 cm in parenchymal thickness), position, shape and echopattern. Corticomedullary differentiation is maintained. **Shows a calculus measuring 3-4 mm in the mid pole with mild hydronephrosis**

**Left Kidney** is normal in size (measures 9.3 cm in length & 1.5 cm in parenchymal thickness), position, shape and echopattern. Corticomedullary differentiation is maintained. No evidence of hydronephrosis. **Shows a calculus measuring 3.4 mm in the mid pole**

**Retroperitoneum** – Obscured by bowel gas.

**Urinary Bladder** is well distended. Wall thickness is normal. No evidence of calculi, mass or mural lesion.

**Uterus** is anteverted and **Bulky** in size, measures 8.8x4.6x5.7 cm. Rest Of Myometrial and endometrial echoes are normal. **Endometrium** measures 8.8 mm. Endometrial cavity is empty. **anterior wall intramural Fibroid measuring 0.8x0.7cm**

**Both ovaries** are normal in size and echopattern.

**Right ovary:** measures 3.0x1.8 cm. **Left ovary:** measures 3.0x1.9cm

**Both adnexa:** No mass is seen.

There is no ascites or pleural effusion.

**IMPRESSION:**

- **Grade I Fatty Liver.**
- **G B Polyp**
- **Bilateral Renal Calculus with mild Right Hydronephrosis**
- **Bulky Uterus With Uterine Fibroid**



**Dr B S Ramkumar 35772**  
**Consultant Radiologist**

**Disclaimer:**

Note: Investigations have their limitations. Solitary pathological/Radiological and other investigations never confirm the final diagnosis. They only help in diagnosing the disease in correlation to clinical symptoms and other related tests.

Please interpret accordingly. This Report is not for Medico - Legal Purposes.

**Narayana Multispeciality Clinic**

17/1, 30th Cross, 8th 'B' Main Road, 4th Block, Jayanagar, Bangalore - 560 011

Clinic No. : 8884000991, 9513919615, Pharmacy No. : 9513919615

E-mail: info.jayanagar@narayanahealth.org, web : www.narayanahealth.org

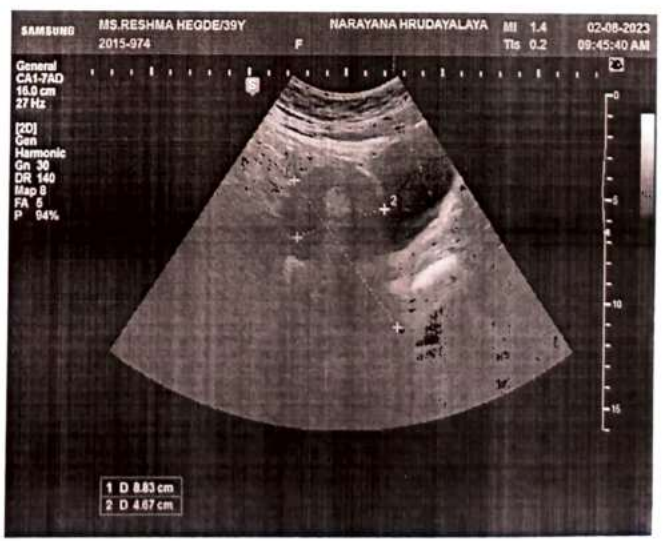
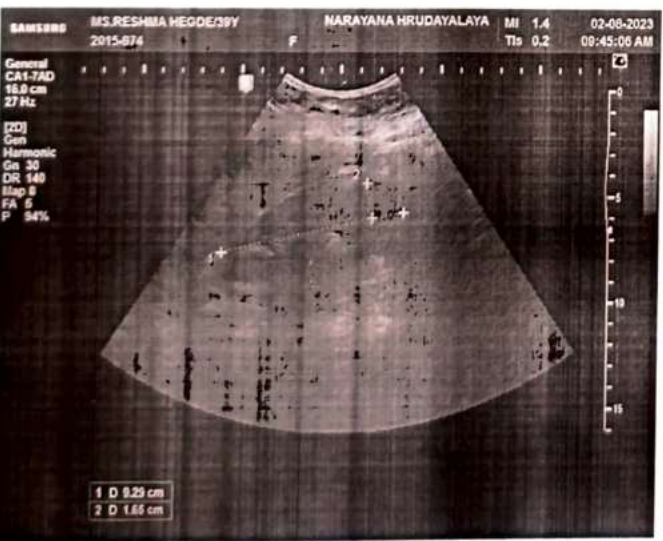
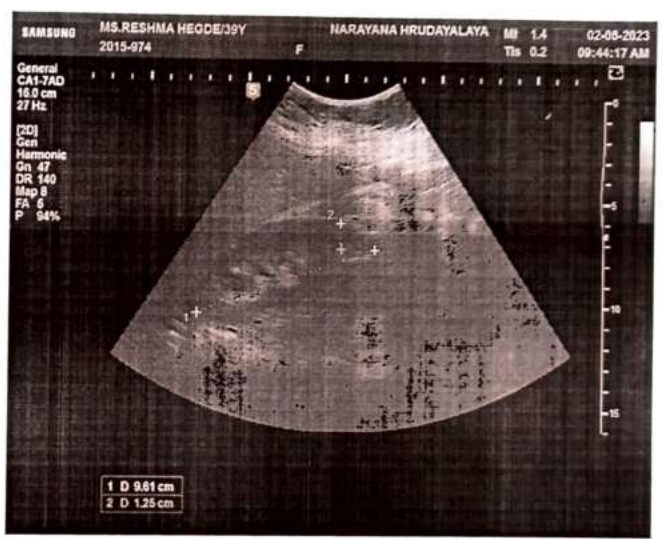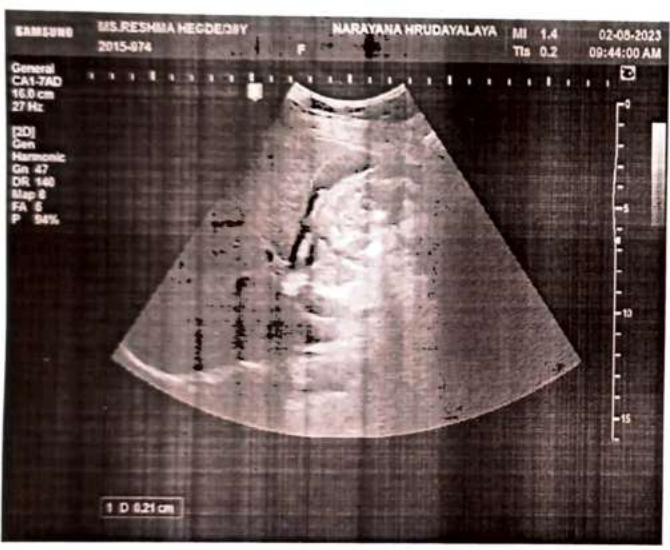
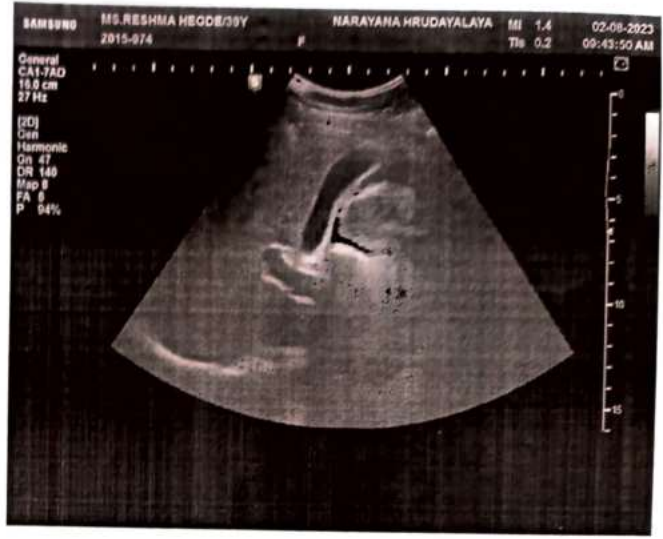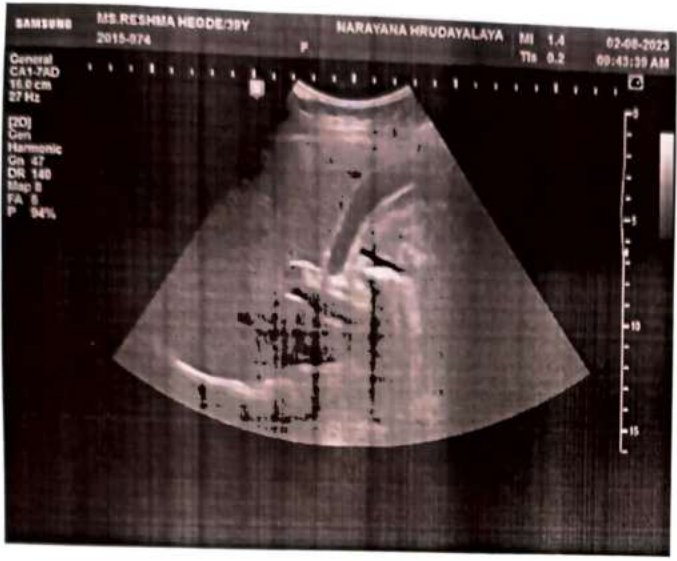


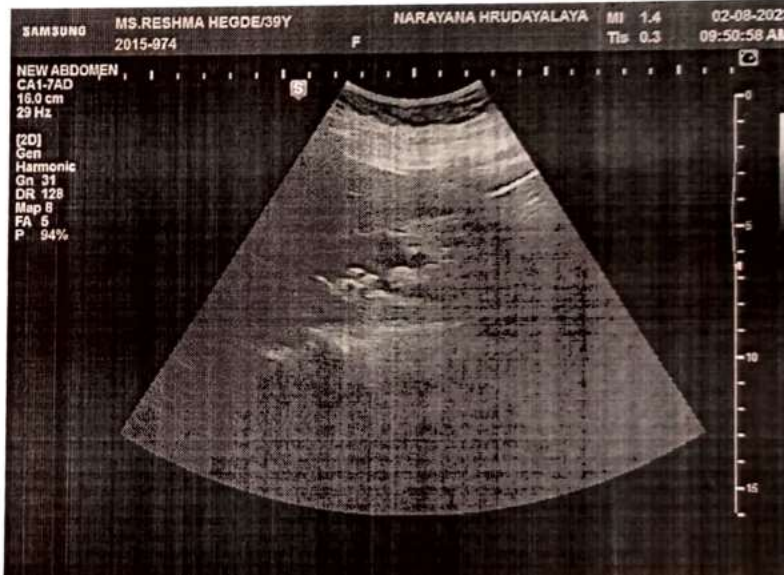
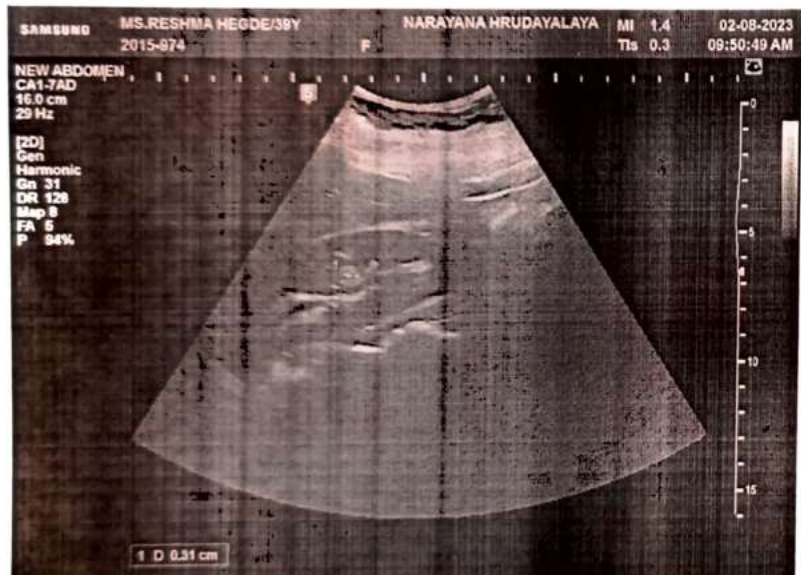
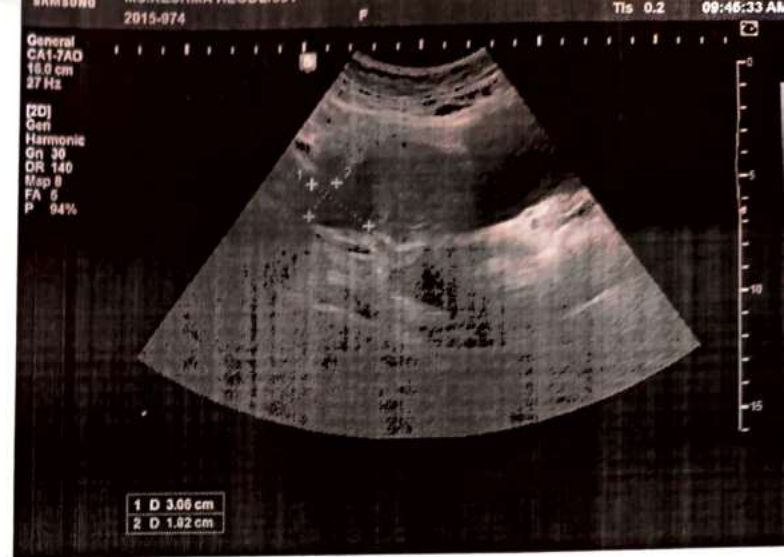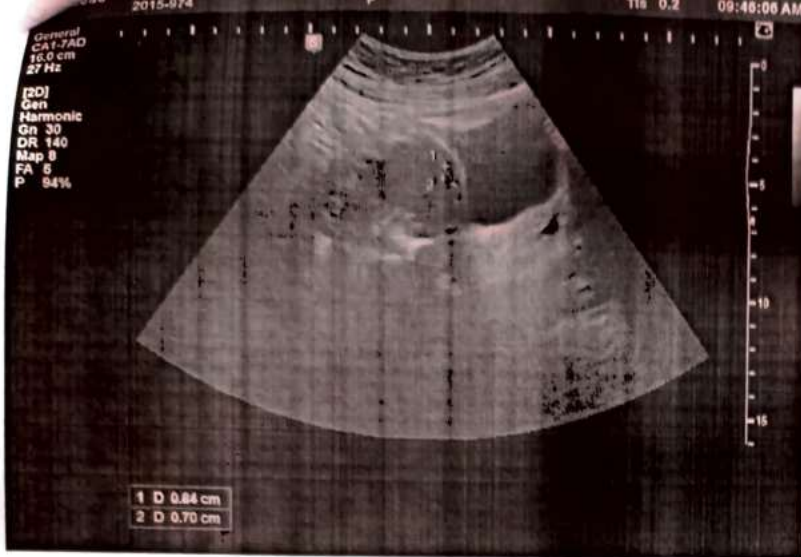
Name  
Birth Date  
Gender

2015 974  
MS RESHMA HEGDE/39Y  
Female

Exam  
Accession #  
Exam Date  
Description  
Operator

02-08-2023



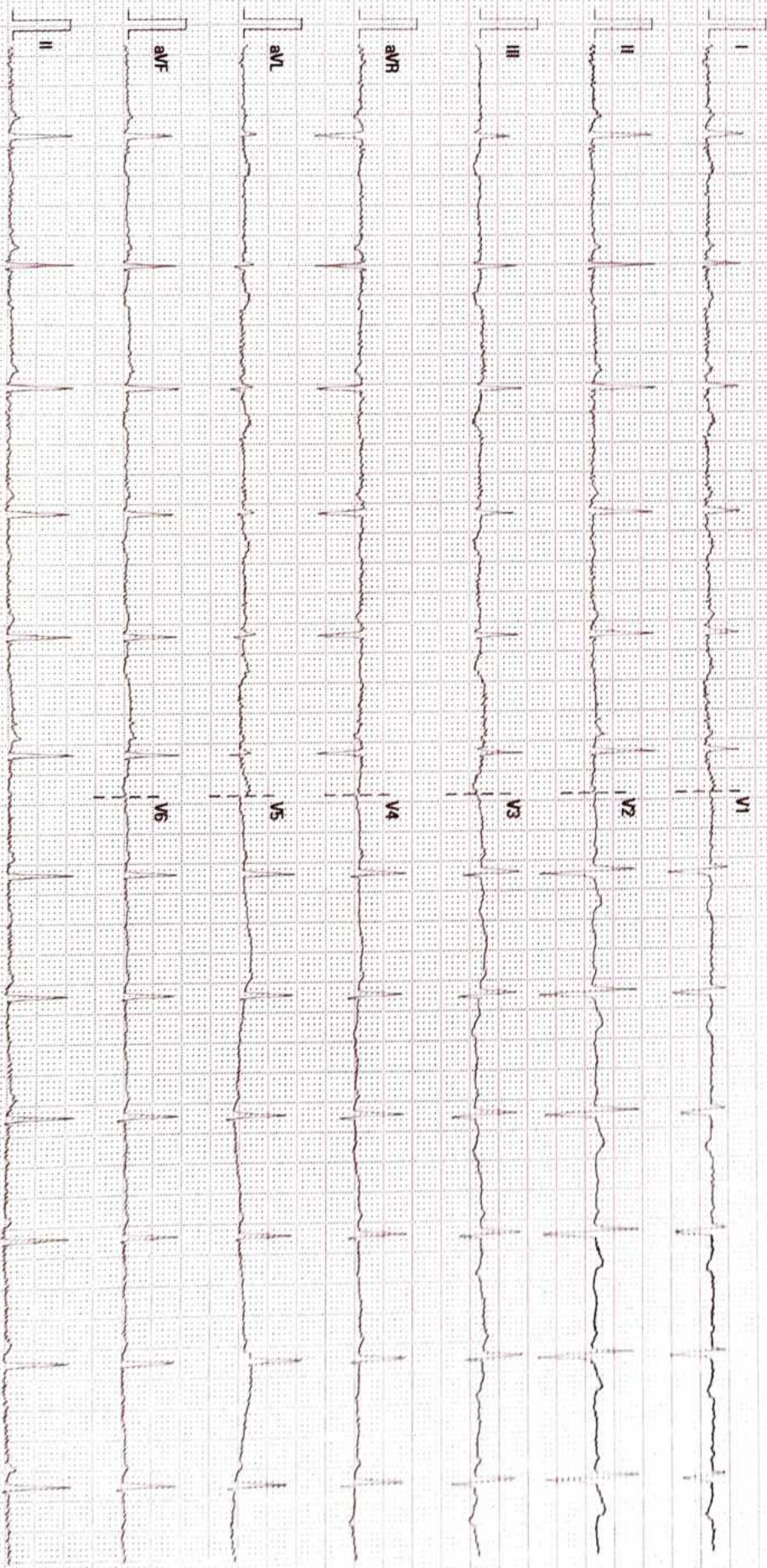


ID: 2015-974  
Name: MRS RESHMA HEGDE  
Age: 39 Years  
Gender: Female

02-08-2023 09:18:56 AM

Vent. Rate 74 bpm  
PR Interval 132 ms  
QRS Duration 80 ms  
QT/QTc Interval 352/377 ms  
P/QRS/T Axes 30/58/-16 deg

DiTechcodes



25 mm/s 10 mm/mV 50 Hz 60R 35 Hz

NARAYANA HEALTH JAYANAGAR

02.06.00.V28.4.1

SN-FN-73007176

**ADULT TRANS-THORACIC ECHO REPORT**

**NAME : MRS.RESHMA HEGDE**

**AGE/SEX : 39YRS/MALE**

**MRN NO : 2015000000974**

**DATE : 02.08.2023**

**FINAL DIAGNOSIS:**

- NORMAL CHAMBER DIMENSION
- NO RWMA
- NORMAL VALVES
- MILD-MR
- MILD-TR
- NORMAL PA PRESSURE
- NORMAL RV /LV FUNCTION
- LVEF-60 %

**MEASUREMENTS**

AO: 29 MM      LVID (d) : 40 MM      IVS (d) : 10 MM      RA : 32 MM  
LA: 33 MM      LVID(s) : 29 MM      PW (d) : 10 MM      RV : 28 MM

EF: 60 %

**VALVES**

MITRAL VALVE : NORMAL

AORTIC VALVE : NORMAL

TRICUSPID VALVE : NORMAL

PULMONARY VALVE : NORMAL

**CHAMBERS**

LEFT ATRIUM : NORMAL

RIGHT ATRIUM : NORMAL

LEFT VENTRICLE : NORMAL, NORMAL LV FUNCTION

RIGHT VENTRICLE : NORMAL, TAPSE-19 MM, NORMAL RV FUNCTION

RVOT/LVOT : NORMAL

Date : 02/08/2023 08:50 AM  
 Department : OBSTETRICS & GYNAECOLOGY  
 Consultant : Dr. Rupa S Iyengar  
 Ref. Hospital :  
 Ref. Doctor :  
 Sponsor Name : ARCOFEMI HEALTHCARE LIMITED

Patient MRN : 2015000000974  
 Patient Name : Ms Reshma Hegde  
 Sex/Age : Female, 39y 8m  
 Address : NO 227, 2ND FLOOR, C BLOCK, DS  
 MAX SAVERA APT, UTTARAHALLI,  
 Bengaluru, Bangalore Urban,  
 Karnataka, India, 560061  
 \* Number : OP-001  
 \* Number : OP, New Visit  
 \* Number : 9740131310

Heart Rate(bpm) :  
 Weight (kg) :  
 Fall Score :  
 Temp (\*F) :  
 BMI :  
 Pain Score :

REF COMPLAINTS AND HPI

ALS :  
 (mmHg) :  
 Height (cm) :  
 Respiratory Rate(brpm) :

GENERAL EXAMINATION

Known/Unknown :  
 Cachectic/ Thin Built/ Average Built/ Obese/ Normal :  
 Negative/ Unknown :  
 Normal/Any Psychological Problem :

Psychological Assessment:  
 Present Family History :  
 Habitus:

SYSTEMIC EXAMINATION

ADDITIONAL ASSESSMENT

INVESTIGATIONS

TREATMENT SUGGESTED

REVIEW ON

Generated By : Vani.(368774)

Generated On

: 02/08/2023 05:18 PM

Page 1 of 1

Appointments

1800-309-0309 (Toll Free)

**Date** : 02/08/2023 08:50 AM  
**Department** : FAMILY MEDICINE  
**Consultant** : Dr. Priya S  
**Ref. Hospital** : -  
**Ref. Doctor** : -  
**Sponsor Name** : ARCOFEMI HEALTHCARE LIMITED

**MRN** : 20150000000974  
**Name** : Ms Reshma Hegde  
**Age** : Female, 39y 8m  
**Address** : NO 227, 2ND FLOOR, C BLOCK, DS  
 MAX SAVERA APPT, UTTARAHALLI,  
 Bengaluru, Bangalore Urban,  
 Karnataka, India, 560061  
**OP-001**  
**Visit Type** : OP, New Visit  
**Registration Number** : 97401131310

**HR** : 130/1 (normal) **Heart Rate (bpm)** : 87 bpm **Temp (\*F)** :  
**WT** : 75 kg **Weight (kg)** : 75 kg **BMI** :  
**FS** : 98.1 **Fall Score** : **Pain Score** :

SPO2: 98.1

**COMPLAINTS AND HPI**

No known comorbidities

**PHYSICAL EXAMINATION**

**Vitals** : Known/Unknown  
**General** : Cachectic/ Thin Built/ Average Built/ Obese/ Normal  
**History** : Negative/ Unknown  
**Assessment** : Normal/Any Psychological Problem

All reports - noted.

**LABORATORY AND INSTRUMENTAL EXAMINATION**

USG Abd - Gr I Fatty liver. GB Polyp.  
 B/L Renal Calculus with mild @ Hydronephrosis. Bladder uterus  
 ECG - NSR  
 APTT - NO RWMA  
 EF: 60%  
 Adv.

**TREATMENT SUGGESTED**

- P. Unimax 0.4 mg o-o-e x 2 weeks.  
 - Lifestyle modifications.

ON

- Anovate Cream YA 1-o-o x 7d.