



# YASHFEEN CARDIAC HOSPITAL™

At. & Po. Viraval, Navsari. 396 445. Phone (H) (02637) 235725

Website : [www.yashfeenhospital.in](http://www.yashfeenhospital.in) E-mail : [info@yashfeenhospital.in](mailto:info@yashfeenhospital.in)  
(For Laboratory Reports Only)



Patient Name : ABEY J

Age : 31 Years Sex : M

Ref By Dr. : -

Area : Navsari

Date : 25/02/2023

Sample Time : 25/02/2023 08:59 No : 17

Time : 11:46AM

## HAEMOGRAM

Test	Findings	UOM	Normal Range
HAEMOGLOBIN	<b>17.1</b>	gm/dl	M-13.5-17.0 F-11.5-15.5
<b>HAEMOGRAM</b>			
RED BLOOD CELL	<b>5.73</b>	10 <sup>6</sup> /μL	3.76 - 5.70
TOTAL LEUCOCYTE COUNT	6400	cells/cumm	4,000-11,000
<b>Differential Count</b>			
Neutrophil	48	%	40-75
Lymphocytes	<b>44</b>	%	20-40
Eosinophil	4	%	1-6
Monocytes	4	%	2-10
Basophils	0	%	0-0
PLATELET COUNT	265000	lacs/cumm	1.5-5.5 Lacs
<b>RBC INDICES</b>			
P.C.V.	48.3	%	M-40-56% F-37-47%
M.C.V.	84.3	cu/microns	76-94
M.C.H.	29.9	pg	27-30
M.C.H.C.	<b>35.5</b>	-	30-35
BLOOD GROUP	"O"	-	-
RH FACTOR	POSITIVE	-	-
E.S.R.(1 hour)	<b>2</b>	mm/hr.	M-5-10, F-5-20

Remarks

Designed By : Sanita Infotech Pvt. Ltd., Navsari

Thanks for Reference



*P. Chaudhary*  
**Dr. PIYUSH B. CHAUDHARI**

Yashfeen Cardiac Hospital  
M.D. Medicine

Reg. No. G-21518

*A. Shah*

Signature

Technician



# YASHFEEN CARDIAC HOSPITAL™

At. & Po. Viraval, Navsari. 396 445. Phone (H) (02637) 235725

Website : [www.yashfeenhospital.in](http://www.yashfeenhospital.in) E-mail : [info@yashfeenhospital.in](mailto:info@yashfeenhospital.in)

(For Laboratory Reports Only)



Patient Name : ABEY J

Ref By Dr. : -

Sample Time : 25/02/2023 08:59 No : 17

Age : 31 Years Sex : M

Area : Navsari

Date : 25/02/2023

Time : 11:46AM

## BIOCHEMICAL TEST REPORT

Test	Findings	UOM	Normal Range
S.CREATININE	0.9	mg/dL	M .0.9-1.4 , F. 0.8-1.2
S.URIC ACID	<u>7.7</u>	mg/dL	Male:3.5-7.2, Female:2.6-6.0
BLOOD UREA NITROGEN	9.9	mg/dL	4.7-23.0



*P. Chaudh*  
Dr. PIYUSH B. CHAUDHARI  
M.D. Medicine  
Reg. No. G-21518

Remarks

Designed By : Sarita Infotech Pvt. Ltd., Navsari

Yashfeen Cardiac Hospital

*Ashah*

Signature

*Thanks for Reference*

Technician



# YASHFEEN CARDIAC HOSPITAL™

At. & Po. Viraval, Navsari. 396 445. Phone (H) (02637) 235725

Website : [www.yashfeenhospital.in](http://www.yashfeenhospital.in) E-mail : [info@yashfeenhospital.in](mailto:info@yashfeenhospital.in)  
(For Laboratory Reports Only)



Patient Name : ABEY J

Age : 31 Years Sex : M

Ref By Dr. : -

Area : Navsari

Date : 25/02/2023

Sample Time : 25/02/2023 08:59 No : 17

Time : 11:46AM

## LIPID PROFILE TEST REPORT

Test	Findings	UOM	Normal Range
S. CHOLESTEROL	172.6	mg/dL	<200:Desirable, 200-239:Borderline High, >=240:High
HDL CHOLESTEROL	45.4	mg/dL	<40:Low(High Risk), >=60:High(Low Risk)
LDL CHOLESTEROL	<b>127.4</b>	mg/dL	<100: Optimal, 100-129: Nearoptimal/ Aboveoptimal, 130-159:BorderlineHigh,16 0-189:High,>=190:Very
VLDL CHOLESTEROL	22.6	mg/dL	UPTO 40
S. TRIGLYCERIDES	112.8	mg/dL	<150:Normal, 150-199:Borderline High,200-499:High, >=500:Very Hi
CHOL/ HDL RATIO	3.8	mg/dL	LESS THAN 5
LDL/ HDL RATIO	2.8	mg/dL	LESS THAN 5



*P. Chaudhary*  
**Dr. PIYUSH B. CHAUDHARI**  
M.D. Medicine  
Reg. No. G-21518

### Remarks

Designed By : Sarita Infotech Pvt. Ltd., Navsari

Yashfeen Cardiac Hospital

*Signature*

Signature

*Thanks for Reference*

Technician



# YASHFEEN CARDIAC HOSPITAL™

At. & Po. Viraval, Navsari. 396 445. Phone (H) (02637) 235725

Website : [www.yashfeenhospital.in](http://www.yashfeenhospital.in) E-mail : [info@yashfeenhospital.in](mailto:info@yashfeenhospital.in)  
(For Laboratory Reports Only)



Patient Name : ABEY J

Age : 31 Years Sex : M

Ref By Dr. : -

Area : Navsari

Date : 25/02/2023

Sample Time : 25/02/2023 08:59 No : 17

Time : 11:46AM

## LIVER FUNCTION TEST REPORT

Test	Findings	UOM	Normal Range
TOTAL BILIRUBIN	0.9	mg/dL	0-1.0
DIRECT BILIRUBIN	0.3	mg/dL	0-0.8
INDIRECT BILIRUBIN	<b>0.6</b>	mg/dL	0-0.2
SGPT	28.3	U/L	Below 40.0
S.ALKALINE PHOSPHATASE	88.3	U/L	CH . 170.0-515.0 A. 37.0-147.0
TOTAL PROTEIN	6.9	g/dl	6.0-8.0
ALBUMIN	5.0	g/dl	3.0-5.0
GLOBULIN	<b>1.9</b>	g/dl	3.0-3.5
A/G	2.6	g/dl	
SGOT	27.4	U/L	Below 40.0



*P. Chaudh*  
Dr. PIYUSH B. CHAUDHARI  
M.D. Medicine  
Reg. No. G-21518

### Remarks

Designed By : Sarita Infotech Pvt. Ltd., Navsari

Yashfeen Cardiac Hospital

*A. Shah*

Signature

*Thanks for Reference*

Technician



# YASHFEEN CARDIAC HOSPITAL™

At. & Po. Viraval, Navsari. 396 445. Phone (H) (02637) 235725

Website : [www.yashfeenhospital.in](http://www.yashfeenhospital.in) E-mail : [info@yashfeenhospital.in](mailto:info@yashfeenhospital.in)  
(For Laboratory Reports Only)



Patient Name : ABEY J

Age : 31 Years Sex : M

Ref By Dr. : -

Area : Navsari

Date : 25/02/2023

Sample Time : 25/02/2023 08:59 No : 17

Time : 11:46AM

## THYROID FUNCTION TEST REPORT

Test	Findings	UOM	Normal Range
T3 (TRIODOTHYRONINE)	1.65	ng/ml	NEWBORNS:0.73-2.88 6DAYS-3MONTHS:0.80-2.7 5 4-12MONTHS:0.86-2.65 1-6YEARS:0.92-2.48 7-11YEARS:0.93-2.31 12-20YEARS:0.91-2.18 ADULT:0.80-2.00
T4 (THYROXINE)	11.53	µg/dl	NEWBORNS:5.04-18.5, 6DAYS-3MONTHS:5.41-17. 0, 4-12 MONTHS:5.67-16.0, 1-6YEARS:5.95-14.7, 7-11 YEARS:5.99-13.8, 12-20 YEARS:5.91-13.2, ADULTS:5.10-14.1
TSH	2.06	µIU/ml	NEWBORNS:0.70-15.2, 6DAYS-3MONTHS:0.72-11. 0, 4-12MONTHS:0.73-8.35, 1-6YEARS:0.70-5.97, 7-11YEARS:0.60-4.84, 12-20YEARS:0.51-4.30, ADULTS:0.27-4.20

### TECHNIQUE

ELECTROCHEMILUMINESCEN  
CE

Remarks

Designed By : Sarita Infotech Pvt. Ltd. Navsari



*P. Chaudh*  
Dr. PIYUSH B. CHAUDHARI

M.D. Medicine

Reg. No. G-21518

*A. Shah*

signature

Yashfeen Cardiac Hospital

Technician

Thanks for Reference



# YASHFEEN CARDIAC HOSPITAL™

At. & Po. Viraval, Navsari. 396 445. Phone (H) (02637) 235725

Website : www.yashfeenhospital.in E-mail : info@yashfeenhospital.in

(For Laboratory Reports Only)



Patient Name : ABEY J

Age : 31 Years Sex : M

Ref By Dr. : -

Area : Navsari

Date : 25/02/2023

Sample Time : 25/02/2023 08:59 No : 17

Time : 11:46AM

## ROUTINE URINE ANALYSIS

Test	Findings	UOM	Normal Range
<b><u>PHYSICAL EXAMINATION</u></b>			
Quantity	-	-	-
Colour	YELLOW	-	-
Appearance	CLEAR	-	-
Reaction	ACIDIC	-	-
Sp. Gravity	1.002	-	-
<b><u>CHEMICAL EXAMINATION</u></b>			
U.Albumin	NIL	-	-
Sugar	NIL	-	-
Acetone	NIL	-	-
Bile Salt	NIL	-	-
Bile Pigment	NIL	-	-
Occult Blood	NIL	-	-
<b><u>MICROSCOPIC EXAMINATION</u></b>			
Pus Cells	1-2	/hpf	-
Epithelial cells	1-2	/hpf	-
Red cells	ABSENT	/hpf	-
Casts	-	/hpf	-
Crystals	<b><u>AMORPHOUS SEEN</u></b>	/hpf	-
Others	-	/hpf	-



*P. Chaudhary*  
Dr. PIYUSH B. CHAUDHARI  
M.D. Medicine  
Reg. No. G-21518

Remarks

Designed By : Santa Infotech Pvt. Ltd., Navsari

Yashfeen Cardiac Hospital

*P. Chaudhary*  
Signature

Thanks for Reference

Technician



# YASHFEEN CARDIAC HOSPITAL™

At. & Po. Viraval, Navsari. 396 445. Phone (H) (02637) 235725

Website : [www.yashfeenhospital.in](http://www.yashfeenhospital.in) E-mail : [info@yashfeenhospital.in](mailto:info@yashfeenhospital.in)  
(For Laboratory Reports Only)



Patient Name : ABEY J

Age : 31 Years Sex : M

Ref By Dr. : -

Area : Navsari

Date : 25/02/2023

Sample Time : 25/02/2023 08:59 No : 17

Time : 11:46AM

## GGT TEST REPORT

Test	Findings	UOM	Normal Range
SERUM GGT	42	U/L	10-71 U/L



*P. Chaudh.*  
**Dr. PIYUSH B. CHAUDHARI**  
M.D. Medicine  
Reg. No. G-21518

### Remarks

Designed By : Sarita Infotech Pvt. Ltd., Navsari

Yashfeen Cardiac Hospital

Signature

*Thanks for Reference*

Technician



# YASHFEEN CARDIAC HOSPITAL™

At. & Po. Viraval, Navsari. 396 445. Phone (H) (02637) 235725

Website : www.yashfeenhospital.in E-mail : info@yashfeenhospital.in  
(For Laboratory Reports Only)



Patient Name : ABEY J

Age : 31 Years Sex : M

Ref By Dr. : -

Area : Navsari

Date : 25/02/2023

Sample Time : 25/02/2023 09:00 No : 17

Time : 11:47AM

## HAEMOGLOBIN A1 C ESTIMATION

Test	Findings	UOM	Normal Range
Hb A1C	5.0	%	>8 :Action Suggested, 7-8 :Good Control, <7 :Goal, 6-7 :Near Normal Glycemia, <6 :Non-diabetic Level

### Technique

METHOD - HPLC

Mean Blood Glucose

96.0

mg/dL



*P. Chaudhary*  
Dr. PIYUSH B. CHAUDHARI  
M.D. Medicine  
Reg. No. G-21518

### Remarks

Designed By : Sarita Infotech Pvt. Ltd., Navsari

Yashfeen Cardiac Hospital

Signature

Thanks for Reference

Technician





# YASHFEEN CARDIAC HOSPITAL™

At. & Po. Viraval, Navsari. 396 445. Phone (H) (02637) 235725

Website : www.yashfeenhospital.in E-mail : info@yashfeenhospital.in

(For Laboratory Reports Only)



Patient Name : ABEY J

Ref By Dr. : -

Sample Time : 25/02/2023 08:59 No : 17

Age : 31 Years Sex : M

Area : Navsari Date : 25/02/2023

Time : 1:40PM

## BLOOD SUGAR TEST REPORT

Test	Findings	UOM	Normal Range
FASTING BLOOD SUGAR	94.2	mg/dL	70-110
FASTING URINE SUGAR	NIL	-	NIL
POSTPANDRIAL BLOOD SUGAR	77.2	mg/dL	70-140
POSTPANDRIAL URINE SUGAR	NIL	-	NIL



*P. Chaudh*  
**Dr. PIYUSH B. CHAUDHARI**  
M.D. Medicine  
Reg. No. G-21513

### Remarks

Designed By : Sarita Infotech Pvt. Ltd., Navsari

Yashfeen Cardiac Hospital

*H. Patel*  
signature

*Thanks for Reference*

Technician



# YASHFEEN CARDIAC HOSPITAL™

At. & Po. Viraval, Navsari. 396 445. Phone (H) (02637) 235725

Website : www.yashfeenhospital.in E-mail : info@yashfeenhospital.in

(For Laboratory Reports Only)



Patient Name : ABEY J

Age : 31 Years Sex : M

Ref By Dr. : -

Area : Navsari Date : 25/02/2023

Sample Time : 25/02/2023 12:54 No : 17

Time : 1:46PM

## STOOL EXAMINATION REPORT

Test	Findings	UOM	Normal Range
<b>PHYSICAL EXAMINATION OF STOOL</b>			
COLOR	<b>BROWN</b>	-	
CONSISTANCY	<b>SEMI SOLID</b>	-	
BLOOD	ABSENT	-	ABSENT
MUCUS	<b>PRESENT</b>	-	
REACTON		-	ALKALINE
PARASITES	-	-	
<b>MICROSCOPIC EXAMINATION STOOL</b>			
PUS CELL	1-2	/hpf	OCCASIONAL
EPITHELIAL CELL	1-2	/hpf	OCCASIONAL
RED CELL	-	/hpf	ABSENT
OVA	-	-	
CYSTS	-	-	
TROPHOZOITS	-	-	
FAT GLOBULES	-	-	
<b>SPECIAL TEST FOR STOOL</b>			
BENZIDINE TEST(OCCULT BLOOD)	NEGATIVE	-	NEGATIVE
BENZIDINE TEST(REDUCING SUGAR)	-	-	
HANGING DROP PREPARATION (VIBRIO CHOLERAEE)	-	-	
OTHER	<b>BACTERIA &amp; AMORPHOUS SEEN</b>	-	



*P. Chaudh.*  
Dr. PIYUSH B. CHAUDHARI  
M.D. Medicine  
Reg. No. G-21518

Remarks

Designed By : Sarita Infotech Pvt. Ltd., Navsari

Yashfeen Cardiac Hospital

*Signature*  
Signature

Thanks for Reference

Technician

ABEY ,  
ID:  
DOB:  
31 Years , ,  
Unknown ,Unknown  
Med.:  
Location:  
Referring Physician:  
Notes:

25-02-2023 10:06:54

Vent. Rate: 90 BPM  
PR int: 161 ms  
QRS dur: 111 ms  
QT/QTc: 334/381 ms  
P-R-T axes: 57 80 49  
Avg. RR: 665 ms  
QTcB: 409 ms  
QTcF: 382 ms

SINUS RHYTHM  
INCOMPLETE RIGHT BUNDLE BRANCH BLOCK  
BORDERLINE ECG

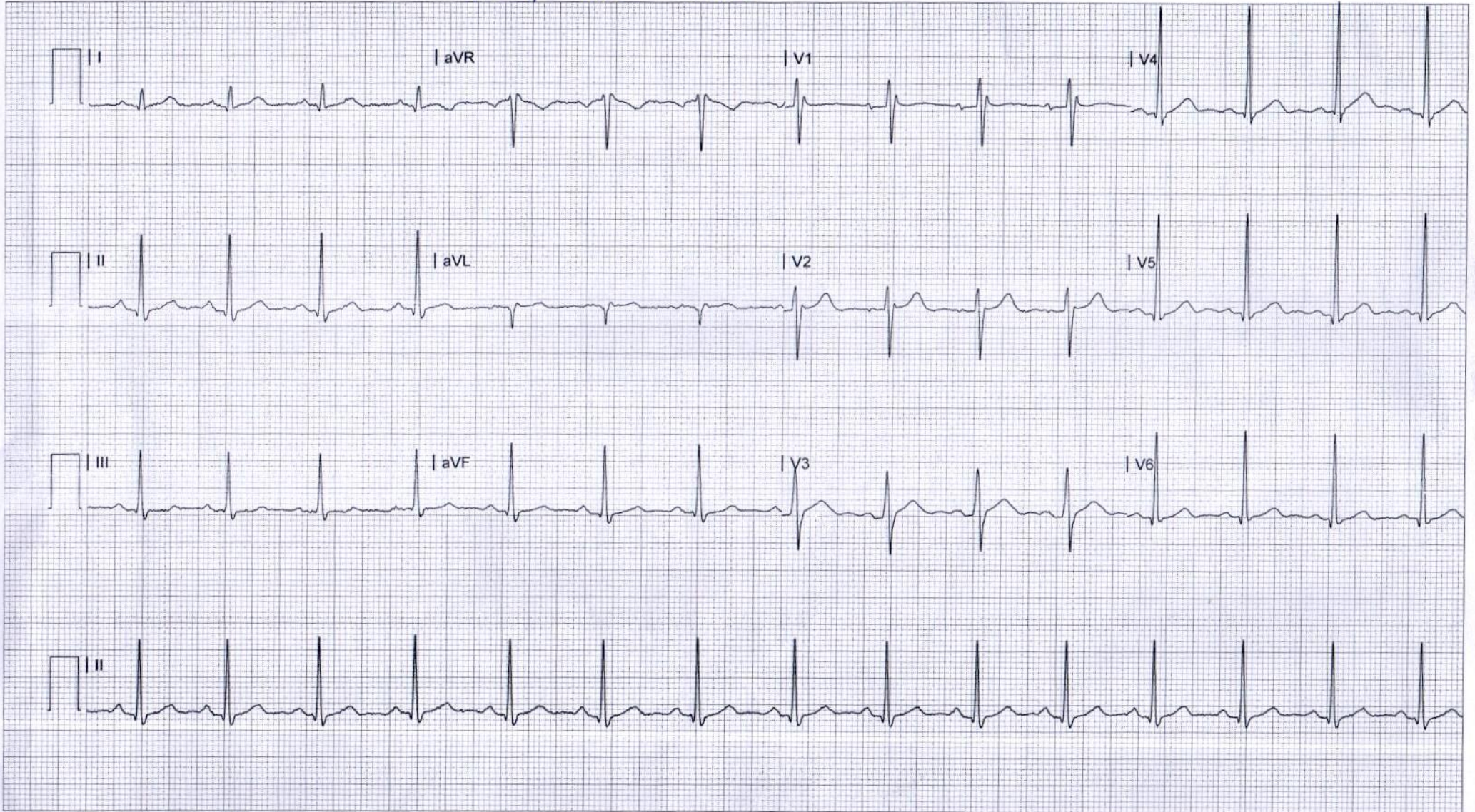
UNCONFIRMED REPORT  
Reviewed by:

*P. Chaudh*  
Dr. PIYUSH B. CHAUDHARI  
M.D. Medicine  
Reg. No. G-21518

Signed by:  
Date:



*Abey Age- 31m*





# YASHFEEN CARDIAC HOSPITAL™

MANAGED BY :- YASHFEEN FOUNDATION

VIRAVAL, NAVSARI. 396 445. PHONE : (H) (02637) 235725

Website : www.yashfeenhospital.in E-mail : info@yashfeenhospital.in

(Regd. No. E/1390/Navsari)

(Stationary For Report Only)

## 2D ECHO CARDIOGRAPHY COLOUR DOPPLER REPORT

Patient Name & No	: ABEY J CH22047912	Age/Sex	UHID :	: 7132
Doctor	: Mohil Nagad	31/ M	No :	: 7548
Referred By	:		Date :	: 25/02/2023

### M-Mode findings

LVIDd : 40mm  
 LVIDs : 28mm  
 IVSd : 10mm  
 PWd : 10mm  
 EF : 60%  
 Aorta : 20mm  
 LA : 30mm

### 2D Imaging

Aortic Valve : Trileaflet, Normal  
 Mitral Valve : Thin, Pliable, Normal Mobility, Trivial MR.  
 Tricuspid Valve : Trivial TR, RVSP: 20+ RAP  
 Pulmonary Valve : Normal

=> : All cardiac chambers are normal sized.  
 => : All cardiac valves are normal.  
 => : No regional wall motion abnormality.  
 => : Normal LV systolic function.  
 => : Normal LV diastolic function.  
 => : IAS/IVS intact.  
 => : No obvious clots/ vegetations/ or effusion.  
 => : IVC Normal size.

### Doppler Findings

=> : No MS/Trivila MR, No TS/Trivial TR, No AS/AR & No PS/PR  
 Mitral inflow Pattern : E > A  
 Tissue Doppler Findings : E' > A'

Impression : Normal LVEF:60%, No RWMA.



Report Prepared By

Report Checked By

**DR. MOHIL NAGAD**  
 Danish Dhada  
 M.B.B.S. P.D.C.C.  
 M.D. Medicine D.M. Cardiology  
 Senior Consultant- Interventional Cardiology  
 Non-Invasive Cardiologist  
 Reg. No. G- 22893  
 YASHFEEN HOSPITAL, NAVSARI

Designed By : Sarita Infotech Pvt. Ltd., Navsari

# YASHFEEN IMAGING & RADIOLOGY DEPARTMENT

MANAGED BY :- YASHFEEN FOUNDATION

VIRAVAL, NAVSARI. 396 445. PHONE : (H) (02637) 235725

Website : [www.yashfeenhospital.in](http://www.yashfeenhospital.in) E-mail : [info@yashfeenhospital.in](mailto:info@yashfeenhospital.in)

Patient's Name:	ABEY J	Age & Sex:	31Yrs/M
Ref. by Dr.	SELF	Date:	25-02-2023

## X RAY CHEST (PA VIEW)

Both lung fields appear normal.

Both hila appear normal.

Both CP angles appear clear.

Cardiac size appears within normal limit.

Both domes of diaphragm appear normal.

Bony thoracic cage appears normal.

### IMPRESSION:

- Normal X-ray chest (PA view).

  
**Dr. DHARMESH DESAI**  
(M.D. Radiology)  
Reg. No. G - 45284  
MD  
YASHFEEN GROUP OF HOSPITAL



Please contact immediately for any typographical error.  
This is only professional opinion, not a final diagnosis. Kindly correlate clinically. Not valid for medicolegal purpose.

# YASHFEEN IMAGING & RADIOLOGY DEPARTMENT

MANAGED BY :- YASHFEEN FOUNDATION

VIRAVAL, NAVSARI. 396 445. PHONE : (H) (02637) 235725

Website : [www.yashfeenhospital.in](http://www.yashfeenhospital.in) E-mail : [info@yashfeenhospital.in](mailto:info@yashfeenhospital.in)

Name	ABEY J	Age	31Y/M
Ref by Dr	SELF	Date	25/02/2023

## USG ABDOMEN (SCREENING)

**Liver** appears normal in size & shape with normal echopattern.  
No e/o focal or diffuse lesion. IHBR appear normal.  
PV and CBD appear normal.

**Gall bladder** appears distended & normal in shape & size. No e/o calculus or mass seen.  
Walls appear normal.

**Pancreas** appears normal in size and echogenicity. No e/o focal or diffuse lesion.

**Spleen** appears normal in size and shows normal echopattern. No e/o focal lesion.

**Both Kidneys** appear normal in size and echopattern. CM Differentiation is preserved.  
4 x 5.2 cm in size simple cortical cyst noted in right lower pole.  
No e/o calculus or hydronephrosis on either side.  
Perirenal spaces appear normal on either side.  
Suprarenal regions appear normal on either side.

**Bladder** is physiologically distended. No e/o calculus or mass. Walls appear normal.

**Prostate** appears normal in size & normal echopattern.  
No e/o calcification.

RIF region appears normal.

No e/o ascites.

### IMPRESSION:

Right renal simple cortical cyst.



Dr. DHARMESH DESAI

(M.D. Radiology)  
Dr. Dharmesh Desai  
Reg. No. 16 - 45284

YASHFEEN GROUP OF HOSPITAL

Please contact immediately for any typographical error.  
This is only professional opinion, not a final diagnosis. Kindly correlate clinically. Not valid for medicolegal purpose.



# YASHFEEN CARDIAC HOSPITAL

## EYE DEPARTMENT

Chief Complaint : *blurring vision on Computer Screen (General)*

Medical History : DM / HT / Asthama / Allergy / Heart / Thyroid / .

Ocular History :

Visual Acuity : *VN < 6/6  
6/6*


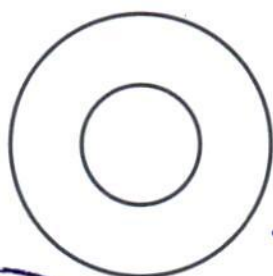
IOP :

NAME /  
25\_FEB\_2023 PM 01:35  
NO. 6559  
SN: 4771998  
REF. DATA  
VD: 12.00 CYL: MIX  
<R> S C A  
- 0.00  
- 0.00 - 0.25 172  
- 0.25  
- 0.00  
S. E. - 0.00  
<L> S C A  
- 0.00  
- 0.00  
- 0.00  
- 0.00  
S. E. - 0.00  
PD: 59.0

	RIGHT EYE (PH.....)				LEFT EYE (PH.....)			
	Sph.	Cyl.	Axis	V/A	Sph.	Cyl.		
Distance	<i>Pl</i>				<i>Pl</i>			
Near	<i>Pl</i>				<i>Pl</i>			

Distance/Reading/Bi-Focal/Progressive/Separate Glasses

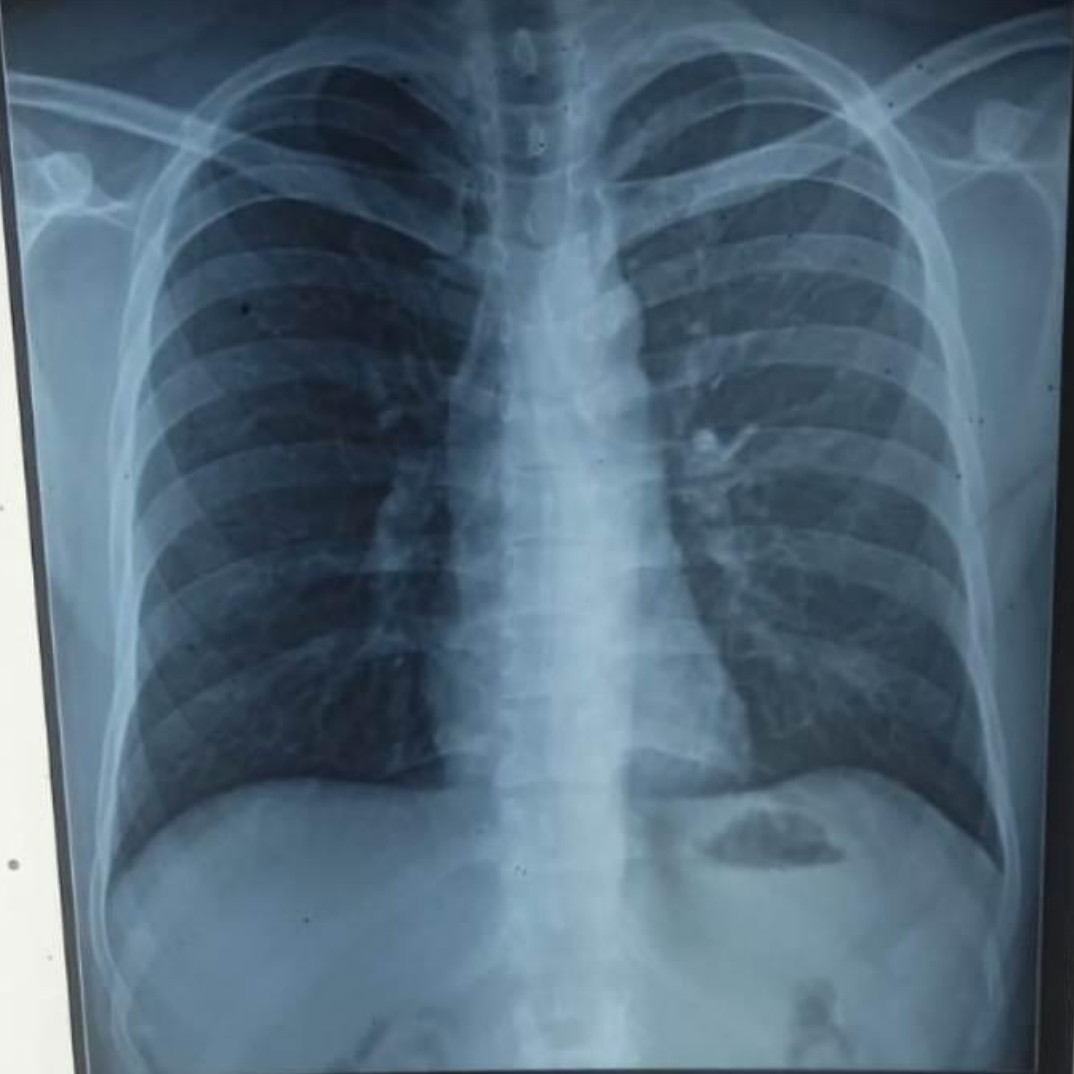
Sle :



*R  
L  
Eulub Resim  
oo  
2*



*my*



CH22047912 ABEY J 31Y 2502231717 CHEST PA 25-02-2023  
YASHFEEN GROUP OF HOSPITALS NAVSARI PH:9924047789