



भारतीय विशिष्ट पहचान प्राधिकरण
भारत सरकार
 Unique Identification Authority of India
Government of India

नामांकन क्रम / Enrollment No.: 2043/97011/03101

To
 संगीता झां
 Sangita Jha
 RITHANI KAILASH PURI
 MEERUT
 Meerut
 I. E. Partapur
 Meerut Meerut
 Uttar Pradesh 250103
 9997614467

19/02/2014
 121026996



ML210269968FT



Sangeeta Jha

आपका आधार क्रमांक / Your Aadhaar No. :

4564 6341 0796

आधार - आम आदमी का अधिकार



भारत सरकार
 Government of India



संगीता झां
 Sangita Jha
 जन्म तिथि / DOB : 07/03/1993
 महिला / Female

[Signature]




Dr. NITIN AGARWAL
 MBBS, MD
 Regn. No. DMC-R-1436

4564 6341 0796

आधार - आम आदमी का अधिकार

ONEPLUS ULTRASOUND LAB
 47, Harsh Vihar, Pitam Pura,
 Delhi-110034
 Ph. 011-42480101, 9599913051
 E-mail: oneplusul@gmail.com



Sangeeta Jha



Dr. NITIN AGARWAL
MBBS, MD
Regn. No. DMC-R-1436

ONEPLUS ULTRASOUND LAB
47, Harsh Vihar, Pitam Pura,
Delhi-110034
Ph. 011-42480101, 9599913051
E-mail: oneplusul@gmail.com



ONEPLUS ULTRASOUND LAB

47, HARSH VIHAR, PITAMPURA, DELHI- 110034

Ms. SANGEETA JHA
 Age : 29/F
 Ref. by : MEDIWHEEL
 Indication1 :
 Indication2 :
 Indication3 :
 COMMENTS : Normal ECG.

ID : 1924
 HWM : 147/59
 Recorded : 25-3-2022 10:34
 Medication1 :
 Medication2 :
 Medication3 :

BPM : 90
 BP : 130/88
 P Axis : 61 deg
 QRS Axis : 78 deg
 T Axis : 35 deg

P duration : 80 msec
 PR duration : 126 msec
 QRS duration : 96 msec
 QT interval : 290 msec
 QTc interval : 342 msec

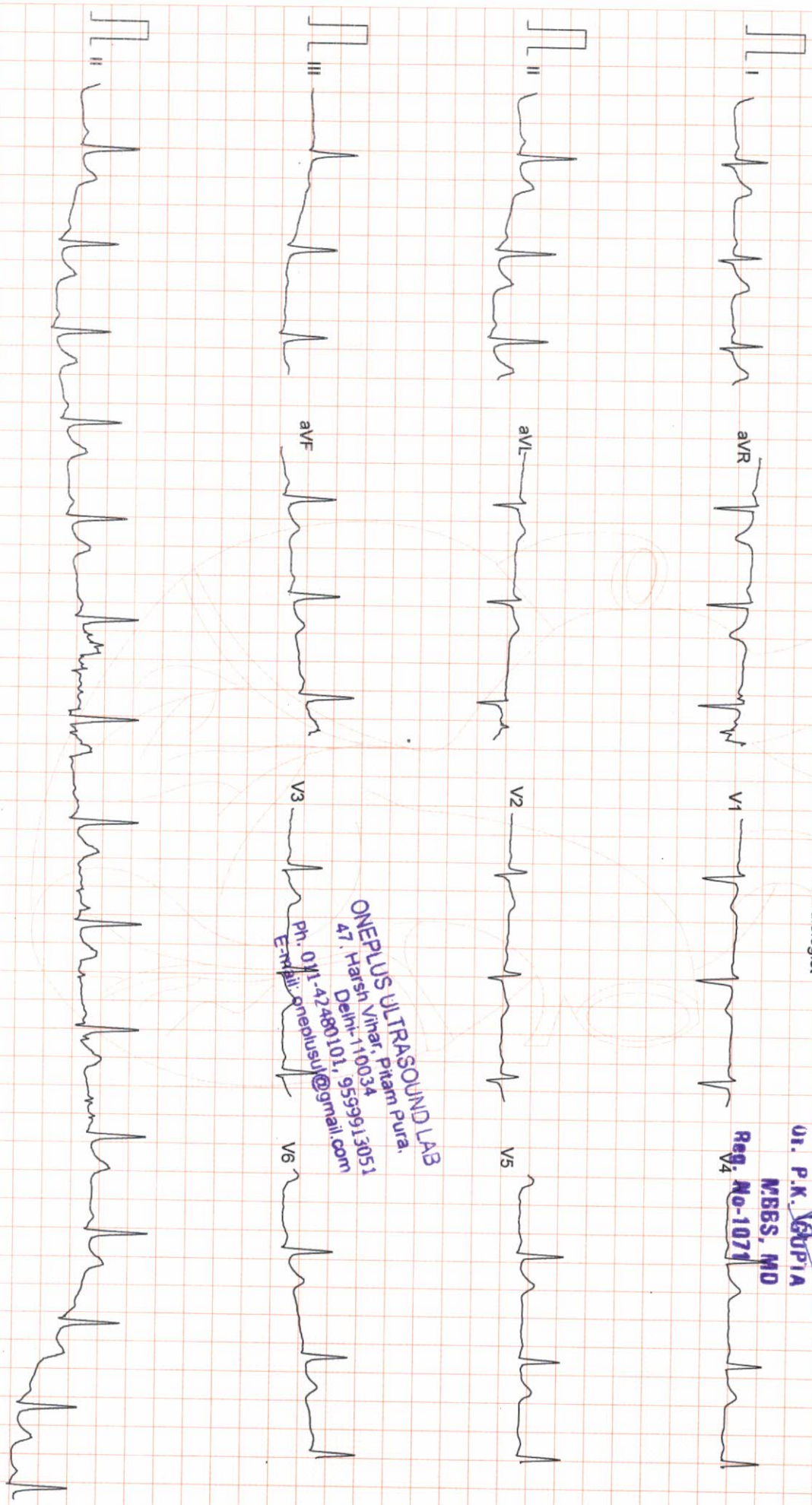
Sangeeta Jha

Unconfirmed Report Reviewed By:
 Cardiologist

Raw E.C.G.(Seq)

Dr. P.K. Gupta
Dr. P.K. GUPTA
MBBS, MD
Reg. No-1071
V4

ONEPLUS ULTRASOUND LAB
 47, Harsh Vihar, Pitam Pura,
 Delhi-110034
 Ph: 011-42480101, 9559913051
 Email: oneplusul@gmail.com



Filtered

25mm/sec 10mm/mV



CardiCom, INDIA

ONEPLUS ULTRASOUND LAB

47, HARSH VIHAR PITAMPURA DELHI 110034

ID : 993

HWMT : 147/59

Recorded : 25-3-2022 10:37

TREADMILL TEST SUMMARY REPORT
Protocol: BRUCE

History:

Medication1 :

Medication2 :

Medication3 :

Ms. SANGEETA JHA
Age : 29/F
Ref. by : MEDIWHEEL
Indication1 :
Indication2 :
Indication3 :

PHASE	PHASE TIME	STAGE TIME	SPEED (Km/Hr.)	GRADE (%)	H.R. (BPM)	B.P. (mmHg)	RPP X100	II	ST LEVEL (mm) V2	V5	METS
SUPINE											
STANDING											
STAGE 1	2:59	2:59	2.70	10.00	91	130/88	118	-0.1	0.0	0.2	4.80
STAGE 2	5:59	2:59	4.00	12.00	95	130/88	123	-0.1	0.0	0.2	7.10
STAGE 3	6:59	0:59	5.40	14.00	117	144/90	168	-0.6	-0.2	-0.1	8.06
PEAK EXER	7:05	1:05			133	154/92	204	-1.2	-0.6	-0.5	8.06
RECOVERY	7:05				166	166/94	275	-1.9	-0.8	-0.9	8.06
	2:59	2:59	0.00	0.00	168	166/94	278	-1.8	-0.9	-0.9	8.15
					85	132/88	112	-1.0	-0.4	-0.6	

RESULTS

Exercise Duration : 7.05 Minutes
 Max Heart Rate : 168 bpm 87 % of target heart rate 191 bpm
 Max Blood Pressure : 166/94 mmHg
 Max Work Load : 8.15 METS
 Reason of Termination :

Negative for isch. risk

ONEPLUS ULTRASOUND LAB
 47, Harsh Vihar, Pitam Pura,
 Delhi-110034
 Ph. 011-42480101, 9559913051
 E-mail: oneplusul@gmail.com

Sangeeta Jha

[Signature]

Capdiplogupta
Dr. MBBS. MD
Reg. No-1071

ONEPLUS ULTRASOUND LAB

SUPINE
PRETEST

ST @ 10mm/mV
80ms PostU

Ms. SANGEETA JHA

ID : 993

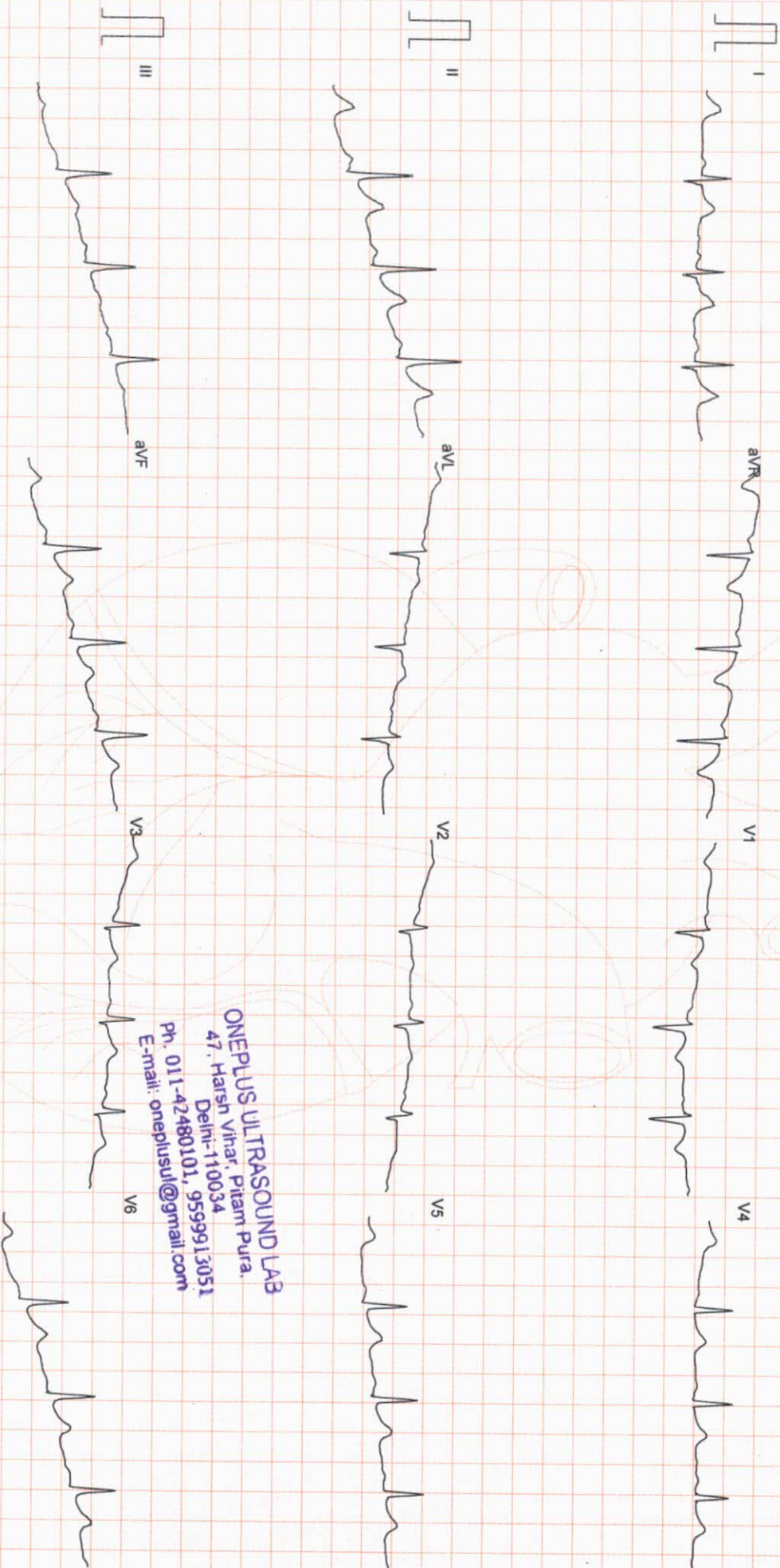
AGE/SEX : 29/F

RECORDED : 25-3-2022 10:37

RATE : 91 BPM

B.P. : 130/88 mmHg

RAW E.C.G.



ONEPLUS ULTRASOUND LAB
47, Harsh Vihar, Pitam Pura,
Delhi-110034
Ph. 011-42480101, 9599913051
E-mail: onepiusul@gmail.com

Filtered

25mm/sec 10mm/mV

CardiCom, INDIA Ph.:091-731-2620740, TeleFax:091-731-2431214

ONEPLUS ULTRASOUND LAB

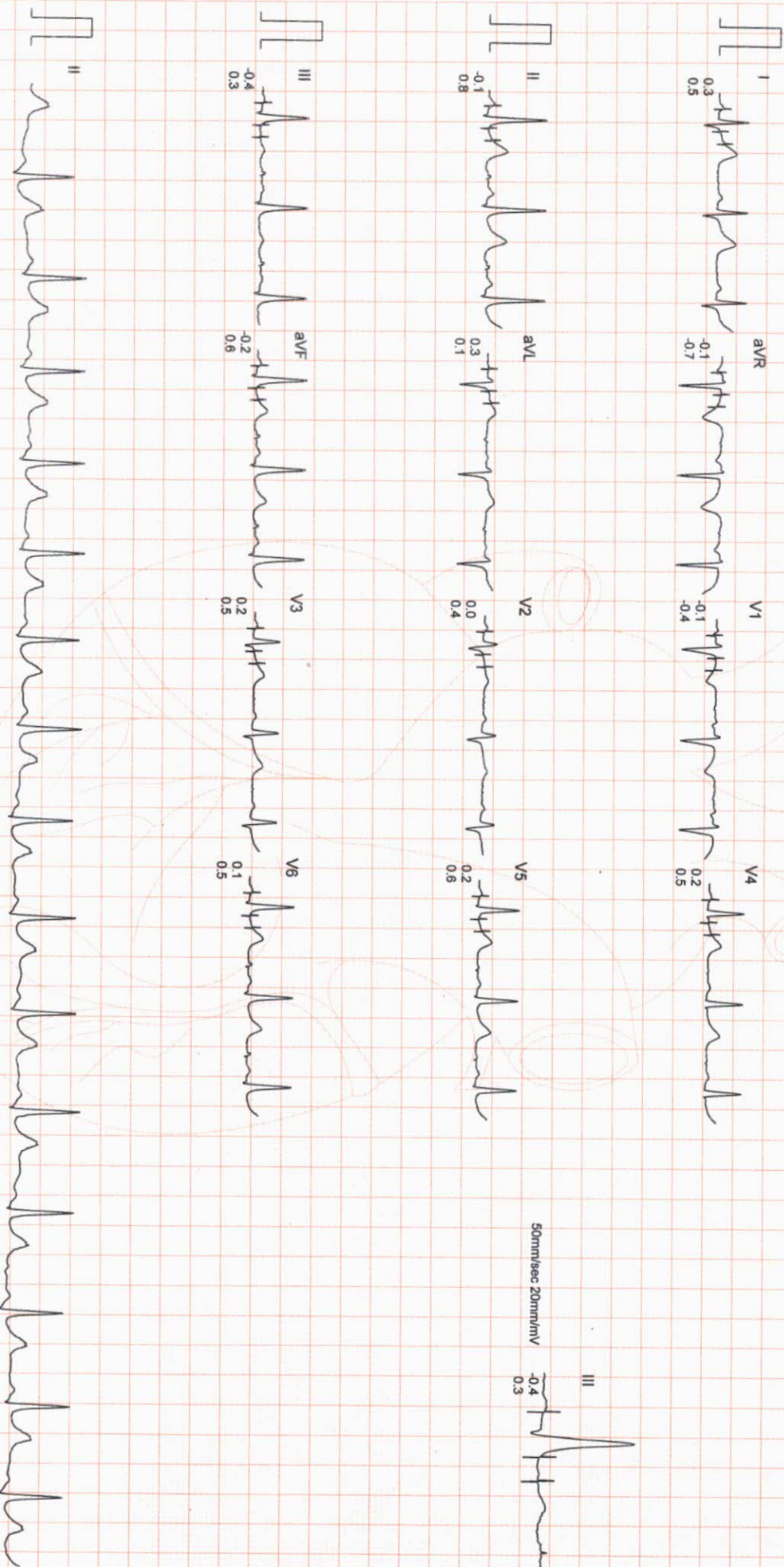
STANDING
PRETEST

ST @ 10mm/mV
80ms PostJ


Ms. SANGEETA JHA
I.D. : 993
AGE/SEX : 29/F
RECORDED : 25-3-2022 10:37

RATE : 95 BPM
B.P. : 130/88 mmHg

LINKED MEDIAN



50mm/Sec 20mm/mV



Filtered

Computer Corrected Baseline

25mm/Sec 10mm/mV

ONEPLUS ULTRASOUND LAB
47, Harsh Vihar, Pitam Pura,
Delhi-110034
Ph. 011-42480101, 9599913051
E-mail: oneplusul@gmail.com
CardCom, INDIA Ph.:091-731-2620740, TeleFax:091-731-2431214

ARTIV

Ph. 091-731-2620740, TeleFax:091-731-2431214

ONEPLUS ULTRASOUND LAB

Ms. SANGEETA JHA

I.D. : 993

AGE/SEX : 29/F

RECORDED : 25-3-2022 10:37

RATE : 117 BPM

B.P. : 144/90 mmHg

BRUCE

EXERCISE 1

PHASE TIME : 2:59

STAGE TIME : 2:59

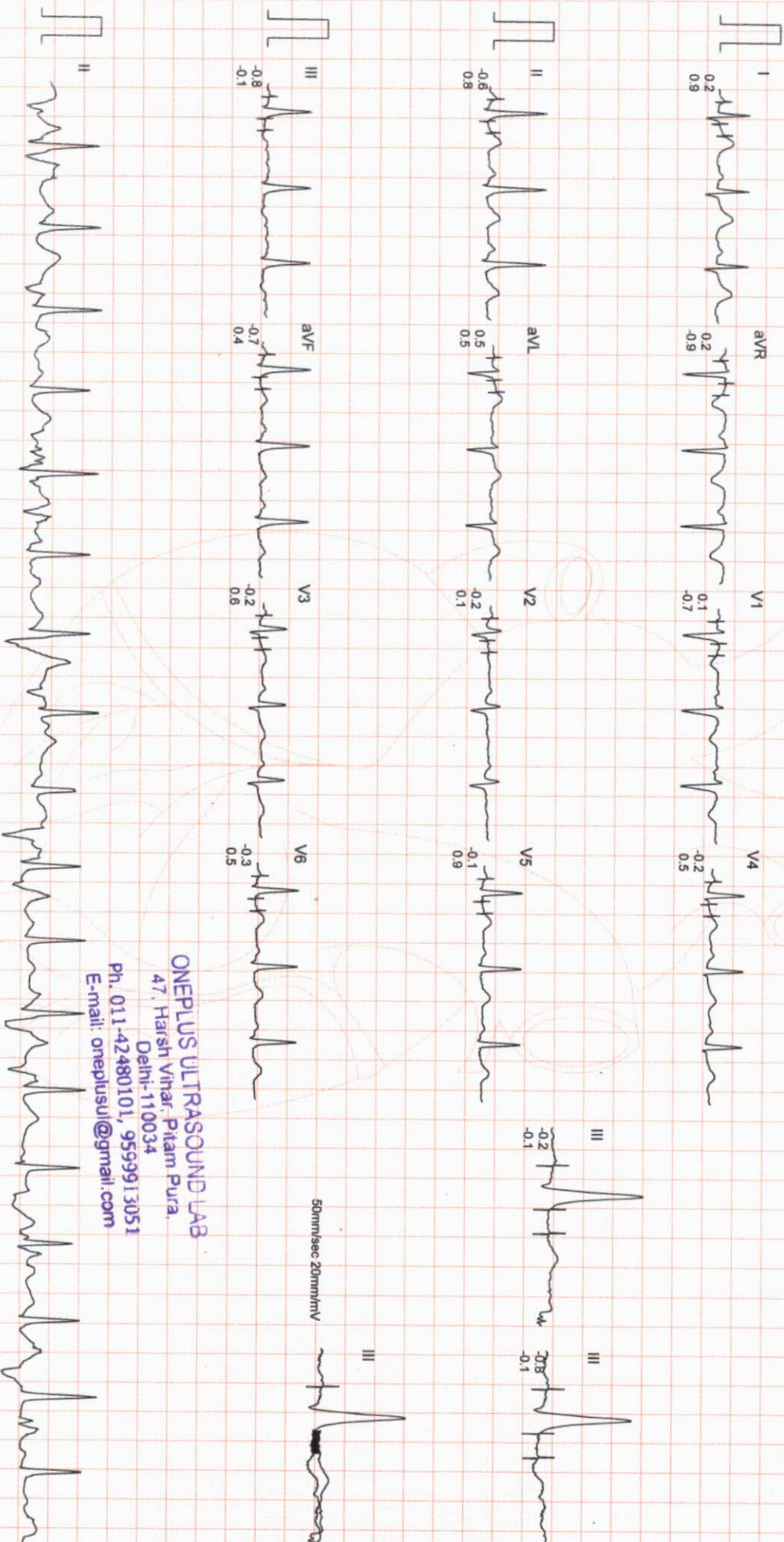
ST @ 10mm/mV

80ms PostU

SPEED : 2.7 Km./Hr.

GRADE : 10.0 %

LINKED MEDIAN



ONEPLUS ULTRASOUND LAB
47, Harsh Vihar, Pitam Pura,
Delhi-110034
Ph. 011-42480101, 9599913051
E-mail: oneplusul@gmail.com

50mm/sec 20mm/mV



Filtered

Computer Corrected Baseline

25mm/sec 10mm/mV

CardiCom, INDIA Ph.:091-731-2620740, TeleFax:091-731-2431214

ONEPLUS ULTRASOUND LAB

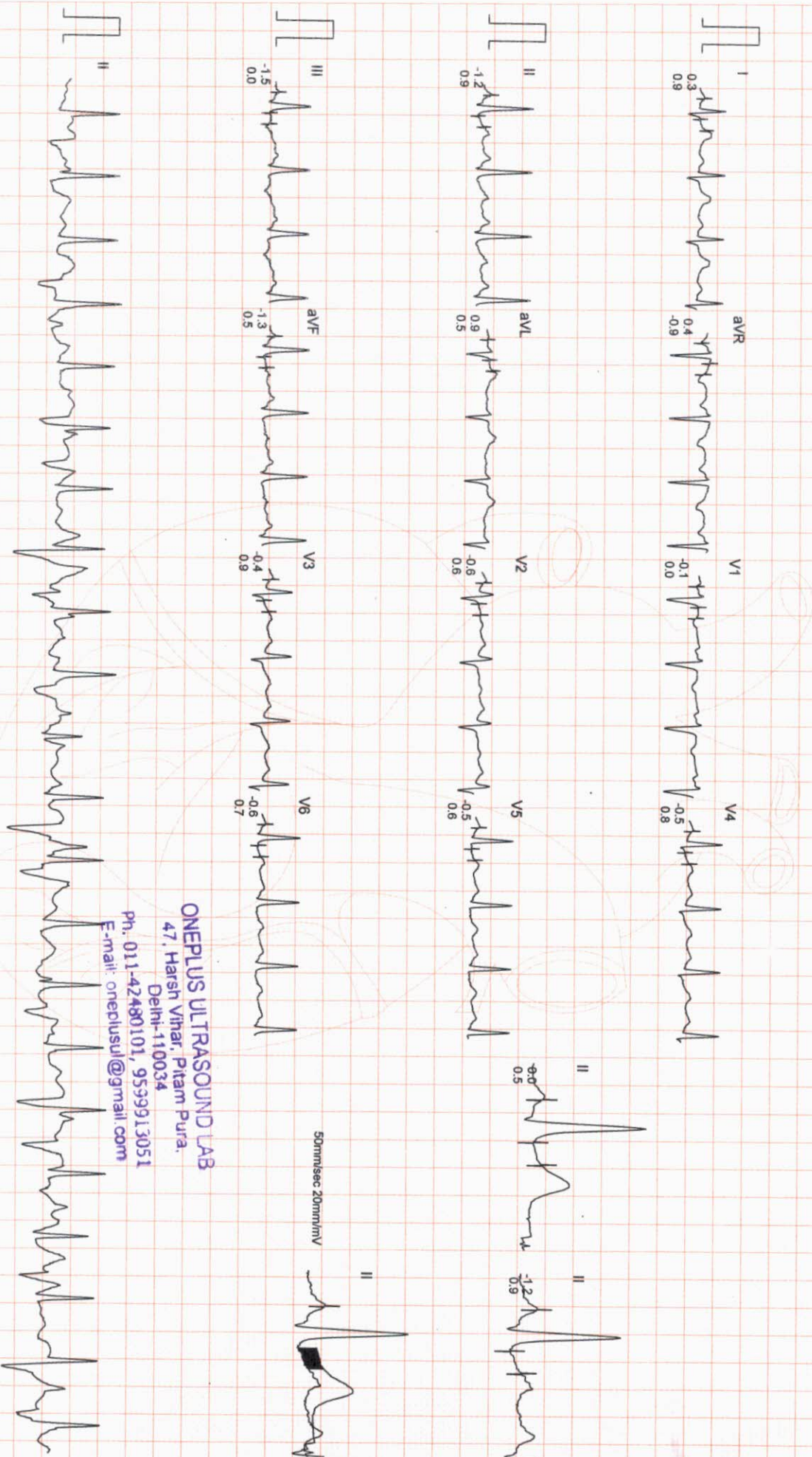
Ms. SANGEETA JHA
I.D. : 993
AGE/SEX : 29/F
RECORDED : 25-3-2022 10:37

RATE : 133 BPM
B.P. : 154/92 mmHg

BRUCE
EXERCISE 2
PHASE TIME : 5:59
STAGE TIME : 2:59

ST @ 10mm/mV
80ms PostJ
SPEED : 4.0 Km./Hr.
GRADE : 12.0 %

LINKED MEDIAN



ONEPLUS ULTRASOUND LAB
47, Harsh Vihar, Pitam Pura,
Delhi-110034
Ph. 011-42480101, 9539913051
E-mail: oneplusul@gmail.com

Filtered Computer Corrected Baseline 25mm/sec 10mm/mV Cardicor, INDIA Ph.:091-731-2620740, Tele/Fax:091-731-2431214

ONEPLUS ULTRASOUND LAB

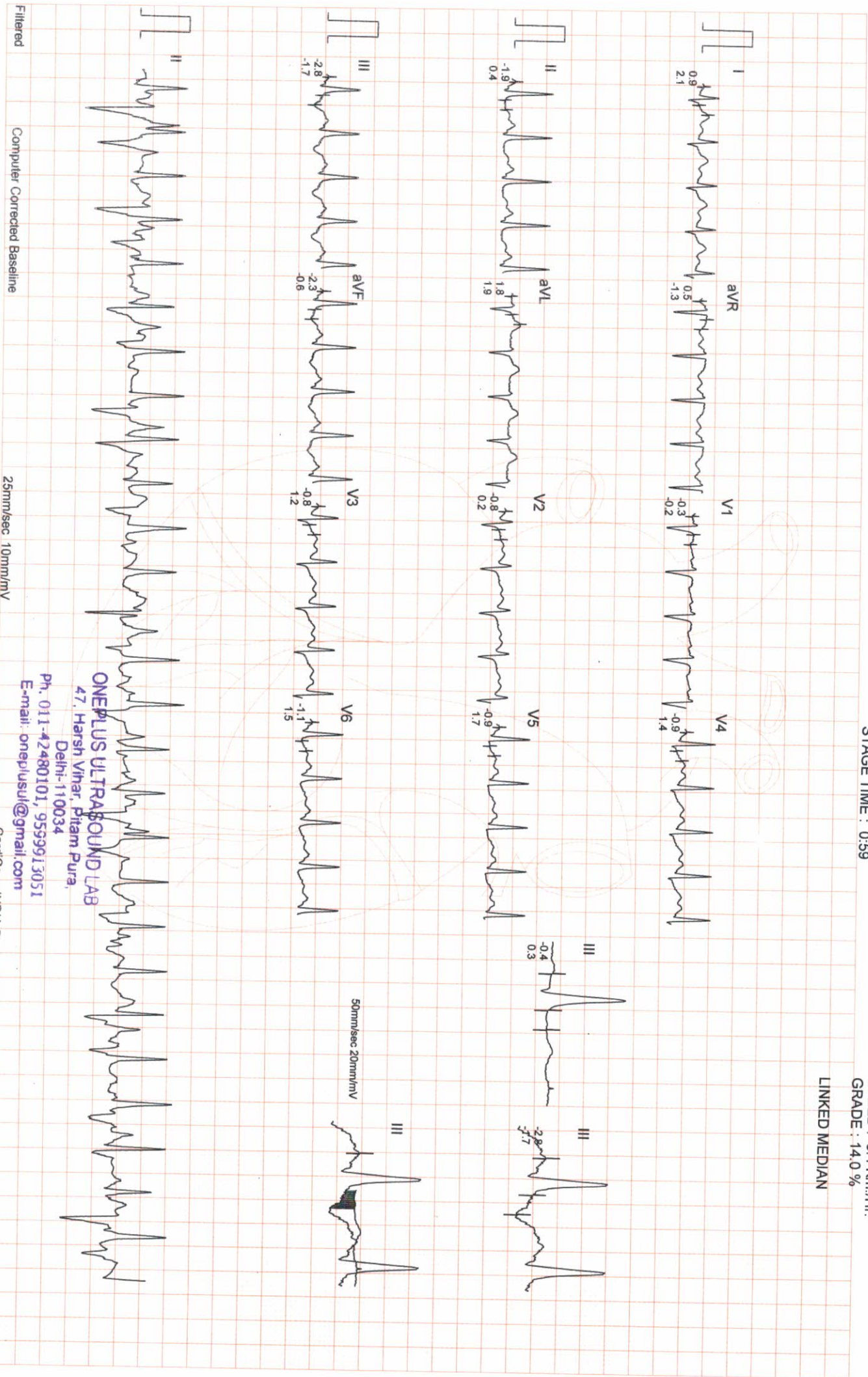
Ms. SANGEETA JHA
I.D. : 993
AGE/SEX : 29/F
RECORDED : 25-3-2022 10:37

RATE : 166 BPM
B.P. : 166/94 mmHg

BRUCE
EXERCISE 3
PHASE TIME : 6:59
STAGE TIME : 0:59

ST @ 10mm/mV
80ms PostJ
SPEED : 5.4 Km./Hr.
GRADE : 14.0 %

LINKED MEDIAN



Filtered Computer Corrected Baseline 25mm/sec 10mm/mV

ONEPLUS ULTRASOUND LAB
47, Harsh Vihar, Pitam Pura,
Delhi-110034
Ph. 011-42480101, 9559913051
E-mail: oneplusul@gmail.com

CardiCom, INDIA Ph.:091-731-2620740, TeleFax:091-731-2431214

ONEPLUS ULTRASOUND LAB

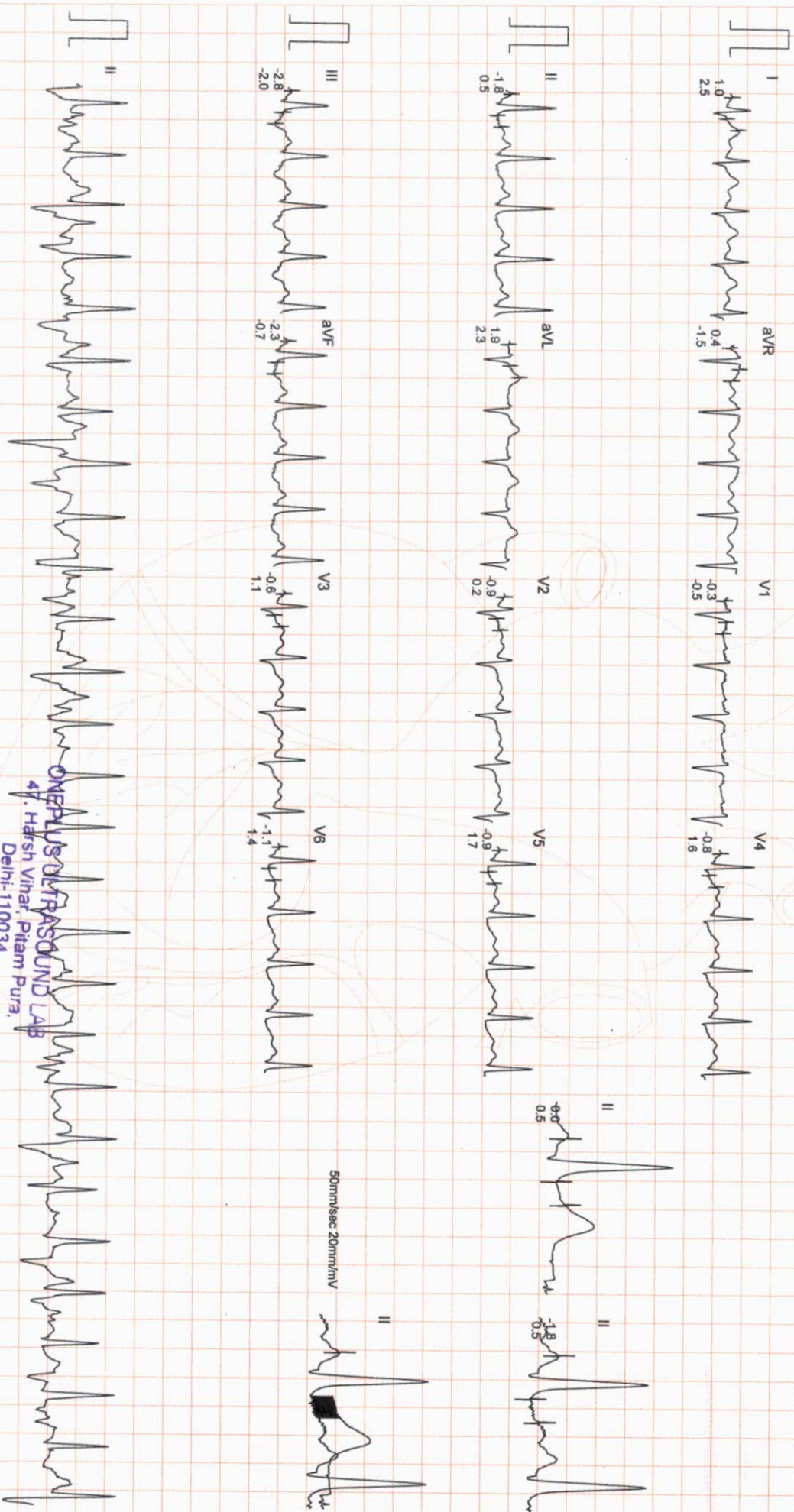Ms. SANGEETA JHA
I.D. : 993
AGE/SEX : 29/F
RECORDED : 25-3-2022 10:37

RATE : 168 BPM
B.P. : 166/94 mmHg

BRUCE
PEAK EXER
PHASE TIME : 7:05
STAGE TIME : 1:05

ST @ 10mm/mV
80ms PostJ
SPEED : 5.4 Km./hr.
GRADE : 14.0 %

LINKED MEDIAN



Filtered Computer Corrected Baseline 25mm/sec 10mm/mV

ONEPLUS ULTRASOUND LAB
4/F, Harsh Vihar, Pitam Pura,
Delhi-110034
Ph: 011-42480101, 9599913051
E-mail: oneplusul@gmail.com

CardiCom, INDIA Ph.:091-731-2620740, TeleFax:091-731-2431214

ONEPLUS ULTRASOUND LAB

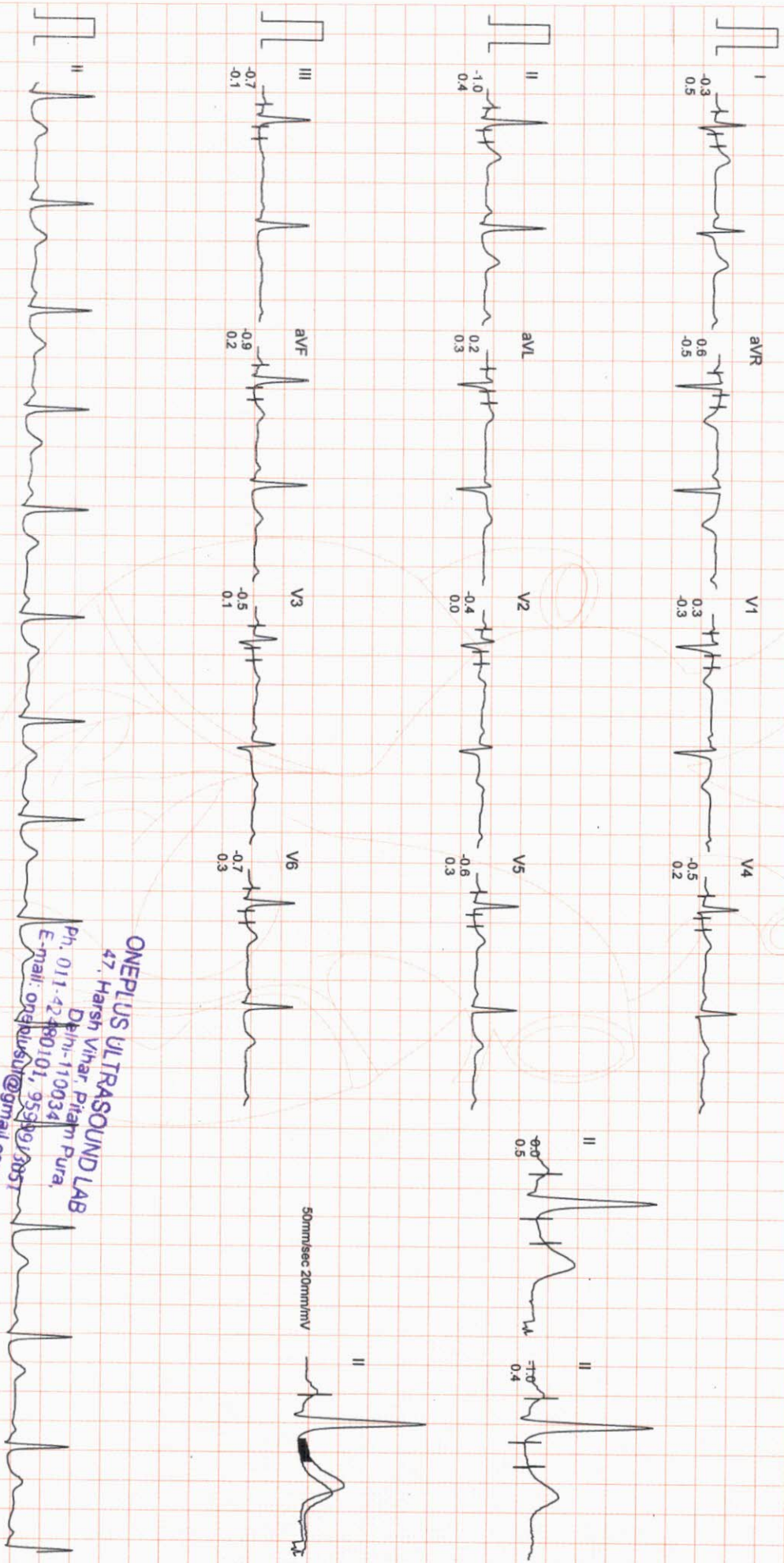
Ms. SANGEETA JHA
 ID : 993
 AGE/SEX : 29/F
 RECORDED : 25-3-2022 10:37

RATE : 85 BPM
 B.P. : 132/88 mmHg

BRUCE
 RECOVERY
 PHASE TIME : 2:59

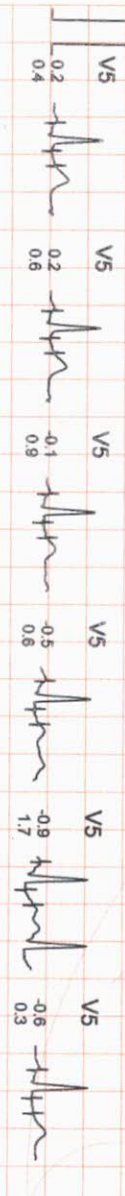

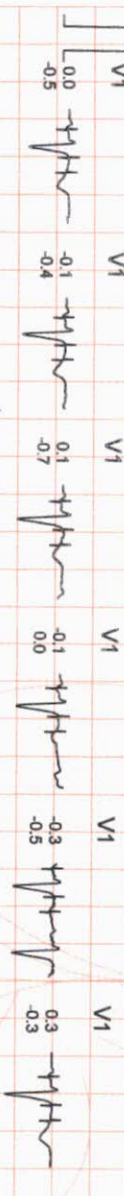



ST @ 10mm/mV
 80ms PostJ
 SPEED : 0.0 Km./Hr.
 GRADE : 0.0 %

LINKED MEDIAN





ONEPLUS ULTRASOUND LAB
 47, Harsh Vihar, Pitam Pura,
 Delhi-110034
 Ph: 011-42480101, 9539913857
 E-mail: onepplusul@gmail.com

STAGE	STAGE 1	STAGE 2	PEAK EXERCISE	RECOVERY
SUPINE	STANDING			
0.0Kmph 0.0% 91 bpm B.P. 130/88 80ms PostU	0.0Kmph 0.0% 95 bpm B.P. 130/88 80ms PostU	2:59 2:59 2:59 4.0Kmph 12.0% 133 bpm B.P. 154/92 80ms PostU	7:05 1:05 5.4Kmph 14.0% 168 bpm B.P. 166/94 80ms PostU	2:59 0.0Kmph 0.0% 85 bpm B.P. 132/88 80ms PostU





ONEPLUS ULTRASOUND LAB
 47, Harsh Vihar, Pitam Pura,
 Delhi-110034
 Ph. 011-42480101, 9539913051
 E-mail: oneplusul@gmail.com

STANDING
0.0Kmph
0.0%
95 bpm
B.P. 130/88
80ms PostJ

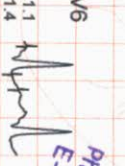



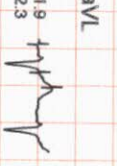


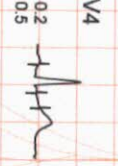


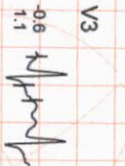








PEAK EXERCISE
7:05
1:05
5.4Kmph
14.0%
168 bpm
B.P. 166/94
80ms PostJ

STANDING
0.0Kmph
0.0%
95 bpm
B.P. 130/88
80ms PostJ



PEAK EXERCISE
7:05
1:05
5.4Kmph
14.0%
168 bpm
B.P. 166/94
80ms PostJ



ONEPLUS ULTRASOUND LAB
47, Harsh Vihar,
Delhi-110034
Ph. 011-42480101, 9539913051
E-mail: oneplusul@gmail.com



OnePLUS
Ultrasound Lab

— QUALITY FIRST... ALWAYS! —

Dr. Nitin Agarwal

Pathologist & Director
Ex. Sr. Res. MAMC
& Lok Nayak Hospital
Ex. Chief of Lab Dr. Lal Path Labs.

Dr. Pooja (Garg) Agarwal

Radiologist & Director
MAMC & Lok Nayak Hospital

Name	: Mrs. SANGEETA JHA	Age/Sex	: 29 YRS/Female
Ref. By	: Dr. MEDIWHEEL	Lab No	: 012203250008
Date	: 25-Mar-2022	Patient ID	: LSHHI93086

X-ray-Chest PA view

Bony cage and soft tissues are normal.
Cardiothoracic ratio is normal.
Mediastinum is normal.
Both hila are normal.
Both costophrenic angles are clear.
Both domes of diaphragm are normal.
Lung fields are clear. No parenchymal lesion seen.

IMPRESSION: Normal Study.


DR. POOJA GARG
RADIOLOGIST
REG NO- DMC/R/03398

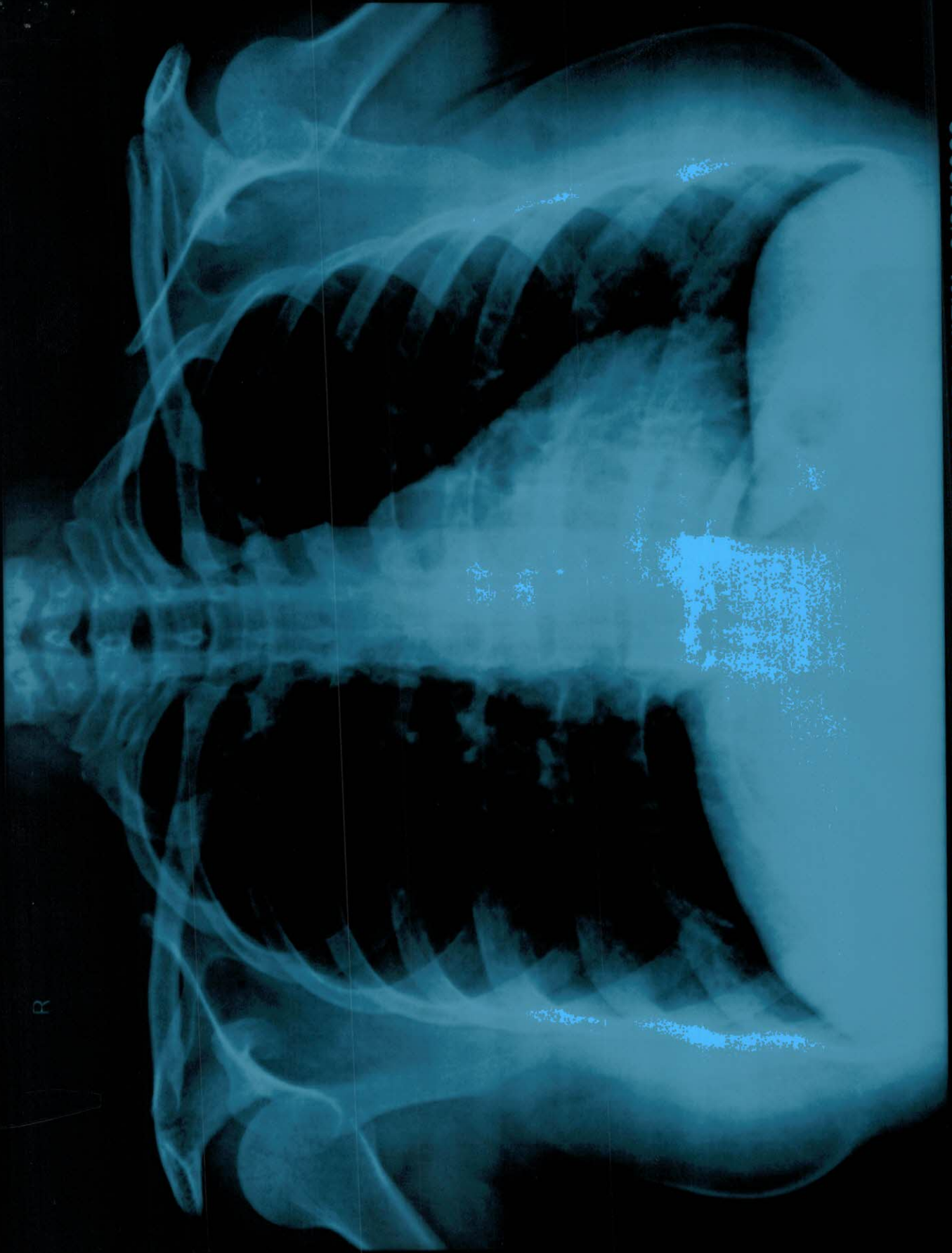
Dr. POOJA GARG
M.B.B.S., D.M.R.D.
Reg No. DMC/R/03398
Radiologist

Type By : darshita

47, Harsh Vihar, Pitampura, New Delhi-110034 | Ph.: 011-42480101, 9599913051
E-mail: oneplusul@gmail.com | Web.: www.oneplusul.in

Clinical correlation is essential for final diagnosis. • If test results are unsatisfactory please contact personally or on phone. • This report is for perusal of doctors only.
• All disputes Subject to Delhi Jurisdiction only. • Not for medicolegal purposes. • All congenital anomalies in a foetus may not be diagnosed in routine obstetric ultrasound.

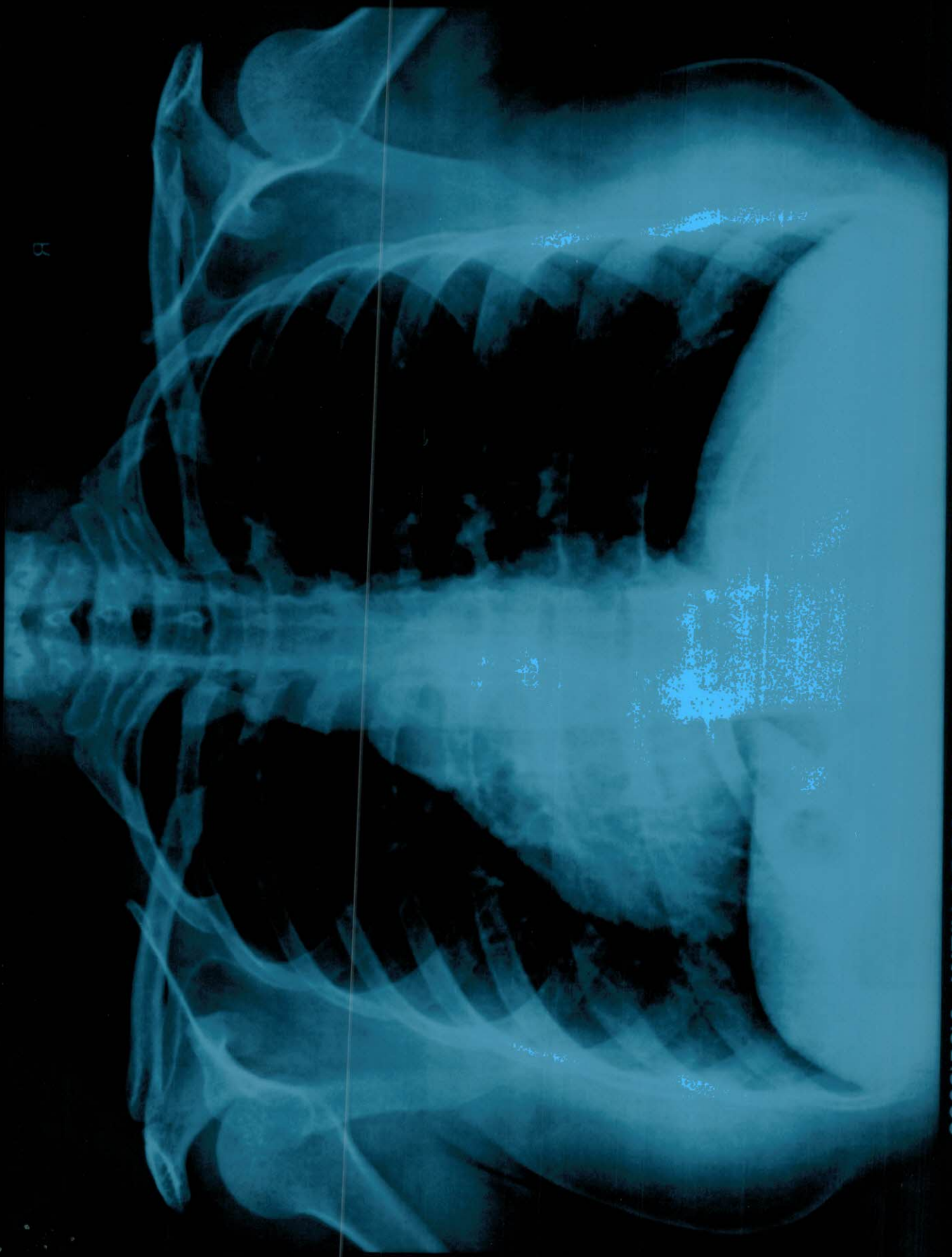
R



MRS.SANGEETA JHA 29 YRS 25-03-2022 F CHEST PA VIEW 3/25/2022

ONEPLUS ULTRASOUND LAB, 47 HARSH VIHAR, PITAMPURA

ONEPLUS ULTRASOUND LAB, 41-HARSH NIHAR, PITAMPURA
MRS. SANGEETA JHA 50 YRS 52-03-5055 F CHEST PA VIEW 3/52/5055



R

Name	: Mrs. SANGEETA JHA	Age/Sex	: 29 YRS/Female
Ref. By	: Dr. MEDIWHEEL	Lab No	: 012203250008
Date	: 25-Mar-2022	Patient ID	: LSHHI93086

ULTRASOUND EXAMINATION----WHOLE ABDOMEN

Liver is enlarged in size (16.7 cm) and normal in outline with normal echopattern. No abscess or mass lesion seen. Hepatic veins, portal vein, IVC and aorta are normal. Intrahepatic biliary radicles are not dilated. CBD is normal in caliber.

Gall bladder is well distended with anechoic lumen .Wall thickness is normal.

Both kidneys are normal in size, shape, position, outline and echopattern. Corticomedullary differentiation is maintained. No pelvicalyceal dilation or calculus or mass lesion is seen.

Spleen is normal in size and echotexture. No mass lesion seen.

Pancreas is normal in size, outline and echotexture .

Urinary bladder is normal in shape and position. No evidence of intravesical stone or mass seen.

Uterus is normal in size (measures 6.7 x 4.5 x 3.4 cm), shape, position and echopattern. No mass seen.


Uterine cavity is empty. **Endometrial thickness** is 6.9 mm.

Both ovaries appear normal in size, shape and echopattern. No tubo-ovarian mass seen.

No abnormal bowel wall thickening seen in right iliac fossa.
No mass or free fluid seen anywhere in abdomen.

IMPRESSION: Mild hepatomegaly.

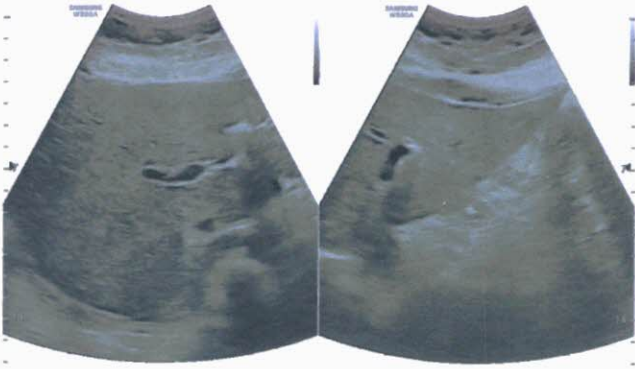Type By : darshita


DR. POOJA GARG
RADIOLOGIST
REG. NO. DMC/R/03398
M.B.B.S., D.M.R.D
Reg No. DMC/R/03398
Radiologist

47, Harsh Vihar, Pitampura, New Delhi-110034 | Ph.: 011-42480101, 9599913051
E-mail: oneplusul@gmail.com | Web.: www.oneplusul.in

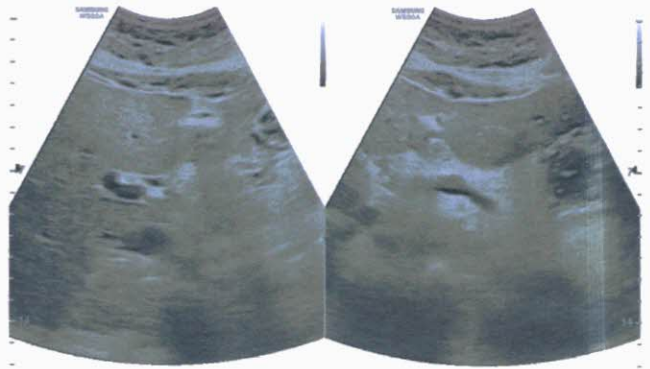
W880A MRS SANGEETA 29/F OnePlus Ultrasound Lab MI 1.5 25-03-2022
CA1-7A / Abdomen / FR 24Hz Tib0.1 11:01:14 AM

2D G58 DR130 FA11 P100 Frq Pen. 18.0cm 2D G58 DR130 FA11 P100 Frq Pen. 18.0cm



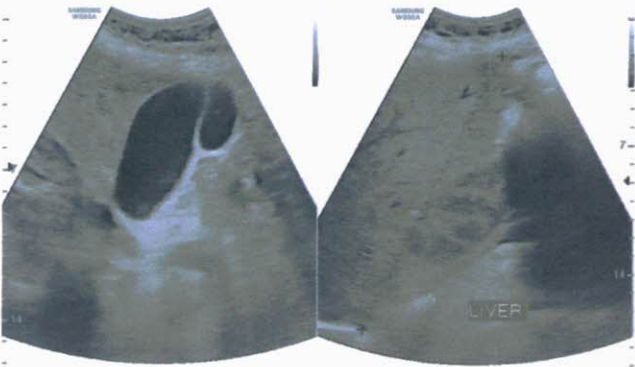
W880A MRS SANGEETA 29/F OnePlus Ultrasound Lab MI 1.5 25-03-2022
CA1-7A / Abdomen / FR 24Hz Tib0.1 11:01:25 AM

2D G58 DR130 FA11 P100 Frq Pen. 18.0cm 2D G58 DR130 FA11 P100 Frq Pen. 18.0cm



W880A MRS SANGEETA 29/F OnePlus Ultrasound Lab MI 1.5 25-03-2022
CA1-7A / Abdomen / FR 21Hz Tib0.1 11:01:46 AM

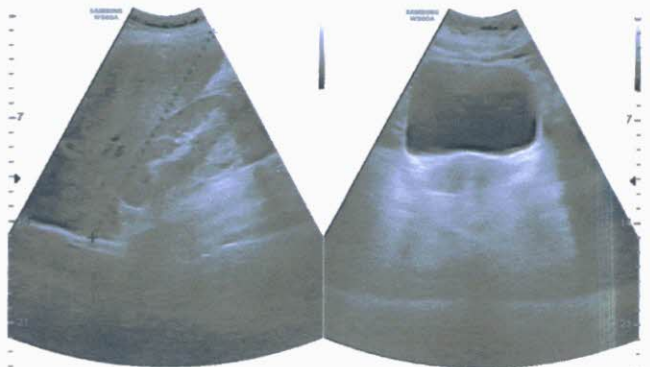2D G58 DR130 FA11 P100 Frq Pen. 18.0cm 2D G58 DR130 FA11 P100 Frq Pen. 18.0cm



D1 16.73 cm

W880A MRS SANGEETA 29/F OnePlus Ultrasound Lab MI 1.5 25-03-2022
CA1-7A / Abdomen / FR 17Hz Tib0.2 11:02:28 AM

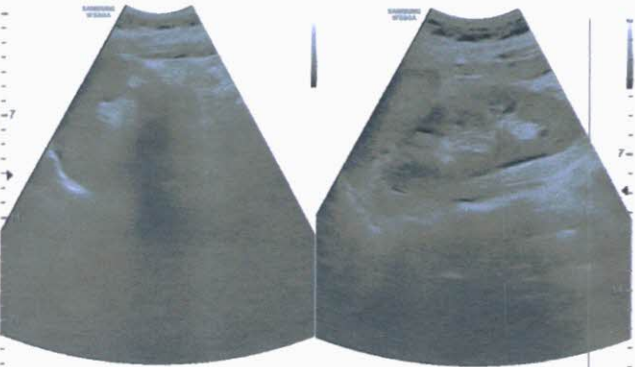2D G58 DR130 FA11 P100 Frq Pen. 24.0cm 2D G58 DR130 FA11 P100 Frq Pen. 24.0cm



D1 16.18 cm

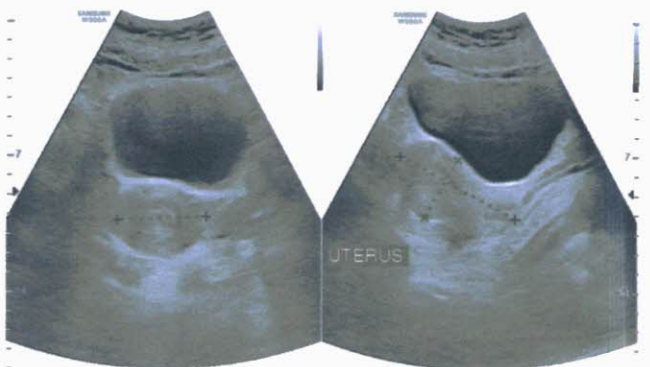
W880A MRS SANGEETA 29/F OnePlus Ultrasound Lab MI 1.5 25-03-2022
CA1-7A / Abdomen / FR 22Hz Tib0.1 11:02:39 AM

2D G58 DR130 FA11 P100 Frq Pen. 24.0cm 2D G58 DR130 FA11 P100 Frq Pen. 18.0cm



W880A MRS SANGEETA 29/F OnePlus Ultrasound Lab MI 1.5 25-03-2022
CA1-7A / Abdomen / FR 22Hz Tib0.1 11:03:05 AM

2D G50 DR130 FA11 P100 Frq Pen. 18.0cm 2D G50 DR130 FA11 P100 Frq Pen. 18.0cm

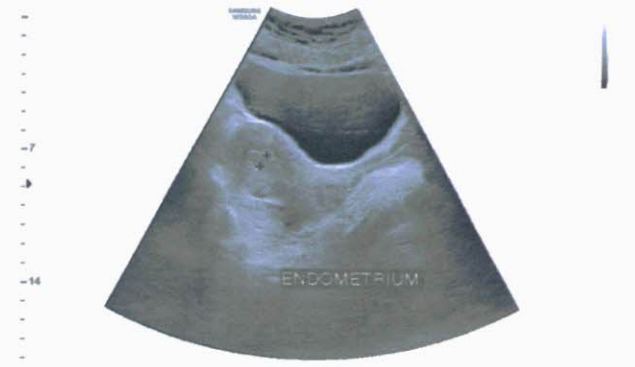

D3 4.55 cm

D1 6.70 cm
D2 3.39 cm

W880A MRS SANGEETA 29/F OnePlus Ultrasound Lab MI 1.5 25-03-2022
CA1-7A / Abdomen / FR 22Hz Tib0.1 11:03:15 AM

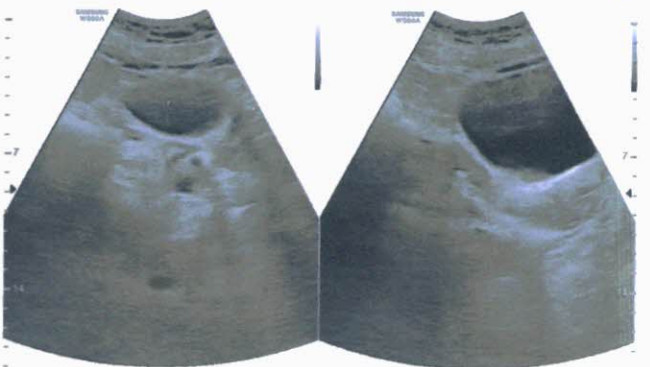
2D G52 DR130 FA11 P100 Frq Pen. 18.0cm



D1 0.69 cm

W880A MRS SANGEETA 29/F OnePlus Ultrasound Lab MI 1.5 25-03-2022
CA1-7A / Abdomen / FR 22Hz Tib0.1 11:03:25 AM

2D G48 DR130 FA11 P100 Frq Pen. 18.0cm 2D G48 DR130 FA11 P100 Frq Pen. 18.0cm





OnePLUS Ultrasound Lab

QUALITY FIRST... ALWAYS!

Dr. Nitin Agarwal
Pathologist & Director
Ex. Sr. Res. MAMC
& Lok Nayak Hospital
Ex. Chief of Lab Dr. Lal Path Labs.

Dr. Pooja (Garg) Agarwal
Radiologist & Director
MAMC & Lok Nayak Hospital



NAME	:Mrs. SANGEETA JHA	Barcode No	:10115977
AGE/GENDER	:29 YRS/Female	SPECIMEN DATE	:25/Mar/2022 08:59AM
PATIENT ID	:93086	SPECIMEN RECEIVED	:25/Mar/2022 09:14AM
REFERRED BY	:Dr. MEDIWHEEL	REPORT DATE	:25/Mar/2022 03:14PM
CENTRE NAME	:ONEPLUS ULTRASOUND LAB	LAB NO.	:012203250008

Test Name	Result	Unit	Ref. Range
-----------	--------	------	------------

HAEMATOLOGY

Health checkup 2 Female

Glycosylated Hemoglobin (HbA1c)	5.2	%	Non Diabetic adults <5.7 Prediabetic (at risk) 5.7-6.4 Diabetes >6.4
--	-----	---	--

Estimated average blood glucose (eag) 103

Reference range (mg/dl):

90 - 120:Excellent control, 121 - 150:Good Control, 151 - 180:Average Control, 181 - 210:Action Suggested

>211:Panic value

BLOOD GROUP (ABO)	A
Rh typing	POSITIVE

NOTE :

- * Apart from major A,B,H antigens which are used for ABO grouping and Rh typing, many minor blood group antigens exist. Agglutination may also vary according to titre of antigen and antibody.
- * So before transfusion, reconfirmation of blood group as well as cross-matching is needed.
- * Presence of maternal antibodies in newborns, may interfere with blood grouping.
- * Auto agglutination (due to cold antibody, falciparum malaria, sepsis, internal malignancy etc.) may also cause erroneous result.

CBC

Haemoglobin	11.6	g/dl	11.5-15.0
Total Leucocyte Count	6390	/cumm	4000-10000
Differential leucocyte count			
Neutrophils	68.6	%	40-80
Lymphocyte	26.80	%	20-40
Monocytes	3.60	%	2-10
Eosinophils	0.8	%	1-6
Basophils	0.2	%	0-2
RBC Count	3.79	million/cumm	3.8-4.8

Checked By.

Dr. NITIN AGARWAL
MBBS, MD (Path)
DMC/R/01436
DR. NITIN AGARWAL
MBBS, MD (PATHOLOGIST)

47, Harsh Vihar, Pitampura, New Delhi-110034 | Ph.: 011-42480101, 9599913051

E-mail: oneplusul@gmail.com | Web.: www.oneplusul.in

Page 1 of 5



OnePLUS Ultrasound Lab

QUALITY FIRST... ALWAYS!

Dr. Nitin Agarwal
Pathologist & Director
Ex. Sr. Res. MAMC
& Lok Nayak Hospital
Ex. Chief of Lab Dr. Lal Path Labs.

Dr. Pooja (Garg) Agarwal
Radiologist & Director
MAMC & Lok Nayak Hospital



NAME	:Mrs. SANGEETA JHA	Barcode No	:10115977
AGE/GENDER	:29 YRS/Female	SPECIMEN DATE	:25/Mar/2022 08:59AM
PATIENT ID	:93086	SPECIMEN RECEIVED	:25/Mar/2022 09:14AM
REFERRED BY	:Dr. MEDIWHEEL	REPORT DATE	:25/Mar/2022 03:14PM
CENTRE NAME	:ONEPLUS ULTRASOUND LAB	LAB NO.	:012203250008

Test Name	Result	Unit	Ref. Range
PCV(Hematocrit)	36.4	%	36-46
MCV	96.1	fL	83-101
MCH	30.5	Pg	27-32
MCHC	31.7	G/dL	32-35
Platelet count	182000	/cumm	150000-450000
RDW-CV	14	%	11.4-14.0
ESR(WESTEGRENs METHOD)	16	mm/1hr	<20

BIOCHEMISTRY

<u>Blood sugar fasting</u>	96	mg/dL	70-110
<u>Blood sugar pp</u>	105	mg/dL	70.0-140.0
<u>Bun (blood urea nitrogen)</u>	12.60	mg/dl	7-18.7
<u>Uric acid, serum</u>	4.6	mg/dl	2.4-5.7
<u>Creatinine, serum</u>	0.61	mg/dl	0.50-0.9

LFT(LIVER FUNCTION TEST)

Bilirubin Total	0.86	mg/dl	0.1-1.2
Bilirubin Conjugated	0.37	mg/dl	0-0.4
Bilirubin Unconjugated	0.49	mg/dl	up to 0.7
SGOT (AST)	22	U/L	0-31
SGPT (ALT)	24	U/L	<34
Alkaline phosphatase	97	U/L	35-104
Gamma glutamyl transpeptidase	27	U/L	<39
Total Protein	6.9	gm/dl	6.60 - 8.70
Albumin	3.8	g/dL	3.8-5.1
Globulin	3.10	gm/dl	1.8-3.4
Albumin/Globulin Ratio	1.23		1.10 - 2.50

LIPID PROFILE

Cholesterol	202	mg/dl	50-200
Triglycerides	93	mg/dL	25-150

Checked By.

Dr NITIN AGARWAL
M B B S , MD (Path)
DMC/R/01436

DR. NITIN AGARWAL
MBBS,MD(PATHOLOGIST)

47, Harsh Vihar, Pitampura, New Delhi-110034 | Ph.: 011-42480101, 9599913051

E-mail: oneplusul@gmail.com | Web.: www.oneplusul.in

Page 2 of 5



OnePLUS

Ultrasound Lab

QUALITY FIRST... ALWAYS!

Dr. Nitin Agarwal
Pathologist & Director
Ex. Sr. Res. MAMC
& Lok Nayak Hospital
Ex. Chief of Lab Dr. Lal Path Labs.

Dr. Pooja (Garg) Agarwal
Radiologist & Director
MAMC & Lok Nayak Hospital



NAME	:Mrs. SANGEETA JHA	Barcode No	:10115977
AGE/GENDER	:29 YRS/Female	SPECIMEN DATE	:25/Mar/2022 08:59AM
PATIENT ID	:93086	SPECIMEN RECEIVED	:25/Mar/2022 09:14AM
REFERRED BY	:Dr. MEDIWHEEL	REPORT DATE	:25/Mar/2022 03:14PM
CENTRE NAME	:ONEPLUS ULTRASOUND LAB	LAB NO.	:012203250008

Test Name	Result	Unit	Ref. Range
HDL Cholesterol	48	mg/dL	30 - 70
LDL cholesterol	135	mg/dL	< 130
VLDL cholesterol	18.6	mg/dL	5-40
Cholesterol/HDL Ratio	4.2		Low Risk 3.3-4.97 Average Risk 4.4-7.1 Moderate Risk 7.1-11.0 High Risk >11.0
LDL/HDL Ratio	2.8		0 - 3.55

According to ATP III and NCEP guidelines

Parameter	Normal	Desirable	Borderline	High
Total cholesterol	<200	200-239		240
Triglycerides	<150	150-199	200-499	500
LDL	Optimal <100 Near Optimal 100-129	130-159	160-180	190
HDL	<40 : LOW 60 : HIGH			

ENDOCRINOLOGY

THYROID PROFILE(T3,T4,TSH)

Triiodothyronine total [t3]	0.72	ng/dl	0.52-1.9
Thyroxine total [t4]	8.90	µg/dl	4.8-11.6
TSH (Thyroid Stimulating Hormone)	4.30	µIU/ml	0.25-5.0

AGE WISE VARIATION IN TSH

AGE	TSH(µIU/ml)	AGE	TSH(µIU/ml)
1-4 weeks	1.00 - 19.0	16-20 yrs	0.25 - 5.0
1-12 mths	1.70 - 9.1	21 - 80 yrs	0.25 - 5.0
1-5 yrs	0.80 - 8.2	I st trimester	0.25 - 5.0
6-10 yrs	0.25 - 5.0	II nd trimester	0.50 - 5.0
11-15 yrs	0.25 - 5.0	II rd trimester	0.4 - 6.0

Checked By.

Dr. NITIN AGARWAL
MBBS, MD (Path)
DMC/R/01436
DR. NITIN AGARWAL
MBBS, MD (PATHOLOGIST)

47, Harsh Vihar, Pitampura, New Delhi-110034 | Ph.: 011-42480101, 9599913051

E-mail: oneplusul@gmail.com | Web.: www.oneplusul.in

Page 3 of 5

Clinical correlation is essential for final diagnosis. • If test results are unsatisfactory please contact personally or on phone. • This report is for perusal of doctors only. • All disputes Subject to Delhi Jurisdiction only. • Not for medicolegal purposes. • All congenital anomalies in a foetus may not be diagnosed in routine obstetric ultrasound.



OnePLUS Ultrasound Lab

— QUALITY FIRST... ALWAYS! —

Dr. Nitin Agarwal

Pathologist & Director
Ex. Sr. Res. MAMC
& Lok Nayak Hospital
Ex. Chief of Lab Dr. Lal Path Labs.

Dr. Pooja (Garg) Agarwal

Radiologist & Director
MAMC & Lok Nayak Hospital



NAME	:Mrs. SANGEETA JHA	Barcode No	:10115977
AGE/GENDER	:29 YRS/Female	SPECIMEN DATE	:25/Mar/2022 08:59AM
PATIENT ID	:93086	SPECIMEN RECEIVED	:25/Mar/2022 09:14AM
REFERRED BY	:Dr. MEDIWHEEL	REPORT DATE	:25/Mar/2022 03:14PM
CENTRE NAME	:ONEPLUS ULTRASOUND LAB	LAB NO.	:012203250008

Test Name	Result	Unit	Ref. Range
-----------	--------	------	------------

Reference ranges - Interpretation of Diagnostic tests - (Jacques Wallach)

1. Primary hypothyroidism is accompanied by depressed serum T3 and T4 values and elevated serum TSH level.
2. Primary hyperthyroidism is accompanied by elevated serum T3 and T4 levels along with depressed TSH values.
3. Slightly elevated T3 levels may be found in pregnancy and estrogen therapy, while depressed levels may be encountered in severe illness, renal failure and during therapy with drugs like propranolol and propyl thiouracil.
4. Although elevated TSH levels are nearly always indicative of primary hypothyroidism, and may be seen in secondary thyrotoxicosis

CLINICAL PATHOLOGY

URINE ROUTINE

Physical examination

Quantity	20	ML
Colour	PALE YELLOW	
Transparency	CLEAR	CLEAR
Sp.gravity	1.015	1.010-1.030
pH	6.50	
Reaction	ACIDIC	ACIDIC

Chemical examination

Urine protein	NIL	NIL
Urine sugar	NIL	NIL
Bilirubin, urine	NEGATIVE	NEGATIVE
Urobilinogen	NORMAL	NORMAL
Ketones	NEGATIVE	NEGATIVE

Microscopic examination

Pus cells.	1-2	/HPF	1-2
Epithelial cells	1-2	/HPF	0-5
R.B.C.	NIL	/HPF	NIL
Casts	NIL	/HPF	NIL
Crystals	NIL	/HPF	NIL
Bacteria	NIL	/HPF	NIL

Checked By.

Dr. NITIN AGARWAL
MBBS, MD (Path)
DMC/R/01436

DR. NITIN AGARWAL
MBBS, MD (PATHOLOGIST)

47, Harsh Vihar, Pitampura, New Delhi-110034 | Ph.: 011-42480101, 9599913051

E-mail: onepusul@gmail.com | Web.: www.oneplusul.in

Page 4 of 5



OnePLUS Ultrasound Lab

QUALITY FIRST... ALWAYS!

Dr. Nitin Agarwal

Pathologist & Director
Ex. Sr. Res. MAMC
& Lok Nayak Hospital
Ex. Chief of Lab Dr. Lal Path Labs.

Dr. Pooja (Garg) Agarwal

Radiologist & Director
MAMC & Lok Nayak Hospital



NAME	:Mrs. SANGEETA JHA	Barcode No	:10115977
AGE/GENDER	:29 YRS/Female	SPECIMEN DATE	:25/Mar/2022 08:59AM
PATIENT ID	:93086	SPECIMEN RECEIVED	:25/Mar/2022 09:14AM
REFERRED BY	:Dr. MEDIWHEEL	REPORT DATE	:25/Mar/2022 03:14PM
CENTRE NAME	:ONEPLUS ULTRASOUND LAB	LAB NO.	:012203250008

Test Name	Result	Unit	Ref. Range
Others.	NIL		NIL
STOOL ROUTINE			
<u>Physical examination</u>			
Colour	BROWNISH		Brownish
Consistency	SEMI FORMED		Semi Formed
Blood	ABSENT		Absent
Mucus	ABSENT		Absent
<u>Chemical examination, stool</u>			
pH	6.00		
<u>Microscopic examination</u>			
Pus cells	0-1	/HPF	10-11
Red blood cells	NIL	NIL	
Ova	ABSENT		NIL
Cysts	NIL		NIL
Bacteria	PRESENT	/HPF	NIL
Others	NIL		

*** End Of Report ***

Checked By.

Dr. NITIN AGARWAL
MBBS, MD (Path)
DMC/R/01436

DR. NITIN AGARWAL
MBBS, MD (PATHOLOGIST)

47, Harsh Vihar, Pitampura, New Delhi-110034 | Ph.: 011-42480101, 9599913051

E-mail: oneplusul@gmail.com | Web.: www.oneplusul.in

Page 5 of 5

Clinical correlation is essential for final diagnosis. • If test results are unsatisfactory please contact personally or on phone. • This report is for perusal of doctors only.
• All disputes Subject to Delhi Jurisdiction only. • Not for medicolegal purposes. • All congenital anomalies in a foetus may not be diagnosed in routine obstetric ultrasound.