



MED111810945

MYSORE-BALLAL CIRCLE

MEDALL HEALTHCARE PVT LTD

CUSTOMER CHECKLIST



Print Date :26/08/2023 07:59 AM

Customer Name : **MR.SHANKAR S ARVINDH**

Ref Dr Name : **MediWheel**

Customer Id : **MED111810945** Visit ID : **712329375**

Age : **32Y/MALE** Phone No : **8870536835**

DOB : **13 Jan 1991** Visit Date : **26/08/2023**

Company Name : **MediWheel**

Package Name : **Mediwheel Full Body Health Checkup Male Below 40**

S.No	Modality	Study	AccessionNo	Time	Signature
1	LAB	BLOOD UREA NITROGEN (BUN)			
2	LAB	GLUCOSE - FASTING			
3	LAB	GLUCOSE - POSTPRANDIAL (2 HRS)			
4	LAB	GLYCOSYLATED HAEMOGLOBIN (HbA1c)			
5	LAB	BLOOD GROUP & RH TYPE (Forward Reverse)			
6	LAB	LIPID PROFILE			
7	LAB	LIVER FUNCTION TEST (LFT)			
8	LAB	URIC ACID			
9	LAB	URINE GLUCOSE - FASTING			
10	LAB	URINE GLUCOSE - POSTPRANDIAL (2 Hrs)			
11	LAB	COMPLETE BLOOD COUNT WITH ESR			
12	LAB	THYROID PROFILE/ TFT(T3, T4, TSH)			
13	LAB	STOOL ANALYSIS - ROUTINE			
14	LAB	URINE ROUTINE			
15	LAB	CREATININE			
16	LAB	BUN/CREATININE RATIO			
17	OTHERS	physical examination	MYS2825784102651		
18	US	ULTRASOUND ABDOMEN	MYS2825784103462		
19	OTHERS	Headfall / 2D Echo ✓ <i>scanned</i>	MYS2825784127528		
20	OTHERS	EYE CHECKUP ✓	MYS2825784135592		
21	X-RAY	X RAY CHEST ✓	MYS2825784145199		
22	OTHERS	Consultation Physician	MYS2825784148004		
23	ECHO	ELECTROCARDIOGRAM ECG ✓	MYS2825784149333		

Registered By (ABHISHEK.N)

H - 172
W - 71
BP - 110/70
puls - 86
uric - 36
HCP - 38


FITNESS CERTIFICATE

NAME: Mr. Shankar S. Aravind	AGE: 32 years
Ht: 172 CMS	Wt: 71 KGS
SEX: male	

PARAMETERS	MEASUREMENTS
PULSE / BP (supine)	86 / mt / /mmHg 110/70
INSPIRATION	42
EXPIRATION	41.
CHEST CIRCUMFERENCE	41.5"
PREVIOUS ILLNESS	Nil
VISION	
FAMILY HISTORY	FATHER: Diabetic MOTHER:

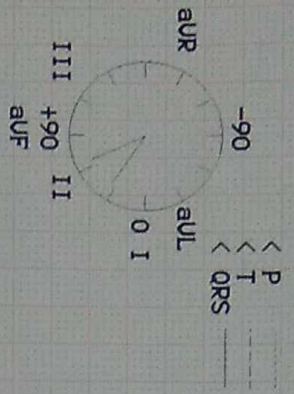
REPORTS: *within normal limits*

DATE: *26/08/23*
PLACE: *Mysore*


Dr. NIKHIL B.
 M.D., D.M. (Cardiologist)
 Interventional Cardiologist
 KMC Reg. No. 90111
CONSULTANT PHYSICIAN



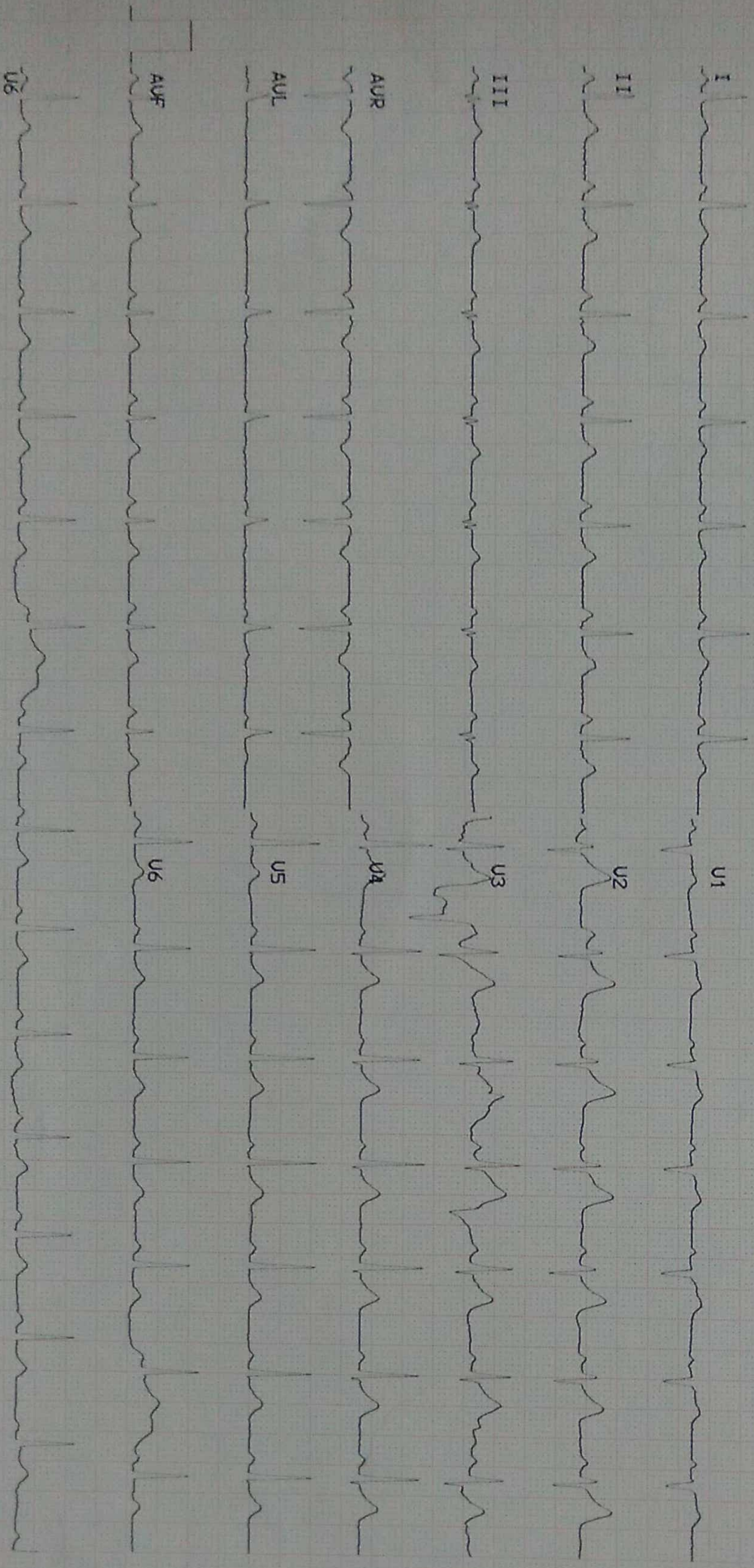
AGE: 32
 Measurement Results:
 QRS : 82 ms
 QT/QTcB : 350 / 420 ms
 PR : 130 ms
 P : 104 ms
 RR/PP : 696 / 690 ms
 P/QRS/T : 65 / 35 / 65 degrees
 QTd/QTcBD : 56 / 67 ms
 Sokolow : 1.5 mV
 NK : 13



Interpretation:
 normal ECG

Normal sinus rhythm
HP

Unconfirmed report.





NETHRADHAMA SUPER SPECIALITY EYE HOSPITAL

NO 1118 GEETHA ROAD, CHAMARAJAPURAM
MYSORE-570005, KARNATAKA

CASE SHEET

Name: ARVINDH S SHANKAR .

OP No: 6OP1262243

Gender: Male Age: 32 Date: 26/08/2023

Complaint

S.No	Eye	Complaint	Duration	Type	Remarks
2	BE	FOR MEDICAL CERTIFICATE	1	Days	

Diagnosis

Eye	ICDCode	ICD	Version	Remarks
BE	25692	REFRACTIVE ERROR - 25692 - 9	9	
BE	H52.7	Disorder of refraction - H52.7 - 10	10	

SCHIRMER'S Test & TBUT

IOP

Type	NCT			DVT Flag				
Target					DVT1	DVT2	DVT3	DVT4
	BD	AD	CL	RE				
RE	12			LE				
LE	10			Time	12:00 AM	12:00 AM	12:00 AM	12:00 AM

AR

RE	SPH	CYL	AXIS	LE	SPH	CYL	AXIS
BD	-2.00	-1.00	135	BD	-2.75	-0.75	170
AD				AD			

Drug Used:

GlassPower

	SPH	CYL	AXIS	ADD
RE	-2.50	-0.50	149	
LE	-2.50	-0.75	3	

Glass Type: 11

VisionDetail

RE	UCVA	PG	PH	LE	UCVA	PG	PH
DV	6/36	6/6		DV	6/36	6/6	
NV		N6		NV		N6	

Subjective

RE	SPH	CYL	AXIS	VA	LE	SPH	CYL	AXIS	VA
Dist	-2.00	-0.75	135	6/6	Dist	-2.50	-0.75	170	6/6
Near				N6	Near				N6

Color Vision


Chart Type	1
RE	38/38
LE	38/38
Remarks	

Recommendations

User Name	Recommendations
Dr RICHHA .	ANT SEG- BE- CLEAR CORNEA, VH-3, LENS- CLEAR FUNDUS- UNDIL- BE- CD- 0.2, FR+ ADV- REVIEW FOR DILATATION

This visit was Electronically Signed by Mrs Sowmya B on 8/26/2023 12:25:24 PM.

This visit was Electronically Signed by Dr RICHHA . on 8/26/2023 12:43:47 PM.


Dr. Richa
MBBS, DOMS, DNB
Consultant - Vitreo Retina
KMC Reg. No. : 105719

Customer Name	MR.SHANKAR S ARVINDH	Customer ID	MED111810945
Age & Gender	32Y/MALE	Visit Date	26/08/2023
Ref Doctor	MediWheel		

2 D ECHOCARDIOGRAPHIC STUDY

M mode measurement:

AORTA	:	3.0cms
LEFT ATRIUM	:	3.1cms
LEFT VENTRICLE (DIASTOLE)	:	4.7cms
(SYSTOLE)	:	2.9cms
VENTRICULAR SEPTUM (DIASTOLE)	:	0.9cms
(SYSTOLE)	:	1.1cms
POSTERIOR WALL (DIASTOLE)	:	0.9cms
(SYSTOLE)	:	1.2cms
EDV	:	81ml
ESV	:	32ml
FRACTIONAL SHORTENING	:	37%
EJECTION FRACTION	:	62%
RVID	:	1.0cms

DOPPLER MEASUREMENTS:

MITRAL VALVE	:	'E' - 0.81 m/s	'A' - 0.35 m/s	NO MR
AORTIC VALVE	:	1.00m/s		NO AR
TRICUSPID VALVE	:	'E' - 0.75m/s	'A' - 0.38m/s	NO TR
PULMONARY VALVE	:	0.70m/s		NO PR



Customer Name	MR.SHANKAR S ARVINDH	Customer ID	MED111810945
Age & Gender	32Y/MALE	Visit Date	26/08/2023
Ref Doctor	MediWheel		

2D ECHOCARDIOGRAPHY FINDINGS:

Left ventricle : Normal size, Normal systolic function.
No regional wall motion abnormalities.

Left Atrium : Normal.

Right Ventricle : Normal.

Right Atrium : Normal.

Mitral valve : Normal, No mitral valve prolapse.

Aortic valve : Normal, Trileaflet.

Tricuspid valve : Normal.

Pulmonary valve : Normal.


IAS : Intact.

IVS : Intact.

Pericardium : No pericardial effusion.

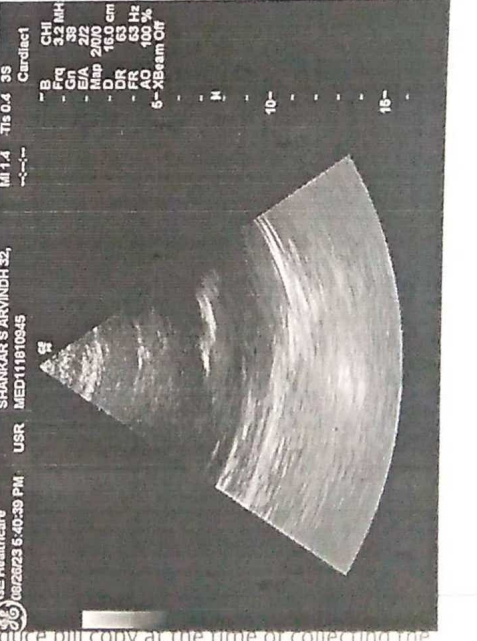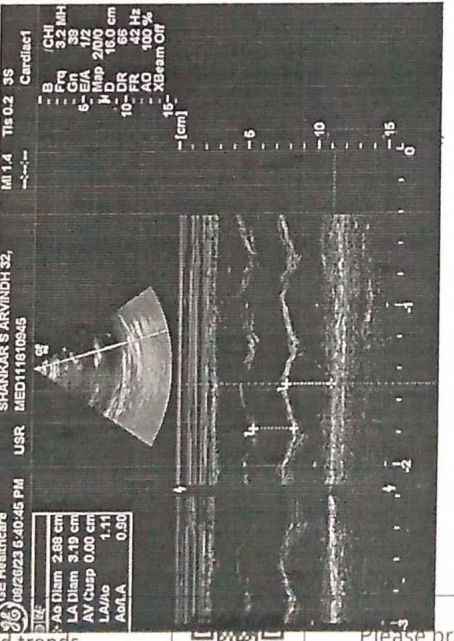
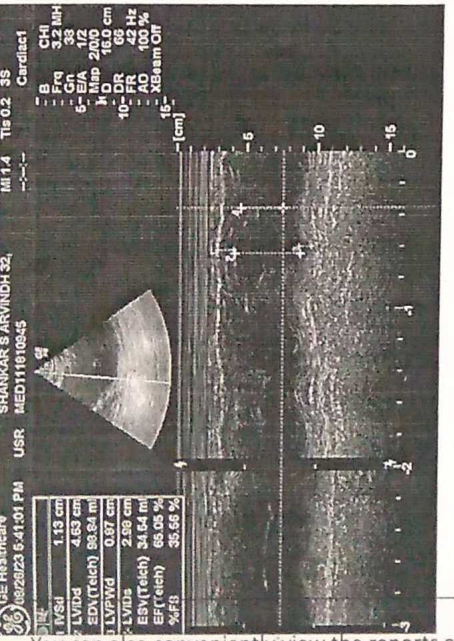
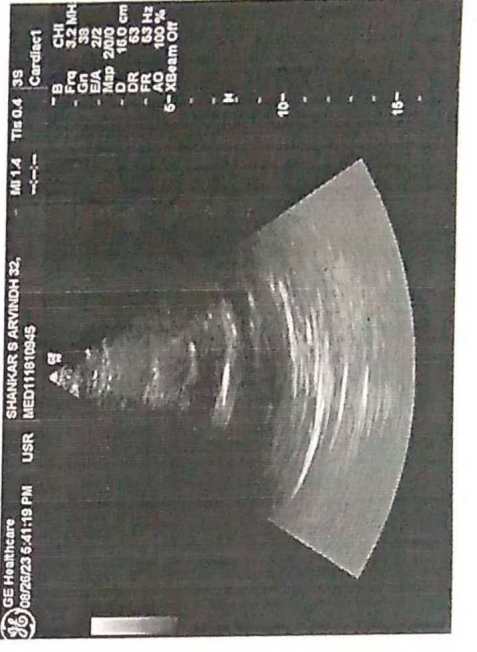
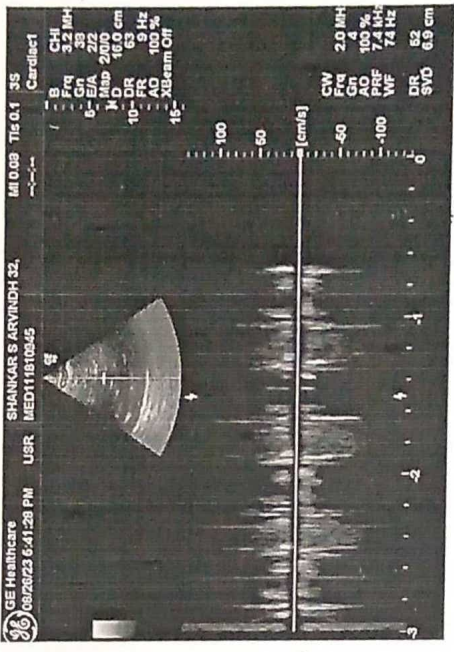
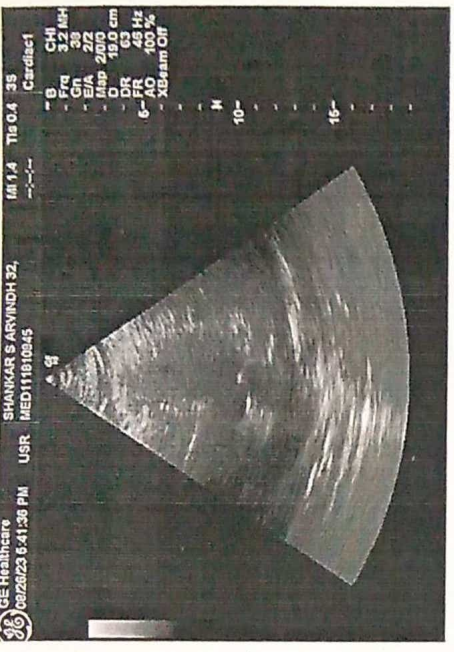
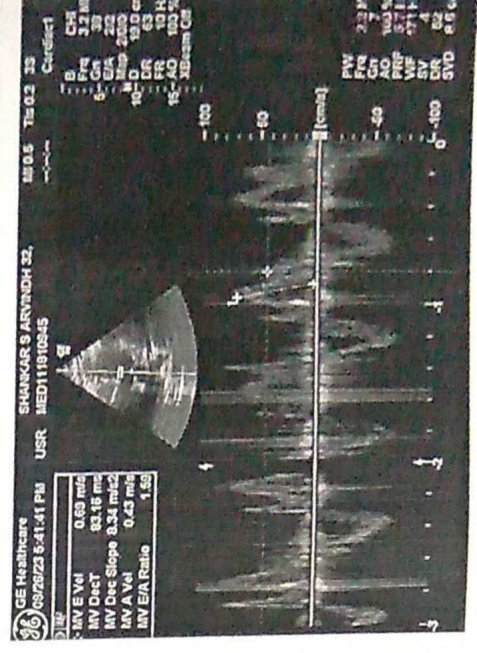
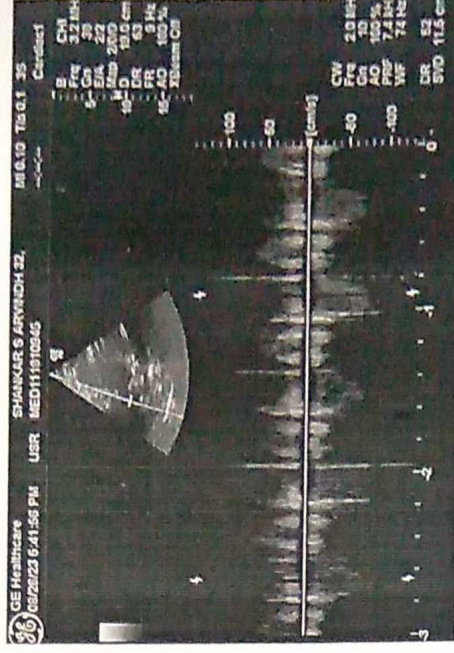
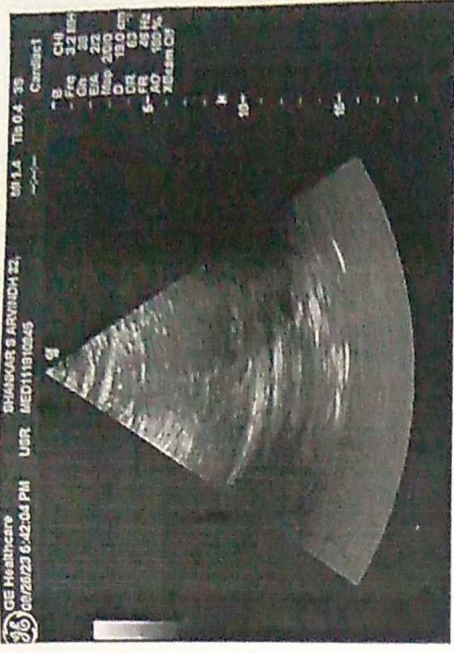IMPRESSION:

- NORMAL SIZED CARDIAC CHAMBERS.
- NORMAL LV SYSTOLIC FUNCTION. EF: 62%.
- NO REGIONAL WALL MOTION ABNORMALITIES.
- NORMAL VALVES.
- NO CLOTS/ PERICARDIAL EFFUSION VEGETATION.



DR. NIKHIL B
INTERVENTIONAL CARDIOLOGIST
NB/mm





You can also conveniently view the reports and trends through our App. Scan QR code to download the App.



Please produce bill copy at the time of collecting the reports. Request you to provide your mobile number or customer id during your subsequent visits.

Customer Name	MR.SHANKAR S ARVINDH	Customer ID	MED111810945
Age & Gender	32Y/MALE	Visit Date	26/08/2023
Ref Doctor	MediWheel		

ABDOMINO-PELVIC ULTRASONOGRAPHY

LIVER is normal in size and shows slightly increased echotexture.

No evidence of focal lesion or intrahepatic biliary ductal dilatation.

Hepatic and portal vein radicals are normal.

GALL BLADDER show normal shape and has clear contents.

Gall bladder wall is of normal thickness. CBD is of normal calibre.

PANCREAS has normal shape, size and uniform echopattern.

No evidence of ductal dilatation or calcification.

SPLEEN show normal shape, size and echopattern.

KIDNEYS move well with respiration and have normal shape, size and echopattern.

Cortico- medullary differentiations are well madeout.

No evidence of calculus or hydronephrosis.

	Bipolar length (cms)	Parenchymal thickness (cms)
Right Kidney	10.3	2.0
Left Kidney	10.5	1.9

URINARY BLADDER show normal shape and wall thickness.

It has clear contents.

PROSTATE shows normal shape, size and echopattern.


No evidence of ascites.

IMPRESSION:

> **GRADE I FATTY CHANGES IN LIVER.**

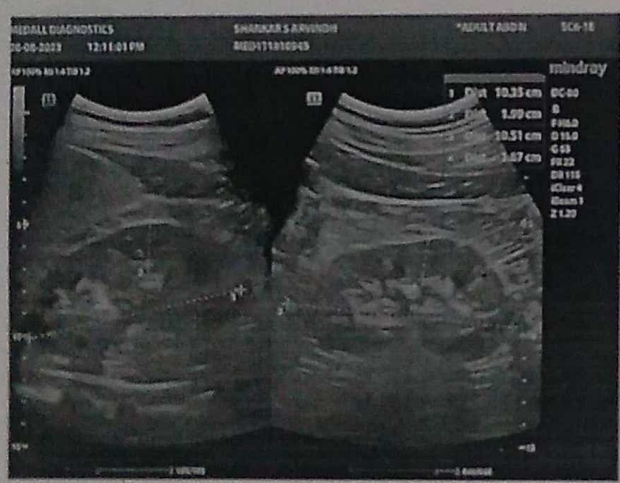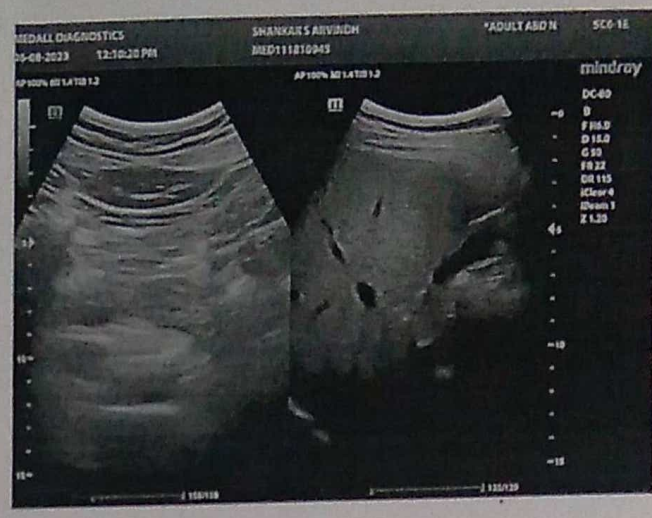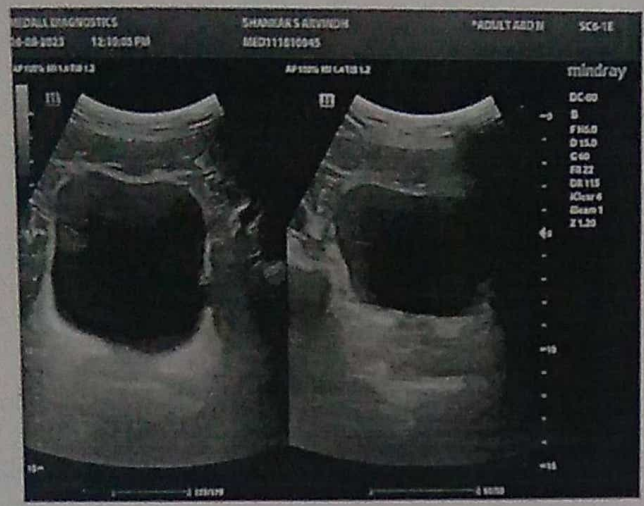CONSULTANT RADIOLOGISTS

DR. ANITHA ADARSH
MB/MS


DR. MOHAN B



Customer Name	MR.SHANKAR S ARVINDH	Customer ID	MED111810945
Age & Gender	32Y/MALE	Visit Date	26/08/2023
Ref Doctor	MediWheel		



You can also conveniently view the reports and trends through our App. Scan QR code to download the App.



Please produce bill copy at the time of collecting the reports. Request you to provide your mobile number or customer id during your subsequent visits.