

नवीन शर्मा
Naveen Sharma
जन्म तारीख/ DOB:
08/06/1972
पुरुष / MALE

2641 2769 2062

माझे आधार, माझी ओळख




[Handwritten signature in blue ink]



Report :

TEST OBJECTIVE : ROUTINE CHECK UP
RISK FACTOR : AGE
ACTIVITY : MODERATE ACTIVE
REASON FOR TERMINATION : FATIGUE, HEART RATE ACHIEVED
EXERCISE TOLERANCE : AVERAGE
EXERCISE INDUCED ARRYTHMIAS : NO
HAEMODYNAMIC RESPONSE : NORMAL
CHRONOTROPIC RESPONSE : NORMAL
FINAL IMPRESSION : STRESS TEST IS NEGATIVE FOR EXERCISE INDUCED ISCHAEMIC HEART DISEASE





1030 / NAVEEN SHARMA / 52 Yrs / M / 0 Cms / 0 Kg Date: 11-Mar-2023 Refd By : BOB

Stage	Time	Duration	Belt Speed (mph)	Elevation	METs	Rate	% THR Achieved	BP	HR	RPP	PVC	Comments
Supine	00:13	0:01	00.0	00.0	01.0	77	46 %	118/80	000	000	00	
Standing	00:37	0:01	00.0	00.0	01.0	80	48 %	118/80	000	000	00	
HV	00:43	0:01	00.0	00.0	01.0	080	48 %	118/80	000	000	00	
Warm Up	01:09	0:01	01.0	00.0	01.0	077	46 %	118/80	000	000	00	
ExStart	01:16	0:06	01.7	10.0	01.1	096	57 %	118/80	000	000	00	
BRUCE Stage 1	04:16	3:00	01.7	10.0	04.7	114	68 %	126/88	143	143	00	
BRUCE Stage 2	07:16	3:00	02.5	12.0	07.1	133	79 %	134/94	178	178	00	
PeakEx	07:47	0:31	03.4	14.0	07.7	146	87 %	134/94	195	195	00	
Recovery	08:46	1:00	00.0	00.0	01.2	117	70 %	130/80	152	152	00	
Recovery	09:46	2:00	00.0	00.0	01.0	094	56 %	126/80	118	118	00	
Recovery	10:06	2:19	00.0	00.0	01.0	098	58 %	126/80	123	123	00	

Findings :

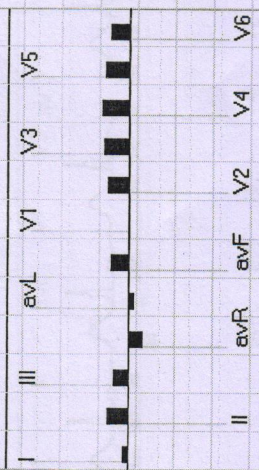

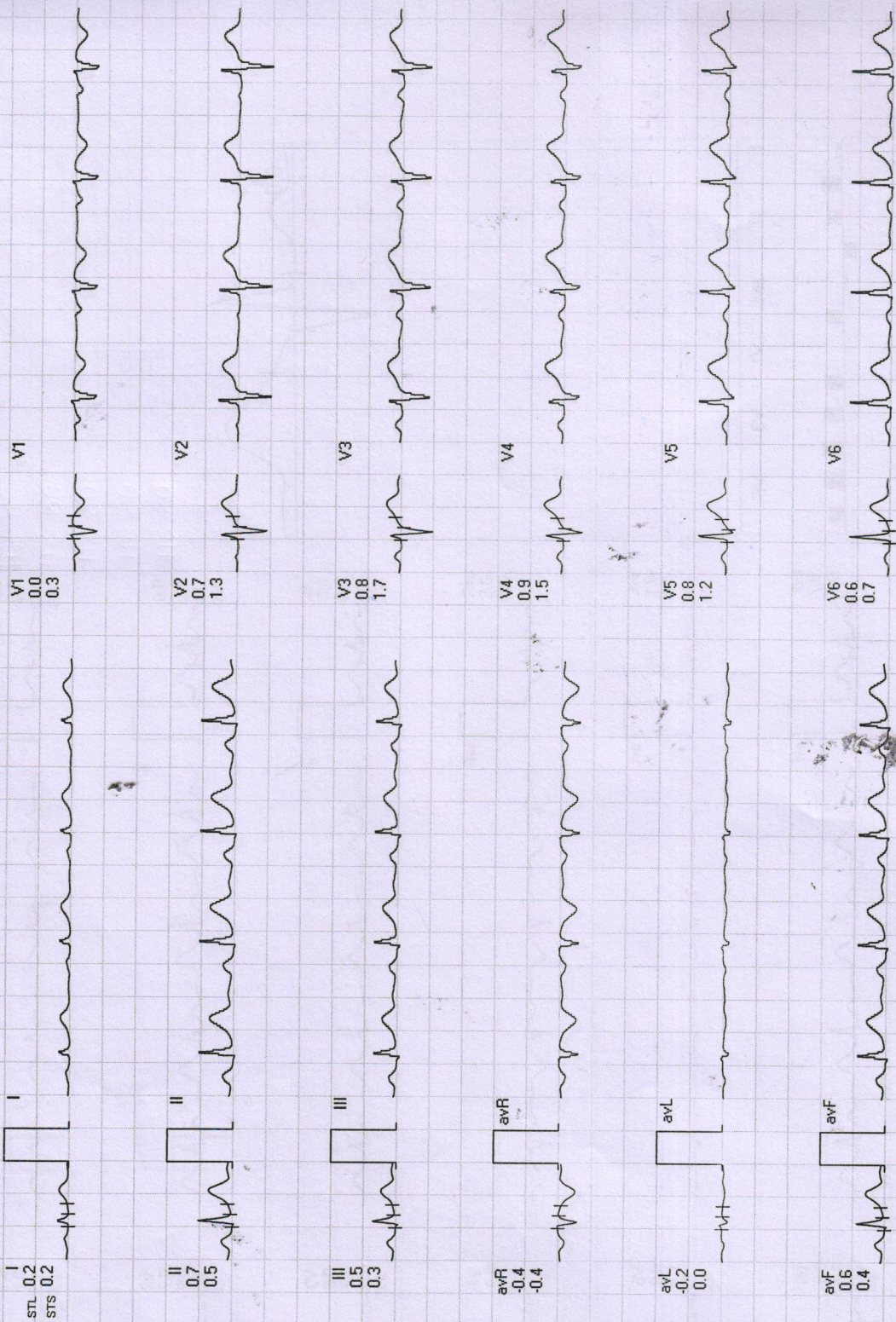
Exercise Time : 06:32
 Max HR Attained : 146 bpm 87% of Target 168
 Max BP Attained : (Sys) 134/94
 Max WorkLoad Attained : 7.7 Fair response to induced stress
 Test End Reasons : Fatigue, Heart Rate Achieved

Date: 11-Mar-2023 12:28:50 PM METS: 1.0 / 77 bpm 45% of THR BP: 118/80 mmHg Rew ECG/BLC On/ Natch On/ HF 0.05 Hz/LF 20 Hz

ExTime: 00:12 0.0 mph. 0.0%

4X 80 mS Post J

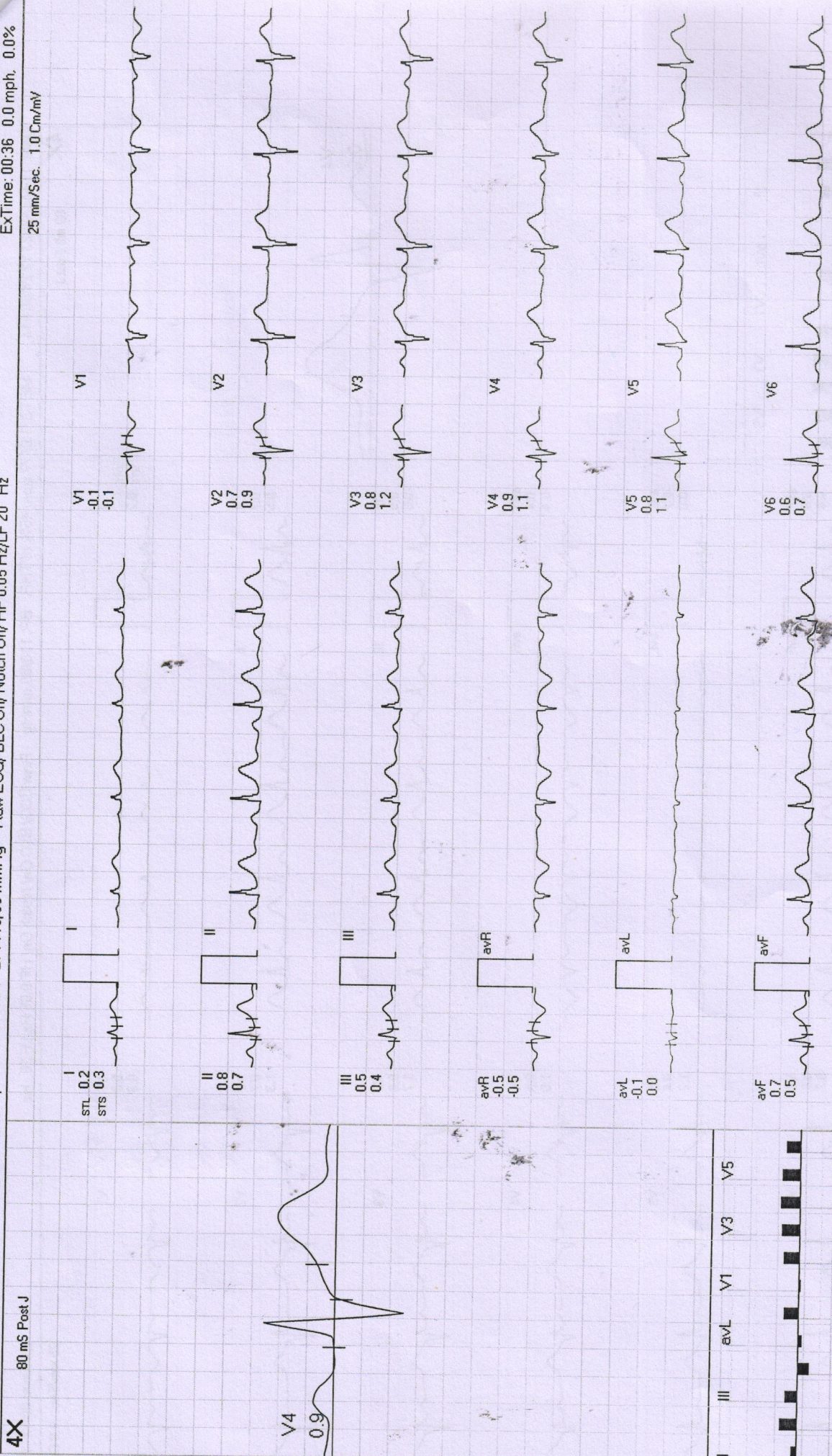
25 mm/Sec. 1.0 Cm/mV



REMARKS:

Date: 11-Mar-2023 12:28:50 PM METS: 1.0/ 80 bpm 47% of THR BP: 118/80 mmHg Raw ECG/ BLC On/ Natch On/ HF 0.05 Hz/ LF 20 Hz

ExTime: 00:36 0.0 mph, 0.0%
25 mm/Sec. 1.0 Cm/mV



REMARKS:

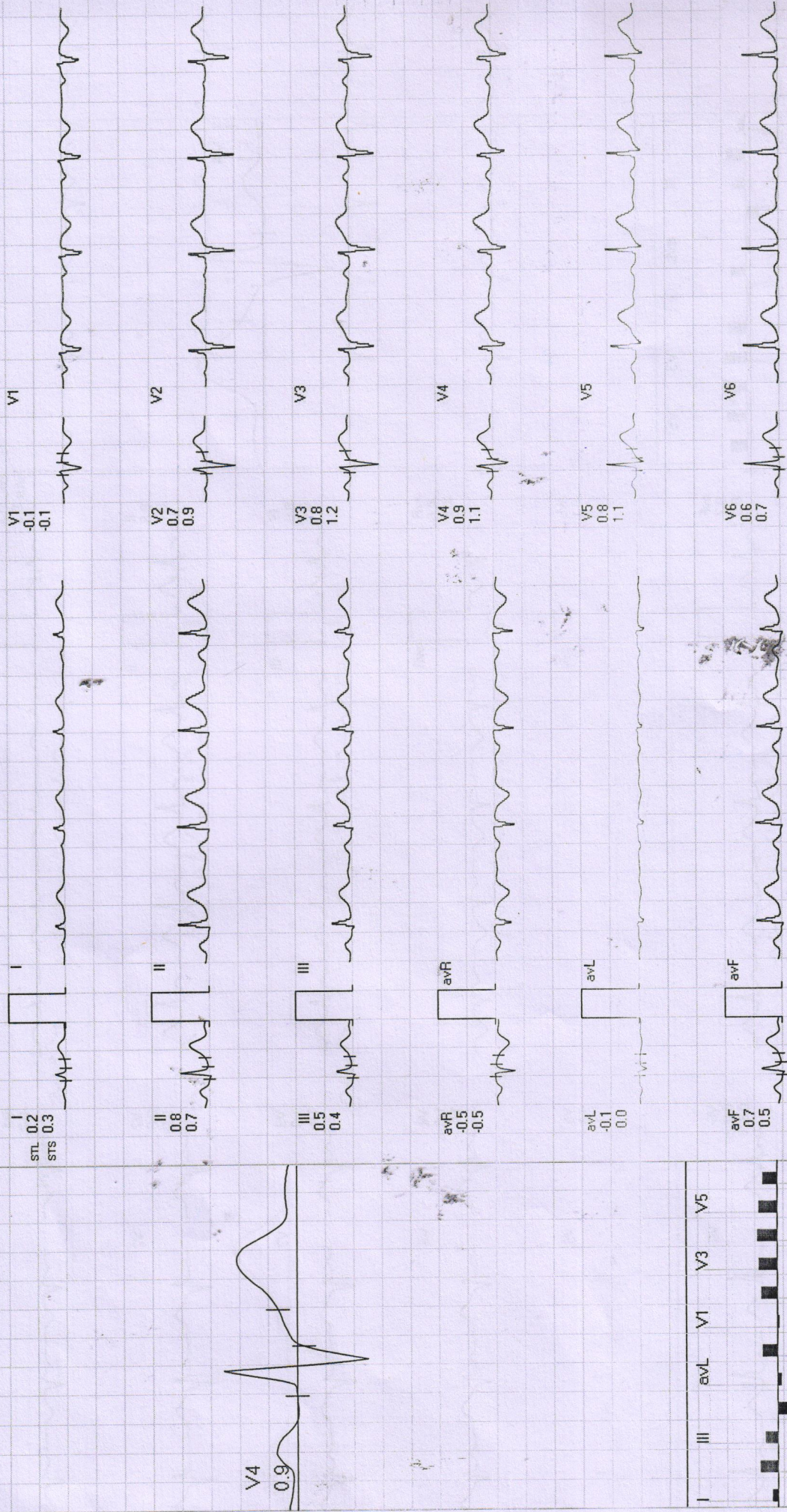
Date: 11-Mar-2023 12:28:50 PM METS: 1.0/80 bpm 47% of THR BP: 118/80 mmHg Raw ECG/BLC On/ Notch On/ HF 0.05 Hz/LF 20 Hz

ExTime: 00:42 0.0 mph, 0.0%

4X

80 mS Post J

25 mm/Sec. 1.0 Cm/mV

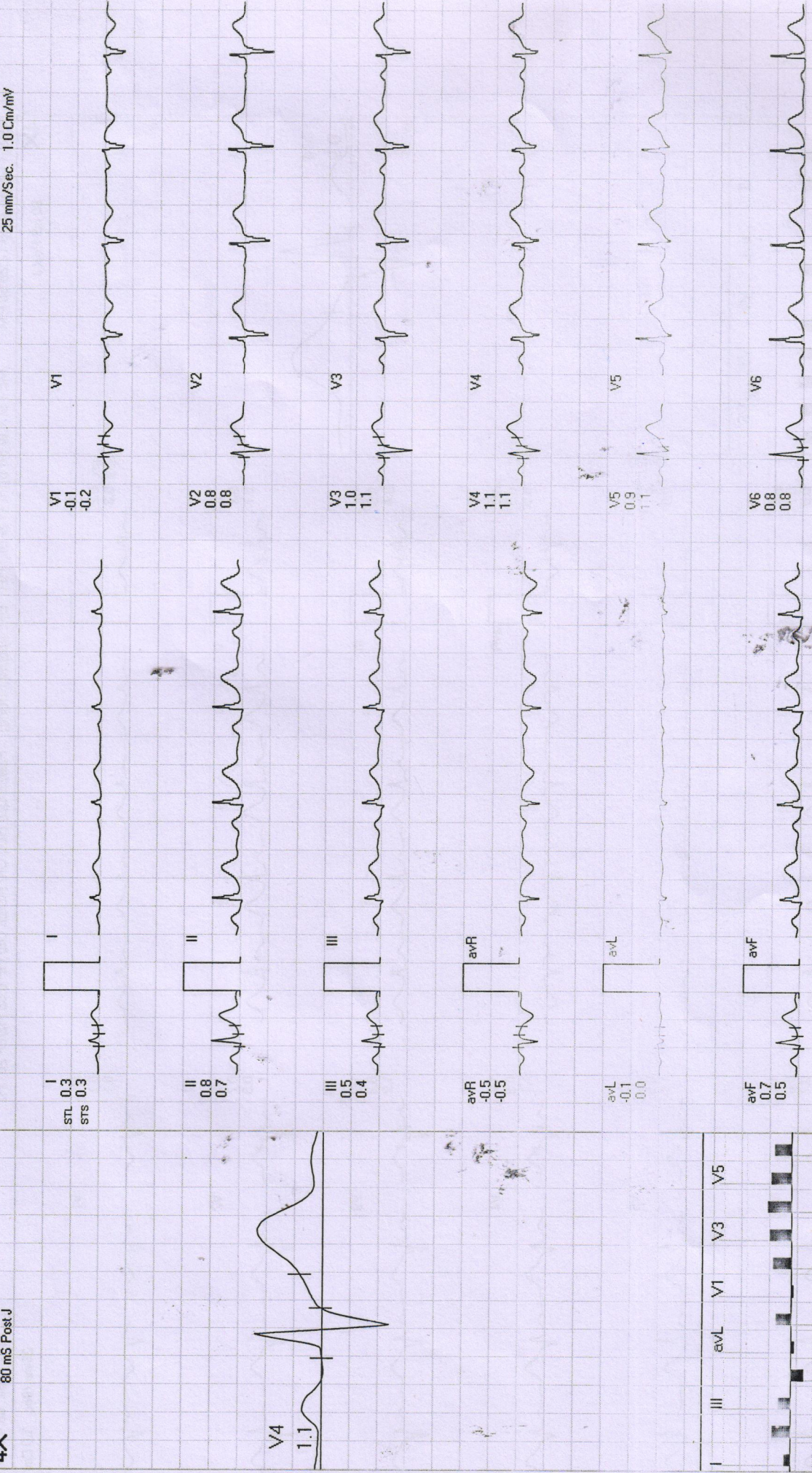


REMARKS:

Date: 11-Mar-2023 12:28:50 PM METS: 1.0/77 bpm 45% of THR BP: 118/80 mmHg Raw ECG/BLC On/ Natch On/ HF 0.05 Hz/LF 20 Hz

ExTime: 01:08 1.0 mph, 0.0%

4X 80 mS Post J



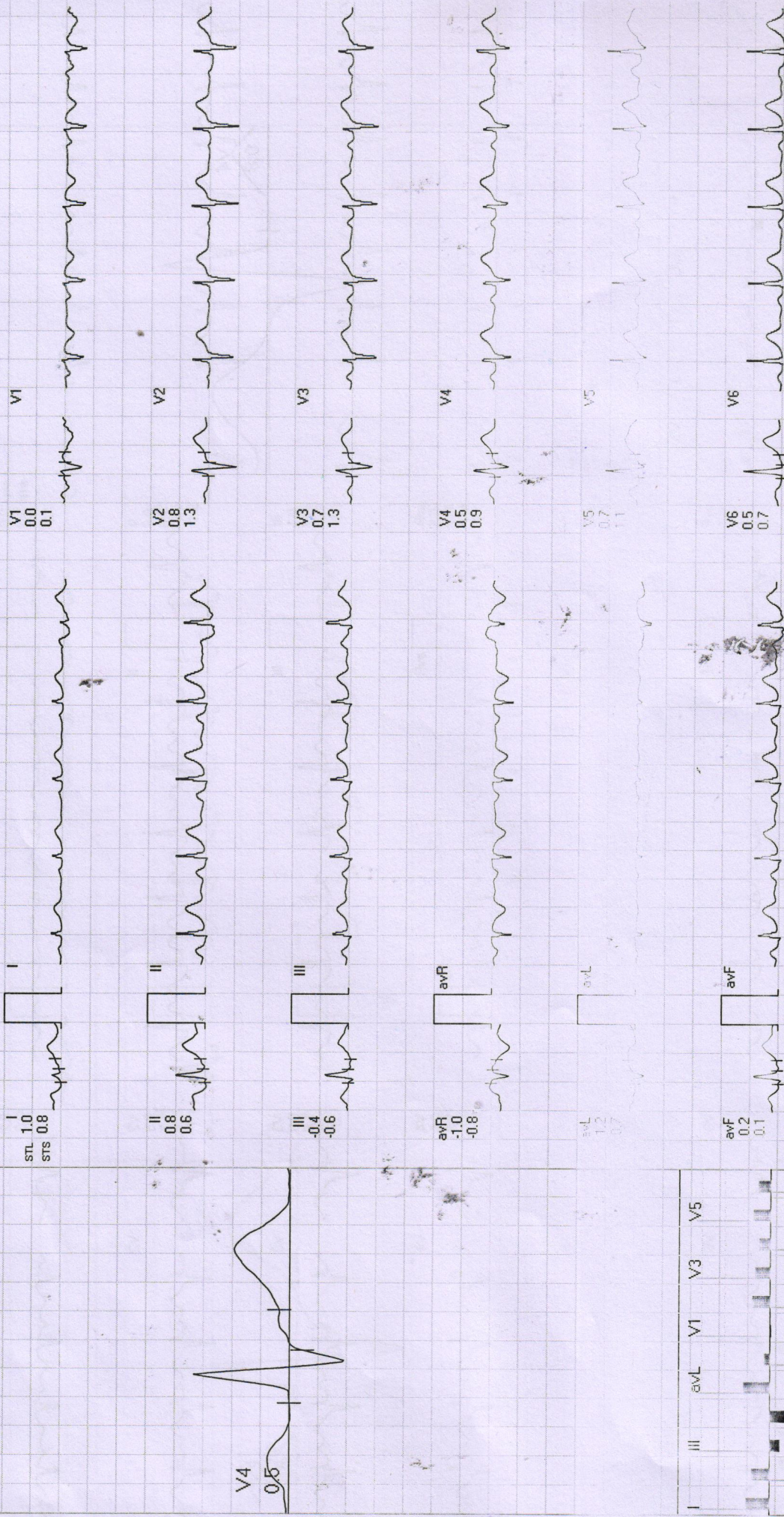
REMARKS: II avR avF V2 V4 V6

Date: 11-Mar-2023 12:28:50 PM METS: 1.0/96 bpm 57% of THR BP: 118/80 mmHg Raw ECG/BLC On/ Notch On/ HF 0.05 Hz/LF 20 Hz

ExTime: 00:00 0.0 mph. 0.0%

4X 80 mS Post J

25 mm/Sec. 1.0 Cm/mV



REMARKS:

Date: 11-Mar-2023 12:28:50 PM

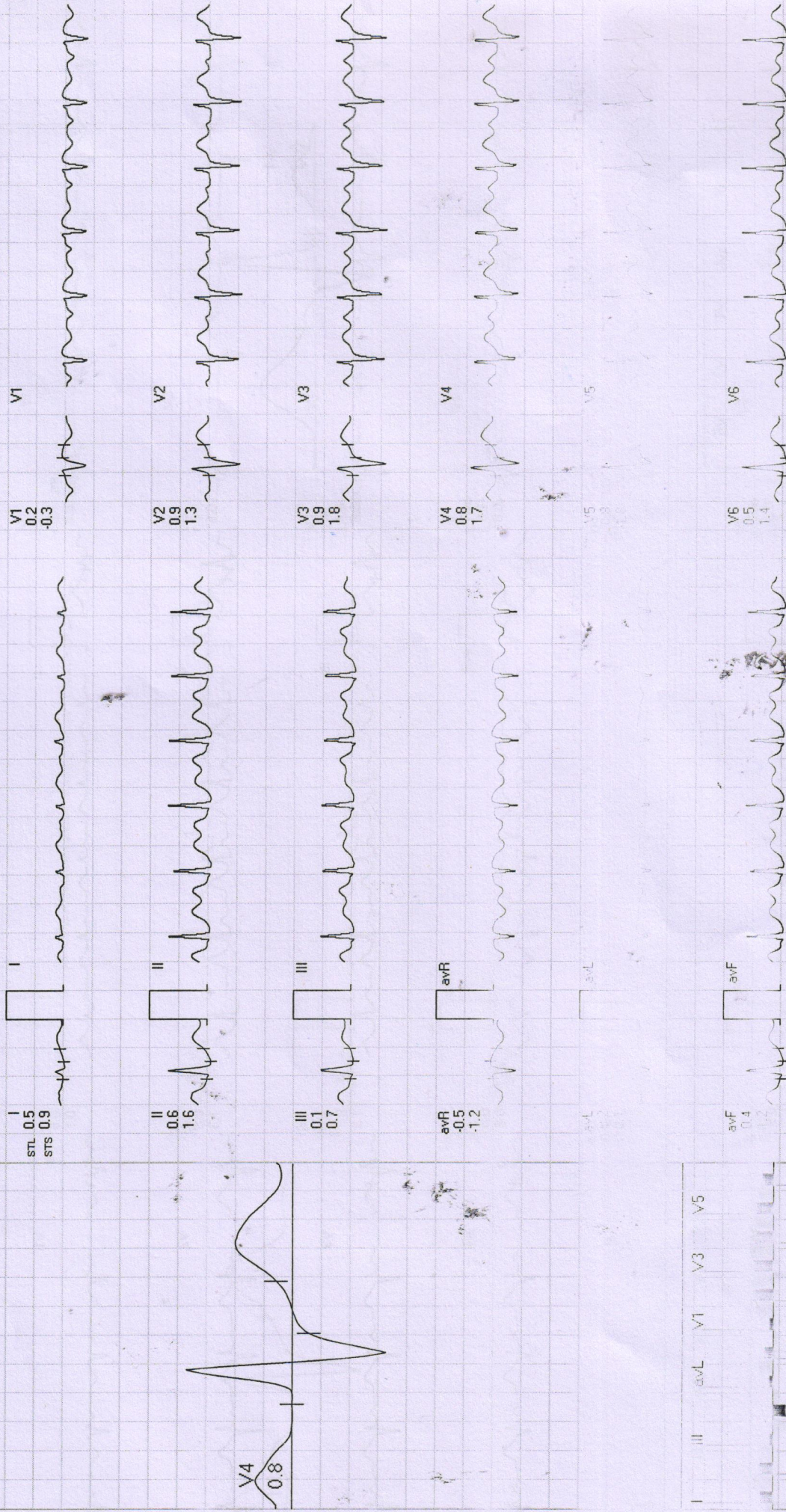METS: 4.7/114 bpm 67% of THR BP: 126/88 mmHg Raw ECG/ BLC On/ Natch On/ HF 0.05 Hz/ LF 20 Hz

ExTime: 03:00 1.7 mph, 10.0%

4X

80 mS Post J

25 mm/Sec. 1.0 Cm/mV



REMARKS:

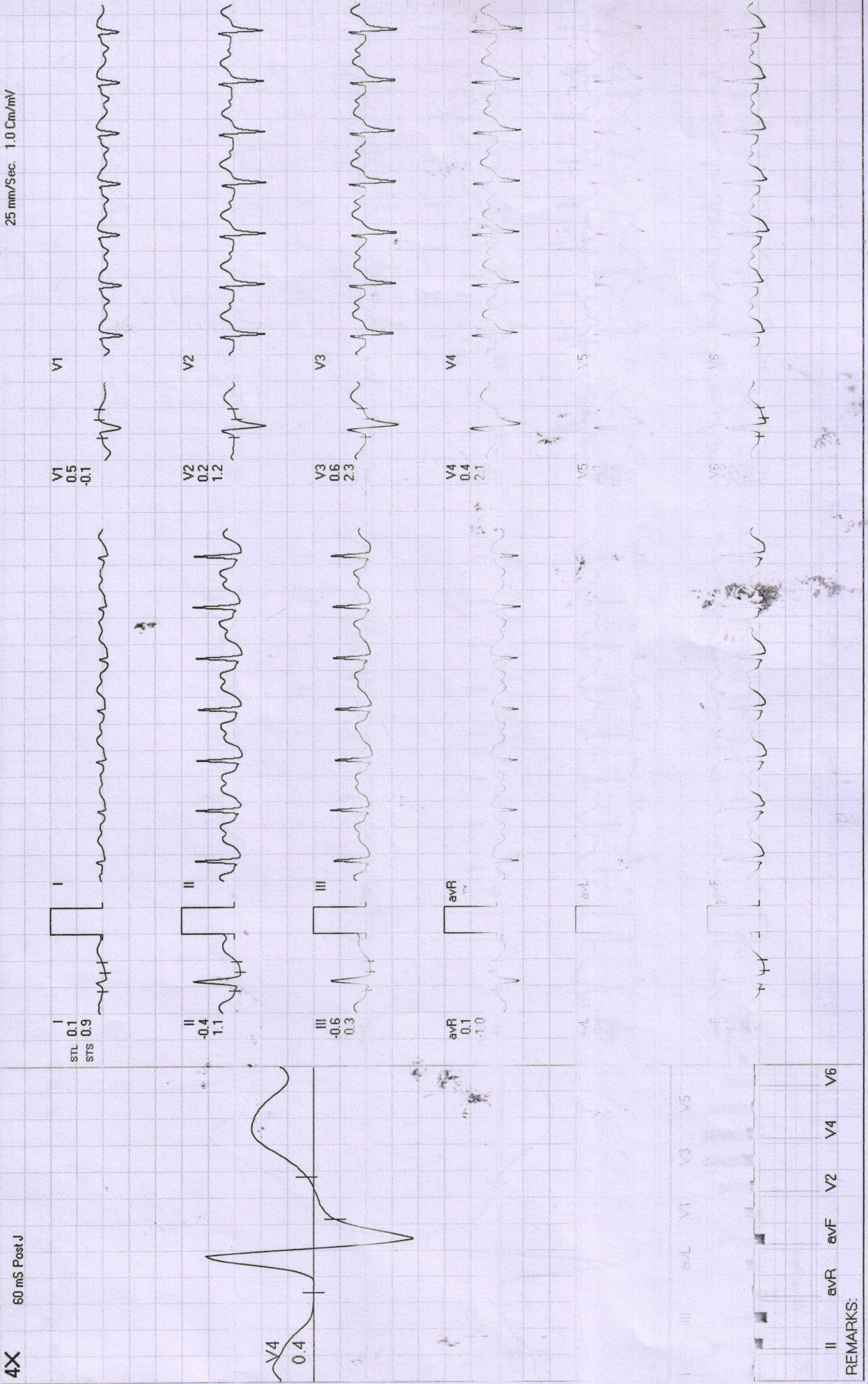


Date: 11-Mar-2023 12:28:50 PM METS: 7.1/133 bpm 79% of THR BP: 134/94 mmHg Raw ECG/BLC On/ Notch On/ HF 0.05 Hz/LF 20 Hz

ExTime: 06:00 2.5 mph, 12.0%

4X

60 mS Post J

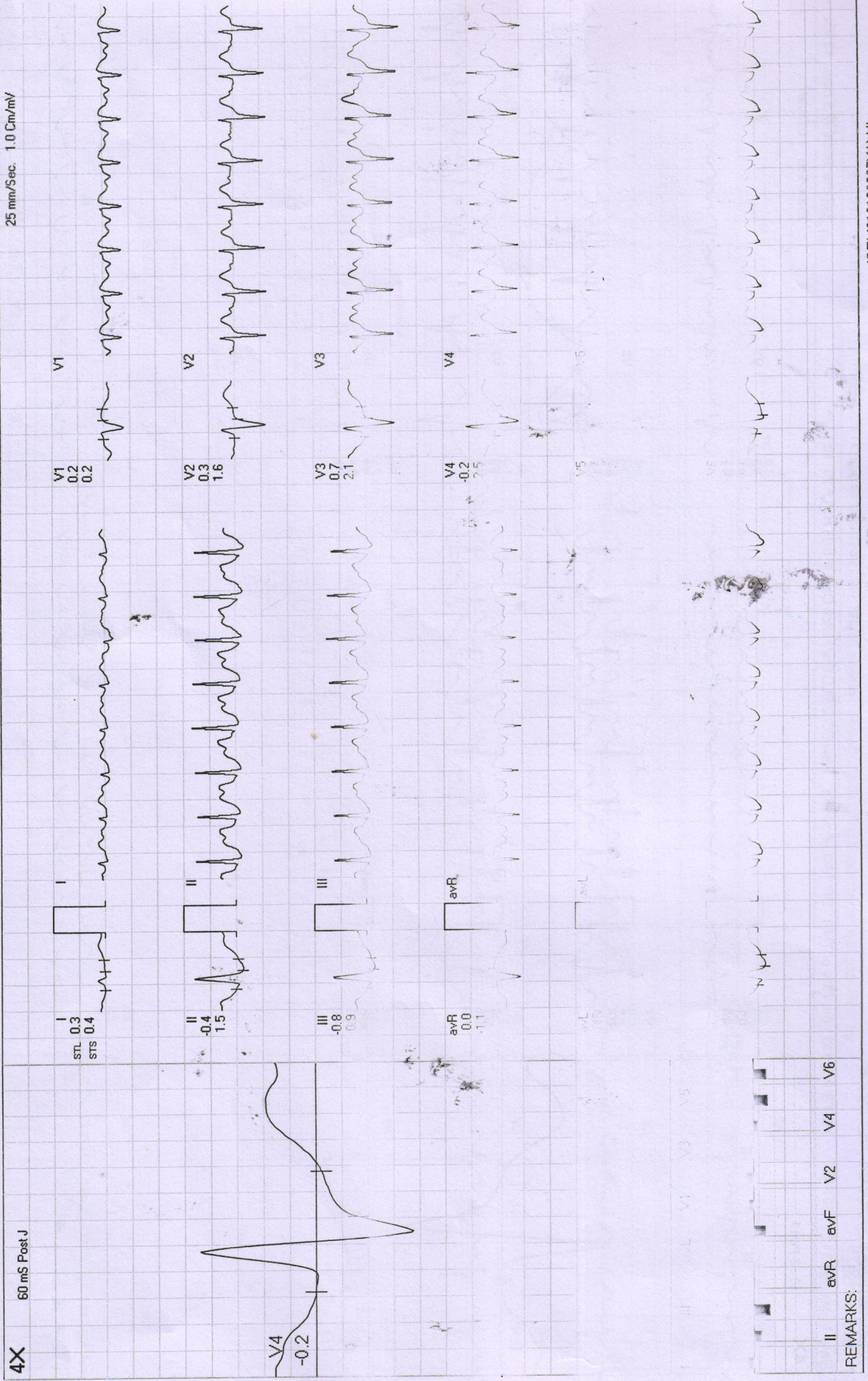


REMARKS:

Date: 11-Mar-2023 12:28:50 PM METS: 7.7 / 146 bpm 86% of THR BP: 134/94 mmHg Raw ECG/BLC On/ HF 0.05 Hz/LF 20 Hz

ExTime: 06:31 3.4 mph, 14.0%

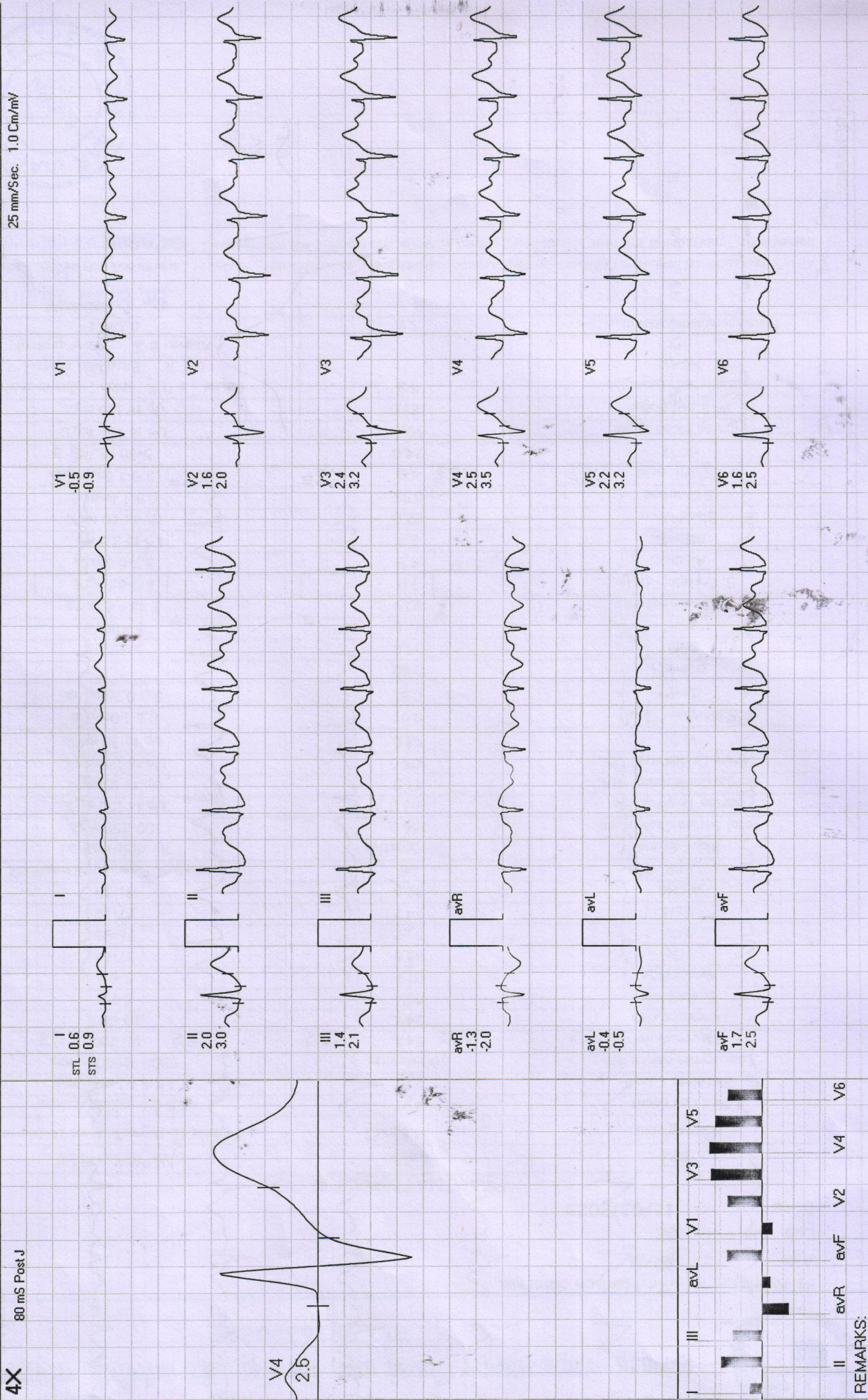
4X 60 mS Post J



REMARKS:



Date: 11-Mar-2023 12:28:50 PM METS: 1.1/117 bpm 69% of THR BP: 130/80 mmHg Raw ECG/ BLC On/ Natch On/ HF 0.05 Hz/LF 20 Hz ExTime: 06:31 0.0 mph, 0.0%

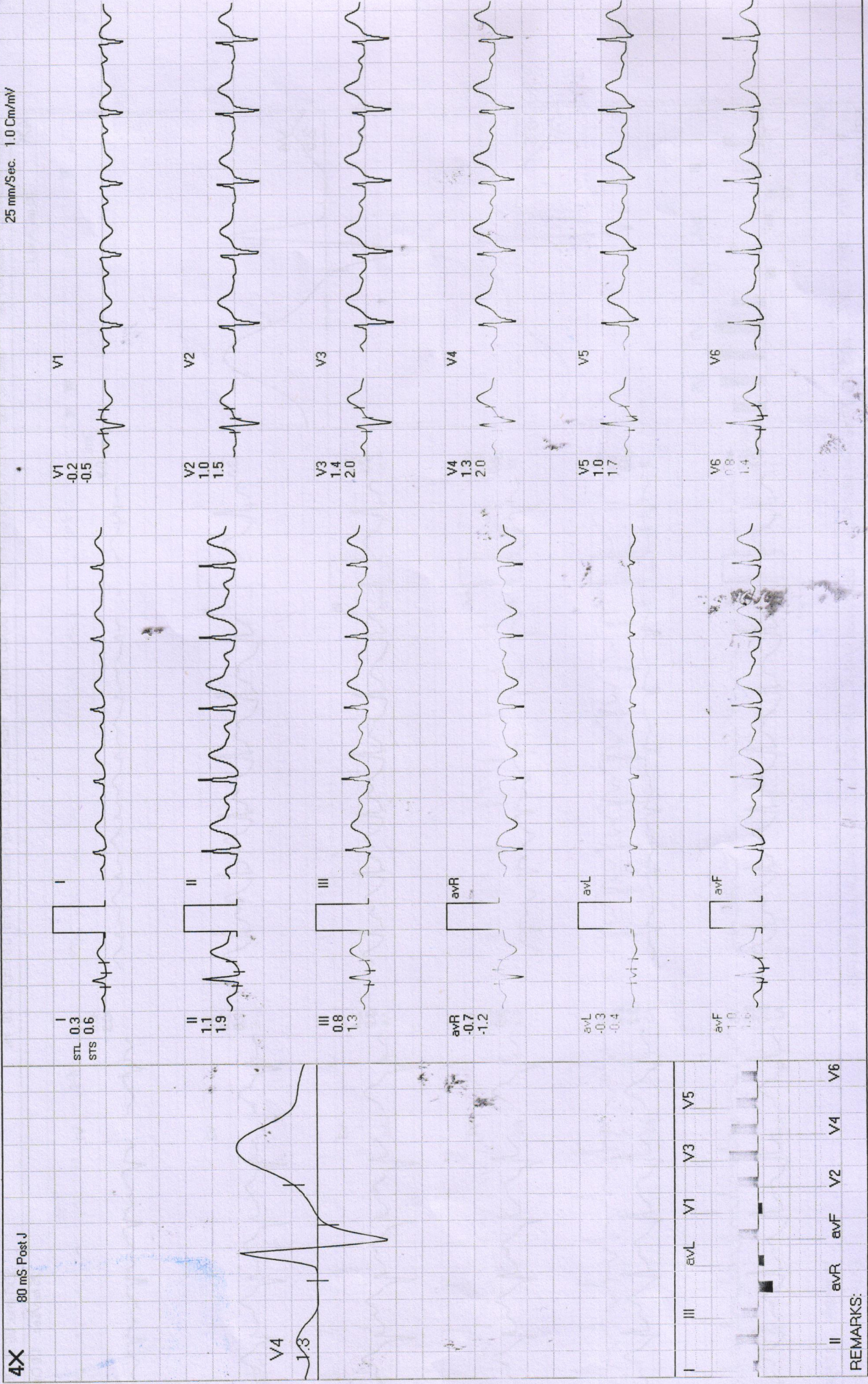


Date: 11-Mar-2023 12:28:50 PM METS: 1.0/ 94 bpm 55% of THR BP: 126/80 mmHg Raw ECG/ BLC On/ Natch On/ HF 0.05 Hz/LF 20 Hz

ExTime: 06:31 0.0 mph, 0.0%

4X

80 mS Post J



REMARKS:



दिवीकर डायग्नोस्टिक सेंटर
 E-7/636, पंजाब नगर बँक के पास, मॉन रोड, अरुण कॉलोनी, भापाल (म.प्र.)
 फॉन : 9826340190

Pt Name :- Mr. Naveen Sharma

Age :- 52/M

Lab. No. :- 02

Date :- 11/03/2023

EXAMINATION OF BLOOD

TEST	RESULT	NORMAL VALUE
Haemoglobin	14.8gms%	Female 12-16gms%, Male 14-18gms%
Red Cell count	4.97	4.5-5.6 million /cumm
Platelet Count	2.57	1.5-5.6 Lac/cumm
Leucocytes per.cu.mm	6000/cumm	5000-11000/cumm
Neutrophils	54%	50-70%
Lymphocytes	34%	20-40%
Eosinophils	05%	0-7%
Monocytes	07%	2-8%
PCV	45.5	37-47
MCV	91.7	76-96
MCH	29.7	27-32
MCHC	32.5	31-35
ESR	05	Male 0-9, Female 0-20mm/FHR
Blood Group	"O" Negative	By slide method
Total Serum Cholesterol	185.0	100-250 mg%
Serum Triglyceride	165.0	Up to 150 mg%
Serum Cholesterol HDL	47.0	Up to 65 mg%
Serum Cholesterol LDL	105.0	Up to 125 mg%
LDL	33.0	Up to 30 mg%
S.Bilirubin(Total)	0.91	0.2-1.0mg/dl
Direct	0.51	0.0-0.25mg/dl
Indirect	0.40	
SGOT	34.0	5-35U/L
SGPT	36.0	8-40U/L
Alk Phosphatase	10.9	3-13 KA units
S. Protein(Total)	7.0	6.0-8.0mg%
Albumin	4.9	3.7-5.3mg%
Globulin	2.4	1.5 to 3.5 mg%
Blood Urea	22.0	Up to 40 mg%
S.Creatine	0.98	0.5-1.4mg/dl
S. Uric Acid	6.0	3.5-7.5mg%
GGTP	24.0	5-35 UL/dl
Fasting Blood Sugar	99.0	Up to 110 mg%
PP Blood Sugar	123.0	Up to 125 mg%
Glycosylated Hemoglobin	5.8	Below - 6.0 % -Non Diabetic control 6-7 % -Excellent control Above- 8 % -Poor control
HBA1c		
Thyrod Stimulating Hormone(TSH)	3.5	0.27-4.2

Dr. B. M. Agarwal
 Pathologist
 All test have technical limitation. Collaborative clinic pathological interpretation is mandatory. In case of disparity test may be repeated immediately. Typographical mistakes should be get correct instantly. This report is not valid for medico legal purpose.

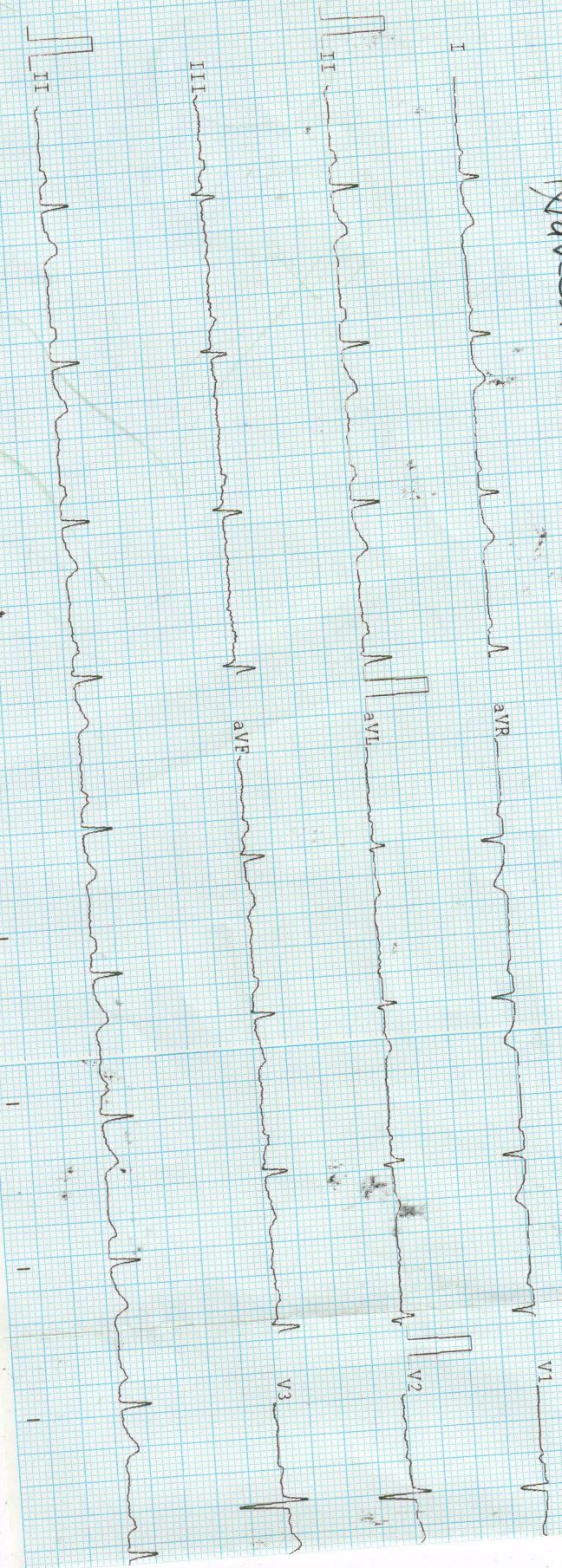


Naveen Sharma

Age - 52 Y/M


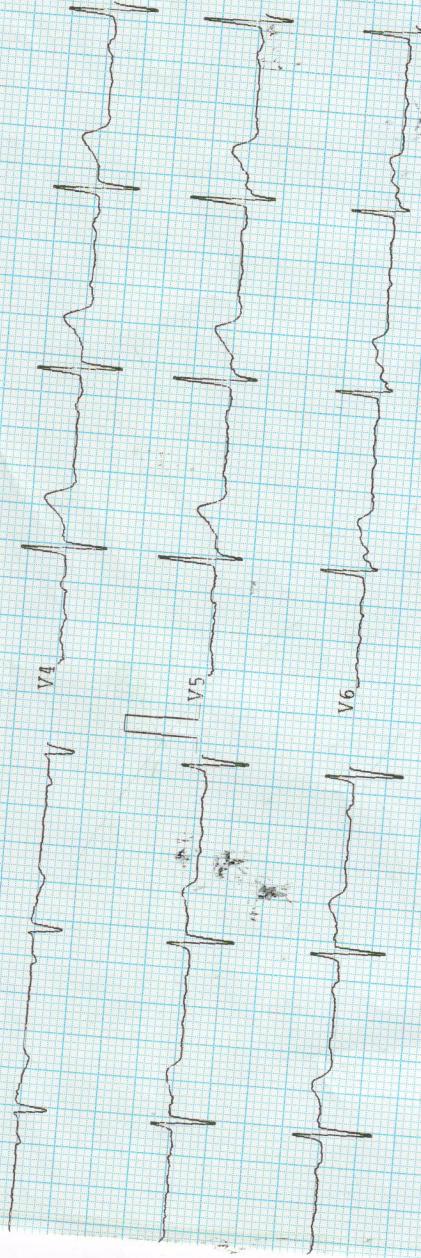
11/03/23

ARROW CE



Observations :-

HR :- 66 bpm
R-R :- 908 ms
P-R :- 127 ms
QRS :- 59 ms
QT/QTc :- 363/380 ms
P Axis :- -48 °
R Axis :- 64 °
T Axis :- 58 °



[Handwritten signature]

Remarks :-

Unconfirmed report

ARROW CE



डॉ. सविता रिडीनिक
 34, भूतल, मोहिनी अदिति आर्कड, शाहपुरा मस्जिद के पास
 भगत नगर रोड, ई-7/194, अरोरा कॉलोनी, भीपाल - 462038
 Mob. : 8989649694, 9516333619
 Clinic Registration : CL/5392/Jun/2017
 PNDT Registration : MPPCPNDT/BPL/2017/206



Name : Mrs. Naveen Sharma 59/ Male YRS./F
 Health Check up No. Date 11/3/23

WHOLE ABDOMEN ULTRASOUND REPORT

Indication :

Liver appears normal / enlarged in size and shape with smooth in outline. Normal / increased parenchymal echogenicity is noted. No E/O focal lesion / IHBR dilatation is seen. Hepatic veins and portal veins appear normal.

No E/O Subdiaphragmatic Collection.

Gall Bladder is physiologically well distended / collapsed. No E/O echogenic foci in GB lumen. GB wall is normal / thickened. No E/O pericholecystic collection. common duct reveals normal course and caliber.

Pancreas appear normal in size, shape and echo texture with smooth contour. No peripancreatic pathology seen. (Not seen due to gases) Spleen is normal / enlarged in size and normal in echo texture. IVC and aorta appear to be normal.

No evidence of lymphadenopathy is noted.

No evidence of free fluid is noted.

Right Kidney is normal in size, shape and position. Corticomedullary differentiation (CMD) is well maintained. Normal cortical thickness is noted. No E/O hydronephrosis or calculus is noted. 2.75cm size single cortical cyst noted.

PTO

Dr. Jayant Yadav, MD
 MBBS, MD (Radiologist) Reg. No. 4166
 रेडियोलॉजिस्ट

Dr. P. Savita, MD
 MBBS, MD (O&G) Reg. No. 9971
 स्त्री रोग विशेषज्ञ

Left Kidney is normal in size, shape and position. CMD is well maintained. Normal cortical thickness is noted. No E/O hydronephrosis or calculus is noted.

Urinary Bladder is well distended (physiological) / collapsed. Its contents are echo free. No E/O bladder wall thickening is noted. ~~Post void residue is insignificant.~~

Prostate is normal in size, shape and echo texture with smooth outline. No E/O focal lesion is noted.


Uterus is ante/retro verted and normal in size, shape and echotexture with smooth outline. No E/O focal lesion is noted, endometrial echo appear normal. Cervical and vaginal shadows appear normal.

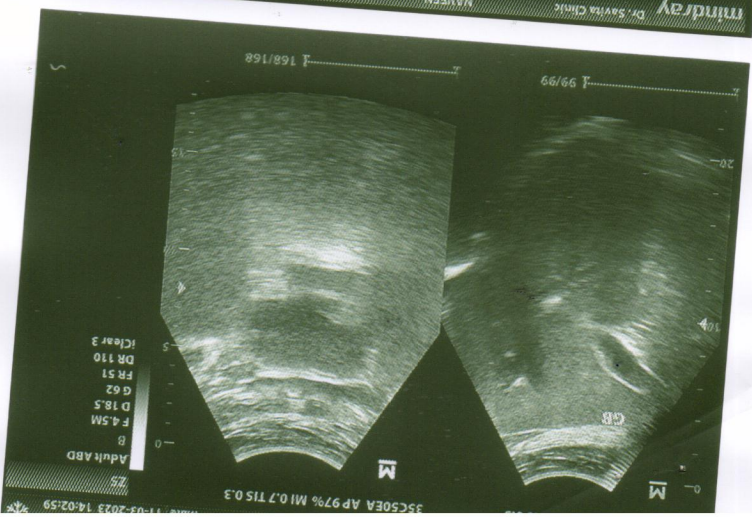
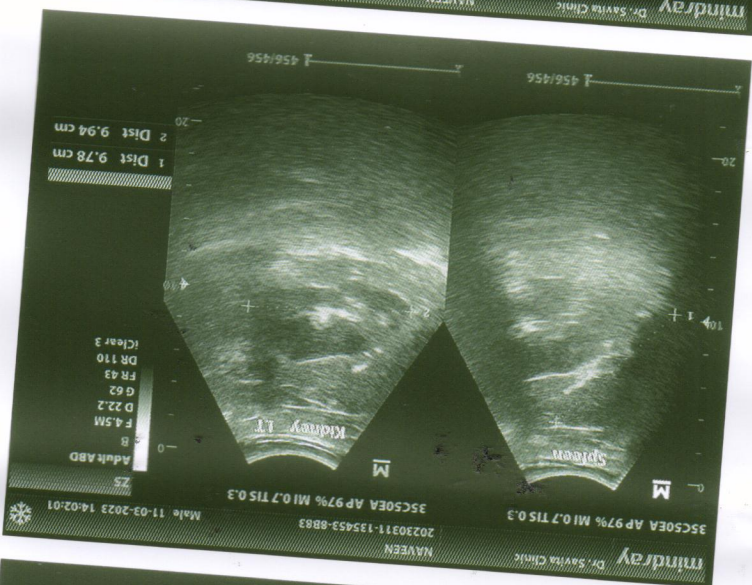
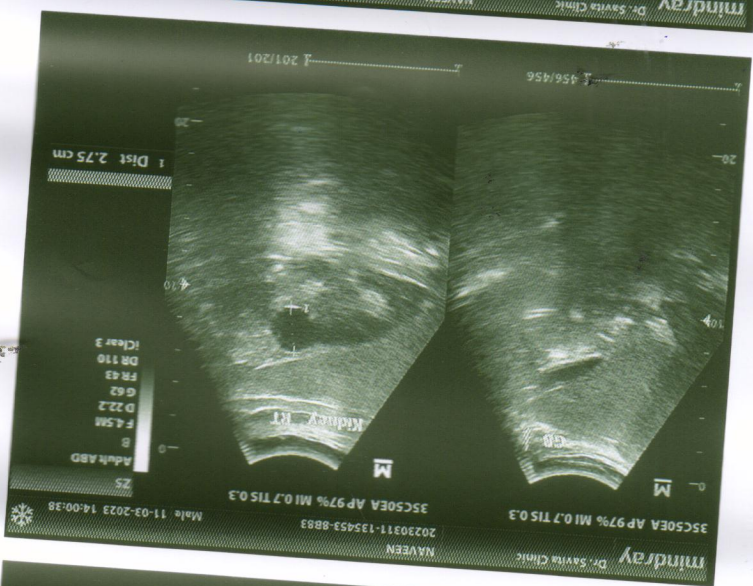
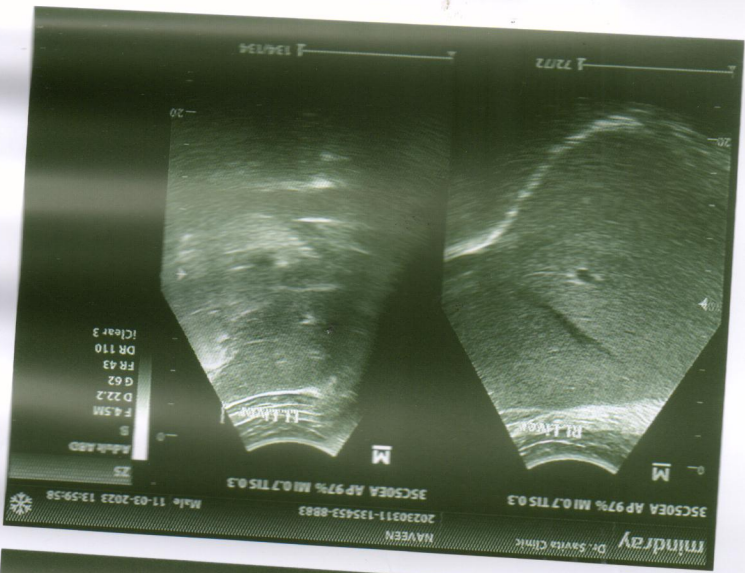
Right Ovary appears Enlarged / Normal in size, shape and echo texture.


Left Ovary appears Enlarged / Normal in size, shape and echo texture.

Impression : Normal study. Rt Renal cortical cyst - 2.75 cm ^{5/31}

Advised clinical Correlation.







Pathologist

Dr. B. M. Agarwal
MBBS, DCP
Consultant Pathologist

A. PHYSICAL EXAMINATION	
1. Colour	Pale Yellow
2. Appearance	Clear
3. Specific Gravity	Q.N.S.
B. CHEMICAL EXAMINATION	
1. Reaction	Acidic
2. Albumin	Nil
3. Sugar	Nil
4. Bile Salts	Absent
C. MICROSCOPIC EXAMINATION	
Pus Cells	2-3/HPF
R.B.C.	Nil
Epithelial Cell	1-2/HPF
Cast	Nil
Crystals (Cal. Oxa)	Nil
Bacteria	Nil
Amorphous	Nil
T. Vaginitis	Nil

URINE ANALYSIS

Pt Name :- Mr. Naveen Sharma
Age :- 52/M
Lab. No. :- 02
Date :- 11/03/2023

डिवाकट डायग्नोस्टिक सेंटर
E-7/636, पंजाब नेशनल बैंक के पास, मॉन रोड, अरुण कॉलोनी, भाोपाल (म.प्र.)
फॉ : 9826340190

