



# PARKLINE DIAGNOSTICS PVT. LTD.

L.G. 3, 4 & 5, Bhuvana Towers, S.D. Road, Secunderabad - 500 003.  
Tel : +91 40-2784 5852, 6649 1787, 7995421787, 7093445852, Fax : +91 40 2784 7864  
Email parklinediagnostics@gmail.com www.parklinediagnostics.com



NABL Accredited  
Certificate No.MC-2566

## MEDICAL EXAMINATION REPORT

Name	MS. A. Bindu madhavi		Date:	12/02/2022		
Company	C/o: mediwheel		Reg. No.:	1294125		
Contact No.	9912201318		Sex	<input checked="" type="checkbox"/> F	Age:	<input type="checkbox"/> 40
Type	Pre-Emp		Emp. No.:	75991		
	Overseas		Height	165 cm		
	Annual	<input checked="" type="checkbox"/>	Weight	85 kgs.		
Remarks	<p>USG: Grade I fatty liver.</p> <p>- (Lt) renal calculus measuring 5.0mm in the pole region. Advice follow up c Urologist.</p> <p>- Bulky (Lt) ovary c simple (Lt) ovarian cyst. Advice follow up c Gynaecologist.</p> <p>- q oral fluid intake.</p>					
				DR. PRIYANKA SANNIDHI MBBS Reg. No: 11351		
Fitness Status	Medically Fit / Unfit		Physician's Signature			



**Distant Vision : Near Vision :**

Right Eye: 6/6

With glasses / Without glasses

left Eye : 6/6

with glasses / without glasses

Colour Vision : BE normal

Right Eye: N6

With glasses / Without glasses

left Eye : N6

with glasses / without glasses

**Dr. KATTA**  
M.B.B.S., D.O., F.F.S.  
Post: 896  
**Ophthalmologist's Signature**

**Right Ear**

Hearing :

(N)

Rinee's Test ;

Weber Test :

Discharge :

NIL

**Left Ear**

Hearing :

(N)

NIL

**SYSTEMIC EXAMINATION**

Pulse : 80 bpm

B.P. : 120/80 mmHg

Lungs :

A. Shape of Chest

B/L symmetrical

B. Breath Sounds

B/L clear (+)

C. Adventitious Sounds

No

Heart :

A. Sounds

S1 S2 (+)

B. Murmurs

No murmurs

**Nervous System**

Abdomen : A. Liver

B. Spleen

C. Piles

NO

D. Any Lump

NO

A. Higher Function :

B. Cranial Nerves :

C. Sensory System :

D. Motor System :

E. Jerks :

(N)

General :

A. Hernia

B. Hydrocele

C. Varicocele

NO

Breast :

Rt

(N)

Lt.

(N)

## CANDIDATE'S DECLARATION

I hereby solemnly declare that I am not suffering from Asthma, Hypertension, Diabetes, Occult Psychological disorders or any other ailment which can be suppressed without my voluntary declaration.

Date :

*Babu Reddy*

Signature

Place :

Note : General Physical Examination and Investigation included in the health check-up Have certain limitations and may not be able to detect all latent and asymptomatic diseases. Any new symptoms developing after the health check-up or persisting thereafter should be brought to the attention of the treating physician.





# PARKLINE DIAGNOSTICS PVT. LTD.

L.G. 3, 4 & 5, Bhuvana Towers, Sarojini Devi Road, Secunderabad - 500 003 Tel. +91 40-2784 5852  
6649 1787 Fax :+91 40 2784 7864 Email : parklinediagnostics@gmail.com www.parklinediagnostics.com



NABL Accredited  
Certificate No. MC-2566

## TEST REPORT

Name : Ms . A BINDU MADHAVI [75991]  
Age / Gender : 40 Years / Female  
Ref.By : Medi Wheel  
Req. No : BIL1794125

TID : UMR0713732  
Registered on : 12-Feb-2022 09:55 AM  
Reported On : 12-Feb-2022 02:17 PM

### DEPARTMENT OF ULTRASOUND Ultrasound Whole Abdomen

**LIVER** : Normal in size (12.9 cm) and increased echotexture. No focal lesions.  
No IHBD /CBD dilatation. Portal vein is normal.

**SPLEEN** : Normal in size (9.7 cm) and echotexture. No focal lesion seen.

**GALL BLADDER** : Well distended. No sludge / gall stones / sol.  
Gall bladder - Wall thickness is normal.  
No pericholecystic oedema.

**PANCREAS** : Normal in size and echotexture.No calcification / sol.  
Pancreatic duct is normal. No peripancreatic fluid collection.

**RIGHT KIDNEY** : Normal in size and echotexture.  
Cortical thickness is normal.  
No evidence of calculi / sol.  
Pelvi calyceal system is normal.  
Right kidney measuring : 9.4 x 3.8 cm.

**LEFT KIDNEY** : Normal in size and echotexture.  
Cortical thickness is normal.  
Pelvi calyceal system is normal.  
Left kidney measures: 10.6 x 4.5 cm  
Calculus measuring 5mm in left polar region.

**URINARY BLADDER** : Well distended.Normal in contour.  
Wall thickness is normal. No calculus / sol.

**UTERUS** : Anteverted measuring 7.3 x 3.5 x 4.0 cm  
Normal in size and echotexture.  
No space occupying lesion is seen.  
Cervix is normal in size and echopattern.

**ENDOMETRIUM** : 2 mm -Normal.

**Right ovary** : 2.6 x 1.3 cm ,Normal in size and echotexture  
**Left ovary** : 5.3 x 3.4 cm ,, bulky in and normal echotexture.  
Simple cyst measuring 3.0 x 2.7 cm in left ovary.

No adnexal mass seen.

No fluid in POD.

The Test marked with\*are not accredited by NABL

Lab Timings (Weekdays) : 7.00 am to 8.30 pm

Sundays & Holidays : 7.00 am to 1.00 pm

Radiologists Timings (Weekdays) : 7.30 am to 1.30 pm

5.30 pm to 7.45 pm  
Sundays & Holidays : 7.30 am to 9.30 am

Free Home Visit for Sample Collection.

Call : 7995421787, 7093445852, 8121147282, 9885202212



# PARKLINE DIAGNOSTICS PVT. LTD.

L.G. 3, 4 & 5, Bhuvana Towers, Sarojini Devi Road, Secunderabad - 500 003 Tel. +91 40-2784 5852  
6649 1787 Fax :+91 40 2784 7864 Email : parklinediagnostics@gmail.com www.parklinediagnostics.com



NABL Accredited  
Certificate No. MC-2566

## TEST REPORT

Name : Ms . A BINDU MADHAVI [75991]  
Age / Gender : 40 Years / Female  
Ref.By : Medi Wheel  
Req. No : BIL1794125

TID : UMR0713732  
Registered on : 12-Feb-2022 09:55 AM  
Reported On : 12-Feb-2022 02:17 PM

### IMPRESSION :

- \* Grade I fatty liver.
- \* Non obstructive left renal calculus.
- \* Bulky left ovary with simple left ovarian cyst.

Clinical correlation.

*for Dings*  
Dr.Karuna Belide  
Consultant Radiologist

The Test marked with\*are not accredited by NABL

Lab Timings (Weekdays) : 7.00 am to 8.30 pm

Sundays & Holidays : 7.00 am to 1.00 pm

Radiologists Timings (Weekdays) : 7.30 am to 1.30 pm

Sundays & Holidays : 7.30 am to 9.30 am

Free Home Visit for Sample Collection.

Call : 7995421787, 7093445852, 8121147282, 9885202212



# PARKLINE DIAGNOSTICS PVT. LTD.

L.G. 3, 4 & 5, Bhuvana Towers, Sarojini Devi Road, Secunderabad - 500 003 Tel. +91 40-2784 5852  
6649 1787 Fax :+91 40 2784 7864 Email : parklinediagnostics@gmail.com www.parklinediagnostics.com



NABL Accredited  
Certificate No. MC-2566

## TEST REPORT

Name : Ms . A BINDU MADHAVI [75991]  
Age / Gender : 40 Years / Female  
Ref.By : Medi Wheel  
Req. No : BIL1794125

TID : UMR0713732  
Registered on : 12-Feb-2022 09:55 AM  
Reported On : 12-Feb-2022 11:13 AM

### DEPARTMENT OF X-RAY X-Ray Chest PA View

Small dense opacities left mid zone - End on vessels / Old healed infection.

Cardiac thoracic ratio is normal.

Hila are normal.

C P angles are free.

Bony cage is normal.

Soft tissues are normal.

### Clinical correlation.

  
Dr. D.J. MOHAN  
MD DMRD  
(Reg No. 8995)  
Consultant Radiologist

The Test marked with\*are not accredited by NABL

Lab Timings (Weekdays) : 7.00 am to 8.30 pm

Sundays & Holidays : 7.00 am to 1.00 pm

Radiologists Timings (Weekdays) : 7.30 am to 1.30 pm

Sundays & Holidays

Page 1 of 1  
& 5.30 pm to 7.45 pm

: 7.30 am to 9.30 am



MSA BINDU MADHAVI  
Female 40Years

HR : 93 bpm  
P : 103 ms  
PR : 150 ms  
QRS : 85 ms  
QT/QTc : 352/438 ms  
P/QRS/T : 61/69/52 °  
RV5/SV1 : 1.531/1.050 mV

Diagnosis Information:  
Sinus Rhythm  
\*\*\*Normal ECG\*\*\*

Report Confirmed by:

NSR  
WNL  
            
CS

Dr. NAVEEN KUMAR .C  
M.D., D.M.  
Consultant Cardiologist  
Reg. No. 52291

PATIENT SUMMARY REPORT

LINE DIAGNOSTICS PVT.LTD

: 1794125  
: MS A BINDU MADHAVI  
SEX : 40 / FEMALE

HEIGHT (cm) : 165  
WEIGHT (kg) : 75  
PROTOCOL : MODIFIED BRUCE

REF. BY : MEDIWHEEL  
DONE BY : DR NAVEEN KUMAR C  
TECHNICIAN : G.M.SURESH

12-02-2022, 11:08:00  
RAC

HISTORY :  
DIAGNOSTIC INFORMATION :

REASON FOR TEST : Routine Check Up.

CLINICAL FACTOR : None.

ACTIVITY : Very Active.

TEST INVESTIGATION : ECG

CRITERIA FOR TERMINATION : THR ACHIEVED

EXERCISE TOLERANCE : Good (> 10 METS).

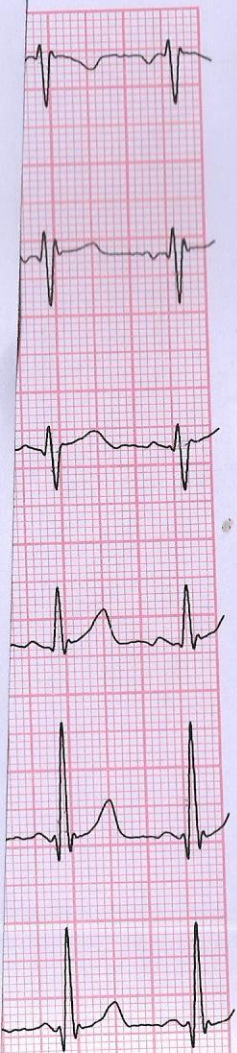
EXERCISE INDUCED ARRHYTHMIAS : No.

HEART RATE RESPONSE : Normal.

BLOOD PRESSURE RESPONSE : Normal.

IMPRESSION :

COMMENTS : Negative for significant ischemia



mm/Sec

Confirmed By   
**DR. NAVEEN KUMAR .C**

Signature M.D., D.M.  
Consultant Cardiologist  
Reg. No. 52291