



Name : Mrs. MUKTA ANKUSH WARGHADE (29/F)

Date : 27/08/2022

Address : NEAR TUKAI MALA AT BAKORI PO KESNAND TAL HAVELI DIST PUNE, PUNE,
PUNE, MAHARASHTRA, INDIA

Examined by:

UHID : MHN1.0000124758

Package : MediWheel Full Body Health Checkup Female Below 40
Package

AHC No : NSKAH27439



CHIEF COMPLAINTS

For corporate health checkup
No specific complaints

- level ground walking



DRUG ALLERGY

NO KNOWN ALLERGY

:27/08/2022



SYSTEMIC REVIEW

Cardiovascular system

- Nil Significant



Past medical history

Do you have any allergies? - No

Do you have any drug allergies? - No

Past medical history - nil significant

Covid 19 - No



Surgical history

Lower segment caesarean section - done-2



Personal history

Marital status - Married

Diet - Mixed Diet

Alcohol - does not consume alcohol

Smoking - No

Chews tobacco - No

Chews paan - No

Uses snuff - No

Illicit substance use - No

Physical activity - Active



Family history

Father - alive

Aged - 60 yrs

Mother - alive

Aged - 55 yrs

Brothers - 1

Sisters - 1

Coronary artery disease - none

Cancer - None

PHYSICAL EXAMINATION



General

General appearance - normal

Build - normal

Height - 143

Weight - 66.6

BMI - 32.57

Pallor - No

Oedema - no

Temperature - 98

SpO2 - 98



Cardiovascular system

Heart rate (Per minute) - 100

Rhythm - Regular

- B.P. Supine

Systolic(mm of Hg) - 120

Diastolic(mm of Hg) - 80

Heart sounds - S1S2+

Swaminarayan Nagar, Off Mumbai-Agra Highway,
Panchvati, Nashik - 422 003.

+91 - 253 - 2510250 / 350 / 450 / 550 / 750

apollonashik@apollohospitals.com

www.askapallo.com

QFAHN/BILL/003/V1



Name : Mrs. MUKTA ANKUSH WARGHADE (29
/F)

UHID : MHN1.0000124758

Date : 27/08/2022

Package : MediWheel Full Body Health Checkup Female Below 40 Package

AHC No : NSKAH27439

Respiratory system

Breath sounds - Normal vesicular breath sounds

Abdomen

Organomegaly - No

Tenderness - No



Printed By : Shweta Sharad Shardul



Name : Mrs. MUKTA ANKUSH WARGHADE (29 /F)

UHID : MHN1.0000124758

Date : 27/08/2022

Package : MediWheel Full Body Health Checkup Female Below 40 Package

AHC No : NSKAH27439

URINE ROUTINE (CUE)

Test Name	Result	Unit	Level	Range
Specific Gravity	1.025		●	1.016-1.026
Color,:	PALE YELLOW			
Transparency:	Clear			
Reaction:	Acidic			7.2-7.8
Protein :	Nil			
Sugar:	Nil			
pH	5.5		●	4.6-8
Blood:	Negative			
Ketone	Negative			
Bile Pigments:	Negative			
Bile Salts :	Negative			
Urobilinogen	Normal			
Nitrite	Negative			
RBC	0-1	/hpf		0-2
WBC/Pus Cells	0-2/hpf	/hpf		
Tc/Sqc(Transitional/Squamous epithelial cells)	3-4/hpf	/hpf		

Lymphocytes	40	%	●	20-45
Eosinophils	03	%	●	1-6
Monocytes	04	%	●	1-10
Basophils	00	%	●	0-1
ERYTHROCYTE SEDIMENTATION RATE (ESR)	21 *	mm/1st hr	●	0-20

BLOOD GROUPING AND TYPING (ABO and Rh)

Test Name	Result	Unit	Level	Range
ABO Group:	B			
Rh (D) Type:	POSITIVE			

LIVER FUNCTION TEST (PACKAGE)

Test Name	Result	Unit	Level	Range
ALT(SGPT) - SERUM / PLASMA	49	U/L	●	30-65
ALBUMIN - SERUM	4.6	g/dL	●	3.5-5
GLOBULIN - SERUM: (Calculated)	3.5	g/dL	●	1.8-3.6
ALBUMIN:GLOBULIN - SERUM(RATIO) (Calculated)	1.1		●	1.1-1.8
ALKALINE PHOSPHATASE - SERUM/PLASMA	65	U/L	●	0-100
AST (SGOT) - SERUM	39 *	U/L	●	15-37
BILIRUBIN, TOTAL - SERUM	0.4	mg/dL	●	0.0-1.0

C B C WITH ESR (AUTOMATION + STANDARD METHOD)

Test Name	Result	Unit	Level	Range
Hemoglobin	13.1	g/dl	●	11.0-16.0
Haematocrit	39.9	%	●	34.0-48.0
RBC COUNT	4.4	Million/ul	●	3.7-5.6
MCV	90.1	fl	●	75.0-95.0
MCH	29.5	pg	●	26.0-32.0
MCHC	32.7	g/dl	●	31.0-36.0
RDW	13.9	%	●	11-16
Platelet Count(Optical/Impedance)	202	10 ³ /m ³	●	140-440
TLC Count	5.8	10 ³ /m ³	●	4.0-11.0
Neutrophils	53	%	●	40-75

LIPID PROFILE TEST (PACKAGE)

Test Name	Result	Unit	Level	Range
Total Cholesterol	153	mg/dL	●	0-200

CREATININE - SERUM / PLASMA

Test Name	Result	Unit	Level	Range
CREATININE - SERUM / PLASMA	0.8	mg/dL	●	0.6-1.0

LIVER FUNCTION TEST (PACKAGE)

Test Name	Result	Unit	Level	Range
GGTP: GAMMA GLUTAMYL TRANSPEPTIDASE - SERUM	81 *	U/L	●	0-50

● Within Normal Range ● Borderline High/Low ● Out of Range



Name : Mrs. MUKTA ANKUSH WARGHADE (29 /F)

UHID : MHN1.0000124758

Date : 27/08/2022

Package : MediWheel Full Body Health Checkup Female Below 40 Package

AHC No : NSKAH27439

GLUCOSE - SERUM / PLASMA (FASTING)

Test Name	Result	Unit	Level	Range
Glucose - Plasma (Fasting)	87	mg/dL	●	70-100

URINE
GLUCOSE(FASTING):
(Strip Method)

Nil

TOTAL T3: TRI IODOTHYRONINE - SERUM 194 ng/dL ●

Healthy Adults: 69 - 215
Pregnant Women: 1st Trimester:121-308
2nd & 3rd Trimesters:152-362

GLUCOSE - SERUM / PLASMA (POST PRANDIAL)

Test Name	Result	Unit	Level	Range
Glucose - Plasma (POST PRANDIAL)	98	mg/dL	●	70-140

URINE
GLUCOSE(POST PRANDIAL):(Strip Method)

Nil

TOTAL T4: THYROXINE - SERUM 7.7 µg/dL ●

Healthy Adults: 5.2 - 12.7
Pregnancy:1st Trimester:7.8 - 16.2
2nd & 3rd Trimesters: 9.1 - 18.3

GLYCOSYLATED HEMOGLOBIN (HbA1C) - WHOLE BLOOD

Test Name	Result	Unit	Level	Range
Glycosylated Hemoglobin (HbA1c)	5.1	%	●	0.0-6.0

Mean Plasma Glucose (MPG) Estimate:

104.26 mg/dL

LIPID PROFILE TEST (PACKAGE)

Test Name	Result	Unit	Level	Range
Triglycerides - Serum	153 *	mg/dL	●	0-150

THYROID PROFILE - I(T3,T4 AND TSH)

Test Name	Result	Unit	Level	Range
TSH: THYROID STIMULATING HORMONE - SERUM	3.9	uIU/mL	●	Euthyroid: 0.3 - 4.5 Hypothyroid: 7.1 - >75.0 Pregnancy(All Trimesters):0.2 -3.5

LIPID PROFILE TEST (PACKAGE)

Test Name	Result	Unit	Level	Range
HDL CHOLESTEROL - SERUM / PLASMA	46	mg/dL	●	40-60
TOTAL CHOLESTEROL/HDL CHOLESTEROL RATIO(Calculated)	3.3		●	0.0-4.5
LDL Cholesterol (Direct LDL)	100	mg/dL	●	

UREA - SERUM / PLASMA

Test Name	Result	Unit	Level	Range
UREA - SERUM / PLASMA	18	mg/dL	●	15-38
UREA NITROGEN SERUM/PLASMA: (Calculated)	8	mg/dL	●	7-18

LIVER FUNCTION TEST (PACKAGE)

Test Name	Result	Unit	Level	Range
PROTEIN, TOTAL - SERUM / PLASMA	8.1	g/dL	●	6.4-8.2
PROTEIN, TOTAL - SERUM / PLASMA	8.1	g/dL	●	6.4-8.2

URIC ACID - SERUM

Test Name	Result	Unit	Level	Range
URIC ACID - SERUM	4.4	mg/dL	●	2.6-6.0

THYROID PROFILE - I(T3,T4 AND TSH)

Test Name	Result	Unit	Level	Range
-----------	--------	------	-------	-------

LIVER FUNCTION TEST (PACKAGE)

Test Name	Result	Unit	Level	Range
-----------	--------	------	-------	-------

● Within Normal Range ● Borderline High/Low ● Out of Range

Swaminarayan Nagar, Off Mumbai-Agra Highway,
Panchvati, Nashik - 422 003.

+91 - 253 - 2510250 / 350 / 450 / 550 / 750

apollonashik@apollohospitals.com

www.askapollo.com

QFAHN/BILL/003/V1



Apollo
HOSPITALS
NASHIK

Name : Mrs. MUKTA ANKUSH WARGHADE (29
/F)

UHID : MHN1.0000124758

Date : 27/08/2022

Package : MediWheel Full Body Health Checkup Female Below 40 Package

AHC No : NSKAH27439

BILIRUBIN CONJUGATED (DIRECT) - SERUM	0.2	mg/dL ●	0.0-0.3
BILIRUBIN UNCONJUGATED - SERUM(Calculated)	0.2	mg/dL ●	0.0-0.7

CARDIAC STRESS TEST - (TMT)

ECG

ULTRASOUND - WHOLE ABDOMEN

Grade I fatty infiltration of liver.

Both ovaries are mildly bulky in size and show multiple
small follicles arranged peripherally with mild echogenic
stroma, s/o PCOD- like morphology of both the ovaries.

No other significant abnormality is detected.

Suggest : Clinical and laboratory correlation.

X-RAY CHEST PA

No significant abnormality is detected.

Suggest : Clinical correlation.

INVESTIGATIONS NOT DONE / NOT YET REPORTED / NOT
PART OF PACKAGE(LAB RADIOLOGY & CARDIOLOGY)

Haematology

STOOL ROUTINE

Histopathology

CERVICAL/VAGINAL SMEAR II SLIDE

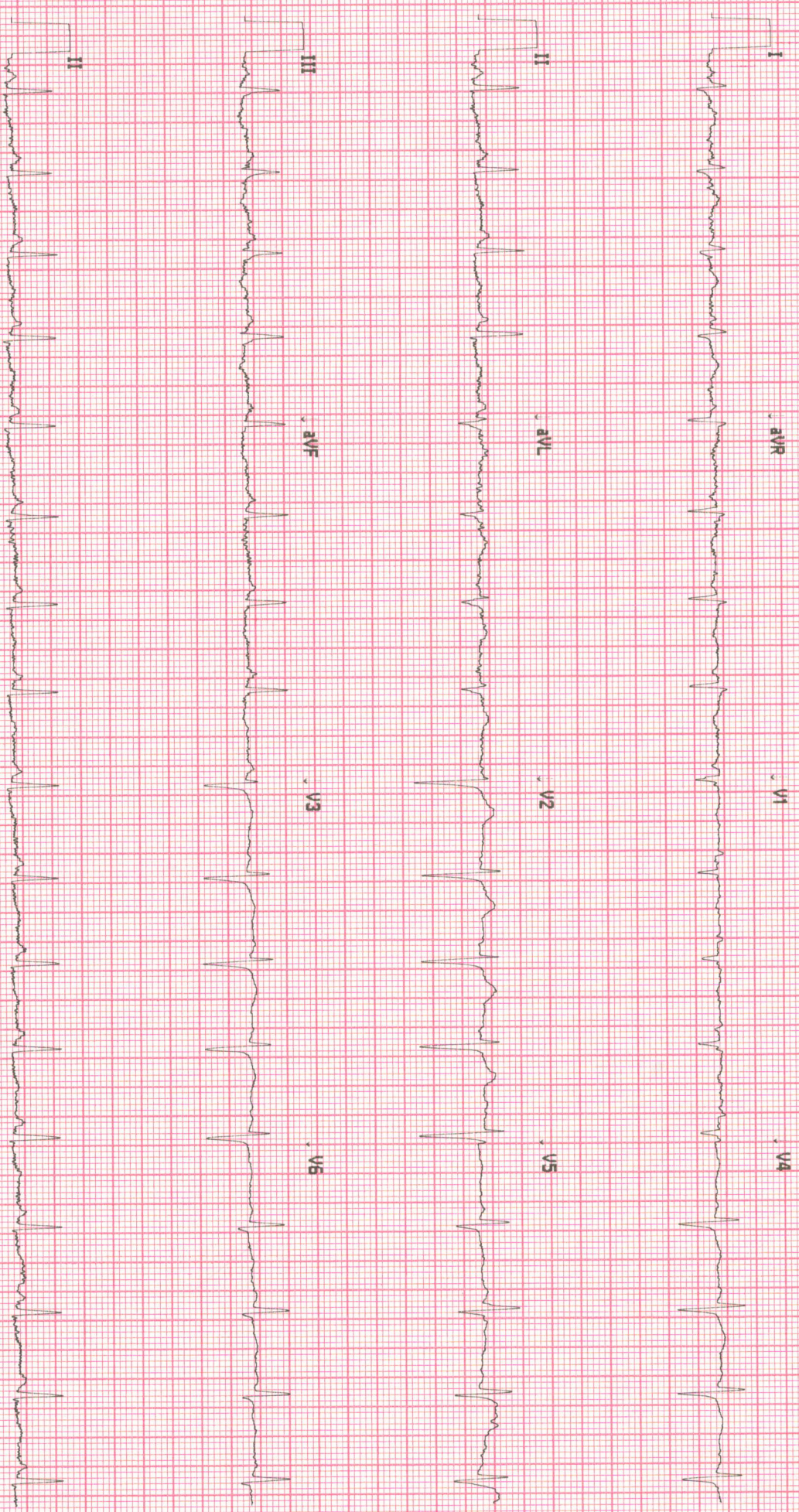
● Within Normal Range ● Borderline High/Low ● Out of Range

Marghade, Mukta
ID:
DOB:
29yr, Female

27-Aug-2022 10:40:34

Vent rate: 100 BPM
PR int: 126 ms
QRS dur: 93 ms
QT/QTc: 346/403 ms
P-R-T axes: 67 89 -19

SINUS TACHYCARDIA
NONSPECIFIC ST & T-WAVE ABNORMALITY
ABNORMAL ECG
UNCONFIRMED REPORT



113500189213

No Site Name

Site # 0 Cart # 2

Version 2.0.4.0 Sequence #19926 25mm/s 10mm/mV 0.05-40 Hz



Screening Echocardiography Report

Name: - Mrs. MUKTA ANKUSH WARGHADE
UHID No: - MHN1. 0000124758
Referred by: -Dr. Sudhir Shetkar
Echo window: - Good


Age/Sex: 29/F
DATE: 27/08/2022
Echo No: -30260

Normal LV systolic function. No RWMA at rest.
Normal RV systolic function.
LV diastolic dysfunction.
AO/LA= 27 mm/ 32 mm, LVIDd/LVIDs= 48 mm/ 27 mm, IVS/PW= 09 mm/10 mm.
No PAH.
No Clot/ Vegetation/Pericardial effusion.
No Coarctation.

Normal Echo Study.

Impression: -

Normal LV systolic function. No RWMA at rest.
Normal RV systolic function.
LV diastolic dysfunction.
No PAH.
No clot/ vegetation/pericardial effusion.
No Coarctation.


DR. Niramal Kolate.



Radiology

Patient Details : Mrs. MUKTA ANKUSH WARGHADE | Female | 29Yr 7Mth 2Days

UHID : MHN1.0000124758 **Patient Location:** AHC

Patient Identifier: NSKAH27439



DRN : 122032602

Completed on : 27-AUG-2022 10:45

Ref Doctor : DR. Rajashri Dhongade

X-RAY CHEST PA

Both lung fields are clear.

Both hila are normal in size and position.

Costophrenic and cardiophrenic angles are clear.

Cardiac size and contour are within normal limits.

Visualized rib cage is normal.


Visualized soft tissues are normal.

Impression

No significant abnormality is detected.


Suggest : Clinical correlation.

---- END OF THE REPORT ----


Dr.Samruddhi Sonawane

Consultant - Radiology

Radiology

Patient Details : Mrs. MUKTA ANKUSH WARGHADE | Female | 29Yr 7Mth 2Days
UHID : MHN1.0000124758 **Patient Location:** AHC
Patient Identifier: NSKAH27439 
DRN : 222019347 **Completed on :** 27-AUG-2022 12:02
Ref Doctor : DR. Rajashri Dhongade

ULTRASOUND - WHOLE ABDOMEN

LIVER : Normal in size and measures 14cm. Diffuse increase in echogenicity of the liver parenchyma is suggestive of fatty infiltration. No I.H.B.D./ focal lesions.

PORTAL VEIN: Normal in size.

GALL BLADDER: Well distended with normal walls and lumen.
No calculi/pericholecystic fluid.

COMMON BILE DUCT: Normal in size.

PANCREAS : Visualized portion of head and body of pancreas appears normal in size and echotexture. Rest of the pancreas is obscured due to bowel gases.

AORTA, IVC and para aortic areas are normal.

SPLEEN : Normal in size (11.3cm) and echotexture.

KIDNEYS: Both kidneys are normal in site, size and echotexture.
No evidence of calculi/ hydronephrosis.
Right kidney measures: 10.7 x 3.8 cm.
Left kidney measures : 11.5 x 4.0 cm.

URINARY BLADDER: Well distended with normal walls.
No evidence of calculi/ growth/ diverticula .

UTERUS: Anteverted. Normal in size and echotexture.
Uterus measures : 7.0 x 4.9 x 3.0 cm.
Combined endometrial thickness is normal and measures 7mm.



Mrs. MUKTA ANKUSH WARGHADE

MHN1.0000124758

NSKAH27439

ULTRASOUND - WHOLE ABDOMEN

OVARIES:

Right ovary volume : 19 cc.

Left ovary volume : 10 cc.

Both (right>left) ovaries appear mildly bulky in size and show multiple small follicles arranged peripherally with mild echogenic stroma.

Visualized bowel loops appear grossly normal.

No evidence of any free fluid in the peritoneal cavity.

Impression

Grade I fatty infiltration of liver.

Both ovaries are mildly bulky in size and show multiple small follicles arranged peripherally with mild echogenic stroma, s/o PCOD- like morphology of both the ovaries.

No other significant abnormality is detected.

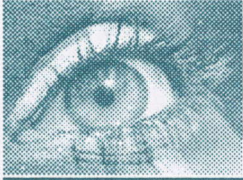
Suggest : Clinical and laboratory correlation.

--- END OF THE REPORT ---

Dr. Harshal S Dhongade

Consultant - Radiology

ONE EYED



OPHTHALMOLOGY



Name : Mrs. Mukta Warghade
 Occupation : _____
 Age : 29 Sex : Male Female S/M/W/D
 Address : NISIC
 Tel. No. _____

Date 27/08/20 UNIT _____
 Room No. _____ Out Patient
 Ref. Physician : _____
 Copies to : _____

REPORT ON OPHTHALMIC EXAMINATION

HISTORY : NO eye has been but
up eye PD surgery @ 50 & repeat vision at 2
 PRESENT COMPLAINT : Itching, Blurring done with.
 PAST HISTORY : DM / HTN / ALLERGY

ON EXAMINATION

VISION :

		RE RIGHT				LE LEFT			
		VA	No	pc	VA	pc			
PGP		SPH	CYL	AXIS	VA	SPH	CYL	AXIS	VA
DIST		_____				_____			
NEAR		_____				_____			

AR / Retinoscopy :

RIGHT			LEFT		
SPH	CYL	AXIS	SPH	CYL	AXIS
_____			-ERR		

Refraction or Acceptance :


		RIGHT				LEFT			
		SPH	CYL	AXIS	VA	SPH	CYL	AXIS	VA
DIST		_____				_____			
NEAR		_____				_____			

[Signature]
CONSULTANT OPTOMETRIST

Shall eye -
pupil - 4mm

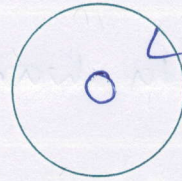
Anterior Segment :

RE



Empty socket
Enophthalmos


LE




Aphakia

Fundus :

RE



LE



glaucoma

Diagnosis :

Advise / Rx :

Refer to Retina specialist for further mg.

Orbital eye outward

Tears left eye

H Swaminarayan Nagar, Off Mumbai-Agra Highway,
Panchvati, Nashik - 422 003.

+91- 253 - 2510250 / 350 / 450 / 550 / 750

apollonashik@apollohospitals.com

www.askapollo.com

QFAHN/BILL/003/V1



27/8/22

Mrs Mukta

1A.

- Missing \bar{c} $\frac{7}{7}$

- class I malocclusion unilaterally.

- No Caries present

Adm. -

Not Reg

Good oral status.