

S. Singh

ONEPLUS ULTRAS 5 PRO LAB
47, Harsh Vihar, Pitam Pura,
De'hi-110034
Ph. 011-42460101, 9599913051
E-mail: oneplusul@gmail.com




Dr. NIKHIL AGGARWAL
MBBS, MD
Regn. No. DMC-R-1436

Wingh

ONEPLUS ULTRASOUND LAB
47, Harch Vihar, Pitam Pura,
Delhi-110034
Ph. 011-42480101, 9599913051
E-mail: oneplusul@gmail.com

S. Nitik
Dr. NITIK AGARWAL
MBBS, MD
Regn. No. DMC-R-1436





OnePLUS

Ultrasound Lab

Dr. Nitin Agarwal

Pathologist & Director
Ex. Sr. Res. MAMC
& Lok Nayak Hospital
Ex. Chief of Lab Dr. Lal Path Labs.

Dr. Pooja (Garg) Agarwal

Radiologist & Director
MAMC & Lok Nayak Hospital



NAME	:Mr. NAGENDRA SINGH	Barcode No	:10134292
AGE/GENDER	:43 YRS/Male	SPECIMEN DATE	:24/Dec/2022 10:12AM
PATIENT ID	:106723	SPECIMEN RECEIVED	:24/Dec/2022 10:27AM
REFERRED BY	:Dr. MEDIWHEEL	REPORT DATE	:24/Dec/2022 03:26PM
CENTRE NAME	:ONEPLUS ULTRASOUND LAB	LAB NO.	:012212240017

Test Name	Result	Unit	Ref. Range
-----------	--------	------	------------

HAEMATOLOGY

Health checkup 2 Male

Glycosylated Hemoglobin (HbA1c)	5.6	%	Non Diabetic adults <5.7 Prediabetic (at risk) 5.7-6.4 Diabetes >6.4
Estimated average blood glucose (eag)	114		

Reference range (mg/dl):

90 - 120:Excellent control, 121 - 150:Good Control, 151 - 180:Average Control, 181 - 210:Action Suggested

>211:Panic value

BLOOD GROUP (ABO)	O
Rh typing	POSITIVE


NOTE :

- * Apart from major A,B,H antigens which are used for ABO grouping and Rh typing, many minor blood group antigens exist. Agglutination may also vary according to titre of antigen and antibody.
- * So before transfusion, reconfirmation of blood group as well as cross-matching is needed.
- * Presence of maternal antibodies in newborns, may interfere with blood grouping.
- * Auto agglutination (due to cold antibody, falciparum malaria, sepsis, internal malignancy etc.) may also cause erroneous result.

CBC

Haemoglobin	15.6	g/dl	13.0-17.0
Total Leucocyte Count	5700	/cumm	4000-10000
Differential leucocyte count			
Neutrophils	68.1	%	40-80
Lymphocyte	26.20	%	20-40
Monocytes	3.70	%	2-10
Eosinophils	01	%	1-6
Basophils	01	%	0-2
RBC Count	5.40	million/cumm	4.5 - 5.5

Checked By.


DR. NITIN AGARWAL
MBBS, MD (Pathology)
DMC/R/01426

47, Harsh Vihar, Pitampura, New Delhi-110034 | Ph.: 011-42480101, 9599913051

E-mail: oneplusul@gmail.com | Web.: www.oneplusul.in

Page 1 of 5

Clinical correlation is essential for final diagnosis. * If test results are unsatisfactory please contact personally or on phone. * This report is for perusal of doctors only. * All disputes Subject to Delhi Jurisdiction only. * Not for medicolegal purposes. * All congenital anomalies in a foetus may not be diagnosed in routine obstetric ultrasound.



OnePLUS

Ultrasound Lab

Dr. Nitin Agarwal

Pathologist & Director

Ex. Sr. Res. MAMC

& Lok Nayak Hospital

Ex. Chief of Lab Dr. Lal Path Labs.

Dr. Pooja (Garg) Agarwal

Radiologist & Director

MAMC & Lok Nayak Hospital



NAME	: Mr. NAGENDRA SINGH	Barcode No	: 10134292
AGE/GENDER	: 43 YRS/Male	SPECIMEN DATE	: 24/Dec/2022 10:12AM
PATIENT ID	: 106723	SPECIMEN RECEIVED	: 24/Dec/2022 10:27AM
REFERRED BY	: Dr. MEDIWHEEL	REPORT DATE	: 24/Dec/2022 03:26PM
CENTRE NAME	: ONEPLUS ULTRASOUND LAB	LAB NO.	: 012212240017

Test Name	Result	Unit	Ref. Range
PCV(Hematocrit)	50	%	40-50
MCV	92.9	fL	83-101
MCH	29	Pg	27-32
MCHC	31.2	G/dL	32-35
Platelet count	186000	/cumm	150000-450000
RDW-CV	14.3	%	11.4-14.0
ESR(WESTEGRENs METHOD)	12	mm in 1st hr	0-20

BIOCHEMISTRY

Blood sugar fasting	113	mg/dL	70-110
Blood sugar pp	101	mg/dL	70.0-140.0
Bun (blood urea nitrogen)	13.60	mg/dl	8.9-21.6
Uric acid, serum	4.6	mg/dl	3.5-7.2
Creatinine, serum	0.9	mg/dl	0.60-1.2

LFT(LIVER FUNCTION TEST)

Bilirubin Total	0.53	mg/dl	0.1-1.2
Bilirubin Conjugated	0.24	mg/dl	0-0.4
Bilirubin Unconjugated	0.29	mg/dl	up to 0.7
SGOT (AST)	33	U/L	0-46
SGPT (ALT)	70	U/L	0-49
Alkaline phosphatase	105	U/L	40-129
Gamma glutamyl transpeptidase	28	U/L	10-45
Total Protein	6.9	gm/dl	6.60 - 8.70
Albumin serum	3.9	g/dL	3.0-5.2
Globulin	3.00	gm/dl	1.8-3.4
Albumin/Globulin Ratio	1.30		1.10 - 2.50

LIPID PROFILE

Cholesterol	195	mg/dl	50-200
Triglycerides	117	mg/dL	25-150

Checked By.

DR. NITIN AGARWAL
 M.B.B.S., MD (Path)
 PMC/R/01436

47, Harsh Vihar, Pitampura, New Delhi-110034 | Ph.: 011-42480101, 9599913051
 E-mail: oneplusul@gmail.com | Web.: www.oneplusul.in

Clinical correlation is essential for final diagnosis. * If test results are unsatisfactory please contact personally or on phone. * This report is for perusal of doctors only. * All disputes Subject to Delhi Jurisdiction only. * Not for medicolegal purposes. * All congenital anomalies in a foetus may not be diagnosed in routine obstetric ultrasound.



OnePLUS Ultrasound Lab

Dr. Nitin Agarwal

Pathologist & Director
Ex. Sr. Res. MAMC
& Lok Nayak Hospital

Ex. Chief of Lab Dr. Lal Path Labs.

Dr. Pooja (Garg) Agarwal

Radiologist & Director
MAMC & Lok Nayak Hospital



NAME	QUALITY FIRST... MR. NAGENDRA SINGH	Barcode No	:10134292
AGE/GENDER	:43 YRS/Male	SPECIMEN DATE	:24/Dec/2022 10:12AM
PATIENT ID	:106723	SPECIMEN RECEIVED	:24/Dec/2022 10:27AM
REFERRED BY	:Dr. MEDIWHEEL	REPORT DATE	:24/Dec/2022 03:26PM
CENTRE NAME	:ONEPLUS ULTRASOUND LAB	LAB NO.	:012212240017

Test Name	Result	Unit	Ref. Range
HDL Cholesterol	46	mg/dL	40 - 60
LDL cholesterol	126	mg/dL	<130
VLDL cholesterol	23.4	mg/dL	5-40
Cholesterol/HDL Ratio	4.2		Low Risk 3.3-4.97 Average Risk 4.4-7.1 Moderate Risk 7.1-11.0 High Risk >11.0
LDL/HDL Ratio	2.7		0 - 3.55

According to ATP III and NCEP guidelines

Parameter	Normal	Desirable	Borderline	High
Total cholesterol	<200		200-239	240
Triglycerides	<150	150-199	200-499	500
LDL	Optimal <100 Near Optimal 100-129	130-159	160-180	190
HDL	<40 : LOW 60 : HIGH			

ENDOCRINOLOGY

PSA TOTAL

Prostatic specific antigen, Total 0.44 ng/ml <4.0

< 40 years	0.21 to 1.72 ng/ml
40 - 49	0.27 to 2.19 ng/ml
50 - 59	0.27 to 3.42 ng/ml
60 - 69	0.22 to 6.16 ng/ml
> 69	0.21 to 6.77 ng/ml

Notes:

Checked By.

Dr. NITIN AGARWAL
M.B.B.S., MD (Path)
DMC/R/01436

DR. NITIN AGARWAL
MBBS, MD (PATHOLOGIST)

47, Harsh Vihar, Pitampura, New Delhi-110034 | Ph.: 011-42480101, 9599913051

E-mail: oneplusul@gmail.com | Web.: www.oneplusul.in

Page 3 of 5

Clinical correlation is essential for final diagnosis. • If test results are unsatisfactory please contact personally or on phone. • This report is for perusal of doctors only. • All disputes Subject to Delhi Jurisdiction only. • Not for medicolegal purposes. • All congenital anomalies in a foetus may not be diagnosed in routine obstetric ultrasound.



OnePLUS

Ultrasound Lab

QUALITY FIRST... ALWAYS!

Dr. Nitin Agarwal

Pathologist & Director

Ex. Sr. Res. MAMC

& Lok Nayak Hospital

Ex. Chief of Lab Dr. Lal Path Labs.

Dr. Pooja (Garg) Agarwal

Radiologist & Director

MAMC & Lok Nayak Hospital



NAME	Mr. NAGENDRA SINGH	Barcode No	:10134292
AGE/GENDER	:43 YRS/Male	SPECIMEN DATE	:24/Dec/2022 10:12AM
PATIENT ID	:106723	SPECIMEN RECEIVED	:24/Dec/2022 10:27AM
REFERRED BY	:Dr. MEDIWHEEL	REPORT DATE	:24/Dec/2022 03:26PM
CENTRE NAME	:ONEPLUS ULTRASOUND LAB	LAB NO.	:012212240017

Test Name	Result	Unit	Ref. Range
-----------	--------	------	------------

PSA is principally produced by the glandular epithelium of the prostate, and is secreted in the seminal fluid. PSA is also present in urine and blood. PSA acts on seminal fluid to fluidify and increase sperm mobility. PSA levels rise in prostatic pathologies such as benign prostatic hyperplasia (BPH) or prostate cancer.

THYROID PROFILE(T3,T4,TSH)

Triiodothyronine total [t3]	0.65	ng/dl	0.52-1.9
Thyroxine total [t4]	7.60	µg/dl	4.4 - 10.8
TSH (Thyroid Stimulating Hormone)	2.50	µIU/ml	0.25-5.0

AGE WISE VARIATION IN TSH

AGE	TSH(µIU/ml)	AGE	TSH(µIU/ml)
1-4 weeks	1.00 - 19.0	16-20 yrs	0.25 - 5.0
1-12 mths	1.70 - 9.1	21 - 80 yrs	0.25 - 5.0
1-5 yrs	0.80 - 8.2	I st trimester	0.25 - 5.0
6-10 yrs	0.25 - 5.0	II nd trimester	0.50 - 5.0
11-15 yrs	0.25 - 5.0	III rd trimester	0.4 - 6.0

Reference ranges - Interpretation of Diagnostic tests - (Jacques Wallach)

1. Primary hypothyroidism is accompanied by depressed serum T3 and T4 values and elevated serum TSH level.
2. Primary hyperthyroidism is accompanied by elevated serum T3 and T4 levels along with depressed TSH values.
3. Slightly elevated T3 levels may be found in pregnancy and estrogen therapy, while depressed levels may be encountered in severe illness, renal failure and during therapy with drugs like propranolol and propyl thiouracil.
4. Although elevated TSH levels are nearly always indicative of primary hypothyroidism, and may be seen in secondary thyrotoxicosis

CLINICAL PATHOLOGY

URINE ROUTINE

Physical examination

Quantity	20	ML
Colour	PALE YELLOW	
Transparency	CLEAR	CLEAR
Sp.gravity	1.015	1.010-1.030
pH	6.00	

Checked By.

Dr. NITIN AGARWAL
 MBBS, MD (Path)
 DMC/R/01430
 DR. NITIN AGARWAL
 MBBS, MD (PATHOLOGIST)

47, Harsh Vihar, Pitampura, New Delhi-110034 | Ph.: 011-42480101, 9599913051

E-mail: oneplusul@gmail.com | Web.: www.oneplusul.in

Page 4 of 5

Clinical correlation is essential for final diagnosis. • If test results are unsatisfactory please contact personally or on phone. • This report is for perusal of doctors only.
 • All disputes Subject to Delhi Jurisdiction only. • Not for medicolegal purposes. • All congenital anomalies in a foetus may not be diagnosed in routine obstetric ultrasound.



OnePLUS

Ultrasound Lab

Dr. Nitin Agarwal

Pathologist & Director

Ex. Sr. Res. MAMC

& Lok Nayak Hospital

Ex. Chief of Lab Dr. Lal Path Labs.

Dr. Pooja (Garg) Agarwal

Radiologist & Director

MAMC & Lok Nayak Hospital



NAME: **Mr. NAGENDRA SINGH**
AGE/GENDER: **:43 YRS/Male**
PATIENT ID: **:106723**
REFERRED BY: **:Dr. MEDIWHEEL**
CENTRE NAME: **:ONEPLUS ULTRASOUND LAB**

Barcode No: **:10134292**
SPECIMEN DATE: **:24/Dec/2022 10:12AM**
SPECIMEN RECEIVED: **:24/Dec/2022 10:27AM**
REPORT DATE: **:24/Dec/2022 03:26PM**
LAB NO.: **:012212240017**

Test Name	Result	Unit	Ref. Range
Reaction	ACIDIC		ACIDIC
<u>Chemical examination</u>			
Urine protein	NIL		NIL
Urine sugar	NIL		NIL
Bilirubin, urine	NEGATIVE		NEGATIVE
Urobilinogen	NORMAL		NORMAL
Ketones	NEGATIVE		NEGATIVE
<u>Microscopic examination</u>			
Pus cells.	2-3	/HPF	0-2
Epithelial cells	1-2	/HPF	NIL
R.B.C.	NIL	/HPF	NIL
Casts	NIL	/HPF	NIL
Crystals	NIL	/HPF	NIL
Bacteria	NIL	/HPF	NIL
Others.	NIL	NIL	NIL

*** End Of Report ***

Checked By.

Dr NITIN AGARWAL
M.B.B.S., MD (Path)
DMC/R/01
DR. NITIN AGARWAL
M.B.B.S., MD (PATHOLOGIST)

47, Harsh Vihar, Pitampura, New Delhi-110034 | Ph.: 011-42480101, 9599913051

E-mail: oneplusul@gmail.com | Web.: www.oneplusul.in

Page 5 of 5

Clinical correlation is essential for final diagnosis. • If test results are unsatisfactory please contact personally or on phone. • This report is for perusal of doctors only. • All disputes Subject to Delhi Jurisdiction only. • Not for medicolegal purposes. • All congenital anomalies in a foetus may not be diagnosed in routine obstetric ultrasound.



OnePLUS
Ultrasound Lab
— QUALITY FIRST... ALWAYS! —

Dr. Nitin Agarwal
Pathologist & Director
Ex. Sr. Res. MAMC
& Lok Nayak Hospital
Ex. Chief of Lab Dr. Lal Path Labs.

Dr. Pooja (Garg) Agarwal
Radiologist & Director
MAMC & Lok Nayak Hospital

To
One Plus

24/12/2022

Dear Sir

Sub: Not willing to give stool sample

I am Nagendra Singh not willing to give
stool sample.

N Singh
Nagendra Singh

9990001280

ONEPLUS ULTRASOUND LAB
47, Harsh Vihar, Pitampura,
Delhi-110034
Ph. 011-42480101, 9599913051
E-mail: oneplusul@gmail.com

47, Harsh Vihar, Pitampura, New Delhi-110034 | Ph.: 011-42480101, 9599913051
E-mail: oneplusul@gmail.com | Web.: www.oneplusul.in

Clinical correlation is essential for final diagnosis. • If test results are unsatisfactory please contact personally or on phone. • This report is for perusal of doctors only.
• All disputes Subject to Delhi Jurisdiction only. • Not for medicolegal purposes. • All congenital anomalies in a foetus may not be diagnosed in routine obstetric ultrasound.

ONEPLUS ULTRASOUND LAB

47, HARSH VIHAR, PITAMPURA, DELHI-110034

Mr. NAGENDRA SINGH
 Age : 43/M
 Ref. by : MEDIWHEEL
 Indication1 :
 Indication2 :
 Indication3 :
 COMMENTS : Normal ECG.

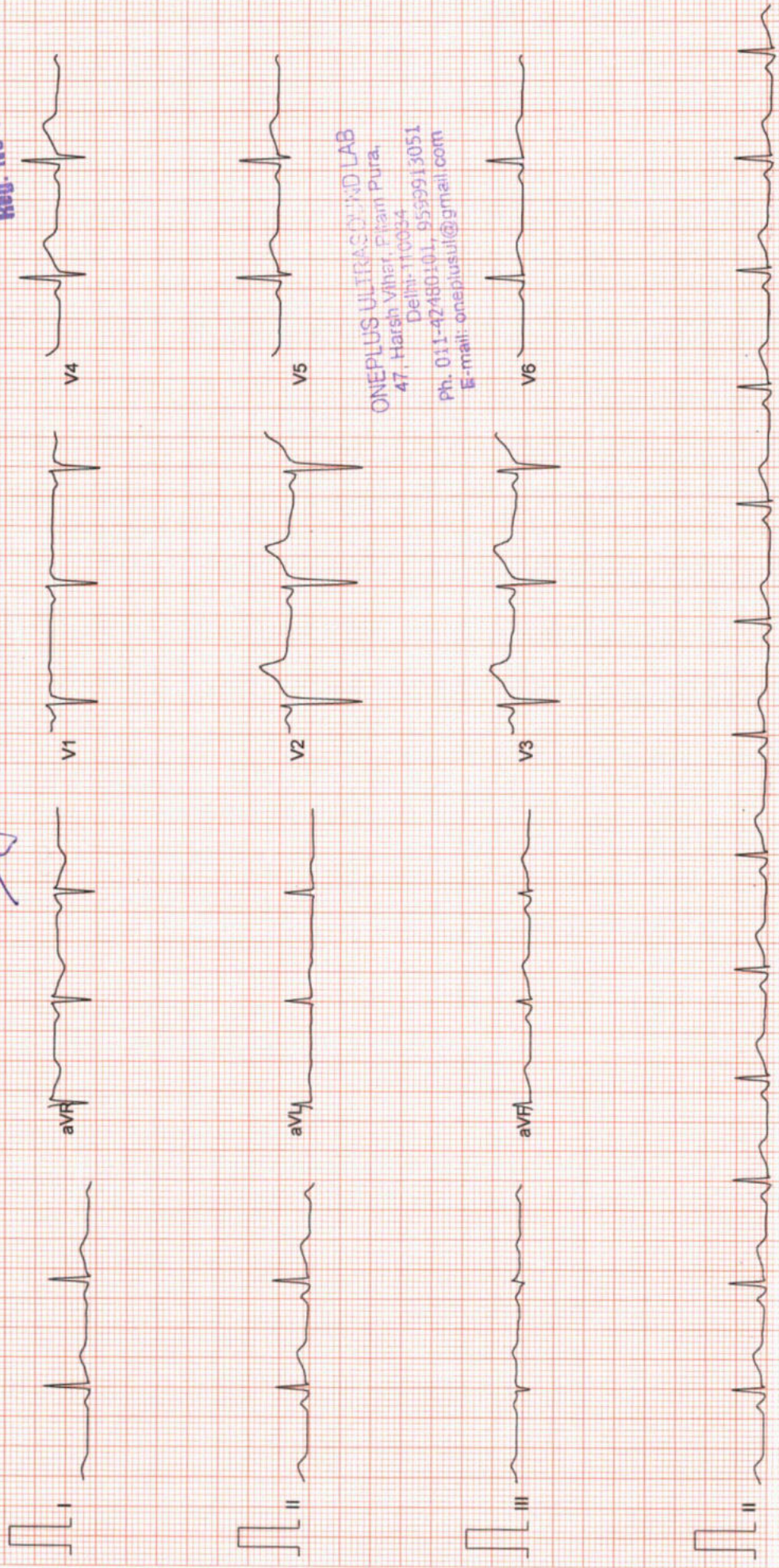
ID : 2055
 H/W/I : 17/1/73
 Recorded : 24-12-2022 11:27
 Medication1 :
 Medication2 :
 Medication3 :

BPM : 81
 BP : 122/80
 P Axis : 60 deg
 QRS Axis : 23 deg
 T Axis : 53 deg

P duration : 93 msec
 PR duration : 123 msec
 QRS duration : 103 msec
 QT interval : 326 msec
 QTc interval : 362 msec

Raw E.C.G.(Seq) *W.K. GUPTA*
Dr. P.K. GUPTA
MBBS, MD
Reg. No-1071

Unconfirmed Report Reviewed By:
 Cardiologist



ONEPLUS ULTRASOUND LAB
 47, Harsh Vihar, Pitampura,
 Delhi-110034
 Ph: 011-42480101, 9559913051
 E-mail: oneplusul@gmail.com

ONEPLUS ULTRASOUND LAB

47, HARSH VIHAR PITAMPURA DELHI 110034

Mr. NAGENDRA SINGH
 Age/Sex : 43/M
 Ref. by : MED/WHEEL
 Indication 1 :
 Indication 2 :
 Indication 3 :

ID : 993
 HI/WI : 171/73
 Recorded : 24-12-2022 11:33

TREADMILL TEST SUMMARY REPORT

Protocol: BRUCE
 History:
 Medication 1 :
 Medication 2 :
 Medication 3 :

PHASE	PHASE TIME	STAGE TIME	SPEED (Km./Hr.)	GRADE (%)	H.R. (BPM)	B.P. (mmHg)	RPP X100	II	ST LEVEL (mm) V2	V5	METS
SUPINE STANDING					85 92	122/80 122/80	103 112	1.1 1.1	1.7 1.5	1.0 1.0	
STAGE 1	2:59	2:59	2.70	10.00	110	122/80	134	0.7	2.8	1.1	4.80
STAGE 2	5:59	2:59	4.00	12.00	134	140/86	187	1.0	3.0	1.1	7.10
STAGE 3	8:59	2:59	5.40	14.00	154	150/90	231	0.0	2.1	0.1	10.00
PEAK EXER	8:59	2:59			154	150/90	231	0.1	2.3	0.3	10.00
RECOVERY	2:59	2:59	0.00	0.00	109	124/82	135	0.3	0.6	0.2	

RESULTS

Exercise Duration : 8:59 Minutes
 Max Heart Rate : 154 bpm 87 % of target heart rate 177 bpm
 Max Blood Pressure : 150/90 mmHg
 Max Work Load : 10.00 METS
 Reason of Termination :

IMPRESSIONS

Negative for inducible Ischemia.

ONEPLUS ULTRASOUND LAB
 47, Harsh Vihar, Pitampura,
 Delhi-110034
 Ph. 011-42460101, 9559913051
 E-mail onepplusul@ptampura.com

(Handwritten Signature)

Dr. P.K. GUPTA
 MBBS, MD
 Cardiologist

ONEPLUS ULTRASOUND LAB

Mr. NAGENDRA SINGH
I.D. : 993

AGE/SEX : 43/M

RECORDED : 24-12-2022 11:33

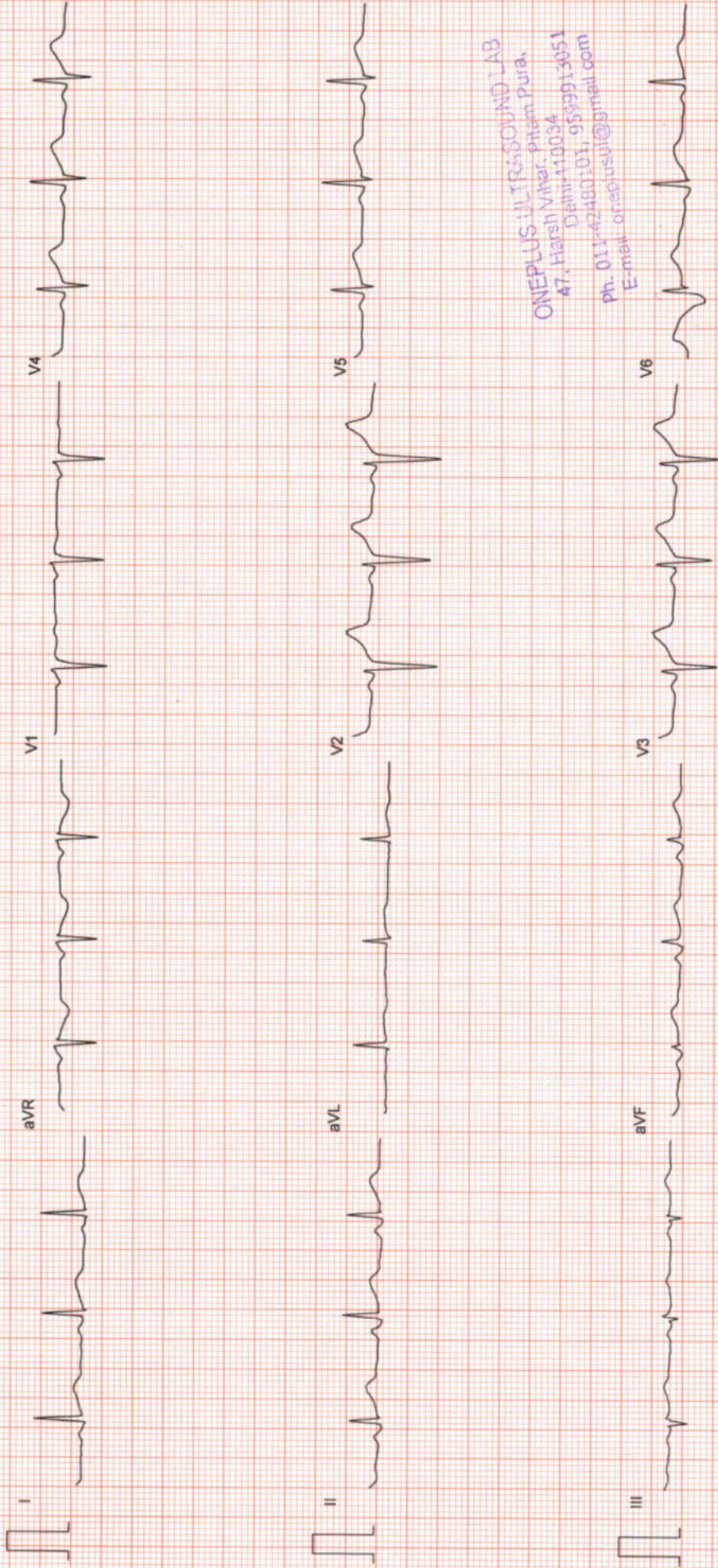
RATE : 85 BPM

B.P. : 122/80 mmHg

ST @ 10mm/mV
80ms Post.J

SUPINE
PRETEST

RAW E.C.G.



ONEPLUS ULTRASOUND LAB
47, Harsh Vihar, Pitam Pura,
Delhi-110034
Ph: 011-42480101, 9599913051
E-mail: oraplusul@gmail.com

ONEPLUS ULTRASOUND LAB

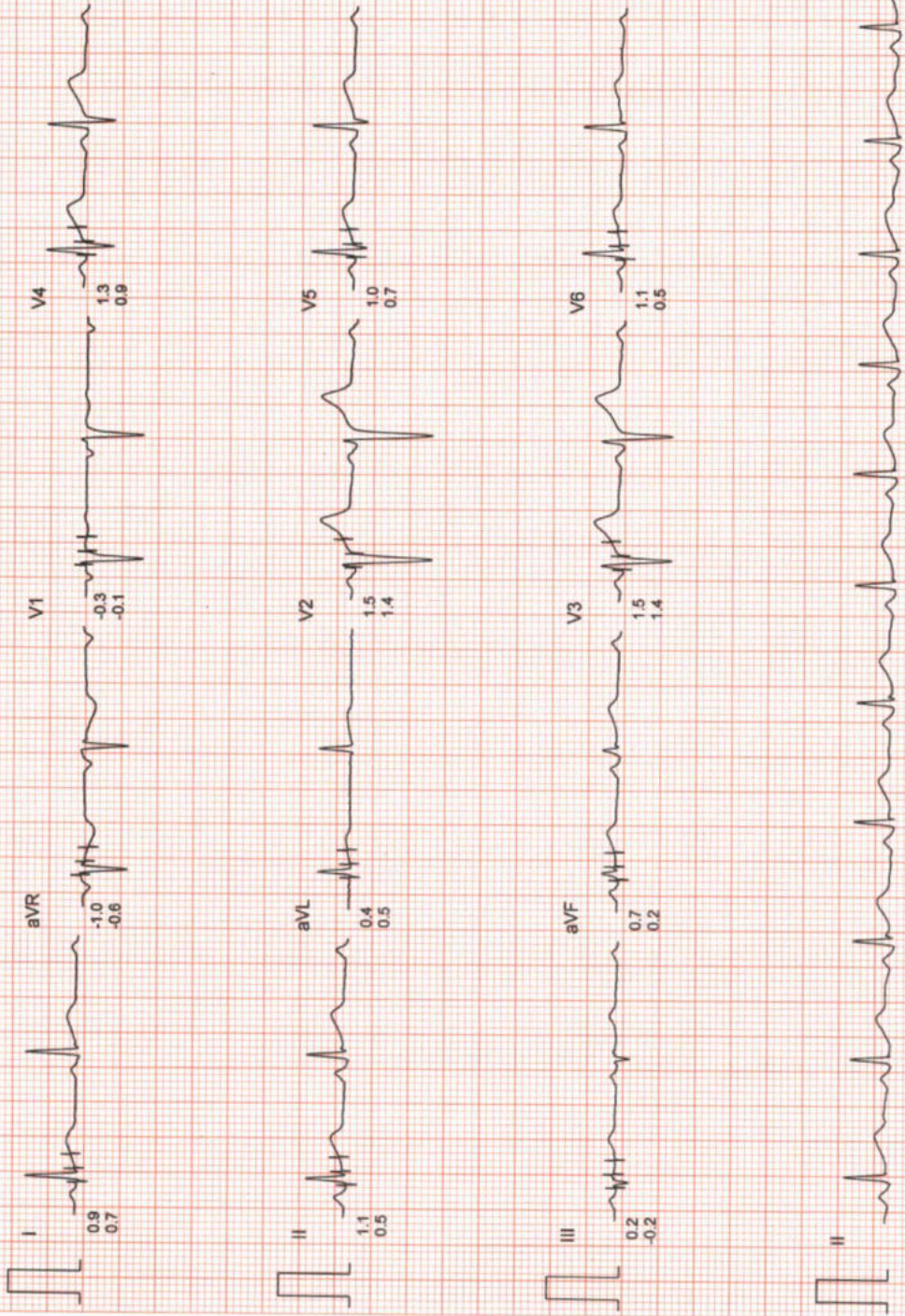
Mr. NAGENDRA SINGH
I.D. : 993
AGE/SEX : 43/M
RECORDED : 24-12-2022 11:33

RATE : 92 BPM
B.P. : 122/80 mmHg

ST @ 10mm/mV
80ms PostJ

STANDING
PRETEST

LINKED MEDIAN



ONEPLUS ULTRASOUND LAB
47, Harsih Vihar, Harsih Pura,
Delhi-110034
Ph. 011-4243010, 9599913051
E-mail: oneplusul@gmail.com

ONEPLUS ULTRASOUND LAB

Mr. NAGENDRA SINGH
I.D. : 993

AGE/SEX : 43/M

RECORDED : 24-12-2022 11:33

RATE : 110 BPM

B.P. : 122/80 mmHg

ST @ 10mm/mV
80ms PostJ

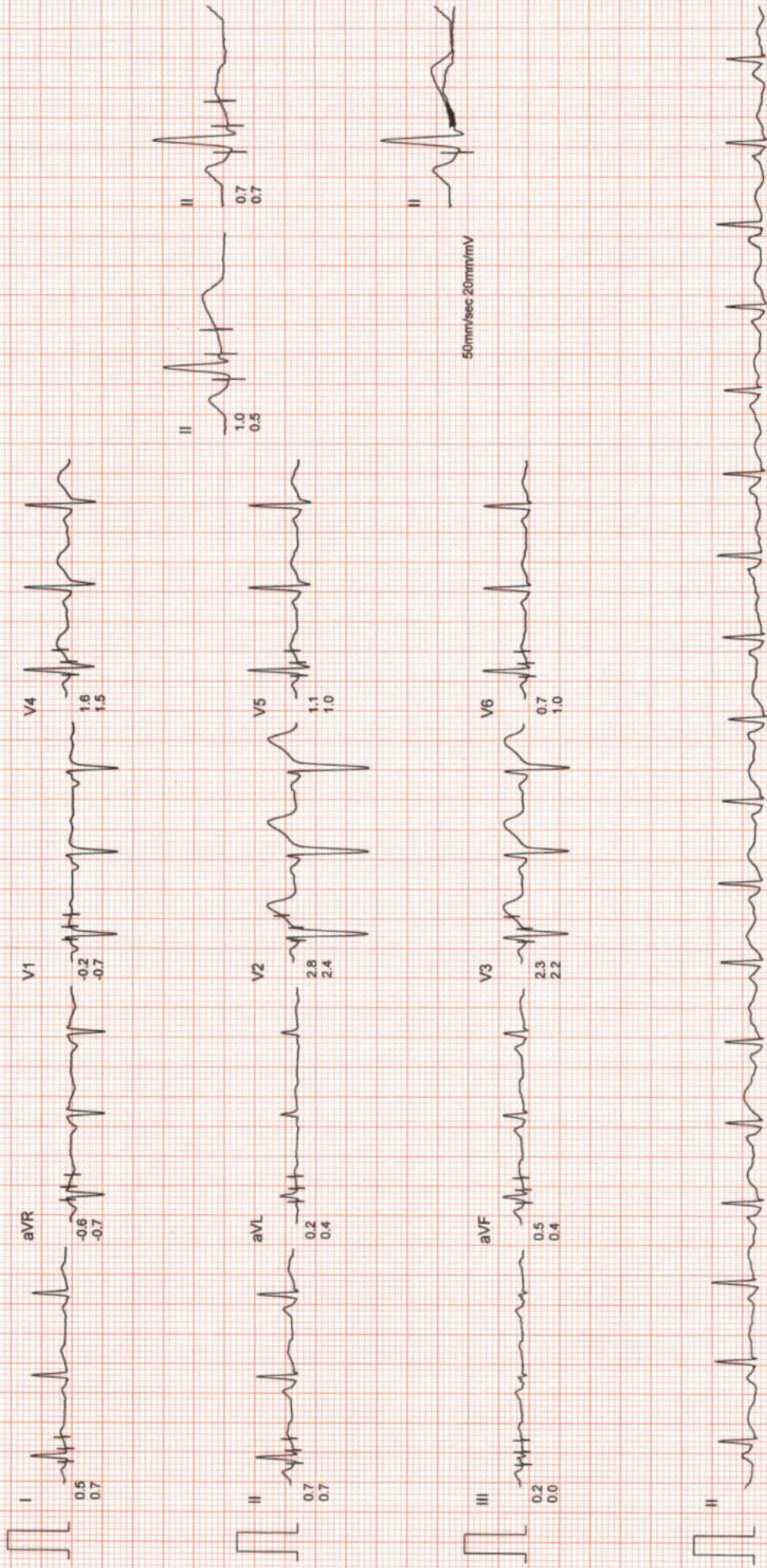
SPEED : 2.7 Km./Hr.
GRADE : 10.0 %

LINKED MEDIAN

BRUCE
EXERCISE 1

PHASE TIME : 2:59

STAGE TIME : 2:59



ONEPLUS ULTRASOUND LAB
47, Harsh Vihar, Pitam Pura,
Delhi-110034
Ph. 011-42406014, 5599913051
E-mail: oneplusul@gmail.com

ONEPLUS ULTRASOUND LAB

Mr. NAGENDRA SINGH
I.D. : 993

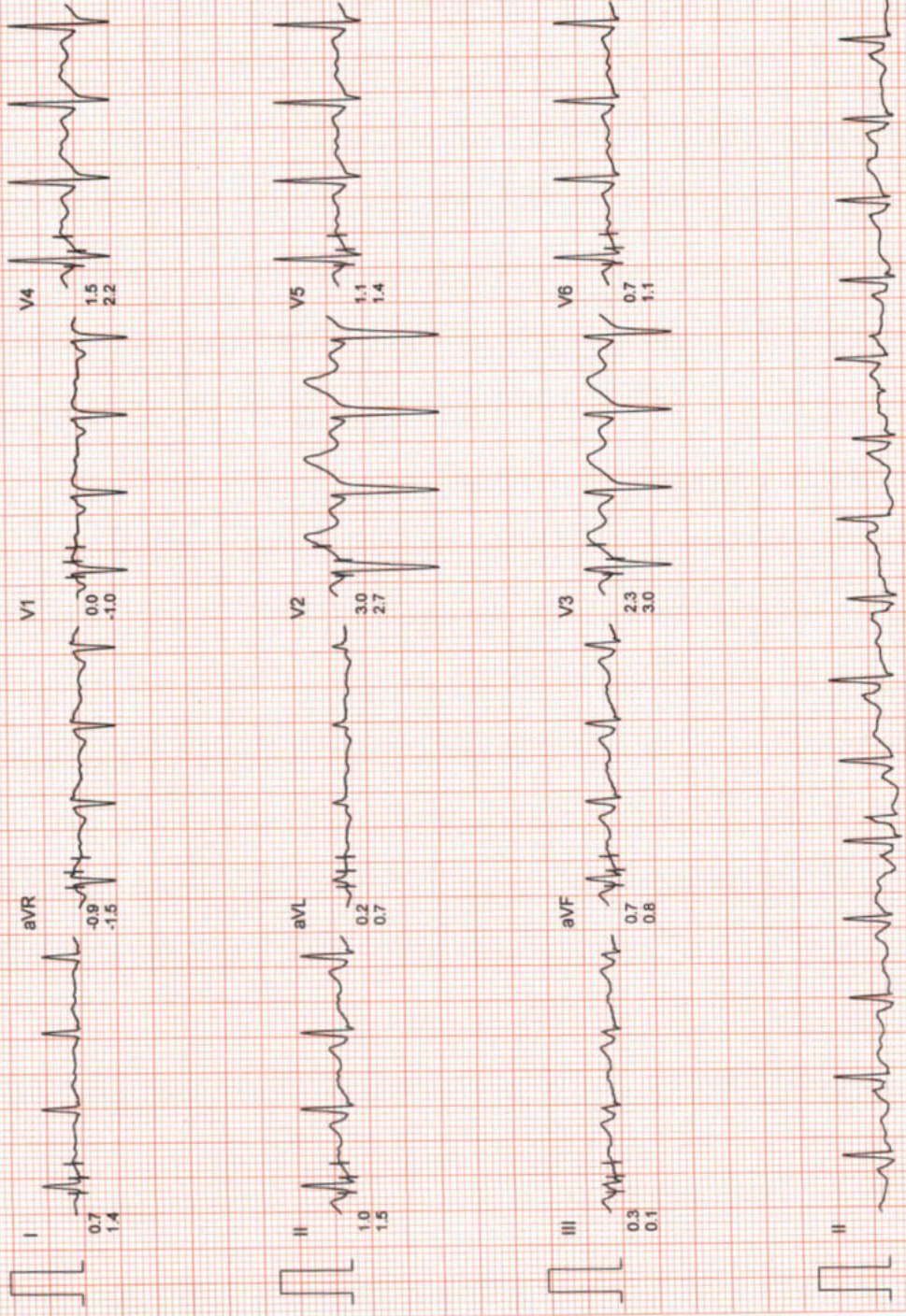
AGE/SEX : 43/M
RECORDED : 24-12-2022 11:33

RATE : 134 BPM
B.P. : 140/86 mmHg

BRUCE
EXERCISE 2
PHASE TIME : 5:59
STAGE TIME : 2:59

ST @ 10mm/mV
80ms PostJ
SPEED : 4.0 Km./Hr.
GRADE : 12.0 %

LINKED MEDIAN



ONEPLUS ULTRASOUND LAB
47, Harsh Vihar, Pitam Pura,
Delhi-110034
Ph. 011-42460101, 9599913051
E-mail: onepplusul@gmail.com

ONEPLUS ULTRASOUND LAB

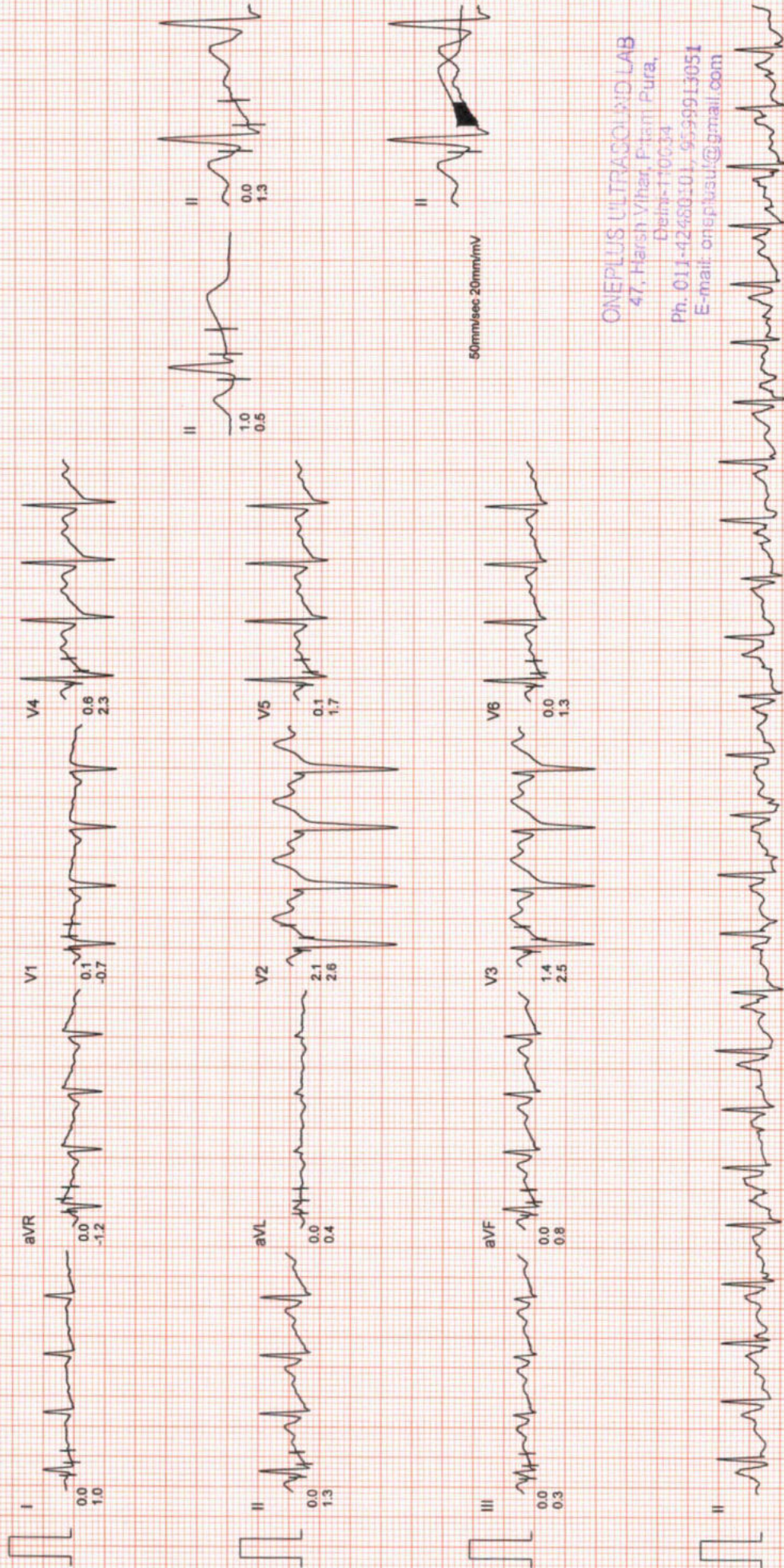
Mr. NAGENDRA SINGH
I.D. : 993

AGE/SEX : 43/M
RECORDED : 24-12-2022 11:33

BRUCE
EXERCISE 3
PHASE TIME : 8:59
STAGE TIME : 2:59

ST @ 10mm/mV
80ms PostJ
SPEED : 5.4 Km./Hr.
GRADE : 14.0 %

LINKED MEDIAN



ONEPLUS ULTRASOUND LAB
47, Harish Vihar, Pitampura,
Delhi-110034
Ph: 011-42480101, 9599913051
E-mail: onepulsul@gmail.com

ONEPLUS ULTRASOUND LAB

Mr. NAGENDRA SINGH

I.D. : 993

AGE/SEX : 43/M

RECORDED : 24-12-2022 11:33

RATE : 154 BPM

B.P. : 150/90 mmHg

BRUCE

PEAK EXER

PHASE TIME : 8:59

STAGE TIME : 2:59

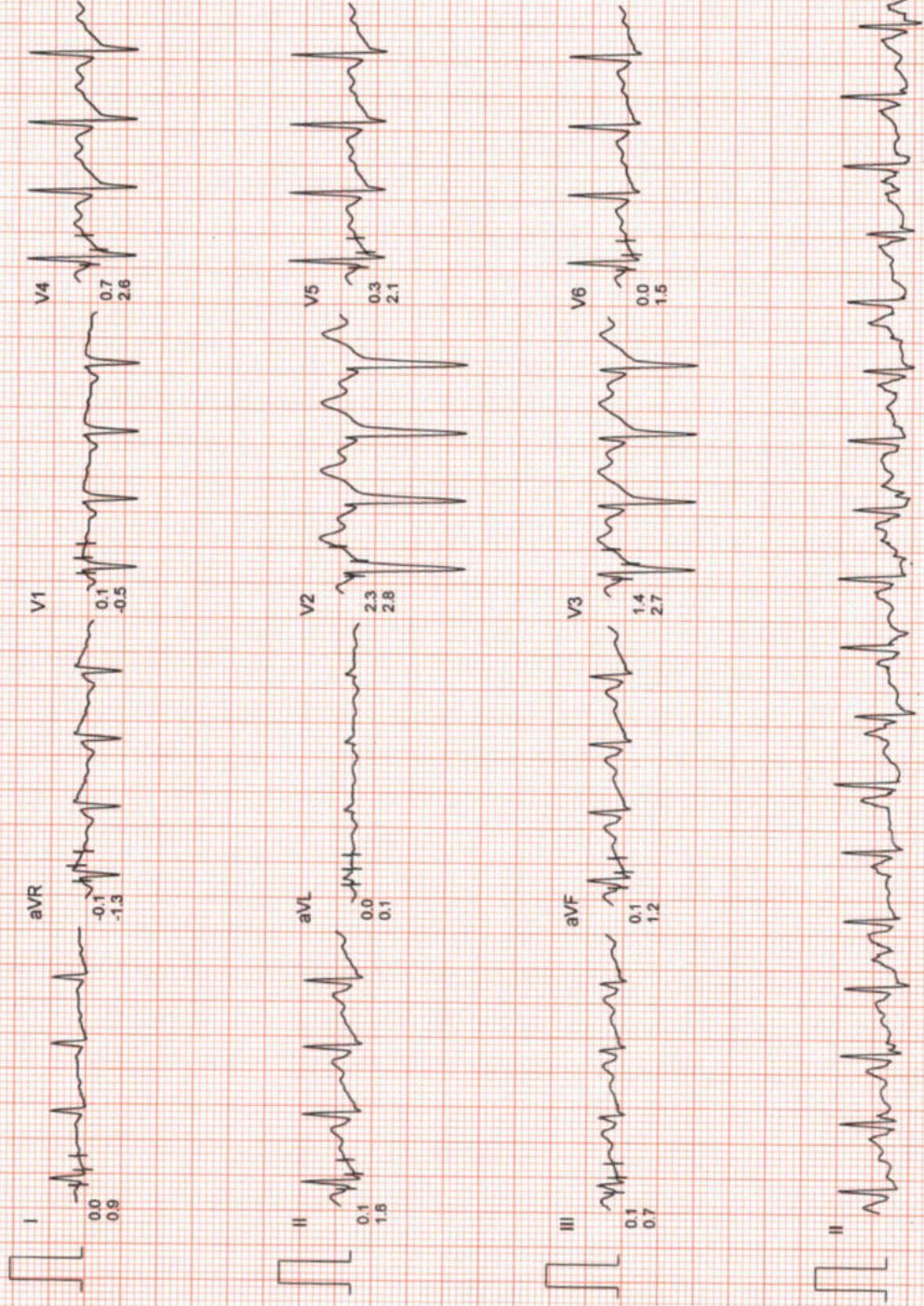
ST @ 10mm/mV

80ms PostJ

SPEED : 5.4 Km/Hr.

GRADE : 14.0 %

LINKED MEDIAN



ONEPLUS ULTRASOUND LAB
 47, Harsh Vihar, Patna, Bihar,
 India-110034
 Ph. 011-4240001, 9859913051
 E-mail: onplusul@gmail.com

ONEPLUS ULTRASOUND LAB

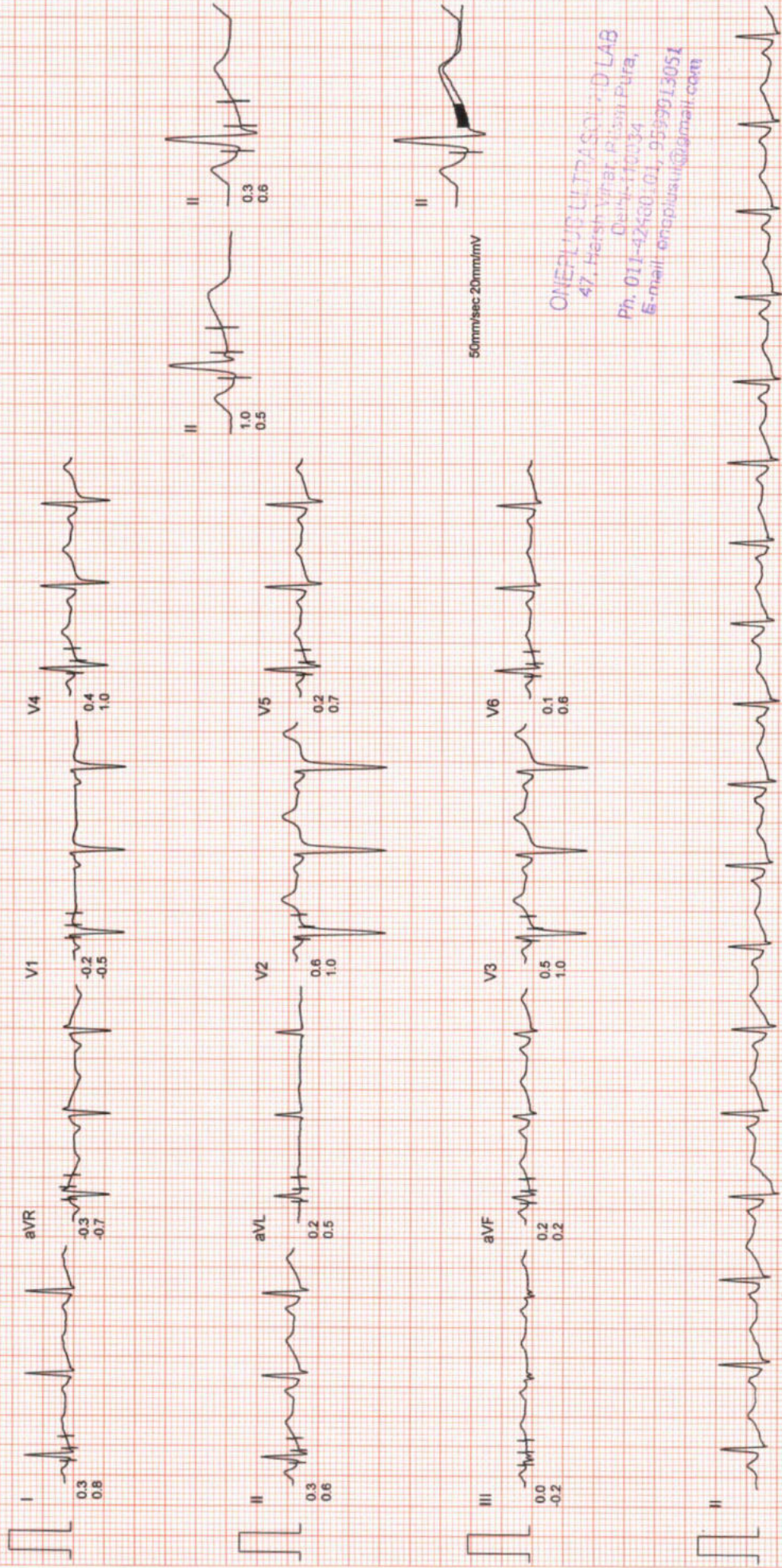
Mr. NAGENDRA SINGH
I.D. : 993

AGE/SEX : 43/M
RECORDED : 24-12-2022 11:33

BRUCE
RECOVERY
PHASE TIME : 2:59

ST @ 10mm/mV
80ms PostJ
SPEED : 0.0 Km./Hr.
GRADE : 0.0 %

LINKED MEDIAN



50mm/sec 20mm/mV

ONEPLUS ULTRASOUND LAB
47, Hattish Vihar, Pusa, New Delhi-110034
Ph. 011-42480101, 9599013051
E-mail: onepplusul@oneplus.com

ONEPLUS ULTRASOUND LAB

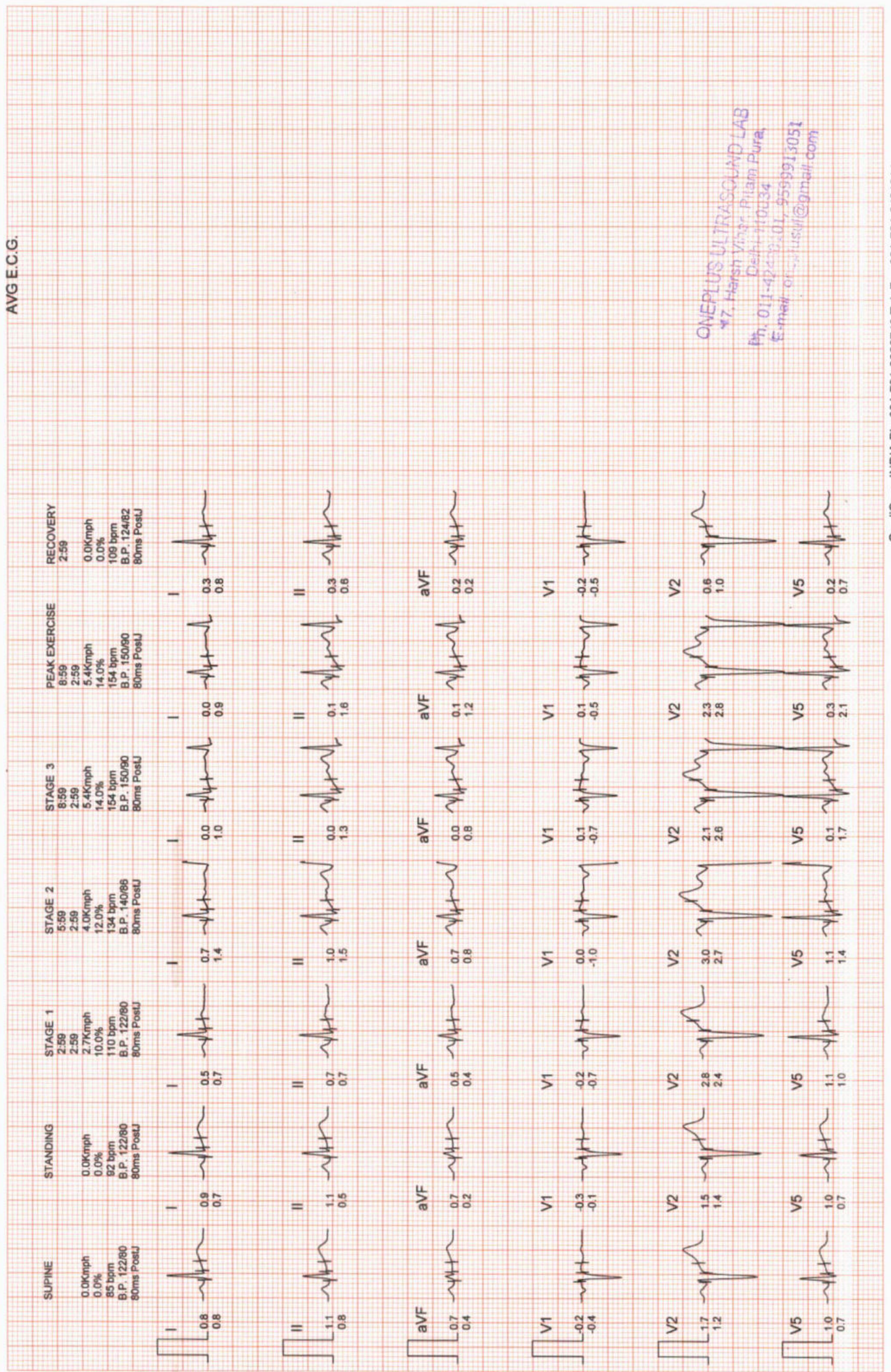
Mr. NAGENDRA SINGH

I.D. : 993

AGE/SEX : 43/M

RECORDED : 24-12-2022 11:33

AVG E.C.G.



ONEPLUS ULTRASOUND LAB
 Dr. Harsh Vignesh Prasad
 Dist. H. H. 10/34
 Ph. 011-4241201, 9599913051
 E-mail: onepplusul@outlook.com

ONEPLUS ULTRASOUND LAB

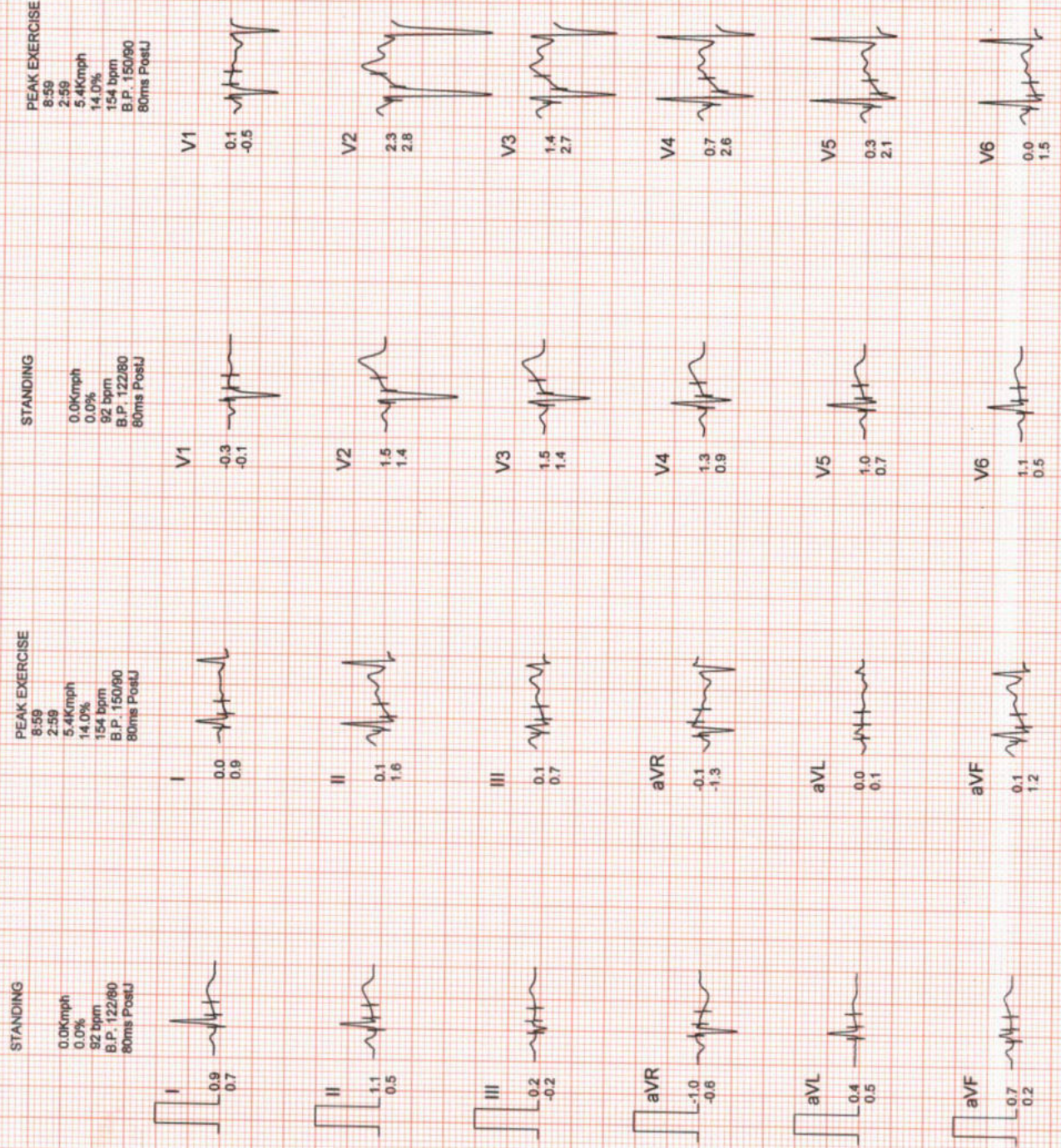
Mr. NAGENDRA SINGH

I.D. : 993

AGE/SEX : 43/M

RECORDED : 24-12-2022 11:33

COMPARISON REPORT



ONEPLUS ULTRASOUND LAB
 #7 Harsh Vihar Postm Pura,
 Delhi-110034
 Ph. 011-42400701, 9559913051
 E-mail: oneplusultrasound@gmail.com



OnePLUS
Ultrasound Lab
— QUALITY FIRST... ALWAYS! —

Dr. Nitin Agarwal
Pathologist & Director
Ex. Sr. Res. MAMC
& Lok Nayak Hospital
Ex. Chief of Lab Dr. Lal Path Labs.

Dr. Pooja (Garg) Agarwal
Radiologist & Director
MAMC & Lok Nayak Hospital

Name	: Mr. NAGENDRA SINGH	Age/Sex	: 43 YRS/Male
Ref. By	: Dr. MEDIWHEEL	Lab No	: 012212240017
Date	: 24-Dec-2022	Patient ID	: LSHHI106723

ULTRASOUND EXAMINATION----WHOLE ABDOMEN

Liver is normal in size (12.3 cm) and normal in outline with **altered echopattern. Diffuse increase in echogenicity of liver parenchyma is noted, suggestive of fatty infiltration (grade I).** Intrahepatic biliary radicles are not dilated. No abscess or mass lesion seen. Hepatic veins, portal vein, IVC and aorta are normal. CBD is normal in caliber.

Gall bladder is well distended with anechoic lumen. Wall thickness is normal.

Both kidneys are normal in size, shape, position, outline and echopattern. Corticomedullary differentiation is maintained. No pelvicalyceal dilation or mass lesion is seen. **A simple subcentimeteric cortical cyst is seen at lower pole of left kidney.**

Spleen is normal in size (9.7 cm) and echotexture. No mass lesion seen.

Pancreas is normal in size, outline and echotexture.


Urinary bladder is normal in shape and position. No evidence of intravesical stone or mass seen.

Prostate is normal in size, shape and echopattern.

No abnormal bowel wall thickening seen in right iliac fossa.
No free fluid seen anywhere in abdomen.

IMPRESSION:

- **Fatty infiltration of liver (grade I) with no hepatomegaly.**


Dr. Shubham K
MD RADIODIAGNOSIS
MBBS, MD
Reg. No. DMC/R/99162
Radiologist

47, Harsh Vihar, Pitampura, New Delhi-110034 | Ph.: 011-42480101, 9599913051
E-mail: oneplusul@gmail.com | Web.: www.oneplusul.in

Plüschonud jwude jebod





OnePLUS
Ultrasound Lab

— QUALITY FIRST... ALWAYS! —

Dr. Nitin Agarwal

Pathologist & Director
Ex. Sr. Res. MAMC
& Lok Nayak Hospital
Ex. Chief of Lab Dr. Lal Path Labs.

Dr. Pooja (Garg) Agarwal

Radiologist & Director
MAMC & Lok Nayak Hospital

Name	: Mr. NAGENDRA SINGH	Age/Sex	: 43 YRS/Male
Ref. By	: Dr. MEDIWHEEL	Lab No	: 012212240017
Date	: 24-Dec-2022	Patient ID	: LSHHI106723

X-ray-Chest PA view

Lung fields are clear. No parenchymal lesion seen.

Cardiothoracic ratio is normal.

Mediastinum is normal.


Both hila are normal.

Both costophrenic angles are clear.

Both domes of diaphragm are normal.

Bony cage and soft tissues are normal.

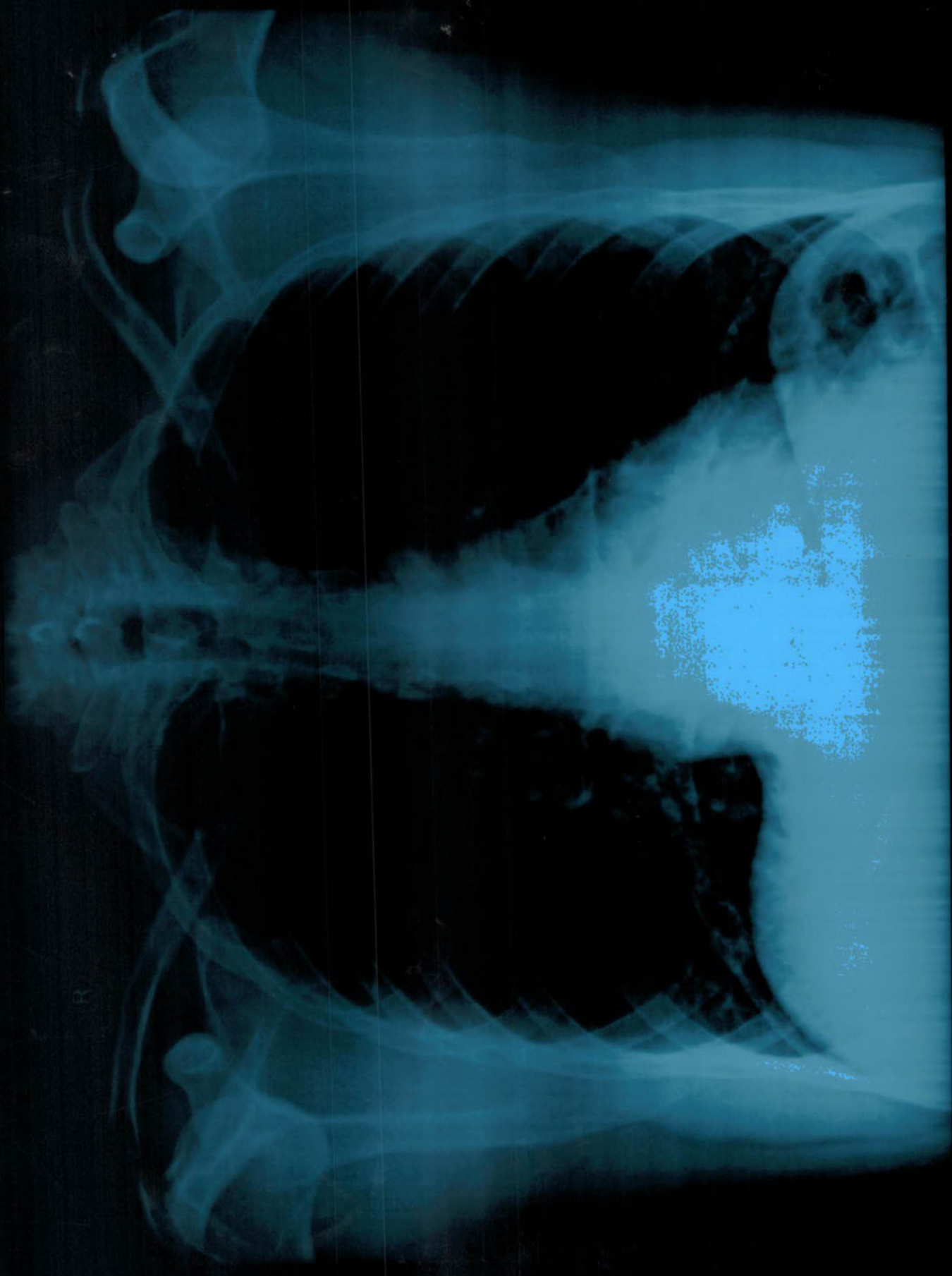
IMPRESSION: Normal Study.


Dr. Shubham K
Dr SHUBHAM K MISHRA
MBBS, MD
Reg. No. DMC/R/99162
Radiologist

47, Harsh Vihar, Pitampura, New Delhi-110034 | Ph.: 011-42480101, 9599913051

E-mail: oneplusul@gmail.com | Web.: www.oneplusul.in

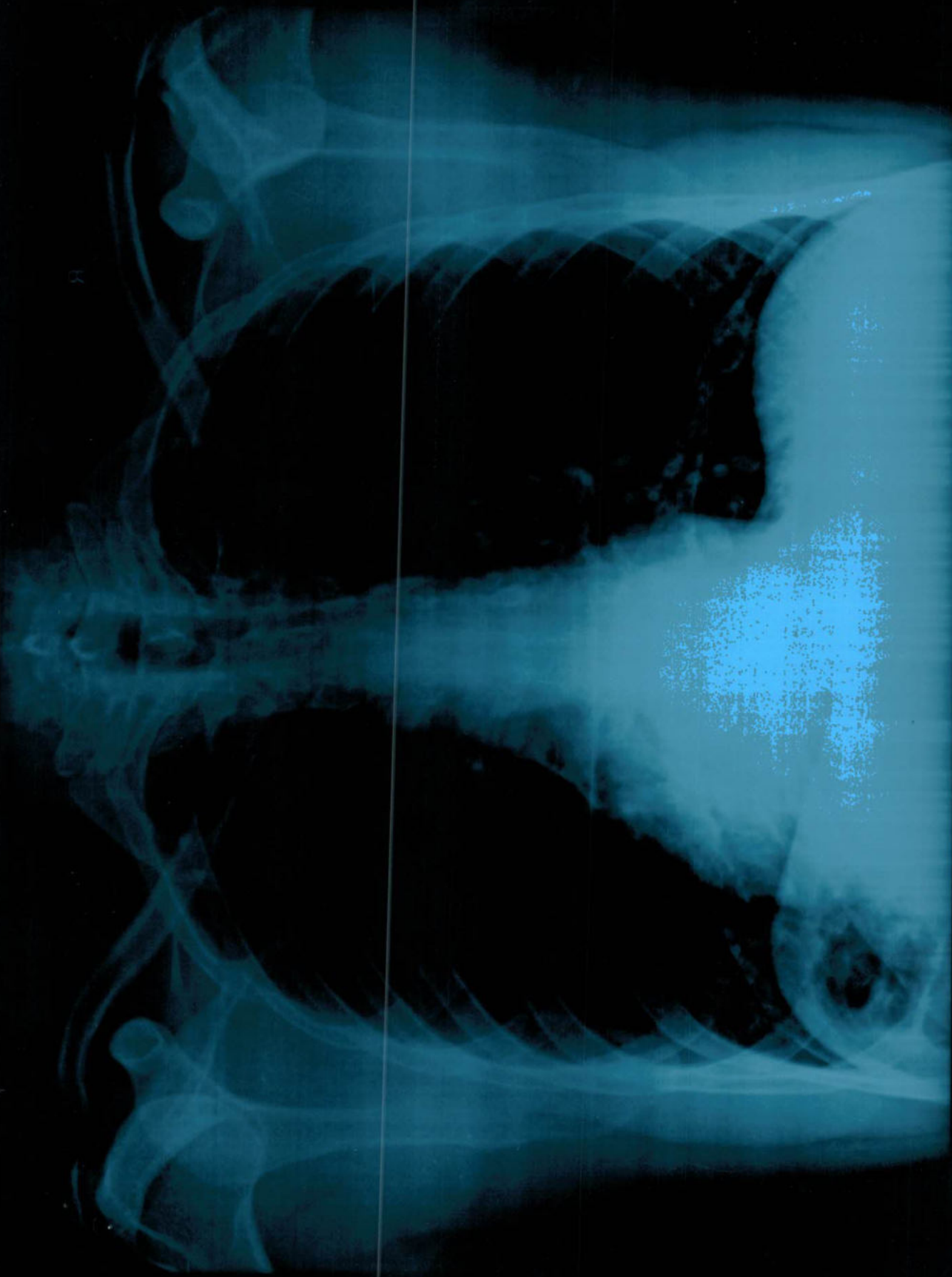
Clinical correlation is essential for final diagnosis. • If test results are unsatisfactory please contact personally or on phone. • This report is for perusal of doctors only.
• All disputes Subject to Delhi Jurisdiction only. • Not for medicolegal purposes. • All congenital anomalies in a foetus may not be diagnosed in routine obstetric ultrasound.



MR NAGENDRA SINGH 43 YRS 24/12/2022 M CHEST PA VIEW 12/24/2022

ONEPLUS ULTRASOUND LAB 47 HARSH VIHAR PITAMPURA

ONEPLUS ULTRASOUND LAB 43 HARSH VIHAR PITAMPURA
MR NAGENDRA SINGH 43 YRS 54/15/50SS M CHEST PA VIEW 15/54/50SS



R