



PARKLINE DIAGNOSTICS PVT. LTD.

L.G. 3, 4 & 5, Bhuvana Towers, S.D. Road, Secunderabad - 500 003.
Tel : +91 40-2784 5852, 6649 1787, 7995421787, 7093445852, Fax : +91 40 2784 7864
Email parklinediagnostics@gmail.com www.parklinediagnostics.com



NABL Accredited
Certificate No.MC-2566

MEDICAL EXAMINATION REPORT

Name	Mr. M. C. Nagaraju		Date	12/02/2022
Company	C/O: Mediwheel		Reg. No.:	1868562
Contact No.	9492902622		Sex	<input checked="" type="checkbox"/> M <input type="checkbox"/> F
			Age	<input type="checkbox"/> 50 <input checked="" type="checkbox"/> 52
Type	Pre-Emp		Emp. No.:	71052
	Overseas		Height	169 cm
	Annual	<input checked="" type="checkbox"/>	Weight	83 kg
Remarks	<p>↑ ESR. Advice follow up.</p> <p>USG: Grade I fatty liver.</p> <p>Exophytic bossnail type I cyst in (Rt) kidney measuring 4.8 X 3.6 cm.</p> <p>Advice follow up.</p> <p>Rest all clinical, lab parameters were</p>			
			DR PRIYANKA SANNIDHI	MBBS
			Regn. No. 11351	
Fitness Status	Medically Fit / Unfit		Physician's Signature	

COMPREHENSIVE MEDICAL EXAMINATION REPORT

NAME Ms. M. B. ~~Chandrasekhar~~ Nagalaxi
AGE 52 yrs / Male
MARITAL STATUS married CHILDREN : M 1 F 1
IDENTIFICATION (IF ANY) A mole on the chest (right side)-

PAST HISTORY

Any family H/o : High Blood Pressure, Heart Disease, Tuberculosis, Diabetes, Asthma, Cancer

Fatu

Any personal H/o Major illness like : Typhoid.....Yes.....Jaundice.....Nil.....Etc.

Any H/o STD.....Nil.....Skin infection.....Nil.....

H/o Blood Transfusion.....Nil.....Recent Vaccination.....COVID 19 2 Doses

H/o Epilepsy.....Nil.....Giddiness.....Nil.....

H/o Surgery.....Nil.....Fracture in the past.....Nil.....

Any Personal H/O.

High Blood Pressure, Heart Disease Tuberculosis, Diabetes, Asthma, Cancer

Drug Abuse, Drug Allergy, Micturition, Bowels, Alcohol, Smoking, Sleep, MC, Wt. Loss/Wt. Gain

Present illness / Medication

GENERAL EXAMINATION

Conjunctiva :

Skin :

Ears :

Nose :

Throat & Oral Cavity :

NAD

Bone, Joints :

Nutritional Status : well Nourished

Lymph Nodes : NPD

Edema Feet : Nil

Varicose Veins : Nil

Distant Vision : Near Vision :

Right Eye: 6/18 - 2.0 sph 6/6

Right Eye: 26

With glasses / Without glasses

With glasses / Without glasses

left Eye: 6/18 - 2.0 sph 6/6

left Eye: 26

with glasses / without glasses

with glasses / without glasses

Colour Vision : BE normal

DR. KATTA
M.B.B.S., D.O., F.R.C.
Ophthalmologist's Signature
Regd. 8507

Right Ear

Left Ear

Hearing : (N)

(N)

Rinee's Test ;

Weber Test :

Discharge : NIL

NIL

SYSTEMIC EXAMINATION

Pulse :

B.P. : 120/80

Lungs : A. Shape of Chest R/L symmetrical
B. Breath Sounds BI - clear ⊕
C. Adventitious Sounds No

Heart : A. Sounds S₁ S₂ ⊕
B. Murmurs No murmurs

Nervous System

Abdomen : A. Liver NPD
B. Spleen NPD
C. Piles NIL
D. Any Lump NIL

A. Higher Function :
B. Cranial Nerves :
C. Sensory System :
D. Motor System :
E. Jerks :

(N)

General : A. Hernia
B. Hydrocele
C. Varicocele
NAD

Breast : Rt _____ Lt. _____

CANDIDATE'S DECLARATION

I hereby solemnly declare that I am not suffering from Asthma, Hypertension, Diabetes, Occult Psychological disorders or any other ailment which can be suppressed without my voluntary declaration.

Date :

Place :


Signature _____

Nagendra

Note : General Physical Examination and Investigation included in the health check-up
Have certain limitations and may not be able to detect all latent and asymptomatic diseases.
Any new symptoms developing after the health check-up or persisting thereafter should be
brought to the attention of the treating physician.



Phone: 27844043
66339096

SECUNDERABAD DENTAL HOSPITAL

CENTRE FOR ADVANCED DENTAL CARE

12/3/2022

ORAL & MAXILLOFACIAL SURGEONS

Dr. Kazim Himathi M.D.S.

Dr. Gautam Dendukuri

FDSRCS (Eng), FFDRCS (Ire),
FFDRCS (OMFS),(Ire)

PROSTHODONTIST

Dr. Chandrakanth Reddy M.D.S.

ENDODONTIST

Dr. Ram Narayan Reddy M.D.S.

ORTHODONTIST

Dr. Rajesh Reddy M.D.S., M.Orth RCS.

Dr. Sudeep Bhalerao M.D.S.

PERIODONTIST

Dr. Veerendranath Reddy M.D.S.

PEDODONTIST

Dr. Soumya M.D.S.

Dr. Mounika M.D.S.

DENTAL SURGEONS

Dr. N. Jagadish Rao B.D.S.

Dr. Baisakhi Saha B.D.S.

Mr. Nagaraju

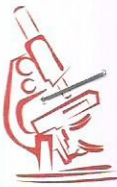c/o: Patient came for a general
checkup

O/B :- Gen. Cervical Abscessions
- old bridges intact

Adv. Fillings

Saha





PARKLINE DIAGNOSTICS PVT. LTD.

L.G. 3, 4 & 5, Bhuvana Towers, Sarojini Devi Road, Secunderabad - 500 003 Tel. +91 40-2784 5852
6649 1787 Fax :+91 40 2784 7864 Email : parklinediagnostics@gmail.com www.parklinediagnostics.com



NABL Accredited
Certificate No. MC-2566

TEST REPORT

Name : Mr . M C NAGARAJU [71052]
Age / Gender : 52 Years / Male
Ref.By : Medi Wheel
Req. No : BIL1868567

TID : UMR0739357
Registered on : 12-Mar-2022 08:53 AM
Reported On : 13-Mar-2022 09:27 AM

DEPARTMENT OF ULTRASOUND Ultrasound Whole Abdomen

LIVER is normal shape, size (13.3 cms) and increased echopattern.
No evidence of focal lesion. No intrahepatic biliary ductal dilatation.
Hepatic and portal vein radicals are normal.

GALL BLADDER shows normal shape and has clear contents.
Gall bladder wall is of normal thickness.
CBD is of normal calibre.

PANCREAS has normal shape, size and uniform echopattern.
No evidence of ductal dilatation or calcification.

SPLEEN shows normal shape, size and echopattern.

KIDNEYS move well with respiration and have normal shape, size and echopattern.
Cortico- medullary differentiations are well madeout.
No evidence of calculus or hydronephrosis.
Right kidney measures 9.3 x 5.2 cms, Left kidney measures 10.1 x 5.5 cms.
E/o exophytic cyst noted in lower pole of right kidney, measuring 4.8 x 3.6 cms.

URINARY BLADDER shows normal shape and wall thickness.
It has clear contents. No evidence of diverticula.

PROSTATE shows normal shape, size and echopattern.

No evidence of free fluid in the abdomen

IMPRESSION:

- * **Grade I Fatty liver.**
- * **Exophytic bosniak type I cyst in right kidney.**

Suggested clinical correlation and follow up.

Dr. Abid Yazden
Consultant Radiologist

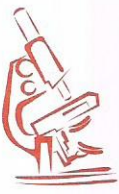The Test marked with*are not accredited by NABL

Lab Timings (Weekdays) : 7.00 am to 8.30 pm
Sundays & Holidays : 7.00 am to 1.00 pm

Radiologists Timings (Weekdays) : 7.30 am to 1.30 pm
& 5.30 pm to 7.45 pm
Sundays & Holidays : 7.30 am to 9.30 am

Free Home Visit for Sample Collection.

Call : 7995421787, 7093445852, 8121147282, 9885202212



PARKLINE DIAGNOSTICS PVT. LTD.

L.G. 3, 4 & 5, Bhuvana Towers, Sarojini Devi Road, Secunderabad - 500 003 Tel. +91 40-2784 5852
6649 1787 Fax :+91 40 2784 7864 Email : parklinediagnostics@gmail.com www.parklinediagnostics.com



NABL Accredited
Certificate No. MC-2566

TEST REPORT

Name : Mr . M C NAGARAJU [71052]
Age / Gender : 52 Years / Male
Ref.By : Medi Wheel
Req. No : BIL1868567

TID : UMR0739357
Registered on : 12-Mar-2022 08:53 AM
Reported On : 12-Mar-2022 10:23 AM

X-RAY CHEST PA VIEW

Lung fields are clear.

Cardia is normal.


Hila are normal.

C P angles are free.

Bony cage is normal.

Soft tissues are normal.

IMPRESSION : NORMAL CHEST X-RAY



Dr. D.J. MOHAN
MD DMRD
(Reg No. 8995)
Consultant Radiologist

The Test marked with*are not accredited by NABL

Lab Timings (Weekdays) : 7.00 am to 8.30 pm
Sundays & Holidays : 7.00 am to 1.00 pm

Radiologists Timings (Weekdays) : 8.30 am to 1.30 pm
& 5.30 pm to 7.45 pm
Sundays & Holidays : 7.30 am to 9.30 am

Free Home Visit for Sample Collection.

Call : 7995421787, 7093445852, 8121147282, 9885202212

REAL TIME ECG REPORT
PATIENT SUMMARY REPORT

LINE DIAGNOSTICS PVT.LTD

: 1868567
: **MR M C NAGARAJU**
SEX : 52 / MALE

HEIGHT (cm) : 169
WEIGHT (kg) : 83
PROTOCOL : BRUCE

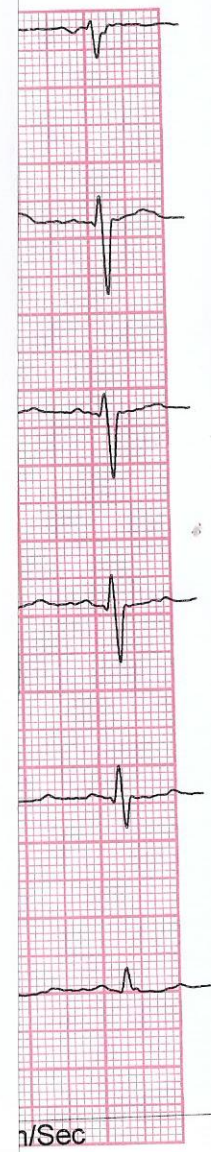
REF. BY : MEDIWHEEL
DONE BY : DR NAVEEN KUMAR C
TECHNICIAN : G.M.SURESH

03-2022, 16:35:
C

HISTORY :
LOCATION :
OBJECT OF TEST : Routine Check Up.
RISK FACTOR : None.
ACTIVITY : Very Active.
PREVIOUS INVESTIGATION : ECG
REASON FOR TERMINATION : THR ACHIEVED
EXERCISE TOLERANCE : Good (> 10 METS).
EXERCISE INDUCED ARRHYTHMIAS : No.
ECG RESPONSE : Normal.
ECG RESPONSE : Normal.

CLINICAL IMPRESSION

COMMENTS : *negative for inducible ischemia*



Dr. NAVEEN KUMAR .C
M.D., D.M.
Consultant Cardiologist
Reg. No. 52291

Confirmed By : _____

Signature

MR.M.C.NAGARAJU

Male 52Years


HR : 75 bpm
P : 109 ms
PR : 166 ms
QRS : 94 ms
QT/QTc : 366/411 ms
P/QRS/T : 39/49/54 °
RV5/SV1 : 1.12/0.609 mV

Diagnosis Information:

Sinus Rhythm

Flattened T Wave(LaVL)

Low T Wave(V5)

NSR
WNL

Dr. NAVLEK KUMAR .C
M.D., D.M.
Consultant Cardiologist
Reg. No. 52291

Report Confirmed by: