

DAKSH HOSPITAL

396 - 397, Gandhi Nagar, Scheme No. 8, ALWAR -301001

Ref. No.

Date.....

MEDICAL EXAMINATION REPORT Mediwheel (BOB)

Name: Mr. Chandra Prakash Age: 39 yrs Sex: Male Date: 24-03-2024

General Physical Examination

Height : 168 cm
Pulse : 66 mt
Respiration : 18/mt

Weight : 71 kg
BP : 110/70 mm/hg
BMI : 25.2 kg/m²

Systemic Exam:-

NORMAL

Dental Check up:-

NORMAL

Eye check-up:-

NORMAL

Skin Check up:-

NORMAL

ENT Check up:-


NORMAL

Impression:-

NORMAL

Recommendation:-

NO


Dr. Mukesh Kumar Gupta
MD Gen. Medicine
Reg. No 5423/16262

डॉ० मुकेश गुप्ता
M.D.F.C.C.S.
फिजिशियन एवं मधुमेह रोग विशेषज्ञ
दक्ष हॉस्पिटल, अलवर
रजि० नं०-5423/16262

Results

Run Date 24/03/2024 09:40:44 AM

Operator DAKSH

Last Name

Sample ID 4

First Name MR CHANDRA PRAKASH

Department

Gender Male

Age

Physician DR. MUKESH GUPTA M.D

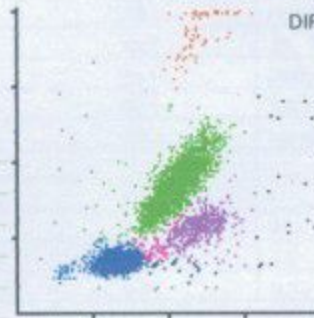
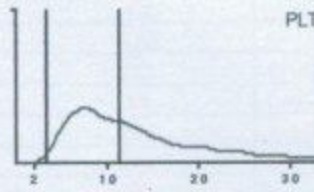
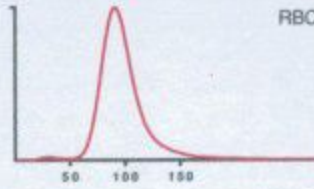
Patient ID AUTO_PID20471

Type Man

Date of birth

Sample comments

			Range
RBC	4.51	10 ⁶ /μL	3.80 - 5.50
HGB	14.0	g/dL	13.0 - 17.0
HCT	43.6	%	39.0 - 52.0
MCV	96.8	μm ³	76.0 - 100.0
MCH	31.1	pg	26.0 - 34.0
MCHC	32.1	g/dL	32.0 - 35.0
RDW-CV	16.0	%	11.0 - 16.0
RDW-SD	60.4	H μm ³	37.0 - 49.0
PLT	299	* 10 ³ /μL	150 - 450
PCT	0.37	* %	0.15 - 0.40
MPV	12.4	H* μm ³	8.0 - 11.0
PDW	22.8	h* μm ³	11.0 - 22.0
P-LCC	141	h 10 ³ /μL	44 - 140
P-LCR	47.3	%	18.0 - 50.0



WBC	9.60	10 ³ /μL	3.50 - 10.00
#	Range	%	Range
NEU	5.12	1.60 - 7.00	53.6 40.0 - 75.0
LYM	3.93	h 1.00 - 3.00	41.1 20.0 - 45.0
MON	0.25	0.20 - 0.80	2.7 2.0 - 10.0
EOS	0.13	0.00 - 0.50	1.3 1.0 - 6.0
BAS	0.13	0.00 - 0.15	1.3 h 0.0 - 1.0
LIC	0.04	0.00 - 0.10	0.4 0.0 - 1.0

Recommended actions

- Slide review
- Susp. Pathologies
- Macroplatelets

Dr. R.S. Gupta

Dr. R.S. GUPTA
MD (Pathology) (MAHE)
RMC No. 7924/19778

24/03/2024 09:41:57 AM

Printed by : DAKSH

S/N107Y0XH04136

1

Doctor

TECHNOLOGIST

All investigation have their own limitations regarding the sensitivity & specificity of individual assay procedures, Isolated laboratory investigations never confirm the final diagnosis of the disease. They only help in arriving at a diagnosis in conjunction with clinical presentation and other related investigations. Report is not valid for medico-legal purpose subject to ALWAR jurisdiction only.

Date :-24/03/2024

Name :- MR CHANDRA PRAKASH

Age & Sex :- 39 Yrs/ male

Refd. :- Dr Mukesh Gupta M.D.

	TEST NAME	RESULT	REFERENCE RANGE	
	ESR	14	00 -20 mm/hrs	
	Blood Group & Rh Factor	B " POSITIVE		
	HbA1C	4.8	4 - 5.6%	
	Blood Sugar (R)	83.1	< 150 mg/dl	
	Blood Sugar (PP)	-	< 140 mg/dl	
	Urine Sugar (F)	-	-	
	Urine Sugar (PP)	-	-	
LIVER	S.Bilirubin Total	1.3	0.30 - 1.20 mg/dl	
	S.Bilirubin Direct	0.4	0.10 - 0.30 mg/dl	
	S.Bilirubin Indirect	0.9	0.30 - 0.90 mg/dl	
	S.G.O.T.	29	> 37 u/l	
	S.G.P.T.	36	> 40 u/l	
	S.Aik. Phosp.	210	80 - 306 u/l	
	G.G.T.	22.1	5 -40 u/l	
	Total Protein	6.8	6.5 - 8.5 gm/dl	
	Albumin	3.8	3.8 - 5.4 gm/dl	
	Globulin	3.0	2.3 - 3.5 gm/dl	
	A/G Ratio	1.2	-	
AST/ALT Ratio	0.80	-		
KIDNEY	Blood Urea	27.1	15 -45 mg/dl	
	S.Creatinine	1.2	0.60 - 1.30 mg/dl	
	BUN	22.1	6 -24 mg/dl	
	S.Uric Acid	5.6	M 3.1 - 7.0, F 2.5 - 5.6 mg/dl	
	BUN/Creatinine Ratio	18.1	-	
LIPID PROFILE	Total Cholesterol	139.1	Up to 200 mg/dl	
	S.HDL	43.1	30 - 70 mg/dl	
	S.LDL	60.1	Up to 170 mg/dl	
	S.VLDL	36.1	5.0 - 40 mg/dl	
	S. Triglycerides	180.1	Up to 170 mg/dl	
	LDL/HDL Ratio	1.3	-	
	Total Cholesterol/ HDL Ratio	3.2	-	
THYROID	T3	92.1	40 - 181 ng/dl	
	T4	6.25	4.6 - 10.5 µg/dl	
	TSH	3.69	0.30 - 5.0 mIU/l	
URINE EXAMINATION			<i>Microscopic Examination:</i>	
General/Chemical Examination:			RBC	Absent
	Colour	Pale Yellow	WBC	1 -2
	Reaction	Acidic	Epithelial Cells	0- 1
	Specific Gravity	QNS	Cast	Absent
	Appearance	Clear	Crystal	Absent
	Albumin	Nil	Spermatozoa	Absent
	Sugar	Nil	Amorphous Sediments	Absent
			Other	Absent
X-RAY CHEST	NORMAL STUDY			
STOOL EXAMINATION			<i>Microscopic Examination:</i>	
General/Chemical Examination:			RBC	-
	Colour	-	WBC	-
	Consistency	-	Ova & Parasites	-

Dr. R.S. Gupta

Dr. R. S. GUPTA
MD (Pathology) (MAHE)
Doctor No. 1924/19778

TECHNOLOGIST

All investigation have their own limitations regarding the sensitivity & specificity of individual assay procedures, Isolated laboratory investigations never confirm the final diagnosis of the disease. They only help in arriving at a diagnosis in conjunction with clinical presentation and other related investigations. Report is not valid for medico-legal purpose subject to ALWAR jurisdiction only.



दक्ष हॉस्पिटल

396, गाँधी नगर स्कीम नं.8, अलवर (राज०) ☎ 0144-2703340

Sonography / 2D Echo Cardiography / Doppler Report

2D/ ECHO REPORT

Name: - Mr Chandra Prakash

Age: - 39 Yrs

Date: - 24-Mar-24

Reg. No.:- Alw/2009/04

BOB health checkup

PROCEDURES:

M-MODE/2D/DOPPLER/COLOR/CONTRASTB.A.S. M²

MEASUREMENT:			DOPPLER:				
AOD	22	NORMAL (20- 37mm)	MV	0.7	NORMAL (cm/sec.) (0.8- 1.3)	MR	No
LA	25	(19- 40mm)	AV	1.4	(1.2- 1.8)	AR	No
AVO	18	(12- 25mm)	TV	0.6	(0.3- 0.8)	TR	No
RVDd.	13.6	(03- 09mm)	PV	0.8	(0.7- 1.1)	PR	No
LVDd	51.7	(37- 56mm)	MITRAL VALVE-				
LVDs	33.6	(22- 40mm)			AML	Normal	
IVS d	8	(06- 12mm)			PML	Normal	
IVS s	10		AORTIC VALVE				
PWd	5.8	(05- 10mm)				1.8	
LV FUNCTION			TV & PV are normal.				
M- E- S Separation		<0.9cm					
Minor		24.42%					
LV Ejection Fraction	64%	65 +/- 12%					

MITRAL E>A

LV WALL MOTION: NO RWMA

ALL CARDIAC CHAMBERS ARE NORMAL

ALL VALVES ARE NORMAL

NO CLOT, VEGETATION, PERICARDIAL EFFUSION

Adv: - Follow up/ review at higher center for confirmation

Note:- Please Correlate clinically. Due to technical limitations as well as inaccuracies inherent in the laboratory and statistical analysis of biological process. Diagnostic accuracy of ECHO is up to 95% only.
Report is not valid for medico-legal purpose.


Dr. MUKESH GUPTA
PHYSICIAN
Physician & Sonologist
RM 5423/16262



"भ्रूण लिंग परीक्षण की शिकायत
104 टोल फ्री सेवा पर भी की
जा सकती है"

भ्रूण लिंग परीक्षण की शिकायत 104 टोल फ्री सेवा पर भी की जा सकती है।



दक्ष हॉस्पिटल

396, गाँधी नगर स्कीम नं.8, अलवर (राज०) ☎ 0144-2703340

Sonography / 2D Echo Cardiography / Doppler Report

Name: MR. CHANDRA PRAKASH /M/39 YRS

Date: 24-Mar-24

BOB HEALTH CHECK UP

U.S.G. OF ABDOMEN & PELVIS

LIVER

Liver is **14.7 cm vertically** with normal echo-texture. Intra hepatic biliary radicals are not dilated. No evidence of focal or diffuse lesion.

GALL BLADDER

Gall bladder is normal dilated. Lumen clear. Wall thickness normal. CBD normal

PANCREAS

Pancreas is normal in size, shape & echo-texture.

SPLEEN

8.7 cm in size with normal shape & echo- texture.

BOTH KIDNEY

Both kidney normal shape, size & echo texture. CMD maintained

PROSTATE is normal shape, size & echo texture..

URINARY BLADDER is normal shape, size & echo texture. lumen appear clear. Wall thickness normal.

Advice- X Ray KUB / URINE EXAM

Please correlate clinically. USG accuracy is 95 % due to technical limitations as well as inaccuracies inherent in the laboratory and statistical analysis biological process.

This report is not valid for medico-legal cases.


Dr. Manish Kumar Gupta
SONOLOGIST
Physician & Sonologist
RM 5423/16262



"भ्रूण लिंग परीक्षण की शिकायत
104 टोल फ्री सेवा पर भी की
जा सकती है"

भ्रूण लिंग परीक्षण की शिकायत 104 टोल फ्री सेवा पर भी की जा सकती है।

11-02-2024 02:36:41 PM

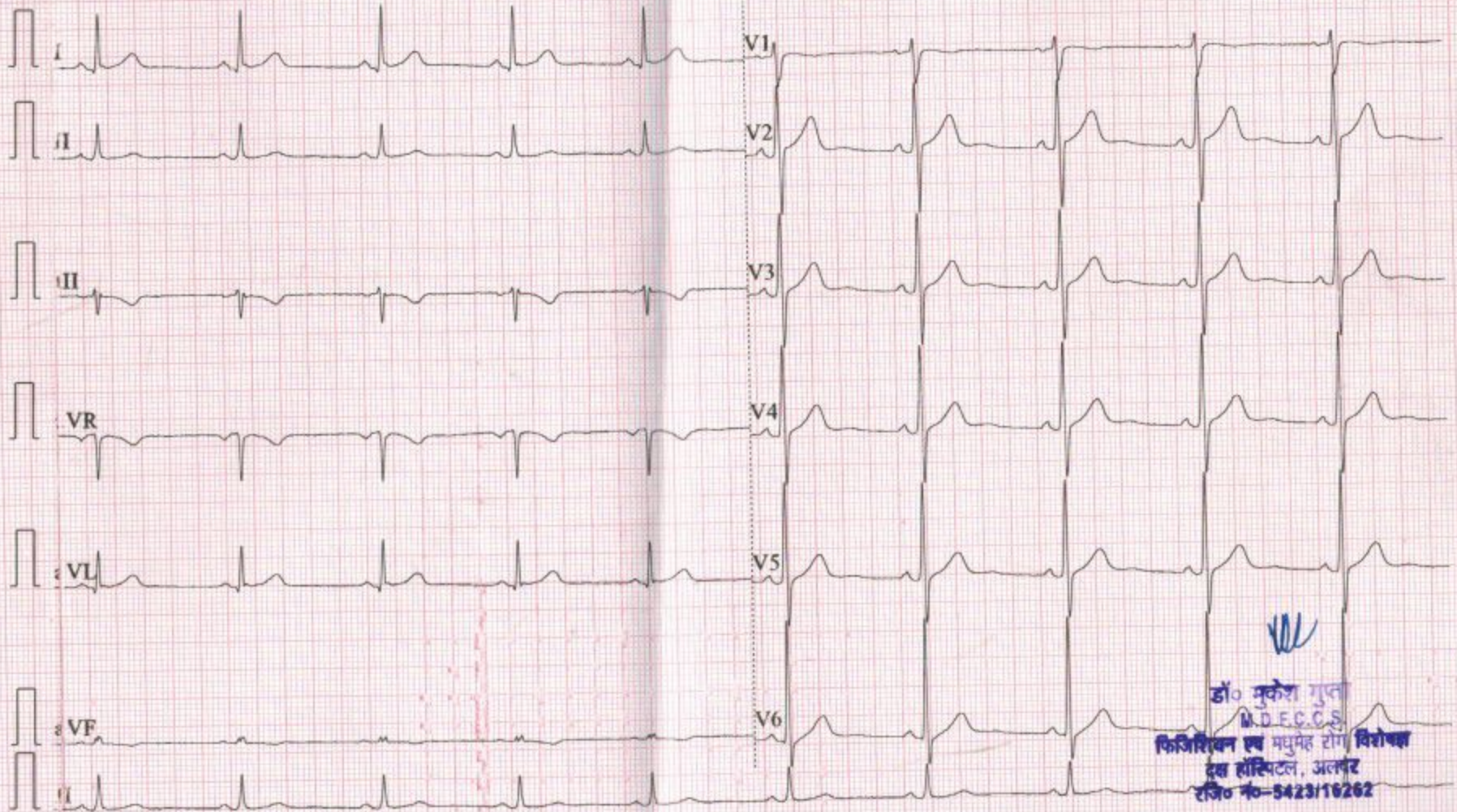
ID: k

male Years

HR	:	60	bpm
P	:	94	ms
PR	:	128	ms
QRS	:	78	ms
QT/QTc	:	388/389	ms
P/QRS/T	:	15/11/-5	°
RV5/SV1	:	1.758/0.554	mV

Diagnosis Information:
Sinus Rhythm
Normal ECG

Report Confirmed by:



(Handwritten signature)

डॉ० मुकेश गुप्ता
M.D.E.C.C.S.
किजिबिन् एच मधुमेह रोग विशेषज्ञ
दक्ष हॉस्पिटल, अलवर
फ़ोन नं०-9423116262

R

