

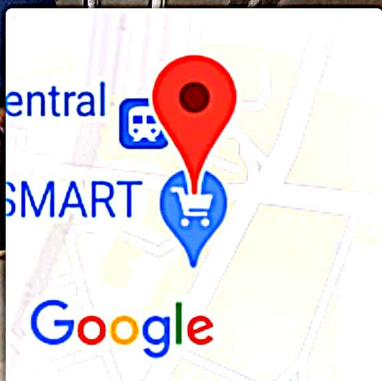
Mumbai, Maharashtra, India

Shop No. - 3, Akhil Bhartiy Bhavan, Belasis Road, Tardeo, Mumbai -
400034, Marzban Parsi Colony, Dalal Estate, Mumbai Central, Mumbai,
Maharashtra 400008, India

Lat 18.968769°

Long 72.819986°

11/09/21 09:38 AM



✓ melwabr

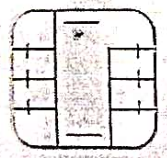
Sidharth

[Signature]
DR. HARI CHHABLANI
M.B.B.S. (P) (RESP MEDICINE) PGCHMM, PGDMLS
FELLOW INTENSIVE CARE
MMC REG. NO. - 91702

"DR. PLUS HEALTHCARE CENTRE"
NATHANI HEIGHTS', B-WING,
42, MUMBAI CENTRAL (EAST)

Transport Department Government of NCT of Delhi
Licence to Drive Vehicles Throughout India

Licence No. : DL-0420070335713 (P) D
Name : SIDHARTH AGARWAL
S/W/D : B B AGARWAL
DOB : 27/09/1985 BG : U
Address :
A-150 SHANKAR GDN VIKAS PURI
NEW DELHI 110018



Auth to Drive : M.CYL.
LMV-NT
Date of Issue : 29/12/2007
29/12/2007

Issue Date : 01/10/2014
Validity(NT) : 28/12/2027
Validity(T) : NA
Inv Carr No : NA

[Signature]
(Holder's Signature)
Issuing Authority
WZ-1, JANAKPURI

"DR- PLUS HEALTHCARE CENTRE"

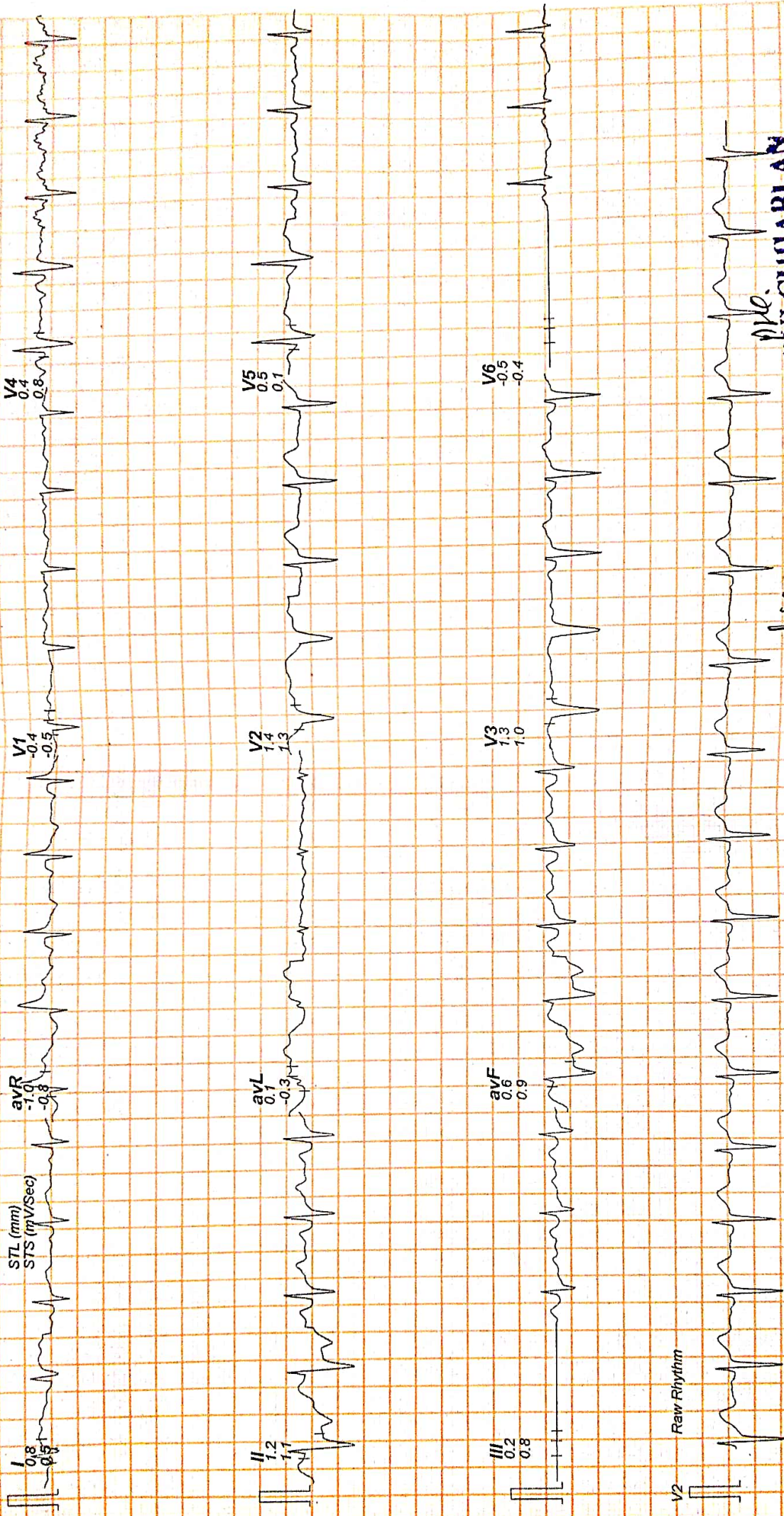
MUMBAI CENTRAL
15079 / SIDHARTH AGARWAL / 35 Yrs / Male / 0 Cm / 0 Kg

Linked Medians Report
BRUCE: Supine (0:39)



Date: 11-09-2021 12:14:16 PM METs: 1.0 HR: 103 Target HR: 56% of 185 BP: 120/80 Post J @ 80mSec

ExTime: 00:00 Speed: 0.0 mph Grade: 00.00 % 25 mm/Sec. 1.0 Cm/mV



Sinus bradycardia

DR. PURNIM CHABLAN
MBBS, DNB, (Medicine)

Consultant Physician And Intensiv
Reg No 7769F

**"DR- PLUS HEALTHCARE CENTRE"
MUMBAI CENTRAL**

REPORT



15079 / SIDHARTH AGARWAL / 35 Yrs / M / 0 Cms / 0 Kg Date: 11-Sep-2021 Refd By : DR.PURVI CHHABLANI

REPORT :

TEST OBJECTIVE	:	ROUTINE CHECK UP
RISK FACTOR	:	AGE, SMOKING
ACTIVITY	:	GOOD
MEDICATION	:	NIL
BRIEF HISTORY	:	SMOKING
OTHER INVESTIGATION	:	NIL
REASON FOR TERMINATION	:	TARGET HEART RATE ACHIEVED
EXERCISE TOLERANCE	:	GOOD
EXERCISE INDUCED ARRHYTHMIAS	:	INSIGNIFICANT
HAEMODYNAMIC RESPONSE	:	NORMAL
CHRONOTROPIC RESPONSE	:	NORMAL
FINAL IMPRESSION	:	STRESS TEST IS NEGATIVE FOR EXERCISE INDUCED ISCHAEMIC HEART DISEASE

DR. PURVI CHHABLANI
MBBS, DNB (Medicine)
Consultant Physician and Internist
REG. NO. 77612

Doctor : DR.PURVI CHHABLANI

"DR- PLUS HEALTHCARE CENTRE"
MUMBAI CENTRAL



Report

15079 / SIDHARTH AGARWAL / 35 Yrs / M / 0 Cms / 0 Kg Date: 11-Sep-2021 Refd By : DR.PURVI CHHABLANI Examined By: DR. HARI CHHABLANI

Stage	Time	Duration	Speed(mph)	Elevation	METs	Rate	% THR	BP	RPP	PVC	Comments
Supine	00:38	0:38	00.0	00.0	01.0	103	56 %	120/80	123	00	
Standing	00:44	0:06	00.0	00.0	01.0	107	58 %	120/80	128	00	
HV	00:49	0:05	00.0	00.0	01.0	105	57 %	120/80	125	00	
Warm Up	00:58	0:09	00.0	00.0	01.0	105	57 %	120/80	125	00	
ExStart	01:04	0:06	01.0	00.0	01.0	104	56 %	120/80	124	00	
BRUCE Stage 1	04:04	3:00	01.7	10.0	04.7	127	69 %	132/80	167	00	
BRUCE Stage 2	07:04	3:00	02.5	12.0	07.1	154	83 %	146/80	224	00	
PeakEx	07:23	0:19	03.4	14.0	07.4	160	86 %	156/80	249	00	
Recovery	08:23				00.0	000	0 %	150/80	000	00	
Recovery	08:46	0:55	01.1	00.0	01.6	144	78 %	140/80	201	00	

FINDINGS :

Exercise Time : 06:19
 Max HR Attained : 160 bpm 86% of Target 185
 Max BP Attained : 156/80
 Max WorkLoad Attained : 7.4 Fair response to induced stress
 Test End Reasons : Test Complete

DR. PURVI CHHABLANI
 MBBS, DNB, (Medicine)
 Consultant Physician And Intensivist
 Reg No 77696

Doctor : DR.PURVI CHHABLANI

"DR- PLUS HEALTHCARE CENTRE"

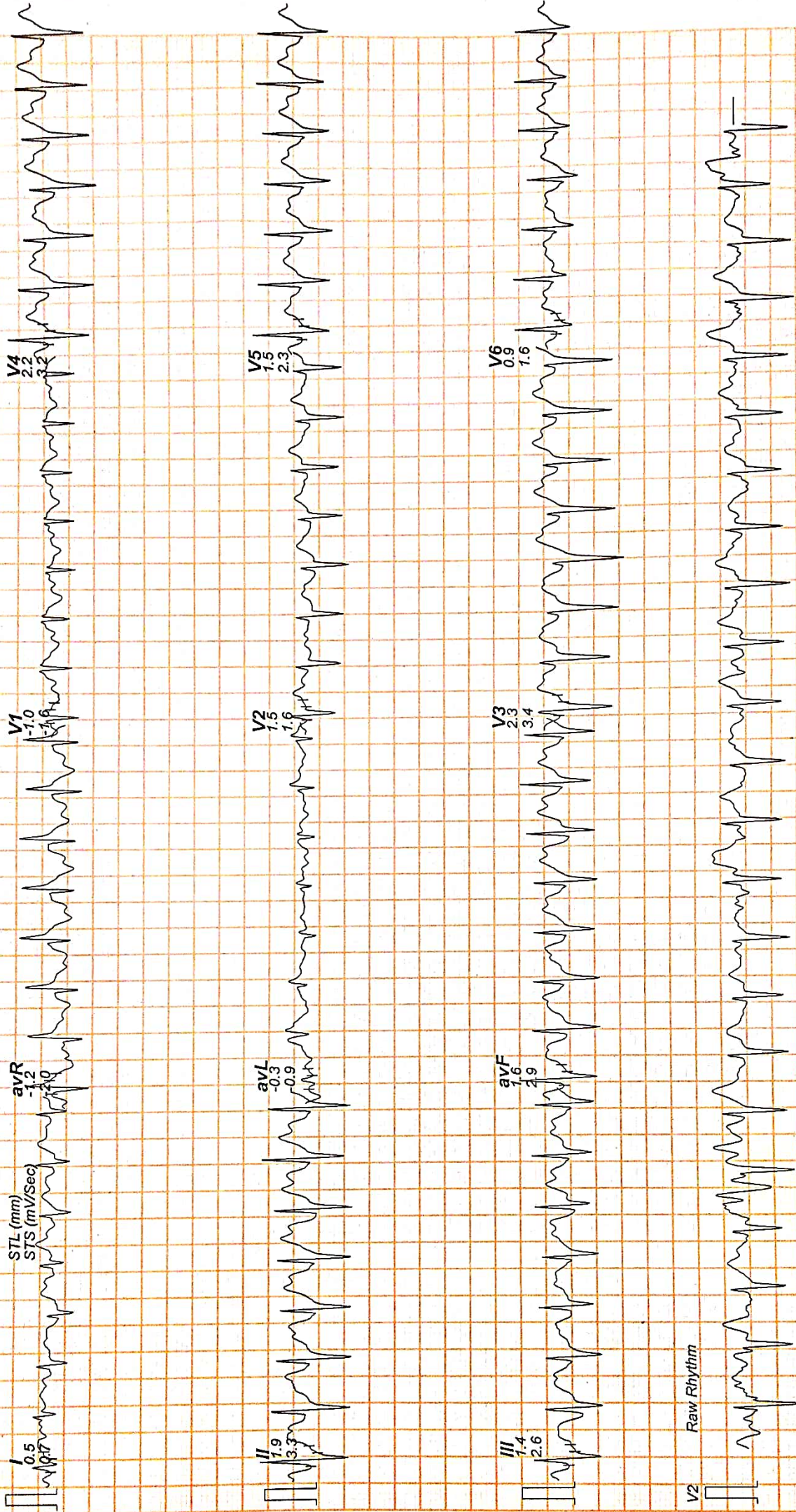
MUMBAI CENTRAL
15079 / SIDHARTH AGARWAL / 35-Yrs / Male / 0 Cm / 0 Kg

Linked Medians Report
Recovery : (00:51)



Date: 11-09-2021 12:14:16 PM METs: 1.9 HR: 142 Target HR: 77% of 185 BP: 140/80 Post J @60mSec

Ex Time: 06:19 Speed: 1.1 mph Grade : 00.00 % 25 mm/Sec. 1.0 Cm/mV



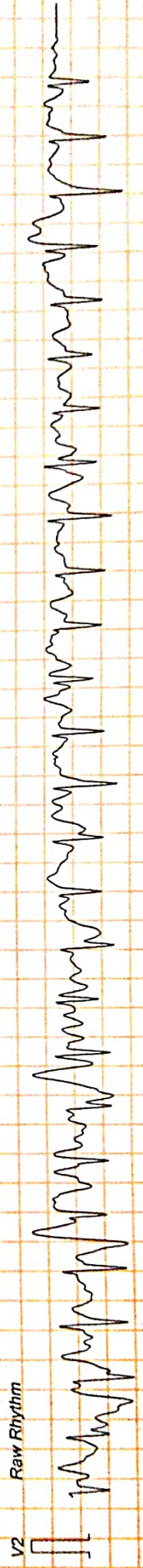
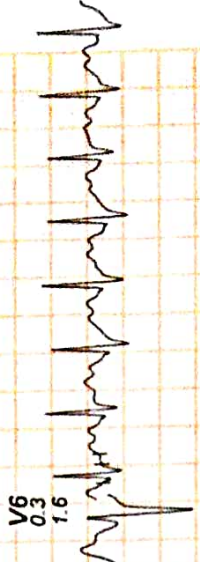
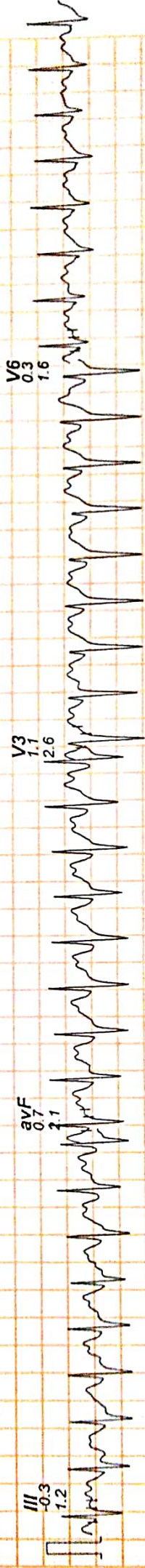


"DR- PLUS HEALTHCARE CENTRE"

MUMBAI CENTRAL
15079 / SIDHARTH AGARWAL / 35 Yrs / Male / 0 Cm / 0 Kg

Linked Medians Report
Recovery : (00:13)



Date: 11 - 09 - 2021 12:14:16 PM METs : 5.7 HR : 164 Target HR : 89% of 185 BP : 156/80 Post J @ 60mSec
Ex Time: 06:19 Speed: 1.1 mph Grade : 00.00 % 25 mmVSec. 1.0 Cm/mV





Dr-Plus Healthcare Centre

NATHANI HEIGHTS, B-Wing, Shop No. 42, Ground Floor, Opp. Mumbai Central Station (East), Mumbai - 400 008.

Patient's Name : SIDHARTH AGARWAL

Report Date : 11/09/2021

Referred By Dr. : DR. HARI CHHABLANI

Age : 35 Years

Sex : MALE

Chest X-ray PA

- No active pulmonary lesion seen.
- Trachea and mediastinum are in midline .
- Cardiac size and configuration are within normal limits .
- Pleural cavities are clear .
- Domes of diaphragm are smooth in outline.
- Bony thorax is normal .


Radiologist

DR. A. J. MAZUMDAR

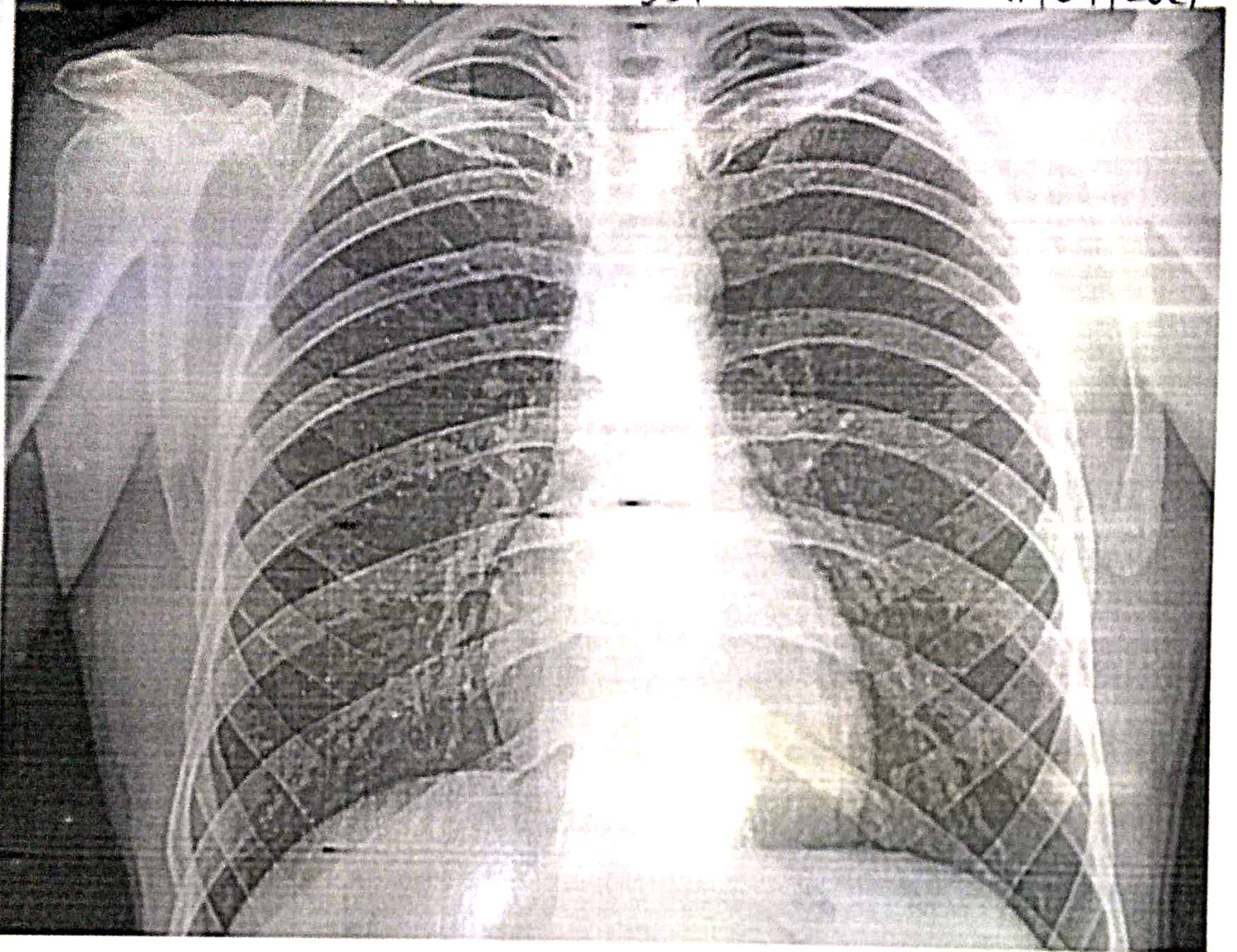
MD. DMRE, MDRD

"DR. PLUS HEALTHCARE CENTRE"
NATHANI HEIGHTS', B-WING,
42, MUMBAI CENTRAL (EAST)

SIDHARTH AGARWAL

35 | M

11 | 09 | 2021





Dr-Plus Healthcare Centre

NATHANI HEIGHTS, B-Wing, Shop No. 42, Ground Floor, Opp. Mumbai Central Station (East), Mumbai - 400 008.

Patient Name	:	SIDHARTH AGARWAL	Sex:	MALE
Doctor's Name	:	DR. H. CHHABLANI	Age:	35 YEARS
Date	:	11/09/2021		

ULTRASONOGRAPHY OF THE ABDOMEN AND THE PELVIS:

The relevant sonographic findings include the following:

HEPATOBIILIARY APPARATUS

The liver is normal in size and echogenicity. No obvious focal parenchymal lesion is seen. Extrahepatic biliary radicals are not dilated.

The portal vein and the common bile duct are normal.

GALL BLADDER

The gall bladder is adequately distended. The wall thickness is normal.

No echogenic contents are noted in its lumen. There is no pericholecystic collection noted.

PANCREAS

The pancreas shows normal echogenicity and size. No focal or diffuse lesions are noted.

No evidence of calcification is noted.

SPLEEN

The spleen appears normal in size and echogenicity. No focal or diffuse lesions are noted.

No evidence of calcification is noted.

KIDNEYS

Right Kidney measure: 10.4 x 4.7 cm, Left kidney measure: 10.2 x 4.3 cm

Both the kidneys appear normal in size, shape and echogenicity. Both the pelvicalyceal system is normal and both corticomedullary differentiations are well maintained. There is no obvious focal or diffuse lesion noted. No evidence of any calculus seen in either kidney.

PROSTATE

The Prostate appears normal and shows a normal echogenicity.

URINARY BLADDER

The urinary bladder shows anechoic contents. Its wall thickness appears normal.

No evidence of calcification is seen.

There is no obvious evidence of abdominal or pelvic lymphadenopathy or ascites noted.

IMPRESSION: No significant abnormality is detected.

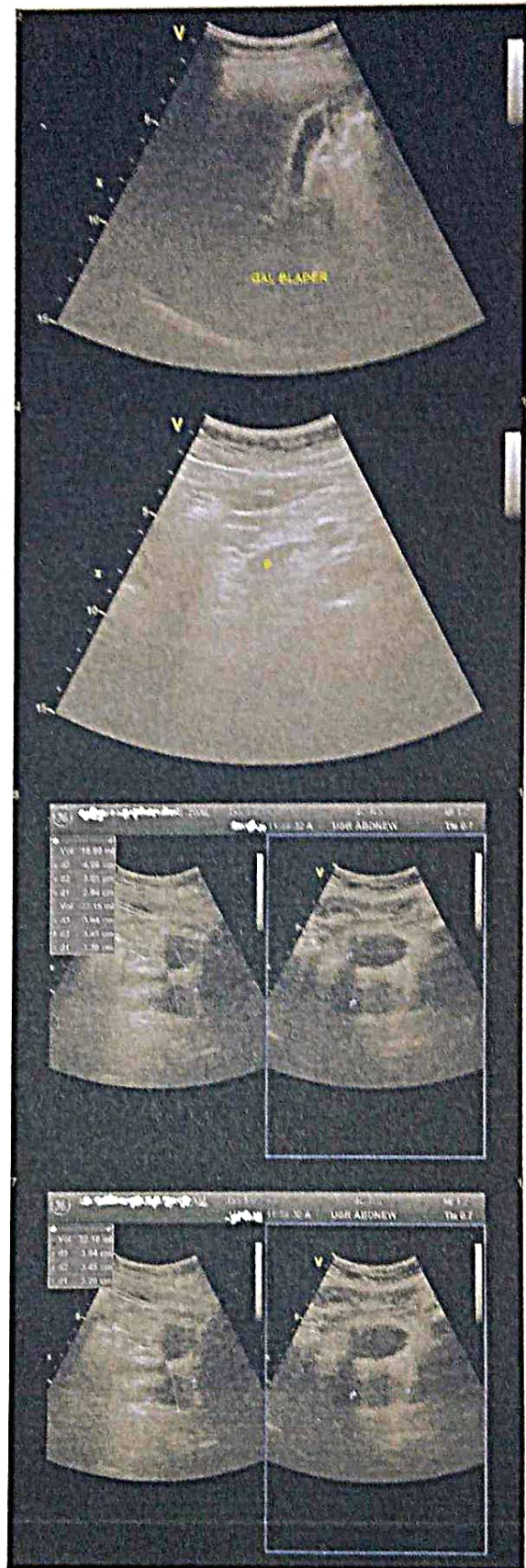
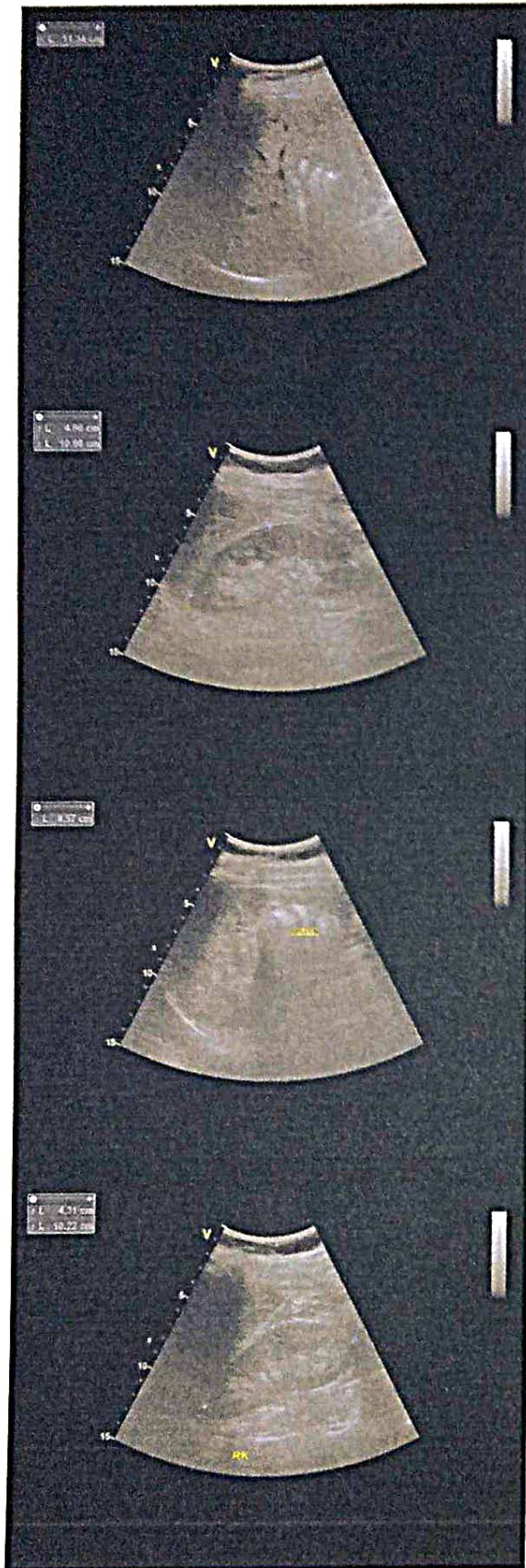
Dr. Parag Jhaveri
MBBS (BOM), DMRE (BOM)
Radio-Sonologist

'DR. PLUS HEALTHCARE CENTRE'
NATHANI HEIGHTS, B-WING.
42, MUMBAI CENTRAL (EAST)

Name **SIDHARTH AGARWAL**

Sex **Male**

Age **35**





Dr-Plus Healthcare Centre

NATHANI HEIGHTS, B-Wing, Shop No. 42, Ground Floor, Opp. Mumbai Central Station (East), Mumbai - 400 008.

Full Name

SIDHARTH AGARWAL

35/M

DATE: 11/09/202

	Type of Test	Actual Reading	Normal Range
1	Fasting Blood Sugar	87	70-100 mg%
2	PPBS	128	110 TO 140 mg%
3	Total Cholesterol	237	120-200 mg%
4	VERY LOW DENSINTY LEVEL(VLDL)	34	10-30 mg/dl
5	High Density Lipid (HDL)	48	40-60 mg%
6	Low Density Lipid (LDL)	155	Upto 150
7	S. Triglycerides	151.8	50-150 mg%
8	CHOL/HDL	4.9	Upto 5
9	HDL/LDL	0.30	
10	S. Creatinine	0.9	0.5-1.2 mg%
11	Blood Urea Nitrogen (BUN)	16.5	7-21 mg%
12	BUN/CREAT RATIO	18.3	
13	S. Proteins	6.8	6.0-7.9 mg%
14	(a) Albumin	3.6	3.5-5.5 mg%
15	(b) Globulin	3.2	2.0-3.5 mg%
16	A/G RATIO	1.12	
17	S. Bilirubin	0.9	0.3-1.3mg%
18	(a) Direct	6.0	0.0-0.8 mg%
19	(b) Indirect	3.0	0.0-0.5 mg%
20	SGOT (AST)	22.6	05-34 IU
21	SGPT (ALT)	30.8	05-40 IU
22	GGTP (GGT)	41.3	05-50 IU
23	SGOT/SGPT	0.7	
24	HBA1C	5.55	UPTO 6.5
25	S. Alkaline Phosphatase	89.2	30-115 IU
26	T3	148.9	80-180ng/dl
27	T4	7.1	4.6-12 ug/dl
28	TSH	2.58	0.4-4.0 mIU/L
29	SERUM URIC ACID	6.52	2.5-7.2mg/dl
30	URINE SUGAR PP	ABSENT	
31	URINE SUGAR FASTING	ABSENT	
32	BLOOD GROUP	" B"POSITIVE"	

DR. RAKESH PATKAR
M.D., D.N.B. (Pathology)
Reg. No. 2013/05/1660



Dr-Plus Healthcare Centre

NATHANI HEIGHTS, B-Wing, Shop No. 42, Ground Floor, Opp. Mumbai Central Station (East), Mumbai - 400 008.

Full Name of life to be assured:

SIDHARTH AGARWAL

35/M

DATE:11/09/2021

HAEMOGRAM

Normal Range

1.	Red Blood Cell Count	4.9	[M : 4.5 - 5.6 / F : 3.5 - 5.5/cu.mm]
2.	Hb%	15	[M: 14-18 / F : 11-16%]
3.	Hematocrit	45	[M : 40-53 / F : 30-47 %]
4.	Indices:		
(a)	MCV(Mean Corpuscular Volume)	89	[79-101 cu.mi.]
(b)	MCH(Mean Corpuscular Hb)	29	[27-32 pg]
(c)	MCHC(Mean Corpuscular Hb Concentration)	32	[32-38%]
5.	Morphology		
	Macrocytes : --	Microcytes: --	Hypochromia: --
	Poikilocytosis: --	Anisocytosis: --	
6.	Target cells: --		
	Spherocytes: --	Elliptocytes: --	
7.	TOTALW.B.C.Count	5,900	{4000-11000/cu.mm}
	Differential Count		
a)	Neutrophils :	67	[45 - 70%]
b)	Lymphocytes :	22	[20 - 45%]
c)	Eosinophils:	05	[01 - 06%]
d)	Monocytes:	05	[00 - 08%]
e)	Basophils :	01	[00 - 01%]
8.	Platelets : 3.65		1.5-4.5 Lacks/cu.mm
9.	Erythrocyte Sedimentation Rate:10		20 mm at end of 1 hour
			Method : Westergrens

ROUTINE URINE EXAMINATION (RUA)

1. Physical Examination:

(i)	Colour:	PLAN YELLOW	(ii)	Sediment:	CLEAR
(iii)	Transparency:	ABSENT	(iv)	Reaction:	ACIDIC
(v)	Specific gravity	1.010			

2. Chemical Examination:

(i)	Protein :	ABSENT	(ii)	Sugar:	ABSENT
(iii)	Bile salt:	ABSENT	(iv)	Bile pigment:	ABSENT

3. Microscopic Examination:

(i)	Red Blood Cells:	ABSENT	(ii)	Epithelial Cells:	ABSENT
(iii)	Crystals:	ABSENT	(iv)	Pus Cells:	02 TO 03/HPF
(v)	Casts:	ABSENT	(vi)	Deposits:	ABSENT
(vii)	Bacteria's :	ABSENT			

DR. RAKESH PATKAR
M.D., N.B. (Pathology)
Reg. No. 2013/05/1660



Dr. Hari Chhablani

Cardiometabolic Physician & Intensivist
M.B.B.S., F.C.C.P. (RESP. MED.), PGDHHM,
PGDMLS, FELLOW INTENSIVE CARE MED.

ATTACHED TO: Wockhardt Hospital • Saifee Hospital • Apollo Spectra Hospital

NATHANI HEIGHTS, B-Wing, Shop No. 42, Ground Floor, Opp. Mumbai Central Station (East),
Mumbai - 400 008. • Cell : 98206 46163 • E : drharichhablani@gmail.com

PHYSICIAN REPORT

11/09/2021

NAME : SIDHARTH AGARWAL

AGE/SEX: 35/M

PRESENTING COMPLAINS: NIL

PAST HISTORY: COVID -19 POSITIVE

TREATMENT HISTORY : NIL

FAMILY HISTORY: NOT SIGNIFICANT

ADDICTION: SMOKING , ALCOHOL

P: 92/MIN

BP: 124/80

RS: CLEAR

CVS: S1,S2 REGULAR

PA: SOFT

CNS: CLINICALLY NAD

ECG: WNL

CXR: WNL

LABS: ATTACHED

EYE EXAMINATION B/E : NEAR VISION - BL N6 DISTANT VISION - 6/6 COLOUR VISION - NORMAL

IMPRESSION : REFER TO CARDIOLOGIST.

DR. HARI CHHABLANI

DR. HARI CHHABLANI
M.B.B.S.;F.C.C.P.(RESP MEDICINE) PGDHHM, PGDMLS
FELLOW INTENSIVE CARE
MMC REG. NO. - 91702