

Employee Name	Mr. Jagadish Rachalkonda
---------------	--------------------------

Employee ID	176814
-------------	--------

Age	34 yrs
-----	--------

Gender	male
--------	------

Date	25/02/2023
------	------------

Name of center	NH SAJJAPUR
----------------	-------------

City	Bangalore
------	-----------

BASIC PARAMTERS:

Height (in mts)	173 cm
Weight (in Kgs)	94 kg
BMI	

Waist circumference (in cms)	106 cm
Hip circumference (in cms)	107 cm
Waist-to-hip ratio	

Systolic BP	110
Diastolic BP	70

A B.K



**Health Check up Booking Confirmed Request(bobS30546),Package Code-
PKG10000248, Beneficiary Code-75104**

Mediwheel <wellness@mediwheel.in>

Thu 2/23/2023 1:22 AM

To: Info Sarjapur <info.sarjapur@narayanahealth.org>

Cc: mediwheelwellness@gmail.com <mediwheelwellness@gmail.com>

Attention: This email originated outside of Narayana Health domain. Links and attachments cannot be verified as authentic. Do not share personal/organisational data including passwords or act based on the content of the email, unless you have verified the authenticity of the sender and email address thoroughly.

011-41195959

Email:wellness@mediwheel.in

Hi **Narayana Multispeciality Clinic**,

Diagnostic/Hospital Location :**83/3 Doddakanneli,Sarjapur,Main Road , Near Wipro Gate-
560035, City:Bangalore**

We have received the confirmation for the following booking .

Beneficiary Name : PKG10000248

Beneficiary Name : Jagadish rachalkonda

Member Age : 32

Member Gender : Male

Member Relation : Spouse

Package Name : Mediwheel Metro Full Body Health Checkup Male Below 40

Location : RANGAREDDY,Telangana-500083

Contact Details : 9618091020

Booking Date : 22-02-2023

Appointment Date : 25-02-2023

Instructions to undergo Health Check:

1. Please ensure you are on complete fasting for 10-To-12-Hours prior to check.
2. During fasting time do not take any kind of medication, alcohol, cigarettes, tobacco or any other liquids (except Water) in the morning.
3. Bring urine sample in a container if possible (containers are available at the Health Check centre).
4. Please bring all your medical prescriptions and previous health medical records with you.
5. Kindly inform the health check reception in case if you have a history of diabetes and cardiac problems.

For Women:

1. Pregnant Women or those suspecting are advised not to undergo any X-Ray test.
2. It is advisable not to undergo any Health Check during menstrual cycle.

We request you to facilitate the employee on priority.

Package Details

Patient Name : Mr Jagadish Rachalkonda, 20100000023965, male, 34y 11m
Package Name : EHP Mediwheel Full Body Health checkup Below 40 Male
Start Date : 25/02/2023 07:54 End Date : 26/02/2023 07:54
Generated By : Hemanth Kumar
Generated On : 25-02-2023 07:54

Service Name	Ordered Date	Service Center	Consultant	Qty	Explicit
CONSULTATION - FIRST VISIT	25/02/2023 07:54 AM	OPD-2F	Dr. Sharma Vasant Kumar	1	No
✓ USG ABDOMEN	25/02/2023 07:54 AM	ULTRA SOUND-2F	Dr. Sharma Vasant Kumar	1	No
✓ XRAY CHEST PA	25/02/2023 07:54 AM	X-RAY	Dr. Sharma Vasant Kumar	1	No
✓ ECHO COLOR DOPPLER	25/02/2023 07:54 AM	ECHO-2F	Dr. Sharma Vasant Kumar	1	No
○ TREADMILL TEST	25/02/2023 07:54 AM	OPD-2F	Dr. Sharma Vasant Kumar	1	No
○ ECG	25/02/2023 07:54 AM	OPD-2F	Dr. Sharma Vasant Kumar	1	No
✓ BLOOD UREA NITROGEN (BUN)	25/02/2023 07:54 AM	BIOCHEMISTRY	Dr. Sharma Vasant Kumar	1	No
✓ URIC ACID	25/02/2023 07:54 AM	BIOCHEMISTRY	Dr. Sharma Vasant Kumar	1	No
✓ THYROID PROFILE (T3, T4, TSH)	25/02/2023 07:54 AM	BIOCHEMISTRY	Dr. Sharma Vasant Kumar	1	No
✓ LIVER FUNCTION TEST (LFT)	25/02/2023 07:54 AM	BIOCHEMISTRY	Dr. Sharma Vasant Kumar	1	No
✓ SERUM CREATININE	25/02/2023 07:54 AM	BIOCHEMISTRY	Dr. Sharma Vasant Kumar	1	No
✓ LIPID PROFILE (CHOL, TRIG, HDL, LDL, VLDL)	25/02/2023 07:54 AM	BIOCHEMISTRY	Dr. Sharma Vasant Kumar	1	No
✓ HBA1C	25/02/2023 07:54 AM	BIOCHEMISTRY	Dr. Sharma Vasant Kumar	1	No
✓ URINE FOR SUGAR (FASTING)	25/02/2023 07:54 AM	CLINICAL PATHOLOGY	Dr. Sharma Vasant Kumar	1	No
✓ URINE FOR SUGAR (POST PRANDIAL)	25/02/2023 07:54 AM	CLINICAL PATHOLOGY	Dr. Sharma Vasant Kumar	1	No
✓ POST PRANDIAL BLOOD SUGAR (PPBS)	25/02/2023 07:54 AM	BIOCHEMISTRY	Dr. Sharma Vasant Kumar	1	No
✓ FASTING BLOOD SUGAR (FBS)	25/02/2023 07:54 AM	BIOCHEMISTRY	Dr. Sharma Vasant Kumar	1	No
✓ BLOOD GROUP & RH TYPING	25/02/2023 07:54 AM	NARAYANA HRUDAYALAYA BLOOD CENTRE	Dr. Sharma Vasant Kumar	1	No
✓ STOOL ROUTINE EXAMINATION	25/02/2023 07:54 AM	CLINICAL PATHOLOGY	Dr. Sharma Vasant Kumar	1	No
✓ URINE ROUTINE & MICROSCOPY	25/02/2023 07:54 AM	CLINICAL PATHOLOGY	Dr. Sharma Vasant Kumar	1	No
✓ ERYTHROCYTE SEDIMENTATION RATE (ESR)	25/02/2023 07:54 AM	HEMATOLOGY	Dr. Sharma Vasant Kumar	1	No

WT - 94
 HT - 173 cm
 HSP - 107 cm
 Wrist - 106 cm



Service Name	Ordered Date	Service Center	Consultant	Qty	Explicit
✓ COMPLETE BLOOD COUNT (CBC)	25/02/2023 07:54 AM	HEMATOLOGY	Dr. Sharma Vasant Kumar	1	No



25-02-2023 07:54

TRANS-THORACIC ECHO REPORT

Patient MRN : 201-23965

Date : 25.02.2023

Patient Name : Mr.JAGADISH RACHALKONDA

Age/Gender : 34 yrs/male

M-MODE / 2D MEASUREMENTS

LVEF (>55)% : 60%	LVID(d) (40-56)mm : 46mm	LVID (s) mm : 31mm
TAPSE (>16) mm : 20mm	IVS (d) (6-10)mm : 11mm	LV-EDV ml : --
LA (<39) mm : 29mm	PWD (d) (6-10)mm : 10 mm	LV-ESV ml : --
RA (<44)mm : 32mm	RV (<35) mm : 27mm	BSA m ² : --

DOPPLER MEASUREMENTS

MITRAL VALVE : E/A - 0.9/0.6 M/S, NORMAL LV DIASTOLIC FUNCTION, MR-TRIVIAL

AORTIC VALVE : PG - 4 MMHG /AR-TRIVIAL

TRICUSPID VALVE : TR -TRIVIAL

PULMONARY VALVE : PG - 4 MMHG

PA PRESSURE : PASP- 21 MMHG/ NORMAL PA PRESSURE.

FINDINGS

SITUS SOLITUS, LEVOCARDIA, AV AND VA CONCORDANT, NORMAL GREAT ARTERY RELATIONSHIP

VALVES

MITRAL : NORMAL

AORTIC : NORMAL

TRICUSPID : NORMAL

PULMONARY : NORMAL

CHAMBERS

LV : NORMAL SIZED, NORMAL LV SYSTOLIC FUNCTION.

RV : NORMAL SIZED, NORMAL RV FUNCTION.

RWMA : NO RWMA

LVOT : NORMAL LV AND VA CONCORDANT, NORMAL GREAT ARTERY RELATIONSHIP

LEFT ATRIUM : NORMAL SIZED

RIGHT ATRIUM : NORMAL SIZED

SEPTAE

IVS : INTACT

IAS : INTACT

ARTERIES & VEINS

AORTA : AORTIC ANNULUS - 18 MM, ASCENDING AORTA- 27 MM,
NORMAL ARCH NORMAL SIZED.

PULMONARY ARTERY : NORMAL

IVC, SVC & CS : IVC - 13 MM, NORMAL SIZED, COLLAPSING, NORMAL RA PRESSURE.

PULMONARY VEINS : NORMAL

PERICARDIUM : NORMAL

VEGETATION / THROMBUS / TUMOR: NIL

OTHER FINDINGS:

SINUS RHYTHM- 76 BPM
NO PREVIOUS ECHO REPORT

CONCLUSION


NORMAL CHAMBER DIMENSIONS

NORMAL PA PRESSURE AORTIC ANNULUS - 18 MM, ASCENDING AORTA - 27 MM,
NORMAL ARCH NORMAL SIZED.

NO RWMA

NORMAL LV SYSTOLIC FUNCTION

LVEF:- 55-60%


CHANDANA V
CARDIAC SONOGRAPHER

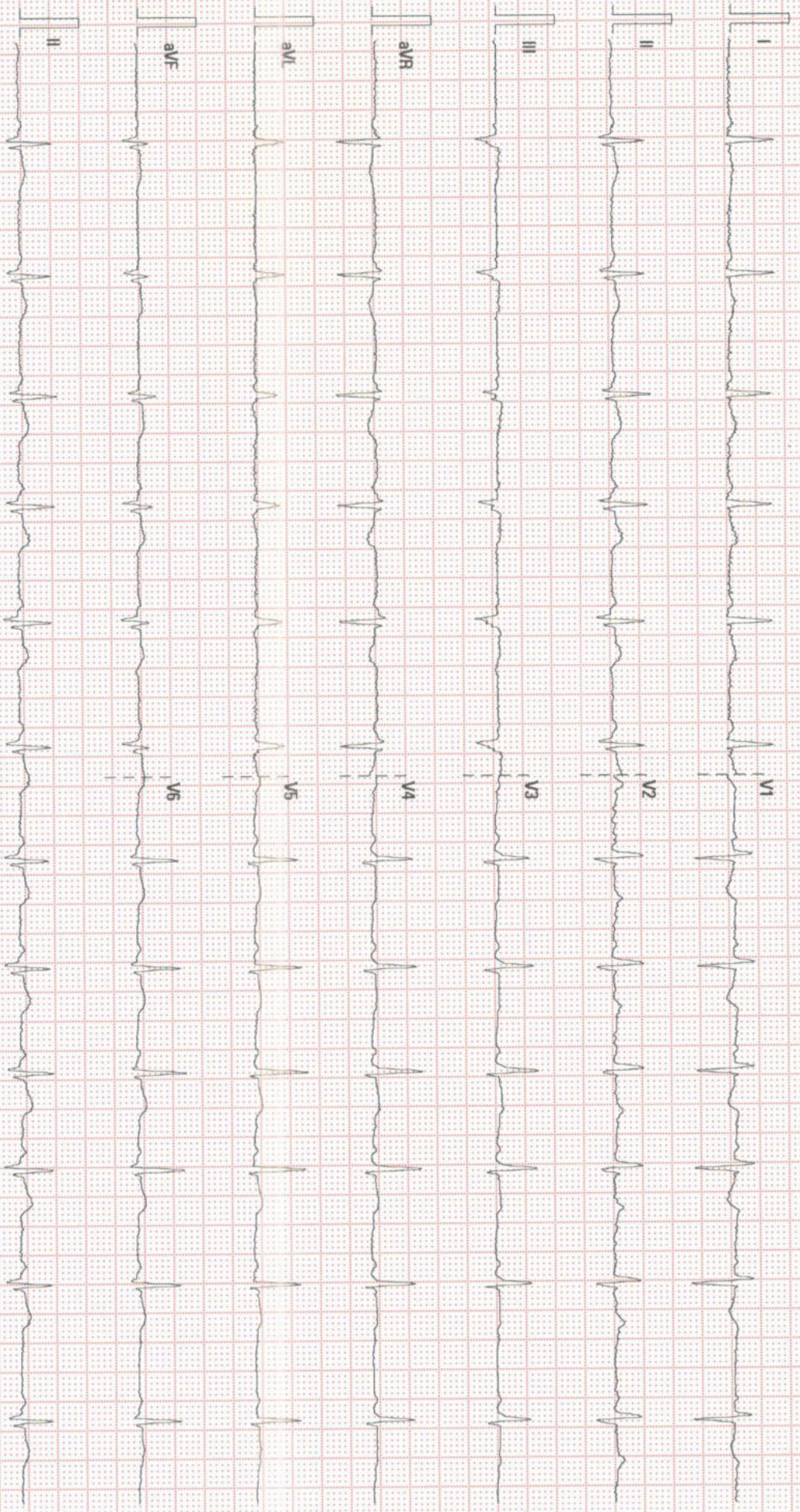
ID: 201-23965
Name: MR JAGADISH
Age: 34 Years
Gender: Male

25-02-2023 09:53:34

Vent. Rate	76 bpm
PR Interval	118 ms
QRS Duration	98 ms
QT/QTc Interval	386/414 ms
P/QRS/T Axes	40/-4/50 deg
RV5/SV1	0.922/0.754 mV
RV5 + SV1	1.676 mV

Sinus arrhythmia
Inferior infarct - age undetermined
Abnormal ECG

Unconfirmed Diagnosis



25 mm/s 10 mm/mV 50 Hz BDR 35 Hz

MAFAYAMA MSC - SARAJAPUR

02 04 00 V28 4 1

SN.FM-58003398

MR. JAGADISH SAHAI, M.D. SPECIALTY CLINIC, SARJAPUR ROAD
KANSIROD, VILL. CHESTHERI, P. A.

R

Patient Name : Mr. JAGADISH RACHALKONDA
Age : 34 Years
Referring Doctor : PKG

Patient ID : 201- 23965
Sex : male
Date : 25 .02.2023

ULTRASOUND ABDOMEN AND PELVIS

FINDINGS:

Liver is normal in size (15 cm) and shows mild diffuse increase in echogenicity. No intra or extra hepatic biliary duct dilatation. No focal lesions.

Portal vein is normal in size, course and caliber. CBD is not dilated.

Gall bladder is normal without evidence of calculi, wall thickening or pericholecystic fluid.

Pancreas to the extent visualized, appears normal in size, contour and echogenicity.

Spleen is normal in size (10.8cm), shape, contour and echopattern. No evidence of mass or focal lesions.

Right Kidney is normal in size (measures 10.5 cm in length & 2 cm in parenchymal thickness), position, shape and echopattern. Corticomedullary differentiation is maintained. No evidence of calculi or hydronephrosis.

Left Kidney is normal in size (measures 10.9 cm in length & 1.8 cm in parenchymal thickness), position, shape and echopattern. Corticomedullary differentiation is maintained. No evidence of calculi or hydronephrosis.

Retroperitoneum – Obscured by bowel gas.

Urinary Bladder is well distended. Wall thickness is normal. No evidence of calculi, mass or mural lesion.

Prostate is normal in echopattern and size, (Volume =14cc).

Fluid - There is no ascites or pleural effusion.

IMPRESSION:

- **GRADE I FATTY LIVER**



Dr. Ananthalakshmi.S
Sonologist

