



PARKLINE DIAGNOSTICS PVT. LTD.

L.G. 3, 4 & 5, Bhuvana Towers, S.D. Road, Secunderabad - 500 003.
 Tel : +91 40-2784 5852, 6649 1787, 7995421787, 7093445852, Fax : +91 40 2784 7864
 Email parklinediagnostics@gmail.com www.parklinediagnostics.com




NABL Accredited
 Certificate No.MC-2566

MEDICAL EXAMINATION REPORT

Name	Mr. G. Gnaneshwar		Date :	26/03/2022	
Company	Olo: Mediwheel		Reg. No. :	1902255	
Contact No.	9849014130		Sex	<input checked="" type="checkbox"/> M	Age : <input type="checkbox"/> 44
Type	Pre-Emp		Emp. No.:	152929	
	Overseas		Height	168 cm	
	Annual	<input checked="" type="checkbox"/>	Weight	68 kg	
Remarks	<p>FBA, c - 7.7 % Denovo DM-I.</p> <p>Advice follow up.</p> <ul style="list-style-type: none"> - Borderline hyperglycemia ⊕. Advice follow up. - Hypercholesterolemia ⊕. Advice follow up. - Rest all physical & lab parameters were 				
			<p>DR. PRIYANKA SANNIDHI MBBS Regn. No : 11351</p>		
Fitness Status	Medically Fit / Unfit		Physician's Signature		

COMPREHENSIVE MEDICAL EXAMINATION REPORT

NAME Mr. G. Gnaneshwar
 AGE 44 yrs / Male
 MARITAL STATUS Married CHILDREN : M F
 IDENTIFICATION (IF ANY) A mole on the nose.



PAST HISTORY

Any family H/o : High Blood Pressure, Heart Disease, Tuberculosis, Diabetes, Asthma, Cancer

Both parents Late father Both parents Late lung can

Any personal H/o Major illness like : Typhoid..... Nil Jaundice..... Nil Etc.

Any H/o STD..... Skin infection..... Nil

H/o Blood Transfusion..... Recent Vaccination..... COVISHIELD 2 Doses

H/o Epilepsy..... Nil Giddiness..... Nil

H/o Surgery..... Fracture in the past..... Nil

Any Personal H/O.

High Blood Pressure, Heart Disease Tuberculosis, Diabetes, Asthma, Cancer

Drug Abuse, Drug Allergy, Micturition, Bowels, Alcohol, Smoking, Sleep, MC, Wt. Loss/Wt. Gain

Present illness / Medication I. VOGLOYD No. 2 Aug.

GENERAL EXAMINATION

Conjunctiva :

Skin :

Ears :

Nose :

Throat & Oral Cavity :

Bone, Joints :

Nutritional Status :

Lymph Nodes :

Edema Feet :

Varicose Veins :

Distant Vision : Near Vision :

Right Eye: 6/6

With glasses / Without glasses

left Eye : 6/6

with glasses / without glasses

Colour Vision : DE normal

Right Ear

Hearing : (N)

Rinee's Test :

Weber Test :

Discharge : NIL

Right Eye: 6/6

With glasses / Without glasses

left Eye : 6/6

with glasses / without glasses

Ophthalmologist's Signature

Left Ear

(N)

NIL

SYSTEMIC EXAMINATION

Pulse :

B.P. :

Lungs: A. Shape of Chest 8/10 symmetrical
B. Breath Sounds B/c - clear ⊕
C. Adventitious Sounds NO

Heart : A. Sounds S1 S2 ⊕
B. Murmurs NO murmurs

Abdomen : A. Liver NPD
B. Spleen NPD
C. Piles NIL
D. Any Lump NIL

General : A. Hernia]
B. Hydrocele NAD
C. Varicocele]

Breast : Rt (N) Lt (N)

Nervous System

A. Higher Function :
B. Cranial Nerves :
C. Sensory System :
D. Motor System : (N)
E. Jerks :


DR. KATTA
M.B.B.S. D.O. F.R.C.
F.O.M.C.
KRS

CANDIDATE'S DECLARATION

I hereby solemnly declare that I am not suffering from Asthma, Hypertension, Diabetes, Occult Psychological disorders or any other ailment which can be suppressed without my voluntary declaration.

Date :

Place :



Signature

SYSTEMIC EXAMINATION

Note : General Physical Examination and Investigation included in the health check-up Have certain limitations and may not be able to detect all latent and asymptomatic diseases. Any new symptoms developing after the health check-up or persisting thereafter should be brought to the attention of the treating physician.



PARKLINE DIAGNOSTICS PVT. LTD.

L.G. 3, 4 & 5, Bhuvana Towers, S.D. Road, Secunderabad - 500 003. Tel :+91 40-2784 5852, 6649 1787, 7995421787, 7093445852, Fax : +91 40 2784 7864 Email parklinediagnostics@gmail.com www.parklinediagnostics.com



NABL Accredited
Certificate No.MC-2566

ENT CONSULTATION

S.No. 1907255 Emp.No. 157979 Date 26/03/22
 Name Mr. G. Ananeshwar Age 44 Yrs Sex M/F

EARS :

Right

Left

EAC

: patent, no cerumen.

-do-

TM

: Intact, pearly white.
Cone of light (+)

-do-

TFT

: Rinne's +ve

Rinne's +ve

Weber's - central

NOSE

: Septum (N). B: 1.5 cm, symmetric (N) - pale (N) - non-tender

THROAT

: Oropharynx (N). B: 1.5 cm, (N) - no mounds
Arytenoids (N)

NECK

: (N)

IMPRESSION:

EN or clinically NAD,

Dr. D. Hari Kumar
 MS ENT
 Head & Neck Surgeon
 Reg. No: 88872

7799686970

Name : Ganeshwal Sex : M Age : 44

Date : 26/3/22

OPD No : 532


Ca⁺⁺ Gn⁺⁺

L.p ? ist lower ant

G. recession ist lower
anterior.

Rx.

Adv. op₄.


MULTI SPECIALITY DENTAL CLINIC
Smile Confidential... Not Confidentially
B.D.S, IMPLANTOLOGIST (USA)
1-3-1, Rajamudaliar Street, Kalasiguda,
Secunderabad



PARKLINE DIAGNOSTICS PVT. LTD.

L.G 3, 4 & 5, Bhuvana Towers, Sarojini Devi Road, Secunderabad - 500 003.
Tel. +91 40 2784 5852, 6649 1787, 77995421787, 7093445852, Fax : + 91 40 2784 7864
Email : parklinediagnostics@gmail.com, www.parklinediagnostics.com



NABL Accredited
Certificate No.: MC-2566

TEST REPORT

Name : Mr . G GNANESHWAR [157979]
Age / Gender : 44 Years / Male
Ref.By : Medi Wheel
Req. No : BIL1907255

TID : UMR0752967
Registered on : 26-Mar-2022 08:23 AM
Reported On : 26-Mar-2022 01:27 PM

Ultrasound Whole Abdomen

LIVER is normal shape, size (13.8 cms) and has uniform echopattern.
No evidence of focal lesion. No intrahepatic biliary ductal dilatation.
Hepatic and portal vein radicals are normal.

GALL BLADDER shows normal shape and has clear contents.
Gall bladder wall is of normal thickness. CBD is of normal calibre.

PANCREAS has normal shape, size and uniform echopattern.
No evidence of ductal dilatation or calcification.

SPLEEN shows normal shape, size and echopattern.

KIDNEYS move well with respiration and have normal shape, size and echopattern.
Cortico- medullary differentiations are well madeout.
No evidence of calculus or hydronephrosis.
Right kidney measures 10.4 x 5.7 cms, Left kidney measures 10.3 x 6.0 cms.

URINARY BLADDER shows normal shape and wall thickness.
It has clear contents. No evidence of diverticula.


PROSTATE shows normal shape, size and echopattern.

No evidence of free fluid in the abdomen

IMPRESSION:

* No sonographic abnormality.

Suggested clinical correlation and follow up


Dr. Abid Yazden
Consultant Radiologist

The Test marked with* are not accredited by NABL

Lab Timings (Weekdays) : 7.00 am to 8.30 pm
Sundays & Holidays : 7.00 am to 1.00 pm

Radiologists Timings (Weekdays) : 7.30 am to 1.30 pm
& 5.30 pm to 7.45 pm
Sundays & Holidays : 7.30 am to 9.30 am



PARKLINE DIAGNOSTICS PVT. LTD.

L.G 3, 4 & 5, Bhuvana Towers, Sarojini Devi Road, Secunderabad - 500 003.
Tel. +91 40 2784 5852, 6649 1787, 77995421787, 7093445852, Fax : + 91 40 2784 7864
Email : parklinediagnostics@gmail.com, www.parklinediagnostics.com



NABL Accredited
Certificate No.: MC-2566

TEST REPORT

Name : Mr . G GNANESHWAR [157979]
Age / Gender : 44 Years / Male
Ref.By : Medi Wheel
Req. No : BIL1907255

TID : UMR0752967
Registered on : 26-Mar-2022 08:23 AM
Reported On : 26-Mar-2022 10:09 AM

X-RAY CHEST PA VIEW

Lung fields are clear.

Cardia is normal.

Hila are normal.


C P angles are free.

Bony cage is normal.

Soft tissues are normal.

IMPRESSION : NORMAL CHEST X-RAY




Dr. D.J. MOHAN
MD DMRD
(Reg No. 8995)
Consultant Radiologist

The Test marked with*are not accredited by NABL

Lab Timings (Weekdays) : 7.00 am to 8.30 pm
Sundays & Holidays : 7.00 am to 1.00 pm

Radiologists Timings (Weekdays) : 8.30 am to 1.30 pm
& 5.30 pm to 7.45 pm
Sundays & Holidays : 7.30 am to 9.30 am

ID: 1907255

26-03-2022 09:35:47 AM

CARDIART


MR.G.GNANESHWAR

Male 44Years

HR : 79 bpm
P : 116 ms
PR : 158 ms
QRS : 85 ms
QT/QTc : 356/409 ms
P/QRS/T : 75/67/73 °
RV5/SV1 : 1.940/0.381 mV

Diagnosis Information:
Sinus Rhythm
Normal ECG

NSR
WNL


DR. NAVIN KUMAR.C
M.D., D.M.
Consultant Cardiologist
Reg. No. 52291

Report Confirmed by:

PATIENT SUMMARY REPORT

LINE DIAGNOSTICS PVT.LTD

: 1907255
: MR.G.GNANESHWAR
/ SEX : 44 / MALE

HEIGHT (cm) : 168
WEIGHT (kg) : 68
PROTOCOL : BRUCE

REF. BY : MEDIWHEEL
DONE BY : DR.NAVEEN KUMAR C
TECHNICIAN : G.M.SURESH

022, 10:32:

EHISTORY

ICATION

ECT OF TEST

K FACTOR

IVITY

HER INVESTIGATION

ASON FOR TERMINATION

ERCISE TOLERANCE

ERCISE INDUCED ARRHYTHMIAS

AEMO RESPONSE

HRONO RESPONSE

INAL IMPRESSION

XTRA COMMENTS

Routine Check Up.

Diabetes.

Very Active.

ECG

THR ACHIEVED

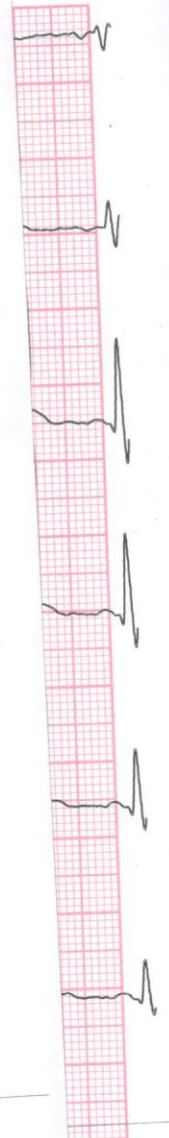
Good (> 10 METS).

No.

Normal.

Normal.

Negative for inducible ischemia



Dr. NAVEEN KUMAR .C
M.D., D.M.

Confirmed By : Consultant Cardiologist
Reg. No. 52291

Signature

Page No.: 1

BPL DYNATRAC

Tested On 26-03-2022, 10:32:36