



Shubham Imaging & ALC Diagnostic Center

ISO 9001:2015 Certified Center

(A Unit of P. K. Arogyam Health & Wellness Center)

E-95, P.C. Colony, Near Sai Netryalaya Transformer, Kankarbagh, Patna - 20

✉ : alcdiagnostics@gmail.com

🌐 : www.pkarogayamhealthcheckup.com

☎ : 7050037694, 9153988577

OPINION MUST BE CORRELATES WITH CLINICALLY & OTHER INVESTIGATION FOR FINAL DIAGNOSIS, NOT FOR MEDICO LEGAL PURPOSE


PATIENT NAME : Mrs. MONALISA

PATIENT ID : 2952

COL DATE : 09/03/2024 REPORTING DATE: 09/03/2024 AGE SEX : 30 YRS/F

REF.BY : DR. / MEDIWHEEL

TEST NAME	RESULT	Unit	REF.RANGE
BLOOD SUGAR (F)	76.0 mg/dl		70 - 110 mg/dl
BLOOD SUGAR (PP)	108.0 mg/dl		70 - 140 mg/dl
LIPID PROFILE:-			
TOTAL CHOLESTROL	241.0 mg/dl		130 -250 mg/dl
TRIGLYCERIDE	172.0 mg/dl		50 -160 mg/dl
HDL CHOLESTROL	53.0 mg/dl		30 - 60 mg/dl
LDL CHOLESTROL	153.6 mg/dl		80 -130 mg/dl
VLDL CHOLESTROL	34.4 mg/dl		15 - 40 mg/dl
T.CH./HDL RATIO	4.5 : 1		Upto 5 :1
LDL /HDL RATIO	2.8 : 1		2 - 4:1


Consultant Radiologist

ESTB BY:-

Dr. P. K. Tiwari
MD, M.Sc (Radio Imaging)
Ph.D (Art Nuclear Medicine)
Consultant Imacionologist

Dr. S. Kumar
MD, (Pat)
Consultant Pathologist

Dr. Abhishek Kumar
MBBS, MD
Consultant Neuropatho Physiologist

Dr. Kumari Suman
MBBS, DGO, MD
Consultant (TVS & HSG Specialist)

Dr. A. K. Singh
MBBS, PGDMCH
Consultant Radiologist & Sonologist

PRINTING MISTAKE SHOULD BE REPORTED BACK IMMEDIATELY / यहाँ जन्म से पहले भ्रुण का लिंग जाँच नहीं होता है।



Shubham Imaging & ALC Diagnostic Center

ISO 9001:2015 Certified Center

(A Unit of P. K. Arogyam Health & Wellness Center)

E-95, P.C. Colony, Near Sai Netryalaya Transformer, Kankarbagh, Patna - 20

✉ : alcdiagnostics@gmail.com

🌐 : www.pkarogayamhealthcheckup.com

☎ : 7050037694, 9153988577

OPINION MUST BE CORRELATES WITH CLINICALLY & OTHER INVESTIGATION FOR FINAL DIAGNOSIS. NOT FOR MEDICO LEGAL PURPOSE

ZPATIENT NAME : Mrs. MONALISA

PATIENT ID : 2952

COL DATE : 09/03/2024 REPORTING DATE: 09/03/2024 AGE SEX:- 30 YRS/F

REF.BY : DR. / MEDIWHEEL .

TEST NAME	RESULT	Unit	REF.RANGE
LFT:-			
SGPT	37.5	IU/L	5 - 40 IU/L
SGOT	27.9	IU/L	5 - 40 IU/L
ALKALINE PHOSPHATASE	97.1	IU/L	M - 53 - 165 IU/L F - 42 - 136 IU/L
TOTAL PROTIN	7.5	g/dl	6.0 - 8.7 g/dl
SERUM ALBUMIN	4.5	g/dl	3.5 - 5.4 g/dl
SERIUM GLUBLINE	3.0	g/dl	2.3 - 3.6 g/dl
AG RATIO	1.5: 1		1.0 - 2.3 g/dl
BILIRUBIN	TOTAL	0.66 mg/dl	0.1 - 1.1 mg/dl
	DIRECT	0.30 mg/dl	0.0 - 0.32 mg/dl
	INDIRECT	0.36 mg/dl	0.0 - 0.78 mg/dl
GGTP(GGT)	25.4	iu/L	8 - 38 iu/L
KFT/RFT			
URIC ACID	4.1	mg/dl	3.2 - 7.0 mg/dl
SERUM CREATNINE	1.1	mg/dl	0.6 - 1.5 mg/dl
BLOOD URIA	34.1	mg/dl	5 - 45 mg/dl
BLOOD URIA NITROZEN(BUN).	15.9	mg/dl	5 - 23 mg/dl

09/03/24
Consultant Radiologist

ESTB BY:-

Dr. P. K. Tiwari
MD, M.Sc (Radio Imaging)
Ph.D (All Nuclear Medicine)
Consultant Imagiologist

Dr. S. Kumar
MD, (Pat)
Consultant Pathologist

Dr. Abhishek Kumar
MBBS, MD
Consultant Neuropatha Physiologist

Dr. Kumari Suman
MBBS, DGO, MD
Consultant (TVS & HSG Specialist)

Dr. A. K. Singh
MBBS, PGDMCH
Consultant Radiologist & Sonologist

PRINTING MISTAKE SHOULD BE REPORTED BACK IMMEDIATELY / यहाँ जन्म से पहले धुण का लिंग जाँच नहीं होता है।



Shubham Imaging & ALC Diagnostic Center

ISO 9001:2015 Certified Center

(A Unit of P. K. Arogyam Health & Wellness Center)

E-95, P.C. Colony, Near Sai Netryalaya Transformer, Kankarbagh, Patna - 20

✉ : alcdiagnostics@gmail.com

🌐 : www.pkarogayamhealthcheckup.com

☎ : 7050037694, 9153988577

OPINION MUST BE CORRELATES WITH CLINICALLY & OTHER INVESTIGATION FOR FINAL DIAGNOSIS. NOT FOR MEDICO LEGAL PURPOSE

PATIENT NAME : Mrs. MONALISA PATIENT ID : 2952
COL DATE : 09/03/2024 REPORTING DATE: 09/03/2024 AGE SEX:- 30 YRS/F
REF.BY : DR. / MEDIWHEEL .

TEST NAME	RESULT	Unit	REF.RANGE
ESR	12 mm/hr		<20 mm/hr
CBC			
Total W.B.C. Count	7,200 /cumm		4,000 - 11,000 /cumm
R B C COUNT	4.23 Million/ CUmm		4 - 7 Million/ CUmm
Platelets count	3.43 Lakh/ cumm		1.5 - 5.0 Lakh/ cumm
Differential Count of W.B.C.			
Neutrophils	70 %		40 -70%
Lymphocytes	24 %		25 - 40%
Eosinophils	05 %		01 - 05%
Mnonocytes	01 %		00 - 02%
Basophiles	00 %		00 - 0%
HAEMOGLOBIN	112.3 gm/dl (84.2 %)		14.6 gm/dl = 100%
PCV	36.8 %		35 - 47 %
MCV	87.0 fl		76 - 96 fl
MCH	29.2 pg		29 - 35 pg
MCHC	33.5 %		30 - 38 %

AK
09/03/24

Consultant Radiologist

ESTB BY:-

Dr. P. K. Tiwari
MD, M.Sc (Radio Imaging)
Ph.D (Ab Nuclear Medicine)
Consultant Imagiologist

Dr. S. Kumar
MD, (Pat)
Consultant Pathologist

Dr. Abhishek Kumar
MBBS, MD
Consultant Neuropatho Physiologist

Dr. Kumari Suman
MBBS, DGO, MD
Consultant (TVS & HSG Specialist)

Dr. A. K. Singh
MBBS, PGDMCH
Consultant Radiologist & Sonologist

PRINTING MISTAKE SHOULD BE REPORTED BACK IMMEDIATELY / यहाँ जन्म से पहले भ्रूण का लिंग जाँच नहीं होता है।



Shubham Imaging & ALC Diagnostic Center

ISO 9001:2015 Certified Center

(A Unit of P. K. Arogyam Health & Wellness Center)

E-95, P.C. Colony, Near Sai Netryalaya Transformer, Kankarbagh, Patna - 20

✉ : alcdiagnostics@gmail.com

🌐 : www.pkarogayamhealthcheckup.com

☎ : 7050037694, 9153988577


OPINION MUST BE CORRELATES WITH CLINICALLY & OTHER INVESTIGATION FOR FINAL DIAGNOSIS. NOT FOR MEDICO LEGAL PURPOSE

PATIENT NAME : Mrs. MONALISA PATIENT ID : 2952
COL DATE : 09/03/2024 REPORTING DATE: 09/03/2024 AGE SEX : 30 YRS/F
REF.BY : DR./ MEDIWHEEL.

GLYCOSYLATED HEMOGLOBIN

TEST NAME	RESULT	Unit	REF.RANGE
HbA1c	4.2 %		Below 5.7 % : Normal 5.7 – 6.4 % : Prediabetic > = 6.5 % : Diabetic
AVERAGE PLASMA GLUCOSE	92.0 mg/dl		90 – 120 mg/dl : Good Control 121– 150 mg/dl : Fair Control 151- 180 mg/dl: Unsatisfactory Control >180 mg/dl : Poor Control

ESTB BY:-


29/03/24
Consultant Radiologist

Dr. P. K. Tiwari

MD, M.Sc (Radio Imaging)
Ph.D (Ab Nuclear Medicine)
Consultant Imaginologist

Dr. S. Kumar

MD, (Pat)
Consultant Pathologist

Dr. Abhishek Kumar

MBBS, MD
Consultant Neuropatho Physiologist

Dr. Kumari Suman

MBBS, DGO, MD
Consultant (TVS & HSG Specialist)

Dr. A. K. Singh

MBBS, PGDMCH
Consultant Radiologist & Sonologist

PRINTING MISTAKE SHOULD BE REPORTED BACK IMMEDIATELY / यहाँ जन्म से पहले धुण का लिंग जाँच नहीं होता है।



Shubham Imaging & ALC Diagnostic Center

ISO 9001:2015 Certified Center

(A Unit of P. K. Arogyam Health & Wellness Center)

E-95, P.C. Colony, Near Sai Netryalaya Transformer, Kankarbagh, Patna - 20

✉ : alcdiagnostics@gmail.com

🌐 : www.pkarogayamhealthcheckup.com

☎ : 7050037694, 9153988577

OPINION MUST BE CORRELATES WITH CLINICALLY & OTHER INVESTIGATION FOR FINAL DIAGNOSIS. NOT FOR MEDICO LEGAL PURPOSE

PATIENT NAME : Mrs. MONALISA PATIENT ID : 2952

COL DATE : 09/03/2024 REPORTING DATE: 09/03/2024 AGE SEX : 33 YRS/F

REF.BY : DR. / MEDIWHEEL.


TEST NAME	RESULT	Unit	REF.RANGE
-----------	--------	------	-----------

BLOOD GROUP : 'A'

Rh Typing : POSITIVE

Note: Do always cross – matching before blood transfusion

ESTB BY:-


Consultant Radiologist

Dr. P. K. Tiwari

MD, M.Sc (Radio Imaging)
Ph.D (AI Nuclear Medicine)
Consultant Imaginologist

Dr. S. Kumar

MD, (Pat)
Consultant Pathologist

Dr. Abhishek Kumar

MBBS, MD
Consultant Neuropatho Physiologist

Dr. Kumari Suman

MBBS, DGO, MD
Consultant (TVS & HSG Specialist)

Dr. A. K. Singh

MBBS, PGDMCH
Consultant Radiologist & Sonologist

PRINTING MISTAKE SHOULD BE REPORTED BACK IMMEDIATELY / यहाँ जन्म से पहले धुण का लिंग जाँच नहीं होता है।



Shubham Imaging & ALC Diagnostic Center

ISO 9001:2015 Certified Center

(A Unit of P. K. Arogyam Health & Wellness Center)

E-95, P.C. Colony, Near Sai Netryalaya Transformer, Kankarbagh, Patna - 20

✉ : alcdiagnostics@gmail.com

🌐 : www.pkarogayamhealthcheckup.com

☎ : 7050037694, 9153988577

OPINION MUST BE CORRELATES WITH CLINICALLY & OTHER INVESTIGATION FOR FINAL DIAGNOSIS. NOT FOR MEDICO LEGAL PURPOSE

PATIENT NAME : Mrs. MONALISA PATIENT ID: 2952
COL DATE : 09/03/2024 REPORTING DATE: 09/03/2024 AGE SEX : 30 YRS/F
REF.BY : DR. / MEDIWHEEL..

ROUTINE EXAMINATION OF URINE

PHYSICAL EXAMINATION

Quantity	20 ml	Colour....	Strow
Appearance...	Clear	Sediment ...	Nil
Specific gravity....	1.010		

CHEMICAL EXAMINATION

Reaction	6.0	Nitrite.....	Not done
Sugar	Nil	Bile Pigment ...	Not done
Albumin	Nil	Urobilinogen....	Not done
Excess of Phosphate....	Nil	Chile.....	Not done
Bile Salt	Not Done	Acetone...	Not done

MICROSCOPIC EXAMINATION

Erythrocytes....	Nil	Casts	Nil
Leucocytes	1-4 / HPE	Crystals....	Nil
Epith. Cell	A, Few	Others	Nil

ESTB BY:-


Consultant Radiologist

Dr. P. K. Tiwari
MD, M.Sc (Radio Imaging)
Ph.D (AI Nuclear Medicine)
Consultant Imaginologist

Dr. S. Kumar
MD, (Pat)
Consultant Pathologist

Dr. Abhishek Kumar
MBBS, MD
Consultant Neuropatho Physiologist

Dr. Kumari Suman
MBBS, DGO, MD
Consultant (TVS & HSG Specialist)

Dr. A. K. Singh
MBBS, PGDMCH
Consultant Radiologist & Sonologist

PRINTING MISTAKE SHOULD BE REPORTED BACK IMMEDIATELY / यहाँ जन्म से पहले भ्रुण का लिंग जांच नहीं होता है।



Shubham Imaging & ALC Diagnostic Center

ISO 9001:2015 Certified Center

(A Unit of P. K. Arogyam Health & Wellness Center)

E-95, P.C. Colony, Near Sai Netryalaya Transformer, Kankarbagh, Patna - 20

✉ : alcdiagnostics@gmail.com

🌐 : www.pkarogyamhealthcheckup.com

☎ : 7050037694, 9153988577

OPINION MUST BE CORRELATES WITH CLINICALLY & OTHER INVESTIGATION FOR FINAL DIAGNOSIS. NOT FOR MEDICO LEGAL PURPOSE

PATIENT NAME : Mrs. MONALISA

PATIENT ID: 2952

COL DATE : 09/03/2024 REPORTING DATE: 09/03/2024 AGE SEX : 30 YRS/F

REF.BY : DR. / MEDIWHEEL.

Investigation	Result	Normal Range
Total Triiodothyronin T3	1.41 ng/mL	0.80 - 2.00 µ ng/mL
Total Thyroxin T4	10.22 ug/mL	5.10 - 14.10 ug/dL
Serum TSH	3.57 µg/mL	0.27 - 4.20 µg/mL

THYROID DISORDER (>: Increase: < Decrease: n Normal


1. T3(n) T4(n) TSH(n) :EUTHYROID STATE:
2. T3(>) T4(>) TSH(<): HYPERTHYROIDISM:
3. T3(<)T4(<) TSH(>): HYPOTHYROIDISM:
4. T3(n)T4(n) TSH(>) : SUB-CLINICAL HYPO-THYROIDISM:
5. T3(n)T4(n) TSH(<): SUB-CLINICAL HYPER-THYROIDISM:
6. T3(>) T4(n) TSH(<): T3 THYROTOXICOSIS:

Total T3/T4 level is dependent on Level:

So determination of free T3/T4is a better MARKER of Thyroid Function.

*FREE T3/T4 ESTIMATION FACILITY IS AVAILABALE ON REQUEST.:

ESTB BY:-


Consultant Radiologist

Dr. P. K. Tiwari

MD, M.Sc (Radio Imaging)
Ph.D (Art Nuclear Medicine)
Consultant Imagonologist

Dr. S. Kumar

MD, (Pat)
Consultant Pathologist

Dr. Abhishek Kumar

MBBS, MD
Consultant Neuropatho Physiologist

Dr. Kumari Suman

MBBS, DGO, MD
Consultant (TVS & HSG Specialist)

Dr. A. K. Singh

MBBS, PGDMCH
Consultant Radiologist & Sonologist

PRINTING MISTAKE SHOULD BE REPORTED BACK IMMEDIATELY / यहाँ जन्म से पहले भ्रुण का लिंग जाँच नहीं होता है।



Shubham Imaging & ALC Diagnostic Center

ISO 9001:2015 Certified Center

(A Unit of P. K. Arogyam Health & Wellness Center)

E-95, P.C. Colony, Near Sai Netryalaya Transformer, Kankarbagh, Patna - 20

✉ : alcdiagnostics@gmail.com

🌐 : www.pkarogyamhealthcheckup.com

☎ : 7050037694, 9153988577

OPINION MUST BE CORRELATES WITH CLINICALLY & OTHER INVESTIGATION FOR FINAL DIAGNOSIS. NOT FOR MEDICO LEGAL PURPOSE

ECHOCARDIOGRAPHY & COLOR DOPPLER REPORT

Patient's Name : Mrs. MONALISHA

Age/Sex : 30 Yrs /F

Ref. by : DR./ MEDIWHEEL

Date : 9-Mar-24

ECHOCARDIOGRAPHIC WINDOW: Fair

2D & M MODE ECHOCARDIOGRAPHY

Left ventricle

EDD: 26	mm (20 - 28 mm / m ²)	ESD: 18	mm(13 - 21 mm /m ²)
IVS : 9	mm (6 - 11 mm)	PW: 8	mm (6 - 11 mm)
Ejection fraction:	60% (61 ± 8%)	FS: 42	% (34 - 44 %)
IVS: Intact		LV clot	Absent

Left atrium/ Aorta 35/31 mm

Right ventricle Normal

Right atrium Normal

Pericardium Normal with no pericardial effusion

2D:

Normal LA/LV Size and normally contracting left ventricle. No RWMA, concentric LVH

Mitral valve

AML/ PML: Normal

Tricuspid valve Normal

Aortic valve Normal

Pulmonary valve Normal

Continuous & Pulse Wave Doppler study

Valve	Velocity (m/sec)			Gradient (mmHg)			Valve area (PHT Method)	Regurg.
	Peak	Mean	EDV	Peak	Mean	EDG		
Mitral	E=07 A=0.6			2.3	2.0			Nil
Tricuspid	E=0.5 A=0.3			1.9	0.2			Nil
Aortic	1.12			5.0	2.5			Nil
Pulmonary	0.9			3.5	1.7			Nil

ESTB BY:-

Consultant Radiologist

Dr. P. K. Tiwari

MD, M.Sc (Radio Imaging)
Ph.D (Alt Nuclear Medicine)
Consultant Imaginologist

Dr. S. Kumar

MD, (Pat)
Consultant Pathologist

Dr. Abhishek Kumar

MBBS, MD
Consultant Neuropatho Physiologist

Dr. Kumari Suman

MBBS, DGO, MD
Consultant (TVS & HSG Specialist)

Dr. A. K. Singh

MBBS, PGDMCH
Consultant Radiologist & Sonologist

PRINTING MISTAKE SHOULD BE REPORTED BACK IMMEDIATELY / यहाँ जन्म से पहले भ्रूण का लिंग जाँच नहीं होता है।



Shubham Imaging & ALC Diagnostic Center

ISO 9001:2015 Certified Center

(A Unit of P. K. Arogyam Health & Wellness Center)

E-95, P.C. Colony, Near Sai Netryalaya Transformer, Kankarbagh, Patna - 20

✉ : alcdiagnostics@gmail.com

🌐 : www.pkarogyamhealthcheckup.com

☎ : 7050037694, 9153988577

OPINION MUST BE CORRELATES WITH CLINICALLY & OTHER INVESTIGATION FOR FINAL DIAGNOSIS. NOT FOR MEDICO LEGAL PURPOSE

Colour Flow Imaging

No TR, No MR/PR, No AR

No flow shunt

COMMENTS :

- ◆ Normal size all chamber
- ◆ Normal LV filling Pressure
- ◆ No RWMA
- ◆ Normal LV systolic function
- ◆ Grade I LV diastolic dysfunction.
- ◆ Global LVEF = 60%
- ◆ All cardiac valves are normal
- ◆ No PAH, Mild concentric LVH
- ◆ No MS / TS / AS / PS / PR
- ◆ No clot / vegetation / pericardial effusion.

IMPRESSION:

All chambers are normal

No RWMA, No PAH

Grade I LV diastolic dysfunction.

Normal LV systolic function, LVEF – 65%

Please correlate clinically

DR. SANDEEP KUMAR MBBS MD

ESTB BY:-

Consultant Radiologist

Dr. P. K. Tiwari

MD, M.Sc (Radio Imaging)
Ph.D (Ab Nuclear Medicine)
Consultant Imagiologist

Dr. S. Kumar

MD, (Pat)
Consultant Pathologist

Dr. Abhishek Kumar

MBBS, MD
Consultant Neuropatho Physiologist

Dr. Kumari Suman

MBBS, DGO, MD
Consultant (TVS & HSG Specialist)

Dr. A. K. Singh

MBBS, PGDMCH
Consultant Radiologist & Sonologist

PRINTING MISTAKE SHOULD BE REPORTED BACK IMMEDIATELY / यहाँ जन्म से पहले भ्रूण का लिंग जांच नहीं होता है।



Shubham Imaging & ALC Diagnostic Center

ISO 9001:2015 Certified Center

(A Unit of P. K. Arogyam Health & Wellness Center)

E-95, P.C. Colony, Near Sai Netryalaya Transformer, Kankarbagh, Patna - 20

✉ : alcdiagnostics@gmail.com

🌐 : www.pkarogyamhealthcheckup.com

☎ : 7050037694, 9153988577

OPINION MUST BE CORRELATES WITH CLINICALLY & OTHER INVESTIGATION FOR FINAL DIAGNOSIS. NOT FOR MEDICO LEGAL PURPOSE

Pt. Name :- MONALISHA

Ref. By :- DR./MEDIWHEEL

Date:- 9-Mar-24

Age / Sex -30 Yrs. F.

REAL TIME U.S.G. OF WHOLE ABDOMEN

Thanks for your kind referral

(Report.)

- LIVER** :- Measures 13.58 cm. Normal in shape, size and echo texture. I.H.B.R. are not dilated. Hepatic veins are normal. No SOL seen.
- G.BL.** :- Lumen is echo free. Wall thickness appears normal.
- C.B.D.** :- Measures 3.3 mm in diameter with echo free lumen. No calculi or mass seen.
- P.V.** :- Measures 7.2 mm in diameter. Appears normal. No thrombus seen.
- PANCREAS** :- Normal in shape, size and echo texture. No calcification mass seen.
- SPLEEN** :- Measures 10.50 cm. Normal in shape, size and echo texture. No SOL seen.
- KIDNEY** :- Both kidney shows normal shape, size & echotexture. C.M.D.intact. P.C.S. are not dilated. No calculi, cyst or hydronephrosis seen on either side.
Right Kidney :- Measures 10.13 X 4.50 cm.
Left Kidney :- Measures 9.35 X 4.25 cm.
- URETER** :- Not dilated. No apparent calculi seen.
- U.BLADDER** :- Shows normal in outline with echo free lumen. No calculi or mass seen.
Pre void - 340 ml. Post void - is in significant
- UTERUS** :- Is normal in size, shape & Anteverted in position measuring 7.57 X 4.46 cm. Endometrial And Myometeriam appears normal in limits No focal mass lesion seen.
- ADNEXA** :- Both ovary appears normal in size and shape.
Rt Ovary Measures - 1.97 cm Lt Ovary Measures 2.04 cm
- P.O.D** :- No collection seen in P.O.D.
- R.I.F.** :- Son graphically no appendicular mass or collection seen.
- OTHERS** :- No Ascites. no Lymph Adenopathy. No pleural effusion seen on either side.

IMPRESSION

- **Son graphically normal scan no detectable lesion seen.**
Otherwise son graphically normal scan. of rest organs

ESTB BY:-

Dr. P. K. Tiwari
MD, M.Sc (Radio Imaging)
Ph.D (AI Nuclear Medicine)
Consultant Radiologist

Dr. S. Kumar
MD, (Pat)
Consultant Pathologist

Dr. Abhishek Kumar
MBBS, MD
Consultant Neuropatho Physiologist

Dr. Kumari Suman
MBBS, DGO, MD
Consultant (TVS & HSG Specialist)

Dr. A. K. Singh
MBBS, PGDMCH
Consultant Radiologist & Sonologist

Consultant Radiologist

Handwritten signature and date: 9/3/24

PRINTING MISTAKE SHOULD BE REPORTED BACK IMMEDIATELY / यहाँ जन्म से पहले भ्रूण का लिंग जाँच नहीं होता है।

Pt. Name :- MONALISHA
Ref. By :- DR./MEDIWHEEL

Date:- 9-Mar-24
Age / Sex -30 Yrs. F.

Thanks for your kind referral

X-RAY CHEST (P.A.VIEW)

The lungs on the either side show equal translucency.

The peripheral pulmonary vasculature is normal.

No focal lung lesion is seen.

The pleural spaces are normal.

Both hila are normal in size, have equal density and bear normal relationship.

The heart and trachea are central in position and no mediastinal abnormality is visible.

The cardiac size is normal.

The domes of the diaphragms are normal in position, and show smooth outline.

IMPRESSION

- NO EVIDENCE OF PULMONARY OR CARDIAC PATHOLOGY IS NOTED.

Le
 9/3/24

Consultant Radiologist

ESTB BY:-

Dr. P. K. Tiwari

MD, M.Sc (Radio Imaging)
 Ph.D (Alt Nuclear Medicine)
 Consultant Imagonologist

Dr. S. Kumar

MD, (Pat)
 Consultant Pathologist

Dr. Abhishek Kumar

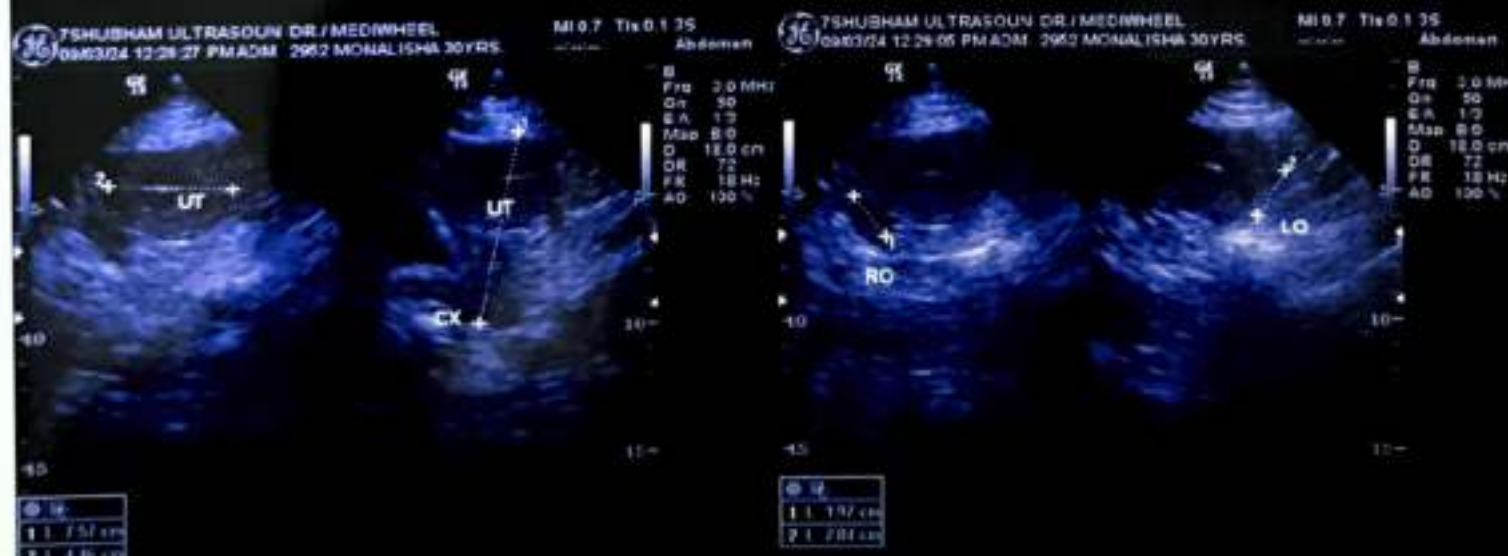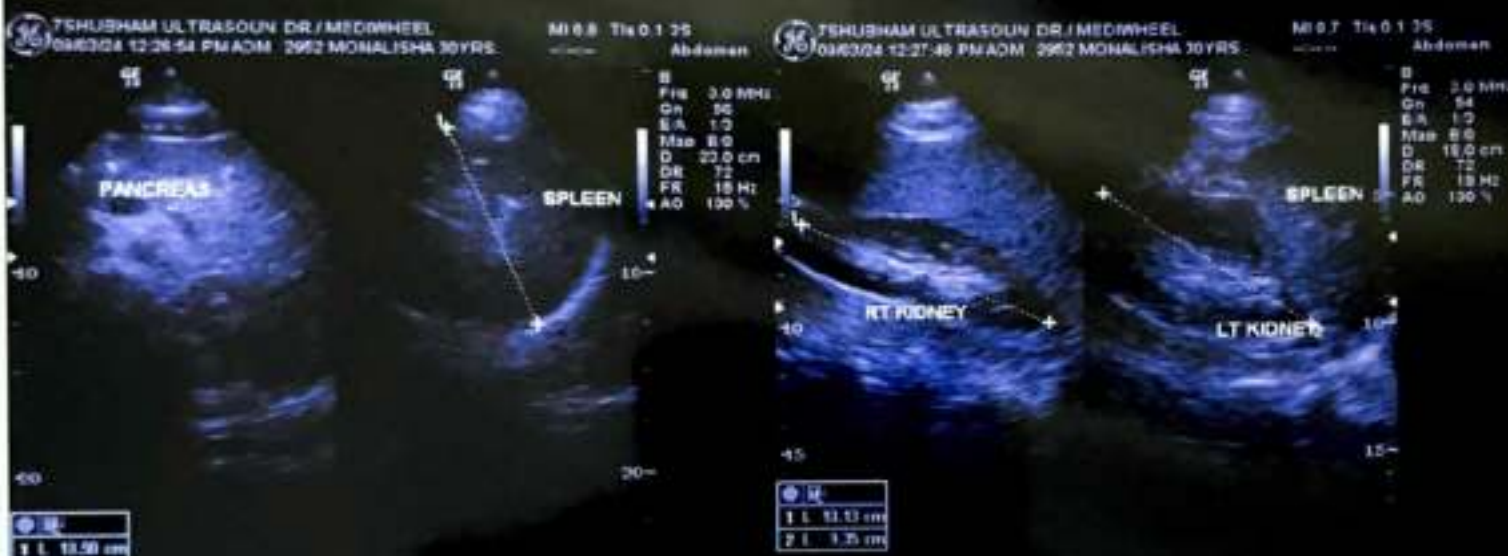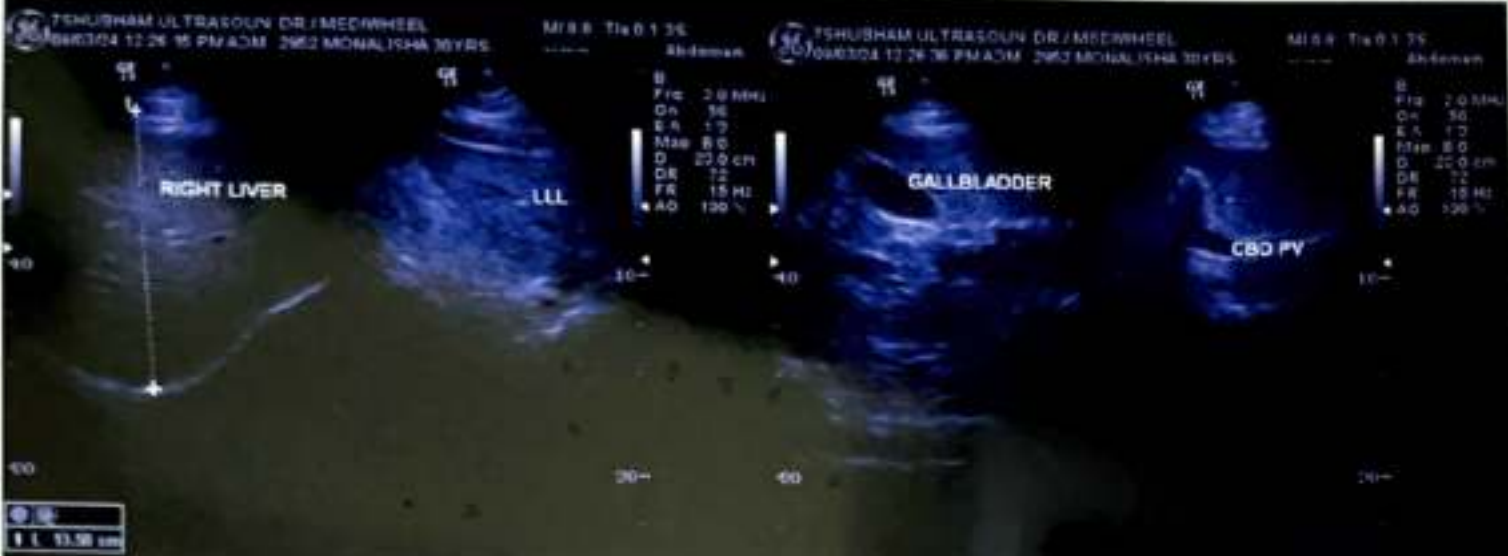MBBS, MD
 Consultant Neuropatho Physiologist

Dr. Kumari Suman

MBBS, DGO, MD
 Consultant (TVS & HSG Specialist)

Dr. A. K. Singh

MBBS, PGDMCH
 Consultant Radiologist & Sanologist



DR./ MEDIWHEEL 2952 MONALISHA 30YRS.

09-Mar-24

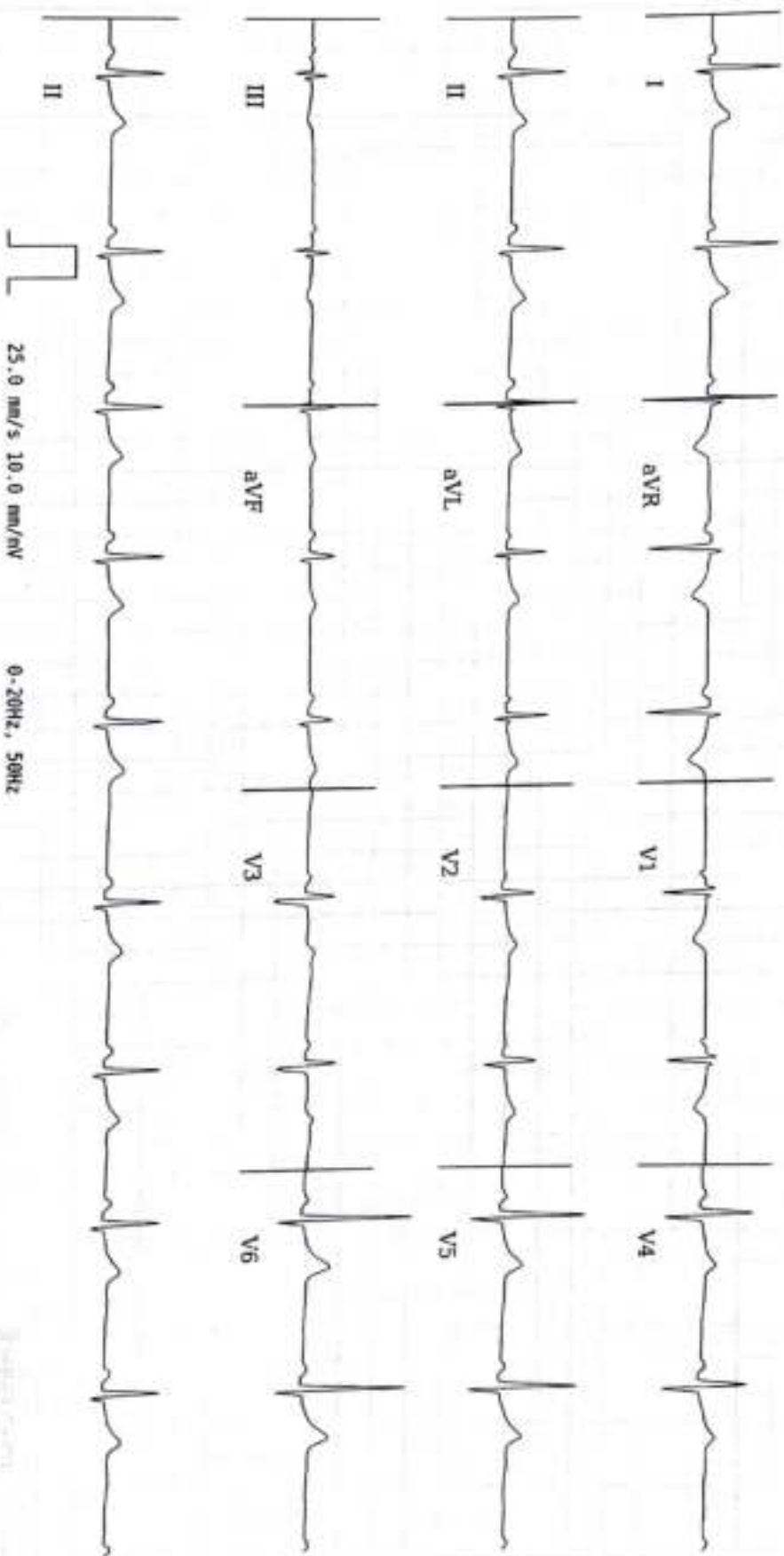


Department of Pathology
& Microbiology

PK AROGYAM

Date and Time: 9th Mar 24 12:01 PM

Age / Gender: 30/Female
Patient ID: 2952
Patient Name: Monalisa



AR: 57bpm

VR: 58bpm

QRSD: 84ms

QT: 420ms

QTcB: 412.94ms

PRI: 138ms

P-R-T: 40° 23° 23°

Sinus Bradycardia. rsr' Pattern in V1. Please correlate clinically.