



बैंक ऑफ बरोडा
Bank of Baroda



नाम
Name: **DEVENDRA KUMAR**

कार्यकारी कुट क्र.
E. C. No. **85321**

पद
DSGN: **Business Associate**

Handwritten signature



Handwritten signature: Devendra Kumar

होल्डर का हस्ताक्षर
Signature of Holder

कार्यकारी अधिकारी, एन. ए. डी. ए-III, नई दिल्ली
Issuing Authority AGM, CRM, DMR-II, N.D.

MALIK RADIX HEALTH CARE PVT. LTD.
C-217, C-218, Nirman Vihar,
Delhi-110092
Ph.: 011-49287456, 011-61381379
Regd. No. 607

Handwritten notes:
Devendra Kumar
~~kumardevendra2@bob.com~~
devendra1989@gmail.com
kumar.devendra2@bob.com



PHYSICAL EXAMINATION REPORT

NAME: *Mr. Devendra Kumar* AGE/GENDER: *34yrs/Male* DATE *23/12/23*

HEIGHT	<i>173 cm</i>
WEIGHT	<i>88 kg</i>
BMI	<i>29.4</i>
BLOOD PRESSURE	<i>130/80 mmHg</i>
OTHER	<i>NAD, Physically Fit & Healthy</i>

Devendra Kumar

[Signature]
 Dr. SHEIKH WAZIR AHMED
 M.D. "Physician"
 PGDCC
 DMC-46499

MALIK RADIX HEALTH CARE PVT. LTD.
 C-217, C-218, Nirman Vihar
 Delhi-110092
 Ph.: 011-49287456, 011-011-51579
 Regd. No. 607

Facilities Available

- Multispeciality Hospital - 24 Hours Emergency - X-Ray/ ECG/ Ultrasound/ CT Scan - Dental - Fully Equipped Operation Theatre
- Fully Functional Lab - 24/7 Casualty/ ICU-Nursery 24/7 Pharmacy - Labour Room - All Speciality OPD - Laproscopic Surgery - ECHO - Plastic Surgery

MALIK RADIX HEALTHCARE PVT LTD

UNI-EMC-217/218 NIRMAN VIHAR VIKAS MARG

DELHI 110092

DEVENDRA KUMAR

I.D. : 2687

AGE/SEX : 34 Yr / M

HT/WT : /

DATE : 23-12-2023 01:40:38 PM

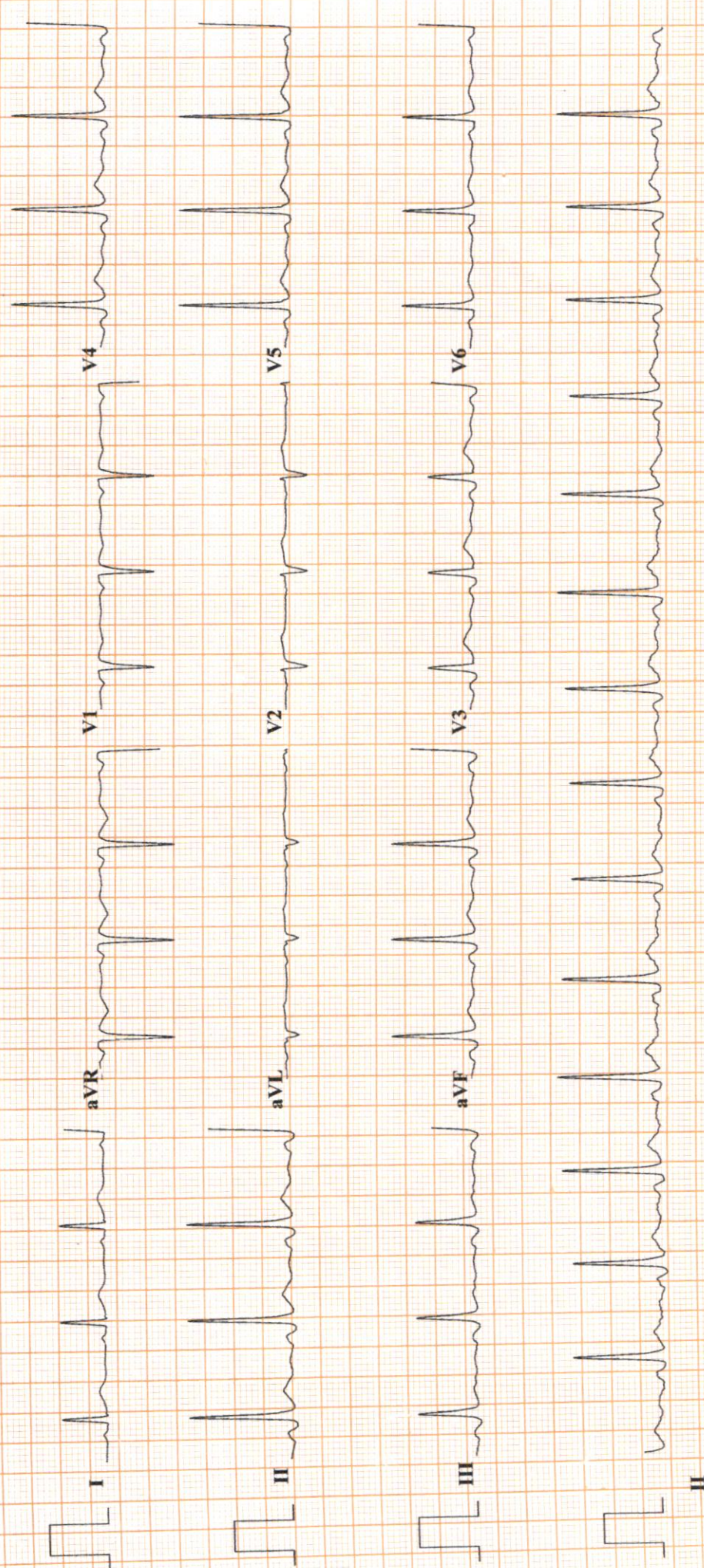
REF BY : Dr.

MACHINE INTERPRETATION : Normal ECG.

RATE : 94 bpm
BP : N/A
P Axis : 73 deg.
QRS Axis : 67 deg.
T Axis : 61 deg.

P Duration : 106 ms
PR Duration : 129 ms
QRS Duration : 73 ms
QT Interval : 307 ms
QTc Interval : 360 ms

Linked Median
Speed : 25 mm/s
Sensitivity : 10 mm/mV



Imp:- Normal ECG.

Dr. SHEIKH NAZAR AHMED
M.D. "Physician"
PGDCC

DMC-46499

Dr.

MALIK RADIX HEALTHCARE PVT. LTD.
 C-217, 218, VIKAS MARG, NIRMAN VIHAR, DELHI-110092
 PHONE NO- 011-22011192 /96

DEVENDRA KUMAR
 ID : 2248
 DATE : 23-12-2023
 AGE/SEX : 34 / M
 HT/WT : 0 / 0
 REF. BY :

TREADMILL TEST REPORT
 PROTOCOL : Bruce
 HISTORY :
 INDICATION :
 MEDICATION :

PHASE	TOTAL TIME	STAGE TIME	SPEED Km/Hr	GRADE %	H.R. bpm	B.P. mmHg	RPP x100	ST LEVEL(MM)			METS
								II	V1	V5	
SUPINE					87	130 / 80	113	1.2	-0.3		0.9
STANDING					94	130 / 80	122	1.2	-0.3		0.9
HYPERVENT					75	130 / 80	97	1.1	-0.3		0.9
Stage 1	2:55	0:8	2.7	10	132	134 / 80	176	2.7	-0.9		1.1
Stage 2	5:55	2:55	4	12	160	138 / 82	220	0.5	0		0.5
PK-EXERCISE	8:7	2:7	5.4	14	178	140 / 88	249	0.4	-0.2		0.5
RECOVERY	11:10	2:55			118	140 / 88	165	1.6	-0.5		0.7
RECOVERY	11:10	2:55			118	140 / 88	165	1.6	-0.5		0.7
RECOVERY	14:10	5:55			114	138 / 86	157	1.2	-0.2		0.7
RECOVERY	14:10	5:55			114	138 / 86	157	1.2	-0.2		0.7

RESULTS

EXERCISE DURATION : 8:7
 MAX HEART RATE : 178 bpm
 MAX BLOOD PRESSURE : 140 / 88 mm Hg
 REASON OF TERMINATION : **THR Achieved.**

MAX WORK LOAD : 9.15 METS

BP RESPONSE : **(R)**
 ARRHYTHMIA : **(R) None,**
 H.R. RESPONSE : **(R)**

IMPRESSIONS

TMT is Negative for provokable myocardial ischemia.

Dr. SHEKH AZIZ AHMED
 M.D. "Physician"
 PGDCC
 DMC-46499

Technician :




Echocardiogram Report

Patient Name	MR. DEVENDRA KUMAR
Date of Test	23/12/2023
Age	34 YRS/ MALE
Ref. by	MEDIWHEEL

Dimensions	Result	Normal Range
AO (ed)	2.8 cm	(2.1 -3.7cm)
LA (es)	3.1 cm	(2.1 -3.7cm)
RVID (ed)	2.8 cm	(1.1-3.0cm)
LVID (ed)	4.2 cm	(3.6 – 5.5 cm)
LVID (es)	2.9 cm	(2.3-3.9cm)
IVS (ed)	1.1 cm	(0.6 – 1-2 cm)
LVPW (ed)	1.1 cm	(0.6 – 1-2 cm)
EF	60 %	
FS	30 %	(28 % - 42 %)

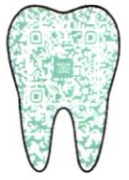Impression:

- NO REGIONAL WALL MOTION ABNORMALITY SEEN
- LVEF= 60 %
- NORMAL CHAMBER DIMENSIONS.
- NORMAL MIP.
- NORMAL COLOR FLOW.
- NO INTRA CARDIAC CLOT/MASS/ VEGETATION/PERICARDIAL EFFUSION SEEN.


Dr. Sheikh Nazir Ahmed
 M.D. "Physician" PGDCC
 (Consultant Non – Invasive Cardiologist)

Facilities Available

- Multispeciality Hospital - 24 Hours Emergency - X-Ray/ ECG/ Ultrasound/ CT Scan - Dental - Fully Equipped Operation Theatre
 - Fully Functional Lab - 24/7 Casualty/ ICU-Nursery 24/7 Pharmacy - Labour Room - All Speciality OPD - Laproscopic Surgery -
 ECHO - Plastic Surgery



CONSULTANTS ON PANEL

PAEDIATRICS

Dr Ravi Malik (MBBS, MD)
Dr Harit Prasad (MBBS, MD, Pdi)
Dr Ritu Jain (MBBS, MD)

GYNAECOLOGY

Dr Renu Malik (MBBS, MD)
Dr Meena Malhotra (MBBS, MD)
Dr Rajini (MBBS, MD)
Dr Manju Gupta (MBBS, MS)
Dr Vaishali Saini (MBBS, DGO)
Dr Rupam Arora (MBBS, MD)

DENTAL

Dr Shruti Malik (BDS, MDS)
Dr Annu Saini (BDS, MDS)
Dr Rachit Thukral (BDS, MDS)
Dr Mohit Mangla (BDS, MDS)
Dr Tarun Mittal (BDS, MDS)
Dr Geetika Sharma (BDS)
Dr Shilpa Verma (BDS)

CHILD GASTROENTROLOGY

Dr S. K Mittal (MBBS, MD)

MEDICINE

Dr A S Talwar (MBBS, MD)
Dr Sunny Uppal (MBBS, MD)
Dr Surendra Rajpal (MBBS, MD)

RESPIRATORY MEDICINE /PULMONOLOGY

Dr Abhinav Bhanot (MBBS, DNB)

LAPAROSCOPY SURGERY

Dr Ajay Jain (MBBS, MS)
Dr Deepak Saran (MBBS, MS)
Dr Pradeep Saini (MBBS, MS)
Dr G. S Garg (MBBS, MS)

ORTHOPAEDICS

Dr Vikas Bhardwaj (MBBS, MS ORTHO, DNB)
Dr Prabhak Aggarwal (MBBS, MS ORTHO)
Dr KB Tiwari (MBBS, MS ORTHO)
Dr Deepak Kumar Arora (MBBS, MS ORTHO)

EYE/OPTHALMOLOGY

Dr Nidhi Gupta (MBBS, MS, DNB, PGDM)
Dr Himanshu Singh Pundir (MBBS, MS)

ENT

Dr Sharad Kumar Singhi (MBBS, MS)
Dr Prateek Sharma (MBBS, MS)
Dr Ashok Singh (MBBS, MS)
Dr A K Lahiri (MBBS, MS)

RADIOLOGY(ULTRASOUND)

Dr K K Sinha (MBBS DNRB)
Dr T K Vohra (MBBS, MD)
Dr Rajesh Malhotra (MBBS, MD)
Dr Ashish Tomar (MBBS, MD)

PATHOLOGY

Dr Reema Dahiya (MBBS, MD PATH)
Dr Meenu Aggarwal (MBBS, MD PATH)

ANAESTHESIA

Dr Rajesh Dhall (MBBS, MD)
Dr Rakesh Atrey (MBBS, MD)
Dr R K Arora (MBBS, MD)
Dr Swaraj Garg (MBBS, MD)

DERMATOLOGY

Dr Niharika Jha (MBBS, MD)

PLASTIC & COSMETIC SURGERY

Dr Ayush Jain (MBBS, MS, MCh)

PAEDIATRIC SURGERY

Dr Dharmendra Singh (MBBS, MS, M.Ch)
Dr Satish Aggarwal (MBBS, MS, M.Ch)

PAEDIATRIC NEPHROLOGY

Dr A S Vasudev (MD, Dip.in. Paed.)

NEPHROLOGY

Dr Javed (MBBS, MD, Nephro)

CARDIOLOGY

Dr Nishant Tyagi (MBBS, MD)

NEUROLOGY

Dr Amit Batra (MBBS, MD)

GASTROENTROLOGY

Dr Deepak Lahoti (MBBS, MD)
Dr Naresh Aggarwal (MBBS, MD)
Dr Ashok Goyal (MBBS, MD)
Dr Ankur Singhal (MBBS, MD)

UROLOGY

Dr Nikhil Sharma (MBBS, Mch)
Dr Ankur Singhal (MBBS, MD)

PSYCHIATRY

Dr Mohit Sharma (MBBS, MD)

PHYSIOTHERAPY

Dr Kirti Dwivedi

NUTRITIONIST

Dr Ravi Kumar
Dr Deepika Kohli
Dr Sakshi Rana

CLINICAL PSYCHOLOGIST

Dr. Sarika Singh

Dr. Shruti Malik

BDS, MDS (Endodontics)

(+91-9899561092)

**Timings : 10:00 am. to 2:00 pm.
6:00 pm. to 8:30 pm.**

Name : Devender Kumar

Age/Sex : 34 y / M

Date : 29/12/23

For Appointment

**011-45152510
+91-9999254639**

CLINICAL EXAMINATION:-

1. TMJ:-

Routine Checkup

2. DENTAL STATUS:

M.H + NOT Relevant

- a. Caries Teeth :
- b. Fracture Teeth :
- c. Root Stumps : 0/2
- d. Gingivitis :
- e. Periodontitis :
- f. Impacted Teeth :
- g. Malaligned Teeth :

Calculus +

stains +

← Gen. Attention Out.

3. ORAL LESIONS:-

Adv.

4. DIAGNOSIS:-

- P-kit

5. TREATMENT PLANNING:

- Night Guard

6. FOLLOW UP:-

Referral To Other Consultant: Yes/ No

If Yes, please mention the Name:

Good

Doctor's Signature

Facilities Available :

- ★ MULTI-SPECIALITY HOSPITAL ★ MODULAR FULLY EQUIPPED OT ★ NURSERY ★ LAPROSCOPIC SURGERY
- ★ 24X7 EMERGENCY ★ OPG ★ DENTAL ★ 24X7 DIAGNOSTICS ★ LABOUR ROOM ★ ECHO ★ EEG ★ DIGITAL X-RAY ★ CT SCAN
- ★ ECG ★ ULTRASOUND ★ RICU/ICU ★ ALL SPECIALITY OPD ★ PLASTIC & COSMETIC SURGERY ★ DIALYSIS ★ PHARMACY



23/12/23

Mr. Devendra Kumar
Age - 34 yrs / Male

Radix Card

8/9 e/p
8/9 e/p

Member No
NSB

Color Ur.
HNL
LNL

Hepatology

- 9 hyperal
 (PS)

Dr. Nidhi Gupta
MBBS, MS, DNB
Casualty Ophthalmologist
Malik Radix Healthcare Pvt. Ltd.
DMC No. 121661

Facilities Available

- Multispeciality Hospital - 24 Hours Emergency - X-Ray/ ECG/ Ultrasound/ CT Scan - Dental - Fully Equipped Operation Theatre
- Fully Functional Lab - 24/7 Casualty/ ICU-Nursery 24/7 Pharmacy - Labour Room - All Speciality OPD - Laproscopic Surgery - ECHO - Plastic Surgery

RADIX
HEALTH
care



Malik Radix Healthcare

C/217, C/218, Vikas Marg, Nirman Vihar, New Delhi, Delhi 110092

A Unit of Malik Radix Healthcare

Toll Free - 1800-120-5457

Whatsapp No - 9811550650

E-mail: info@radixhealthcare.org

Website: www.radixhealthcare.org

Mr. Devendra Kumar
Age - 34 yrs / M

23/12/23

3/4 ear
throat
nose } wall

new treatment required

Ashok
23/12/23

DR. ASHOK SINGH

MBBS, MS (ENT)

Senior ENT & Head

Neck Skull Base Surgeon

Regn. No. DMC - 26962

MALIK RADIX HEALTHCARE PVT. LTD.

Facilities Available

- Multispeciality Hospital - 24 Hours Emergency - X-Ray/ ECG/ Ultrasound/ CT Scan - Dental - Fully Equipped Operation Theatre
- Fully Functional Lab - 24/7 Casualty/ ICU-Nursery 24/7 Pharmacy - Labour Room - All Speciality OPD - Laproscopic Surgery - ECHO - Plastic Surgery



LAB REPORT

Reg. Date	23/12/2023	Patient Id	2312230007	DOB.	
Name	MR. DEVENDRA KUMAR	Gender	M	Perm. ID	
Age	34 Yrs.	Panel	MEDIWHEEL	Reported	23/12/2023 17:03:07
Ref. By	MEDIWHEEL				

Test Name	Result	Units	Ref. Range
MEDIWHEEL ANNUAL PLUS			
<u>HAEMATOLOGY</u>			
<u>COMPLETE HAEMOGRAM</u>			
HAEMOGLOBIN (HB%)	14.9	gm/dl	13 - 18
TOTAL LEUCOCYTE COUNT (TLC)	8,100	/cumm	4000 - 11000
<u>DIFFERENTIAL LEUCOCYTE COUNT (DLC)</u>			
NEUTROPHIL	59	%	40 - 80
LYMPHOCYTE	34	%	28 - 55
MONOCYTE	04	%	02 - 10
EOSINOPHIL	03	%	01 - 06
BASOPHIL	00	%	0 - 0
ESR (WESTEGREN'S METHOD)	10	mm/1st hr.	0 - 10
R B C COUNT	5.33	Millions/cmm	4.247 - 5.4
P.C.V / HAEMATOCRIT	47.2	%	40 - 54
M C V	88.6	fl.	80 - 100
M C H	28.0	Picogram	27.0 - 31.0
M C H C	31.6	gm/dl	33 - 37
PLATELET COUNT	2.34	Lakh/cu mm	1.50 - 4.50
BLOOD GROUP ABO	" B "		
RH TYPING	Positive		
BLOOD SUGAR FASTING	88.31	mg/dl	70 - 100
BLOOD SUGAR PP	111.94	mg/dl	90 - 140
<u>THYROID PROFILE</u>			
Free T3 ELFA	2.94	ng/ml	02 - 04
Free T4 ELFA	1.10	ug/dl	0.8 - 2.7

Checked by : _____
Page 1 Contd...2

If test results are alarming or unexpected, patient is advised to contact the laboratory immediately for possible remedial action.

Facilities Available

- Multispeciality Hospital - 24 Hours Emergency - X-Ray/ ECG/ Ultrasound/ CT Scan - Dental- Fully Equipped Operation Theatre
- Fully Functional Lab - 24/7 Casualty/ ICU-Nursery 24/7 Pharmacy - Labour Room - All Speciality OPD - Laproscopic Surgery - ECHO - Plastic Surgery



LAB REPORT

Reg. Date	23/12/2023	Patient Id	2312230007	DOB.	
Name	MR. DEVENDRA KUMAR	Gender	M	Perm. ID	
Age	34 Yrs.	Panel	MEDIWHEEL	Reported	23/12/2023 17:03:07
Ref. By	MEDIWHEEL				

Test Name	Result	Units	Ref. Range
TSH Serum/ELFA	1.270	uIU/ml	0.25 - 5.50 uIU/ml

Interpretation

Clinical Use

- Diagnose Hypothyroidism and Hyperthyroidism
- Monitor T4 replacement or T4 suppressive Therapy
- Quantify TSH levels in the subnormal range

Increased Levels : Primary Hypothyroidism Subclinical Hypothyroidism, TSH dependent, Thyroid Hormone Resistance.

Decreased Levels : Grave's Disease, Autonomous Thyroid Hormone Secretion, TSH Deficiency

LIPID PROFILE

TOTAL CHOLESTEROL	175.00	mg/dL	130.0 - 200.0 (<200)
TRIGLYCERIDES	130.50	mg/dL	80.5 - 150.0 (<150)
H D L CHOLESTEROL DIRECT	36.41	mg/dL	35.0 - 60.0 (<40->59)
V L D L	26.1	mg/dL	4.0 - 30. (23-45)
L D L CHOLESTEROL	112.5	mg/dL	50.0 - 150.0 (50-150)
TOTAL CHOLESTEROL / HDL RATIO	4.8		3.3 - 5.1
LDL / HDL CHOLESTEROL RATIO	3.1		1.5 - 3.5

LIVER FUNCTION TEST (LFT)

BILIRUBIN TOTAL	0.75	mg/dl	0.2 - 1.2
-----------------	------	-------	-----------

Checked by : _____
Page 2 Contd...3

If test results are alarming or unexpected, patient is advised to contact the laboratory immediately for possible remedial action.

Facilities Available

- Multispeciality Hospital - 24 Hours Emergency - X-Ray/ ECG/ Ultrasound/ CT Scan - Dental- Fully Equipped Operation Theatre
- Fully Functional Lab - 24/7 Casualty/ ICU-Nursery 24/7 Pharmacy - Labour Room - All Speciality OPD - Laproscopic Surgery -
ECHO - Plastic Surgery



LAB REPORT

Reg. Date	23/12/2023	Patient Id	2312230007	DOB.	
Name	MR. DEVENDRA KUMAR	Gender	M	Perm. ID	
Age	34 Yrs.	Panel	MEDIWHEEL	Reported	23/12/2023 17:03:07
Ref. By	MEDIWHEEL				

Test Name	Result	Units	Ref. Range
CONJUGATED (D. BILIRUBIN)	0.22	mg/dl	0.00 - 0.3
UNCONJUGATED (I.D.BILIRUBIN)	0.53	mg/dl	0.2 - 0.9
SGOT / AST	30.80	IU/L	0 - 35
SGPT / ALT	71.8	IU/L	0 - 35
ALKALINE PHOSPHATASE	97.00	U/L	64 - 306
TOTAL PROTEIN	8.74	gm/dl	6.0 - 8.3
ALBUMIN	4.72	gm/dl	3.2 - 5.0
GLOBULIN	4.02	gm/dl	2.5 - 5.6
A/G RATIO	1.17		0.9 - 2.0
GAMMA GT	24.21	IU/L	0.0 - 45.0
SERUM CREATININE	0.60	mg/dl	0.7 - 1.4
SERUM URIC ACID	7.13	mg/dl	3.4 - 7.0
BLOOD UREA NITROGEN (BUN)	8.14	mg/dl	6.0 - 21.0
BUN/CREAT RATIO	13.5	mg/dl	
Urine Routine Examination			

10 - 20

PHYSICAL EXAMINATION

QUANTITY	30	ml.	
COLOUR	Pale Yellow		Pale Yellow
TRANSPARENCY	Clear		
SPECIFIC GRAVITY	1.025		
PH	6.0		

CHEMICAL EXAMINATION

ALBUMIN	Nil		
SUGAR	Nil		

MICROSCOPIC EXAMINATION

PUS CELLS	1-2	/HPF	
-----------	-----	------	--

Checked by : _____
Page 3 Contd...4

If test results are alarming or unexpected, patient is advised to contact the laboratory immediately for possible remedial action.

Facilities Available

- Multispeciality Hospital - 24 Hours Emergency - X-Ray/ ECG/ Ultrasound/ CT Scan - Dental- Fully Equipped Operation Theatre
- Fully Functional Lab - 24/7 Casualty/ ICU-Nursery 24/7 Pharmacy - Labour Room - All Speciality OPD - Laproscopic Surgery - ECHO - Plastic Surgery



LAB REPORT

Reg. Date	23/12/2023	Patient Id	2312230007	DOB.	
Name	MR. DEVENDRA KUMAR	Gender	M	Perm. ID	
Age	34 Yrs.	Panel	MEDIWHEEL	Reported	23/12/2023 17:03:07
Ref. By	MEDIWHEEL				

Test Name	Result	Units	Ref. Range
RBC'S	Nil	/HPF	
CASTS	Nil		
CRYSTALS	NIL		
EPITHELIAL CELLS	0-1	/HPF	
BACTERIA	Nil		
OTHERS	Nil		

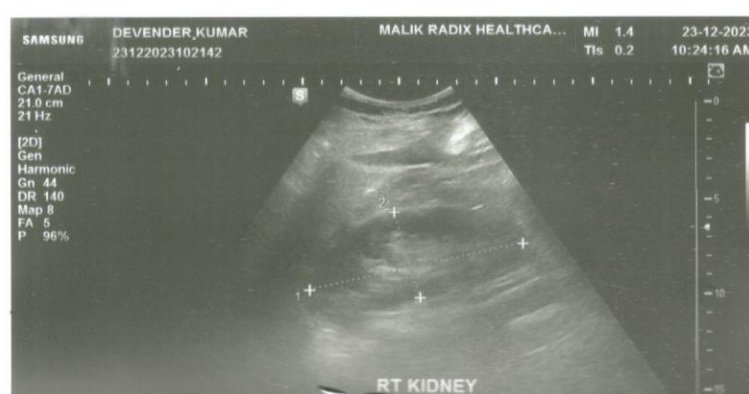
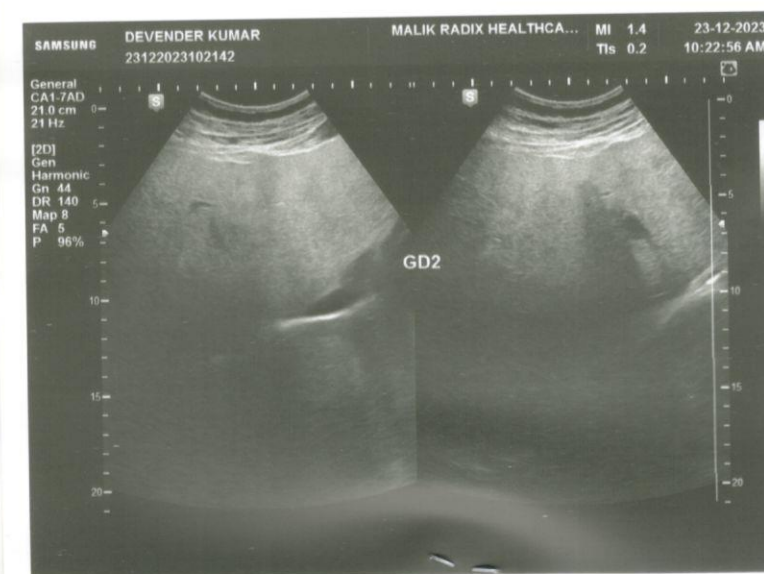
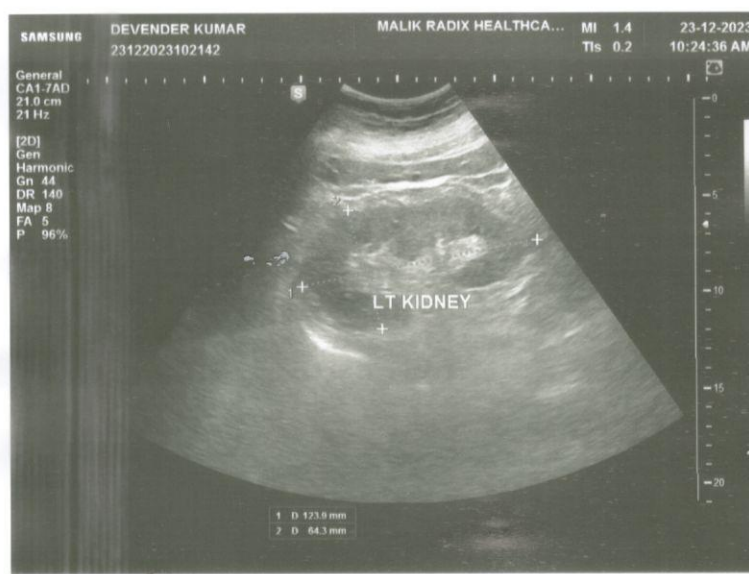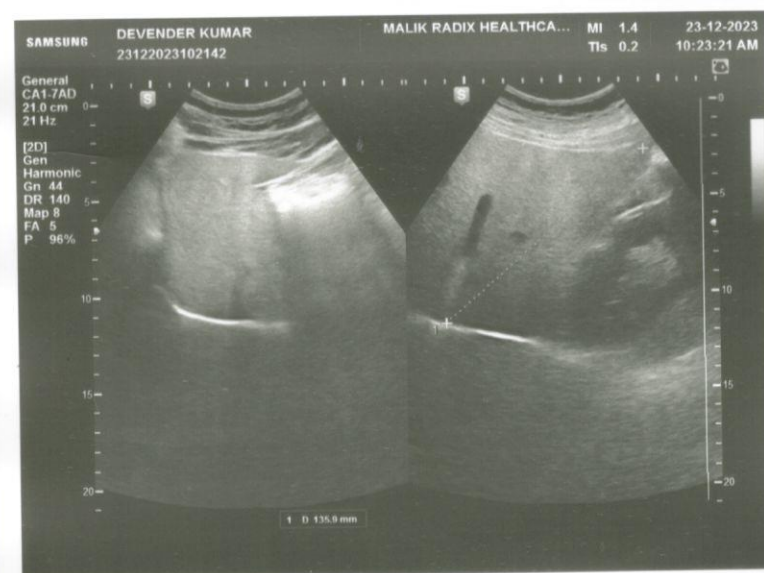
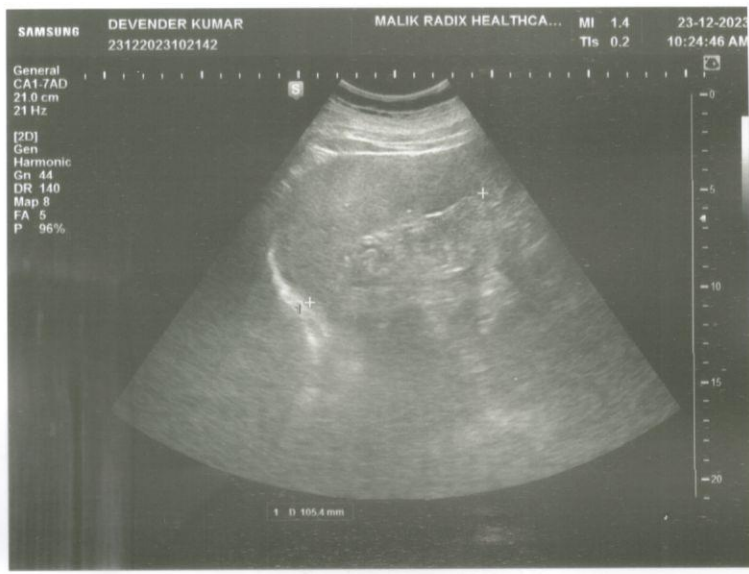
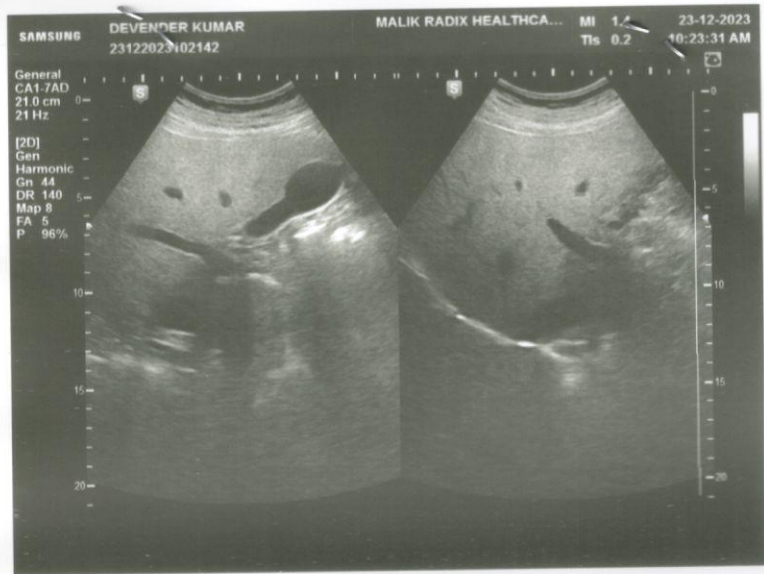
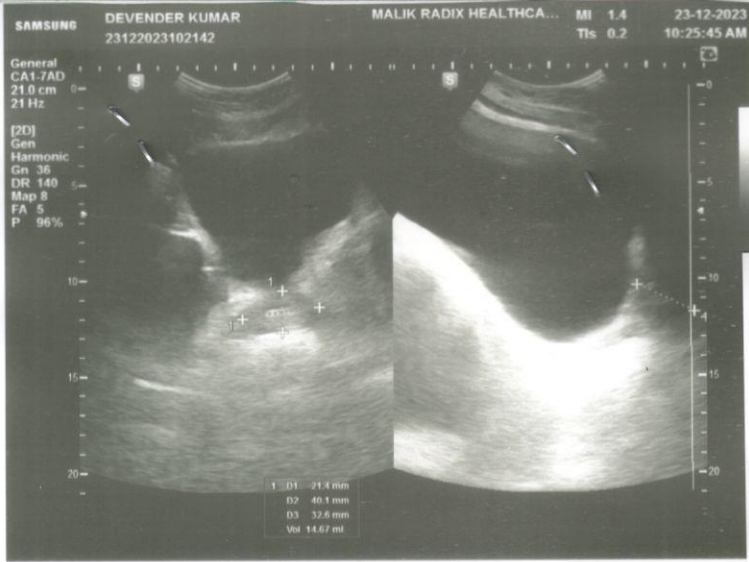
Dr. Reema Dahiyia
DR. REEMA DAHIYA
 M.B.B.S, MD (Path.)
 Checked by: _____
 Malik Radix Healthcare Pvt. Ltd.
 C-217, C-218, Nirman Vihar,


DR. MEENU AGGARWAL
 M.B.B.S, MD (Path.)

If test results are alarming or unexpected, patient is advised to contact the laboratory immediately for possible remedial action.

Facilities Available

- Multispeciality Hospital - 24 Hours Emergency - X-Ray/ ECG/ Ultrasound/ CT Scan - Dental- Fully Equipped Operation Theatre
- Fully Functional Lab - 24/7 Casualty/ ICU-Nursery 24/7 Pharmacy - Labour Room - All Speciality OPD - Laproscopic Surgery - ECHO - Plastic Surgery





NAME	MR. DEVENDRA KUMAR	AGE	34 YRS/M
REFD. BY.	HEALTH CHCEK UP	DATE	23.12.23

Ultrasound Examination of Whole Abdomen & Pelvis:

Liver: Liver appears normal in size (13.6 cm) with normal outlines and shows increased parenchymal echotexture. No focal SOL is seen in liver. IHBR & portal radicles are normal.

Gallbladder: Gallbladder is well distended. No evidence of cholecystitis or cholelithiasis seen. Common bile duct is normal in course & caliber.

Pancreas: Pancreas shows normal size, outlines & echotexture. No focal lesion is seen. MPD is not dilated.

Spleen: Spleen shows normal size (10.5 cm), outline & echotexture.

Kidneys: Kidneys show normal size, shape, position & echotexture. No calculus/ hydronephrosis or SOL is seen in kidneys. Cortico- medullary differentiation and cortical thickness is normal on both sides.

Right kidney measures -11.2 x 4.7 cm

Left kidney measures -12.4 x 6.4 cm

Great abdominal vessels are normal.

No ascites seen.

No para-aortic lymph nodes seen.

Urinary bladder Urinary bladder is well distended. Walls and lumen appear normal.

Prostate is normal in size (14.6 cc) with normal outline and echotexture. No focal lesion is seen.

IMPRESSION:

Grade II Fatty Liver

Dr Shreyash Tiwary MD (Rad- diag)

Regn. No. DMC 85802

RADIOLOGIST :


Facilities Available

R

NEVENMIRA KR 31 X M F1203416 CHESTVA 11.12.2023 10:10 AM



UHID	PT203446	LAB No.	XRY2308093
Name	Mr. DEVENDRA KUMAR	Regn. No.	GEN2332838
Age / Sex	34 Yrs / M	Receiving Dt/Time	23-Dec-2023 10:40
		Reporting Dt/Time	23-Dec-2023 11:34 AM

**XRAY**

CHEST (PA)

Both lung fields are normal.

Cp angles are clear.

Hila are normal...


Heart size appears within normal limits.

Soft tissue shadows and bony thorax are normal.

IMP- NORMAL CHEST X-RAY

Advised....please correlate clinically.

***** END OF REPORT *****


DR. K.K. SINHA
M.B.B.S. D.M.R.D.
SENIOR CONSULTANT
Reg. No. 25437 (DMC)

DR. RAJESH MALHOTRA
MBBS, MD (RADIOLOGY)
CONSULTANT RADIOLOGY
Reg.No.DMC9299

DR. T. K VOHRA
MD (RADIODIAGNOSIS)
SENIOR CONSULTANT
Reg. No. 3272 (DMC)

DR. MUKESH KOSHAL
MBBS, MD (RADIOLOGY)
CONSULTANT RADIOLOGY
Reg.No.DMC10407

DR. SHREYASH TIWARY
MBBS, MD (RADIOLOGY)
CONSULTANT RADIOLOGY
Reg.No.DMC85802

Facilities Available



LAB REPORT

Reg. Date	23/12/2023	Patient Id	2312230007	DOB.	
Name	MR. DEVENDRA KUMAR	Gender	M	Perm. ID	
Age	34 Yrs.	Panel	MEDIWHEEL	Reported	24/12/2023 12:14:03
Ref. By	MEDIWHEEL				

Test Name	Result	Units	Ref. Range
MEDIWHEEL ANNUAL PLUS			
HBA1C	5.3	%	

Interpretation

- Non Diabetic : 4-6%
- Good Diabetic Control : 6-8%
- Fair Control : 8-10%
- Poor Control : >10%

The Glycosylated haemoglobin assay has been validated as a reliable indicator Of mean blood glucose levels for a period of 8-12 week period. ADA recommended the testing twice a year in patients with stable blood glucose and quarterly. If treatment change, or if blood glucose levels are unstable.

TO BE CORRELATED CLINICALLY.

Dr. Reema Dahiya
DR. REEMA DAHIYA
 M.B.B.S, MD (Path.)
 Checked by : _____
 Malik Radix Healthcare Pvt. Ltd.
 C-217, C-218, Nirman Vihar,
 Delhi-110092

DR. MEENU AGGARWAL
 M.B.B.S, MD (Path.)

If test results are alarming or unexpected, patient is advised to contact the laboratory immediately for possible remedial action.

Facilities Available

- Multispeciality Hospital - 24 Hours Emergency - X-Ray/ ECG/ Ultrasound/ CT Scan - Dental- Fully Equipped Operation Theatre
- Fully Functional Lab - 24/7 Casualty/ ICU-Nursery 24/7 Pharmacy - Labour Room - All Speciality OPD - Laproscopic Surgery - ECHO - Plastic Surgery