



Dr. Charu Kohli's Clinic
C-234 Defence Colony, New Delhi-110024
Ph 41550792 ,24336960, 24332759
E- mail: drcharukohli@yahoo.com

NAME : POONAM

DATE : 29.9.2024

Mammography bilateral breast

Mammography using low radiation dose and compression was carried out using a dedicated CR based digital system ,in the cranio and medio lateral oblique projections.

Both breasts are composed of equitable portions of fatty and fibroglandular tissue.

No mammographically demonstrable discrete space- occupying lesion is identified in the breast parenchyma in the views taken.

No evidence of calcification is seen in both breast parenchymae.

The skin,sub cutaneous tissues and the nipple appear normal.

There is no evidence of axillary lymphadenopathy.

Impression: Study is within normal limits

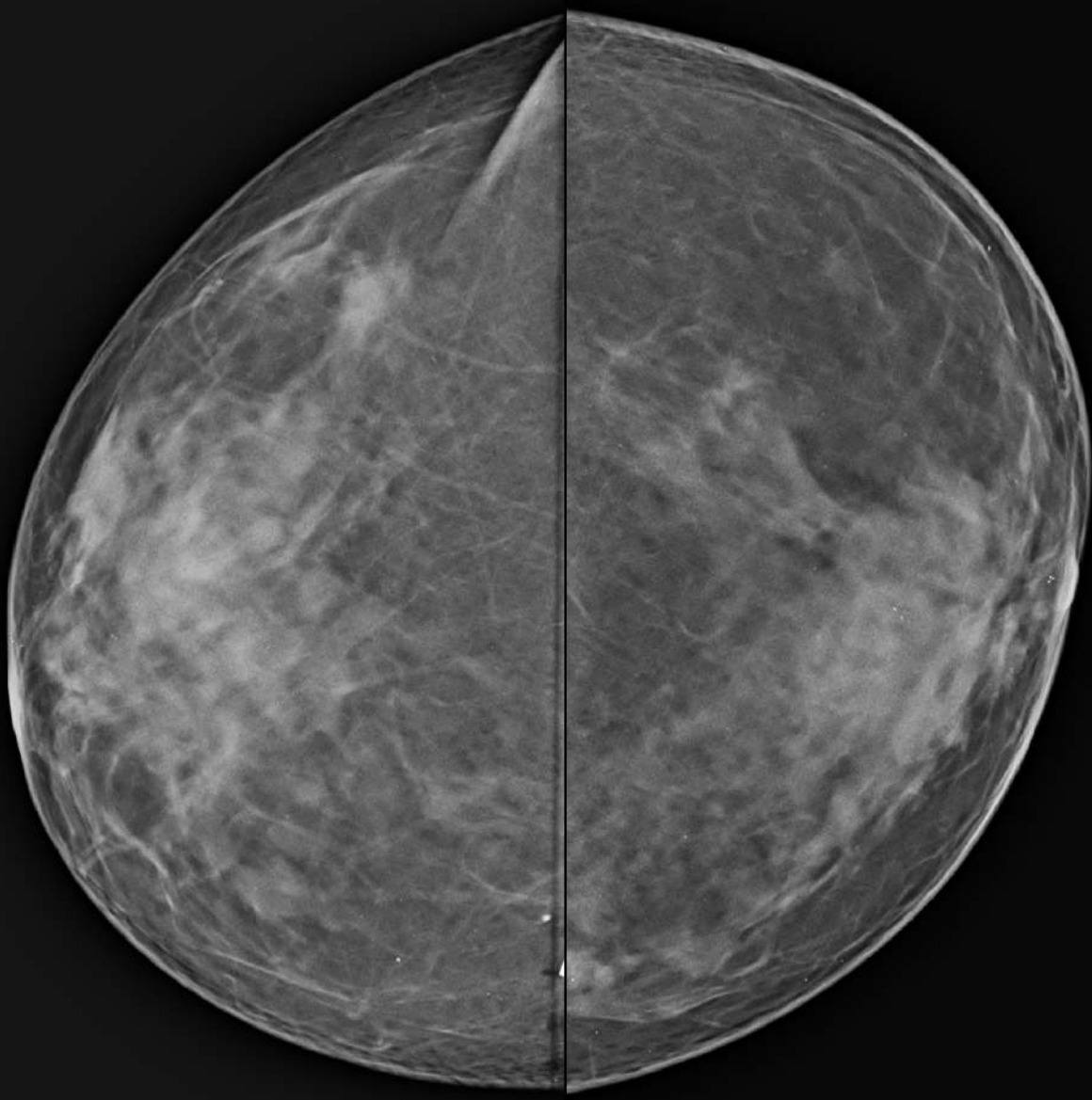
Charu Kohli

DR. CHARU KOHLI
MBBS, DMRD
Consultant Radiologist

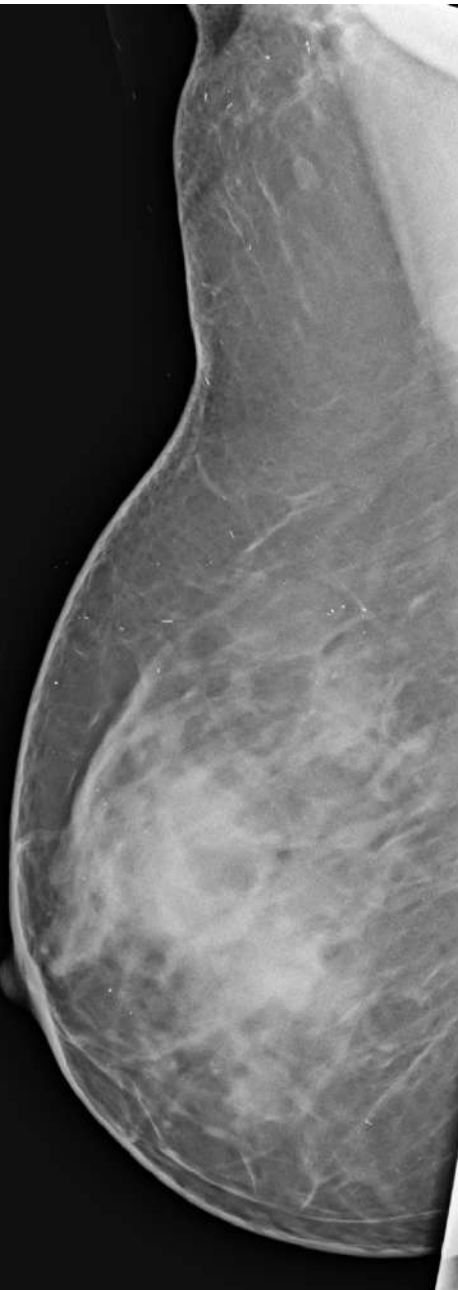
IMPORTANT: Owing to technical limitations ,in case of any error in the study ,the Doctor cannot be held responsible for claim of damages of any nature, and this report is not valid for any Medicolegal aspect.

RCC

LCC



RMLO



LMLO

