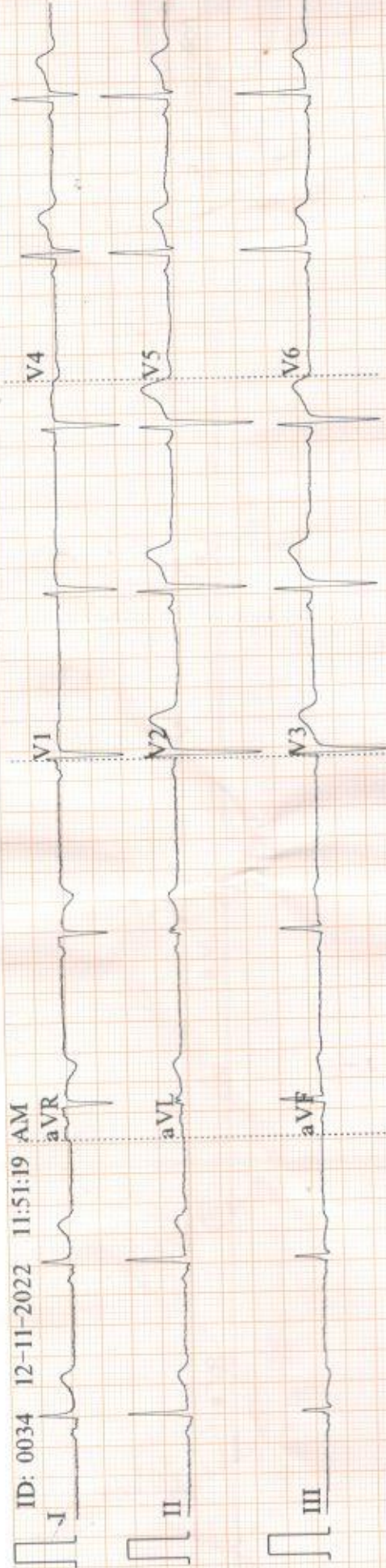


Standard	L 1	L II	L III	L III Inspiration



ID: 0034 12-11-2022 11:51:19 AM

0.5~35Hz AC50 2.5mm/s 10mm/mV ♥59 V1.0 SEMIP V1.7 DDRCSRL

NDRUM REGIO

- : 0471
- : 0475
- : 0474
- : 0474
- : 0474
- : 0471
- : 0471
- : 0471
- : 04652
- : 9496C
- : 0470
- : 0470
- : 0474
- : 0472
- : 0472
- : 0471
- : 04651

Art:W CE

V1

V2

V3

V6

Standard

ID: 0034  
 Male / mmHg  
 34 Years / kg  
 cm  
 HR : 55 bpm  
 P : 91 ms  
 PR : 127 ms  
 QRS : 80 ms  
 QT/QTc : 377/361 ms  
 PQRST : 37/49/27 °  
 RV5/SVI : 1.043/1.025 mV Report Confirmed by:

Diagnosis Information:

Ni bers Ablinangn kate.

*[Handwritten signature]*

CC

AutoW



**ECHO REPORT**

Name: VIKAS	Age/Sex:34Y/M	Date:12/11/2022
-------------	---------------	-----------------

**Left Ventricle:-**

	Diastole	Systole
IVS	1.06cm	1.20cm
LV	4.23cm	2.68cm
LVPW	1.13cm	1.20cm

EF - 66% FS - 36%

AO	LA
3.17cm	3.53cm

PV - 1.15m/s  
AV - 1.37m/s  
MVE - 0.93m/s  
MVA - 0.67m/s  
E/A - 1.39

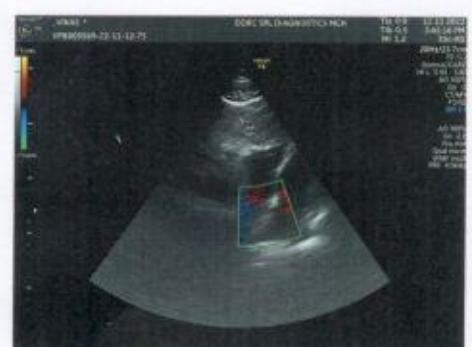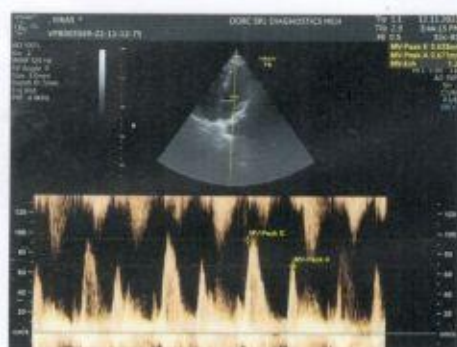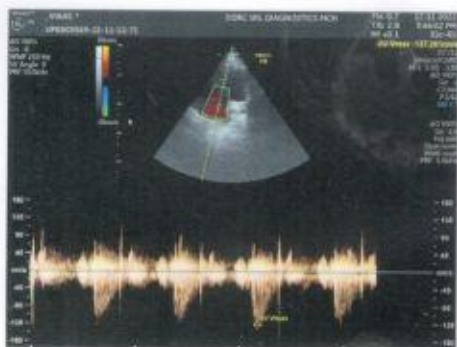
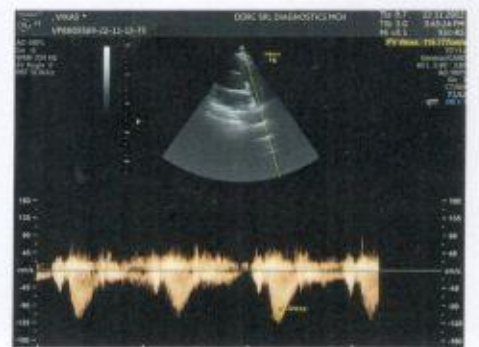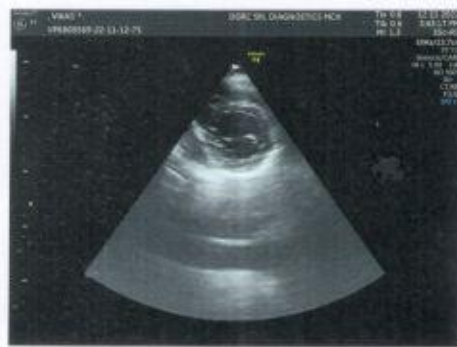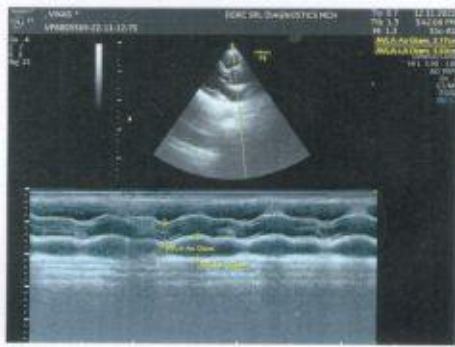**IMPRESSION:-**

- Normal chambers dimensions
- No RWMA
- Good LV systolic function
- No diastolic dysfunction
- No AS,AR,MS,MR,TR,PAH
- No Vegetation/clot/effusion
- IAS/IVS intact



  
Consultant Cardiologist

**DR. J. PRABAKARAN**  
Consulting Cardiologist  
TCMC Reg No: 72354



- Any disorders of Urinary System?  Y/N
- Any disorder of the Eyes, Ears, Nose, Throat or Mouth & Skin  Y/N

**FOR FEMALE CANDIDATES ONLY**

- a. Is there any history of diseases of breast/genital organs?  Y/N
- b. Is there any history of abnormal PAP Smear/Mammogram/USG of Pelvis or any other tests? (If yes attach reports)  Y/N
- c. Do you suspect any disease of Uterus, Cervix or Ovaries?  Y/N
- d. Do you have any history of miscarriage/abortion or MTP  Y/N
- e. For Parous Women, were there any complication during pregnancy such as gestational diabetes, hypertension etc  Y/N
- f. Are you now pregnant? If yes, how many months?  Y/N

**CONFIDENTIAL COMMENTS FROM MEDICAL EXAMINER**

- Was the examinee co-operative?
- Is there anything about the examinee's health, lifestyle that might affect him/her in the near future with regard to his/her job?
- Are there any points on which you suggest further information be obtained?
- Based on your clinical impression, please provide your suggestions and recommendations below:

*Grade & Fatty Liver*

➤ Do you think he/she is **MEDICALLY FIT** or **UNFIT** for employment.

**MEDICAL EXAMINER'S DECLARATION**

I hereby confirm that I have examined the above individual after verification of his/her identity and the findings stated above are true and correct to the best of my knowledge.

Name & Signature of the Medical Examiner

**Dr. SERIN LOPEZ, MBBS**  
**MEDICAL OFFICER**  
 DDRC SRL Diagnostics Ltd.  
 Aster Square, Medical College P.O., TVM  
 Reg. No. 77656

Seal of Medical Examiner



Name & Seal of DDRC SRL Branch

Date & Time

*12/1/20*

**DDRC SRL Diagnostics Private Limited**

Corp. Office: DDRC SRL Tower, G- 131, Panampilly Nagar, Ernakulam - 682 036  
 Ph No. 0484-2318223 2318222, e-mail: info@ddrcsrl.com, web: www.ddrcsrl.com  
 Regd. Office: 4th Floor, Prime Square, Plot No. 1, Gaiwadi Industrial Estate, S.V. Road, Goregaon (West), Mumbai - 400062.

Acc no: 4182VK005107

Name: Mr. Vikas Abhimanyu Kute

Age: 34 y

Sex: Male

Date: 12.11.2

**RADIOLOGY DIVISION**

**US SCAN WHOLE ABDOMEN**

**LIVER** is normal in size (12.3 cm). Margins are regular. **Hepatic parenchyma shows mildly increased echogenicity.** No focal lesions seen. No dilatation of intrahepatic biliary radicles. CBD is not dilated. Portal vein is normal in caliber (10 mm).

**GALL BLADDER** is partially distended and grossly normal. No pericholecystic fluid seen.

**SPLEEN** is normal in size (9.9 cm) and parenchymal echotexture. No focal lesion seen.

**PANCREAS** obscured by bowel air.

**RIGHT KIDNEY** is normal in size (9.6 x 4.2 cm) and shows normal parenchymal echotexture. Cortico medullary differentiation is maintained. Parenchymal thickness is normal. No echogenic focus with shadowing suggestive of renal calculi seen. No dilatation of pelvicalyceal system seen. Ureter is not dilated. Perinephric spaces are normal.

**LEFT KIDNEY** is normal in size (9.9 x 4.9 cm) and shows normal parenchymal echotexture. Cortico medullary differentiation is maintained. Parenchymal thickness is normal. No echogenic focus with shadowing suggestive of renal calculi seen. No dilatation of pelvicalyceal system seen. Ureter is not dilated. Perinephric spaces are normal.

**PARAAORTIC AREA** (Lower part visualised) No retroperitoneal lymphadenopathy or mass seen.

**URINARY BLADDER** is partially distended, normal in wall thickness, lumen clear.


**PROSTATE** is normal in size (vol - 15.3 cc) and shows normal echotexture. No focal lesion seen.

No ascites or pleural effusion.

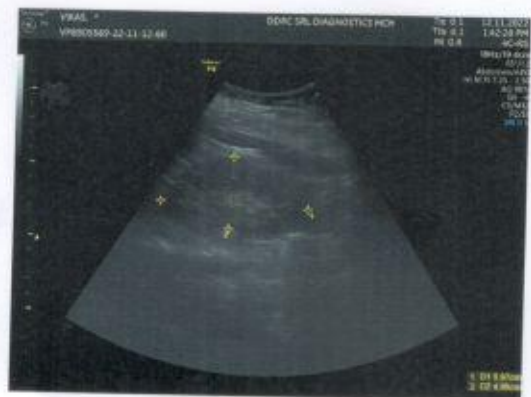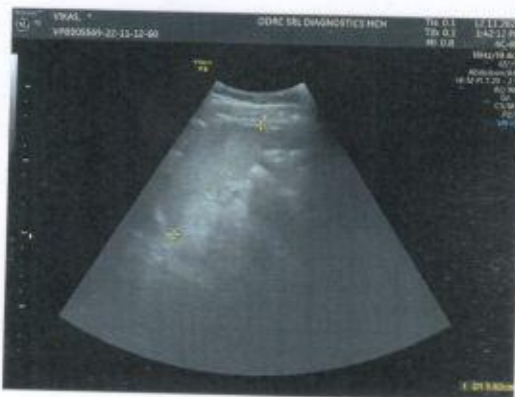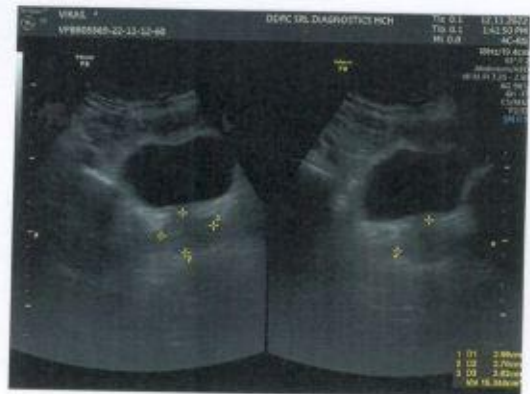
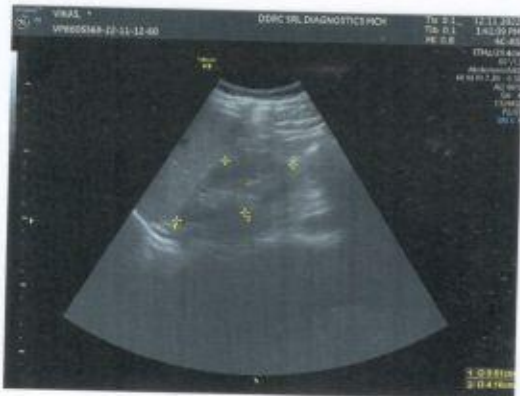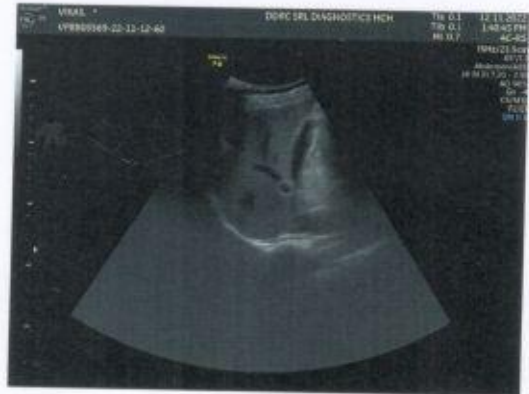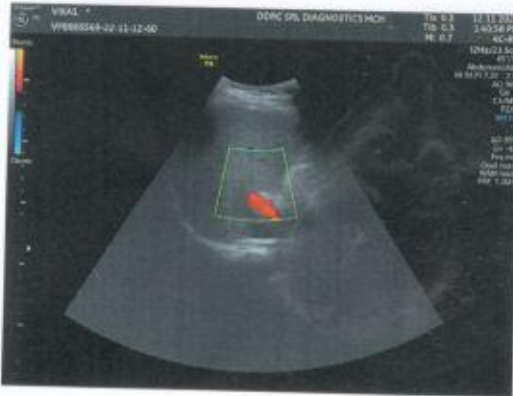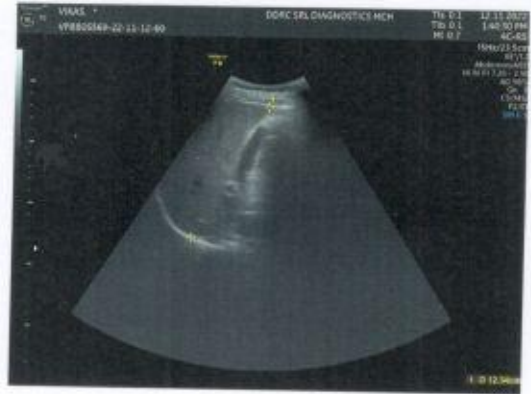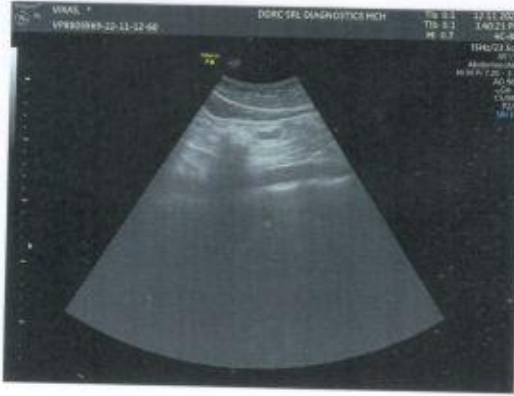**Gaseous distension of bowel loops noted. No obvious bowel wall thickening seen sonologically.**

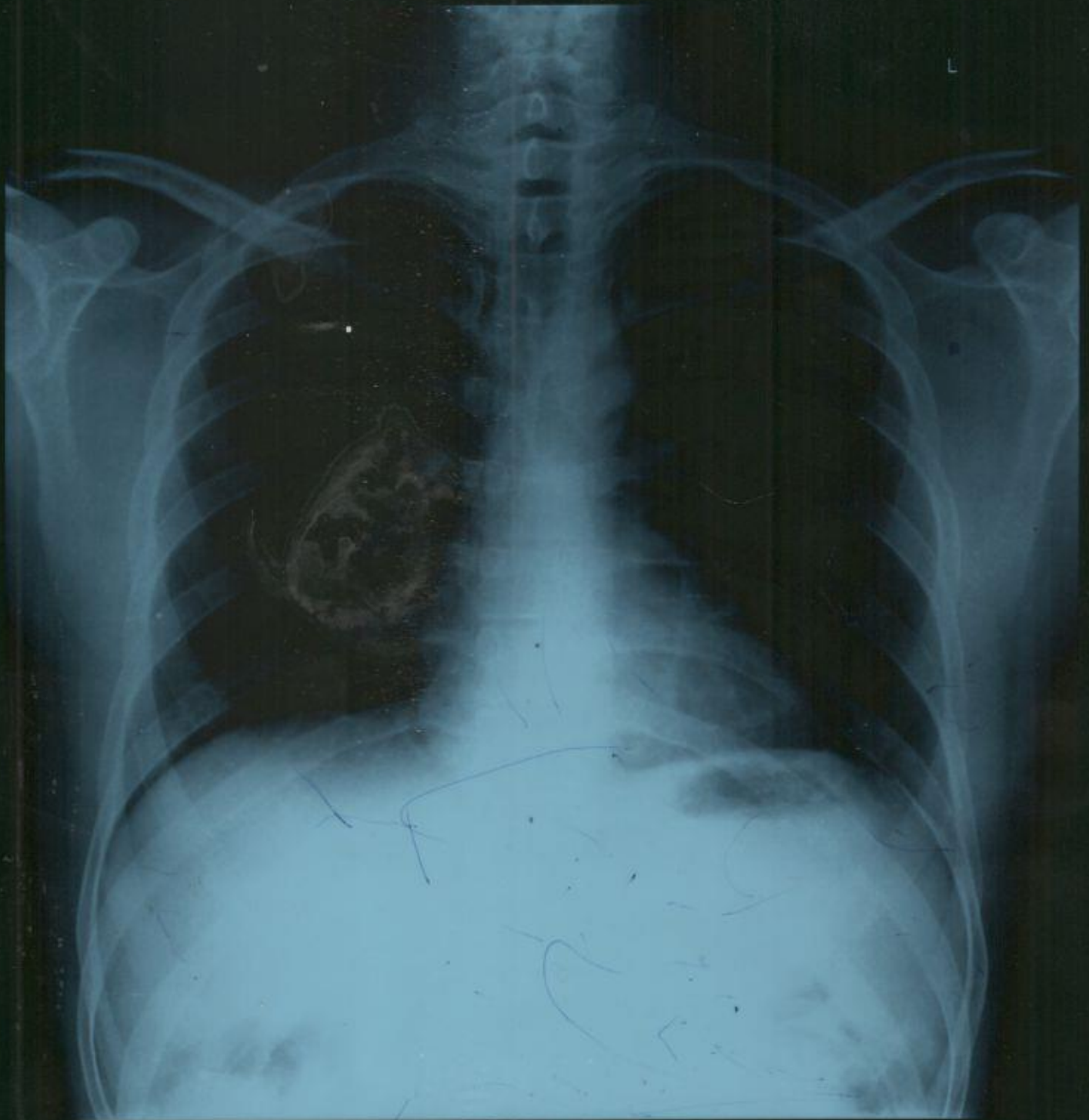**CONCLUSION:-**

- Grade I fatty liver.

  
**Dr. Nisha Unni MD, DNB (RD)**  
Consultant radiologist.

Thanks, your feedback will be appreciated.  
(Please bring relevant investigation reports during all visits).  
Because of technical and technological limitations complete accuracy cannot be assured on imaging.  
Suggested correlation with clinical findings and other relevant investigations consultations, and if required repeat imaging recommended in the event of controversies. AR





DDRC SRL  
MR VIKAS ABHIMANYU KUTE 34Y M 11/12/2022 CHEST- PA VK005107 n