



H Swaminarayan Nagar, Off Mumbai-Agra Highway,
Panchvati, Nashik - 422 003.
+91- 253 - 2510250 / 350 / 450 / 550 / 750
apollonashik@apollohospitals.com
www.askapollo.com

QFAHN/BILL/003/V1



Apollo
HOSPITALS
NASHIK

Name : Mrs. MAYUREE MAHESH THUBE (32 /F)
Address : NASHIK, NASHIK, NASHIK, MAHARASHTRA, INDIA
Examined by:
Package : MediWheel Full Body Health Checkup Female Below 40
Package

Date : 08/11/2022
UHID : MHN1.0000127858
AHC No : NSKAH28206

CHIEF COMPLAINTS

For corporate health checkup
No specific complaints

PRESENT KNOWN ILLNESS

Present known illness

No history of : - Diabetes mellitus, Hypertension, Thyroid disorder, Heart disease, Stroke, Asthma, COPD, Cancer

DRUG ALLERGY

NO KNOWN ALLERGY

:08/11/2022

Immunization history

- Covid Dose1, Covid Dose2

SYSTEMIC REVIEW

Cardiovascular system

- Nil Significant

Personal history

Marital status - Married
No. of children - 01
Diet - Mixed Diet
Alcohol - does not consume alcohol
Smoking - No
Chews tobacco - No
Physical activity - Active

Past medical history

Do you have any allergies? - No
Do you have any drug allergies? - No
Past medical history - nil significant
Covid 19 - Yes
- March 2021
Post detection (3 Weeks) - No
Hospitalization for Covid 19 - No
Oxygen support - No

Family history

Hypertension - father
Coronary artery disease - none
Cancer - None

Surgical history

Lower segment caesarean section - done

PHYSICAL EXAMINATION

General

General appearance - normal
Build - normal
Height - 156
Weight - 64.5
BMI - 26.5
Pallor - No



H Swaminarayan Nagar, Off Mumbai-Agra Highway,
Panchvati, Nashik - 422 003.

+91- 253 - 2510250 / 350 / 450 / 550 / 750

apollonashik@apollohospitals.com

www.askapollo.com

QFAHN/BILL/003/V1



Name : Mrs. MAYUREE MAHESH THUBE (32 /F)

UHID : MHN1.0000127858

Date : 08/11/2022

Package : MediWheel Full Body Health Checkup Female Below 40 Package

AHC No : NSKAH28206

Oedema - no
Temperature - 96.5
SpO2 - 98

Cardiovascular system

Heart rate (Per minute) - 62
Rhythm - Regular
- B.P. Supine
Systolic(mm of Hg) - 100
Diastolic(mm of Hg) - 60
Heart sounds - S1S2+

Respiratory system

Breath sounds - Normal vesicular breath sounds

Abdomen

Organomegaly - No
Tenderness - No





H Swaminarayan Nagar, Off Mumbai-Agra Highway,
Panchvati, Nashik - 422 003.

+91- 253 - 2510250 / 350 / 450 / 550 / 750

apollonashik@apollohospitals.com

www.askapollo.com

QFAHN/BILL/003/V1



Name : Mrs. MAYUREE MAHESH THUBE (32 /F)

UHID : MHN1.0000127858

Date : 08/11/2022

Package : MediWheel Full Body Health Checkup Female Below 40 Package

AHC No : NSKAH28206

URINE ROUTINE (CUE)

Test Name	Result	Unit	Level	Range
Specific Gravity	1.030 *		●	1.016-1.026
Color,:	pale yellow			
Transparency:	Slightly Turbid			
Reaction:	Acidic			7.2-7.8
Protein :	Absent			
Sugar:	Absent			
Blood:	5.5		●	4.6-8
Ketone	Absent			
Bile Pigments:	Absent			
Bile Salts :	Negative			
Urobilinogen	Normal			
Nitrite	Negative			
RBC	00	/hpf	●	0-2
WBC/Pus Cells	5-6	/hpf		
Tc/Sqc(Transitional/Squamous epithelial cells)	4-5	/hpf		

Neutrophils	65	%	●	40-75
Lymphocytes	29	%	●	20-45
Eosinophils	01	%	●	1-6
Monocytes	05	%	●	1-10
Basophils	00	%	●	0-1
ERYTHROCYTE SEDIMENTATION RATE (ESR)	6.0	mm/1st hr	●	0-20

BLOOD GROUPING AND TYPING (ABO and Rh)

Test Name	Result	Unit	Level	Range
ABO Group:	B			
Rh (D) Type:	POSITIVE			

LIVER FUNCTION TEST (PACKAGE)

Test Name	Result	Unit	Level	Range
ALT(SGPT) - SERUM / PLASMA	31	U/L	●	30-65
ALBUMIN - SERUM	4.1	g/dL	●	3.5-5
ALKALINE PHOSPHATASE - SERUM/PLASMA	62	U/L	●	0-100
AST (SGOT) - SERUM	28	U/L	●	15-37

C B C WITH ESR (AUTOMATION + STANDARD METHOD)

Test Name	Result	Unit	Level	Range
Hemoglobin	13.9	g/dl		11.0-16.0
Haematocrit	42.5	%	●	34.0-48.0
RBC COUNT	5.37	Million/ul	●	3.7-5.6
MCV	79.2	fl	●	75.0-95.0
MCH	25.9 *	pg	●	26.0-32.0
MCHC	32.7	g/dl	●	31.0-36.0
RDW	12.9	%	●	11-16
Platelet Count(Optical/Impedance)	228	10 ³ /m ³	●	140-440
TLC Count	6.83	10 ³ /m ³	●	4.0-11.0

LIPID PROFILE TEST (PACKAGE)

Test Name	Result	Unit	Level	Range
Total Cholesterol	137	mg/dL	●	0-200

CREATININE - SERUM / PLASMA

Test Name	Result	Unit	Level	Range
CREATININE - SERUM / PLASMA	0.6	mg/dL	●	0.6-1.0

LIVER FUNCTION TEST (PACKAGE)

Test Name	Result	Unit	Level	Range
-----------	--------	------	-------	-------

● Within Normal Range ● Borderline High/Low ● Out of Range



H Swaminarayan Nagar, Off Mumbai-Agra Highway,
Panchvati, Nashik - 422 003.
+91- 253 - 2510250 / 350 / 450 / 550 / 750
apollonashik@apollohospitals.com
www.askapollo.com

QFAHN/BILL/003/V1



Name : Mrs. MAYUREE MAHESH THUBE (32 /F)

UHID : MHN1.0000127858

Date : 08/11/2022

Package : MediWheel Full Body Health Checkup Female Below 40 Package

AHC No : NSKAH28206

GGTP: GAMMA GLUTAMYL TRANSPEPTIDASE - SERUM 13 U/L 0-50

GLUCOSE - SERUM / PLASMA (FASTING)

Test Name	Result	Unit	Level	Range
Glucose - Plasma (Fasting)	77	mg/dL		70-100
URINE GLUCOSE(FASTING): (Dip Method)	Nil			

GLUCOSE - SERUM / PLASMA (POST PRANDIAL)

Test Name	Result	Unit	Level	Range
Glucose - Plasma (POST PRANDIAL)	80	mg/dL		70-140
URINE GLUCOSE(POST PRANDIAL):(Strip Method)	Nil			

GLYCOSYLATED HEMOGLOBIN (HbA1C) - WHOLE BLOOD

Test Name	Result	Unit	Level	Range
Glycosylated Hemoglobin (HbA1c)	5.1	%		0.0-6.0
an Plasma Glucose (MPG) Estimate:	104.2600	mg/dL		

LIPID PROFILE TEST (PACKAGE)

Test Name	Result	Unit	Level	Range
HDL CHOLESTEROL - SERUM / PLASMA	47	mg/dL		40-60
TOTAL CHOLESTEROL/HDL CHOLESTEROL RATIO(Calculated)	2.9			0.0-4.5
LDL Cholesterol (Direct LDL)	94	mg/dL		

LIVER FUNCTION TEST (PACKAGE)

Test Name	Result	Unit	Level	Range
PROTEIN, TOTAL - SERUM / PLASMA	7.6	g/dL		6.4-8.2
PROTEIN, TOTAL - SERUM / PLASMA	7.6	g/dL		6.4-8.2

LIPID PROFILE TEST (PACKAGE)

Test Name	Result	Unit	Level	Range
Triglycerides - Serum	78	mg/dL		0-150

UREA - SERUM / PLASMA

Test Name	Result	Unit	Level	Range
UREA - SERUM / PLASMA	14 *	mg/dL		15-38
UREA NITROGEN SERUM/PLASMA: (Calculated)	7	mg/dL		7-18

URIC ACID - SERUM

Test Name	Result	Unit	Level	Range
URIC ACID - SERUM	4.7	mg/dL		2.6-6.0

LIVER FUNCTION TEST (PACKAGE)

Test Name	Result	Unit	Level	Range
BILIRUBIN CONJUGATED (DIRECT) - SERUM	0.2	mg/dL		0.0-0.3
BILIRUBIN UNCONJUGATED - SERUM(Calculated)	0.3	mg/dL		0.0-0.7

CARDIAC STRESS TEST - (TMT)

ECG

ULTRASOUND - WHOLE ABDOMEN

Bulky ovaries showing PCOS like picture. A well-defined oval anterior abdominal wall mass lesion is most likely to be a hematoma. Advice : CECT abdomen for further evaluation.

X-RAY CHEST PA

● Within Normal Range ● Borderline High/Low ● Out of Range



H Swaminarayan Nagar, Off Mumbai-Agra Highway,
Panchvati, Nashik - 422 003.

+91- 253 - 2510250 / 350 / 450 / 550 / 750

apollonashik@apollohospitals.com

www.askapollo.com

QFAHN/BILL/003/V1



Name : Mrs. MAYUREE MAHESH THUBE (32 /F)

UHID : MHN1.0000127858

Date : 08/11/2022

Package : MediWheel Full Body Health Checkup Female Below 40 Package

AHC No : NSKAH28206

No significant abnormality is detected.

INVESTIGATIONS NOT DONE / NOT YET REPORTED / NOT PART OF PACKAGE(LAB,RADIOLOGY & CARDIOLOGY)

Haematology

STOOL ROUTINE

Biochemistry

TSH: THYROID STIMULATING HORMONE - SERUM

TOTAL T3: TRI IODOTHYRONINE - SERUM

Histopathology

CERVICAL/VAGINAL SMEAR II SLIDE

Biochemistry

TOTAL T4: THYROXINE - SERUM



Within Normal Range



Borderline High/Low



Out of Range



H Swaminarayan Nagar, Off Mumbai-Agra Highway,
Panchvati, Nashik - 422 003.

+91- 253 - 2510250 / 350 / 450 / 550 / 750

apollonashik@apollohospitals.com

www.askapollo.com

QFAHN/BILL/003/V1



Name : Mrs. MAYUREE MAHESH THUBE (32 /F)

UHID : MHN1.0000127858

Date : 08/11/2022

Package : MediWheel Full Body Health Checkup Female Below 40 Package

AHC No : NSKAH28206

Printed By :

AHC Physician / Consultant Internal Medicine



Note :- The Health Check-up examinations and routine investigations have certain limitations and may not be able to detect all the diseases. Any new or persisting symptoms should be brought to the attention of the Consulting Physician. Additional tests, consultations and follow up may be required in some cases.

ID: 000127868
Visit:

8-Nov-2022
12:19:05

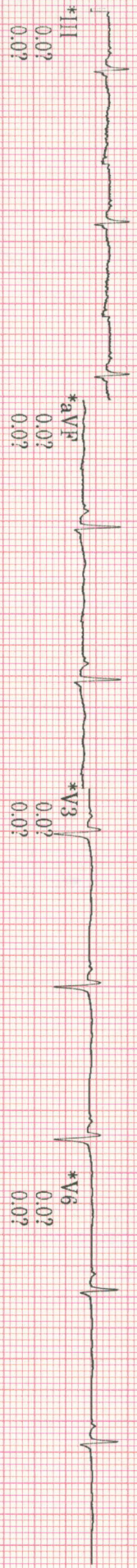

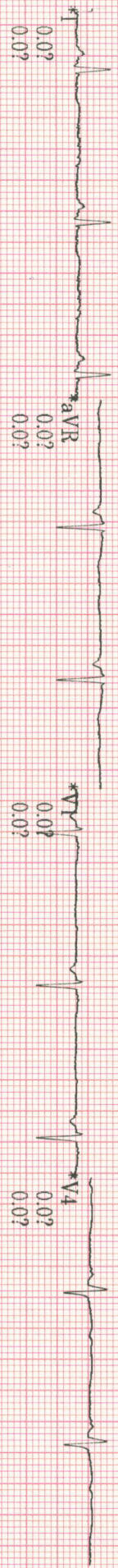
61bpm
BP: 110/70

PRETEST
SUPINE
0:28

BRUCE
** *mph
** **%

ST @ 10mm/mV
80ms postJ

Lead
ST(mm)
Slope(mV/s)



Raw Rhythm
40 Hz 25.0 mm/s 10.0 mm/mV
A-H-S-50Hz HR 46

* Computer Synthesized Rhythm

MAC55 010B

ARROW CE



H Swaminarayan Nagar, Off Mumbai-Agra Highway,
Panchvati, Nashik - 422 003.

+91- 253 - 2510250 / 350 / 450 / 550 / 750

apollonashik@apollohospitals.com

www.askapollo.com

QFAHN/BILL/003/V1



Apollo
HOSPITALS
NASHIK

MD (Radiology)

Patient Details : Mrs. MAYUREE MAHESH THUBE | Female | 32Yr 0Mth 0Days

UHID : MHN1.0000127858

Patient Location: AHC

Patient Identifier: NSKAH28206



DRN : 122043840

Completed on : 08-NOV-2022 11:39

Ref Doctor : Dr. Rajashri Dhongade

X-RAY CHEST PA

Both lung fields are clear.

Both hila are normal in size and position.

Costophrenic and cardiophrenic angles are clear.

Cardiac size and contour are within normal limits.

Rib cage is normal.

Soft tissues are normal.

Impression

No significant abnormality is detected.

--- END OF THE REPORT ---

Kunal Kalyanrao Patil

Consultant - MD (Radiodiagnosis)




Swaminarayan Nagar, Off Mumbai-Agra Highway,
Panchvati, Nashik - 422 003.
+91- 253 - 2510250 / 350 / 450 / 550 / 750
apollonashik@apollohospitals.com
www.askapollo.com

QFAHN/BILL/003/V1



MD (Radiology)

Patient Details : Mrs. MAYUREE MAHESH THUBE | Female | 32Yr 0Mth 0Days
UHID : MHN1.0000127858 **Patient Location:** AHC
Patient Identifier: NSKAH28206 
DRN : 222027047 **Completed on :** 08-NOV-2022 11:44
Ref Doctor : Dr. Rajashri Dhongade

ULTRASOUND - WHOLE ABDOMEN

LIVER : Normal in size. Echotexture is uniform and normal.
No I.H.B.D./ focal lesions.

PORTAL VEIN: Normal in size.

GALL BLADDER: Well distended with normal walls and lumen.
No calculi/pericholecystic fluid.

COMMON BILE DUCT: Normal in size.

PANCREAS : Visualized portion of head and body of pancreas appears normal in size and echotexture. Rest of the pancreas is obscured due to bowel gases.

AORTA, IVC and para aortic areas are normal.

SPLEEN : Normal in size and echotexture.

KIDNEYS: Both kidneys are normal in site, size and echotexture.
No evidence of calculi/ hydronephrosis.
Right kidney measures : 10.2 x 3.8 cm.
Left kidney measures : 11.5 x 4.1 cm.

URINARY BLADDER: Well distended with normal walls.
No evidence of calculi/ growth/ diverticula .

UTERUS: Anteverted. Normal in size and echotexture.
Uterus measures : 4.2 x 3.9 x 8.8 cm.
Combined endometrial thickness is normal and measures 7.3mm.



H Swaminarayan Nagar, Off Mumbai-Agra Highway,
Panchvati, Nashik - 422 003.

+91- 253 - 2510250 / 350 / 450 / 550 / 750

apollonashik@apollohospitals.com

www.askapollo.com

QFAHN/BILL/003/V1



Mrs. MAYUREE MAHESH THUBE

MHN1.0000127858

NSKAH28206

ULTRASOUND - WHOLE ABDOMEN

OVARIES:

Right ovary measures : 3.9 x 2.7 x 2.7 cm, Vol - 15.8cc.

Left ovary measures : 3.5 x 2.3 x 2.3 cm, Vol - 10cc.

Both ovaries are bulky in size with echogenic stroma and multiple small follicles within.

Normal in size and echotexture.

Visualized bowel loops appear grossly normal.

No evidence of any free fluid in the peritoneal cavity.

A defect of size 1.2cm is seen in the anterior wall (linea alba) in supraumbilical region approx. 2 to 3cm from umbilicus.

A well-defined oval hypoechoic lesion of size 4.7 x 1.6cm is seen in the subcutaneous region. A similar lesion of size 1.5 x 1.0 cm is seen below the linea alba. These two lesions are seen communicating with each other. These lesions show heterogeneous predominantly hypoechoic echotexture. No vascularity on colour doppler.

Impression

Bulky ovaries showing PCOS like picture.

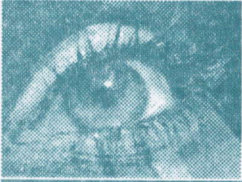
A well-defined oval anterior abdominal wall mass lesion is most likely to be a hematoma.

Advice : CECT abdomen for further evaluation.

--- END OF THE REPORT ---

Kunal Kalyanrao Patil

Consultant - MD (Radiodiagnosis)



OPHTHALMOLOGY



Name : Mrs. Mayumi Thube Date 8/11/22 UNIT _____
 Occupation : _____ Room No. _____ Out Patient
 Age : 32 Sex : Male Female S/M/W/D Ref. Physician : _____
 Address : NM Copies to : _____
 Tel. No. _____

REPORT ON OPHTHALMIC EXAMINATION

HISTORY : _____
 PRESENT COMPLAINT : _____
 PAST HISTORY : DM / HTN / ALLERGY

ON EXAMINATION

VISION : RE LE
6/60P 6/60P

PGP	RIGHT				LEFT			
	SPH	CYL	AXIS	VA	SPH	CYL	AXIS	VA
DIST	<u>3-25</u>				<u>3-25</u>			
NEAR								

R / Retinoscopy :

RIGHT			LEFT		
SPH	CYL	AXIS	SPH	CYL	AXIS
<u>3-0</u>	<u>0-5</u>	<u>59</u>	<u>3-5</u>	-	-

Refraction or Acceptance :



	RIGHT				LEFT			
	SPH	CYL	AXIS	VA	SPH	CYL	AXIS	VA
DIST	<u>3-25</u>	-	-	<u>6/60</u>	<u>3-25</u>	-	-	<u>6/60</u>
NEAR				<u>6/60</u>				<u>6/60</u>

Handwritten signature/initials

Anterior Segment :

RE

LE

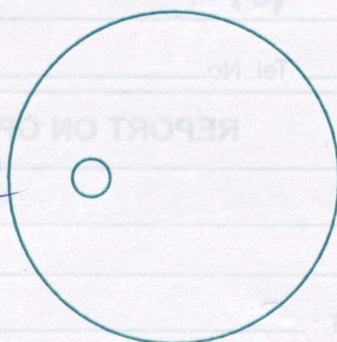
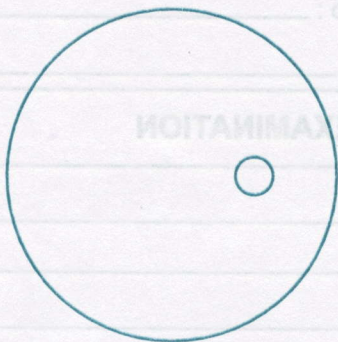
① Pupils mm
w/c clear

Fundus :

RE

LE



gou @

Diagnosis :

① Moderate Myopia

Advise / Rx:

Can do 12

LEFT				RIGHT			
VA	CYL	SPH	AXIS	VA	CYL	SPH	AXIS
3/4	-	-2.5	180	3/4	-	-2.5	180

CONSULTANT OPHTHALMOLOGIST



H Swaminarayan Nagar, Off Mumbai-Agra Highway,
Panchvati, Nashik - 422 003.

+91- 253 - 2510250 / 350 / 450 / 550 / 750

apollonashik@apollohospitals.com

www.askapollo.com

QFAHN/BJLL/003/V1



8/11/22

For

Mayuri Thube

Stains & calculus

$\frac{+}{+} / \frac{+}{+}$

Adm - scaling.

Apollo
HOSPITALS
NASHIK

1
20

ID: 000127858

Visit:

8-Nov-2022

12:18:37

32years

Asian

Female

BRUCE

Max HR: 187bpm

Max BP: 130/70

Reason for Termination: Patient fatigue

Comments:

Total Exercise time: 6:46

Maximum predicted 175bpm

Maximum workload: 8.1METS

25.0 mm/s

10.0 mm/mV

100hz

Referred by:
Test ind:

Phase Name	Stage Name	Time in Stage	Speed (mph)	Grade (%)	WorkLoad (METS)	HR (bpm)	BP (mmHg)	RPP (x100)
PRETEST	SUPINE	0:02	***	***	1.0	58		
	STANDING	0:03	***	***	1.0	58		
	HYPERVERENT	0:06	0.7	0.0	1.0	62	110/70	68
EXERCISE	STAGE 1	3:00	1.7	10.0	4.6	133		
	STAGE 2	3:00	2.5	12.0	7.0	141	120/70	169
	STAGE 3	0:46	3.4	14.0	8.1	187	130/70	243
RECOVERY	Post	4:42	***	***	1.0	97	130/70	126

TMT Positive for SU
