



ANUBIKSHAN

Diagnostic Centre

Near Asansol District Hospital(Main Gate)
S.B. Gorai Road, Asansol-713301
Email ID : anubikshan.dc@gmail.com
Ph. : 0341-3590332, M. : 9732362727, 7872772680



BANK OF BARODA MEDICAL EXAMINATION REPORT

Client name :- Pijush Misra (PIJUSH MISRA)
Ref. No. :- 10000 236
Date of birth :- 15.03.1977 Sex :- Male / Female
Identification mark on the body :- Nothing as such found,
Photo ID Xerox :- Adhar card no. 9934 1951 6075.
Date & place of medical examination :- 12.11.2022, Asansol.

Request for medical exam. of **BANK OF BARODA** through Medi Assist Health Care India (Pvt.) Ltd.

- A) 1. Height :- 181 cm. 2. Weight :- 86 kgs.
 3. Chest Inspiration :- 110 cm. 4. Chest Expiration :- 106 cm.
 5. Abdomen Girth :- 104 cm.
 6. Blood Pressure :- I) 156/87 mm. of Hg. II) 150/84 mm. of Hg.
 7. Pulse Rate :- 78 / minute. Character of pulse :- Regular

- B) 1. Are you now in good health? Yes.
 2. Are you currently taking any medicine? Yes, (Telomikind AM) to control ↑BP.
 3.) Are you married? Yes
 4. Have you ever had a positive test for HIV / AIDS / Malignancy? No
 5. Have you ever suffering from sexually transmitted disease or Hepatitis B or C?
No
 6. Have you any congenital disorders? No
 7. Have you any respiratory disorders? No
 8. Have you any musculo skeletal disorders? No
 9. Have you CVS disorders? No
 10. Have you GI system disorders? No
 11. Have you urinary system disorders? No
 12. Have you reproductive system disorders? No





ANUBIKSHAN

Diagnostic Centre

Near Asansol District Hospital(Main Gate)
S.B. Gorai Road, Asansol-713301
Email ID : anubikshan.dc@gmail.com
Ph. : 0341-3590332, M. : 9732362727, 7872772680



13. Have you Diabetes / Hypertension / Endocrine disorders? NO.....
14. Have you ever done any surgical operation? NO.....
15. Have you any ear problem? No.....
16. Have you any eye problem? VA 6/6 (CP), Near VA - No, with kangles
VA 6/6 (CP), Member NC
17. Have you nervous system disorders? No.....
18. Have you any abnormal growth? NO.....
19. Have you any blood disorders? NO.....
20. What is general appearance of the client? Healthy.....
21. Does the appearance correspond with the age? Yes.....
22. Is there any personal peculiarities? no.....
23. Tobacco (Stick / gms)- Panmasala/Cigar / Cigarette / Bidi / Gutkha Yes NO
Alcohol(ml)- Beer / Wine / Hard Liquor :- Qty./ Day For No. of Yrs

12/11/22

24. Family History	Age if living	Age at death	Present state of health or cause of death
Father	<u>65y</u>	<u>65y</u>	<u>N.D</u>
Mother	<u>71y</u>	<u>Alive</u>	<u>(Good health)</u>
Brother (s)	<u>NIL</u>		
Sister (s)	<u>49y, 39y</u>	<u>Alive</u>	<u>(Good health)</u>

25. ANY REMARK BY THE MEDICAL EXAMINAR: - Mild to moderate fatty change of liver with little high value of cholesterol which is under medication otherwise normal. He is also under medication for hypertension.

Prabin Prasad
Signature of the Client

Dr. Sanjeev Shah
Name of the Doctor

Date: - 12/11/2022

Dr. Sanjeev Shah
Signature & Seal of the Doctor





Dr. Sanjeev Kevin Shah
M.B.B.S., MD (Med.)
Reg. No. 16138

भारत सरकार
GOVERNMENT OF INDIA

पिजुश मिश्रा
PIJUSH MISRA
जन्म तिथि/ DOB: 15/03/1977
पुरुष / MALE

9934 1951 6075

आधार-आम आदमी का अधिकार



Sanjeev

Dr. Sanjeev Kevin Shah
M.B.B.S., MD (Med.)
Reg. No. 16138



भारतीय विशिष्ट पहचान प्राधिकरण
UNIQUE IDENTIFICATION AUTHORITY OF INDIA

पता: 7 TETRA SCHOOL, 1020 AREA,
एरिया, एयर फ़ोर्स स्टेशन,
लोहेगांव, पुणे,
महाराष्ट्र - 411032

Address:
7 TETRA SCHOOL, 1020 AREA,
AIR FORCE STATION, Pune City,
Pune,
Maharashtra - 411032

Aadhaar-Aam Admi ka Adhikar



ANUBIKSHAN

Diagnostic Centre

Near Asansol District Hospital(Main Gate)
S.B. Gorai Road, Asansol-713301
Email ID : anubikshan.dc@gmail.com
website: www.anubikshan.com

PATIENT ID:2022K9025 NAME: PIJUSH MISHRA AGE:47 YR MALE
ADVISED BY:Dr. .M.O., BANK OF BARODA.,
DATE OF RECEIPT : 12/11/2022 DELIVERY DATE : 12/11/2022 TIME : 07:00 PM

HEAMATOLOGY TEST

TEST	RESULT	NORMAL RANGE
* Haemoglobin :-	14.2 gm/dl	14 - 18 gm/dl
* Total Leucocyte Count :-	6,800 /cu mm	4,000-11,000/cu mm
* Differential Leucocyte Count ::		
* -----		
Neutrophil	63 %	40-75%
Lymphocyte	33 %	20-45%
Monocyte	01 %	2-10%
Eosinophil	03 %	1-6%
Basophil	00 %	0-1%
* Erythrocyte Sedimentation	10 mm / 1st hour	Less than 15 mm (M) Less than 20 mm (F)
* P. C. V.	45 %	45.0-50.0% (M) 37.0-47.0% (F)
* M. C. V.	81.8 fl.	77-93 fl
* M. C. H.	25.8 pg.	27.0-32.0 pg
* M.C.H.C.	31.6 gm/dl.	31.0-35.0 gm/dl
* Platelet Count	1,76,000 /cu mm	1.5 - 4.0Lakh/cu mm
* R. B. C.	5.5 million/cu mm	6.0-8.0million/cu mm(M) 3.8-5.8million/cu mm(F)

All Reference ranges are age and sex matched. Reference limit mentioned herein are in accordance with the literature provided along with the kit. Which may change in chemistry or the kit.

DR. APARNA MONDAL.
M.B.B.S., M.D (Pathology)
(Regd. No. 57881)

DR. SWARUP GHOSH
M.B.B.S., M.D (Pathology)
(Regd. No. 52140)



ANUBIKSHAN

Diagnostic Centre

Near Asansol District Hospital(Main Gate)
S.B. Gorai Road, Asansol-713301
Email ID : anubikshan.dc@gmail.com
website: www.anubikshan.com

PATIENT ID:2022K9025 NAME: PIJUSH MISHRA AGE:47 YR MALE
ADVISED BY:Dr. .M.O., BANK OF BARODA.,
DATE OF RECEIPT : 12/11/2022 DELIVERY DATE : 12/11/2022 TIME : 07:00 PM

BIO CHEMISTRY REPORT

TEST	RESULT	NORMAL RANGE
Plasma Glucose (Fasting)	108.7 mg/dl	70 - 115 mg/dl
Plasma Glucose (P.P)	127.5 mg/dl	80 - 150 mg/dl
Uric-Acid	3.5 mg/dl	3.5 mg/dl - 7.2 mg/dl
Creatinine	0.96 mg/dl	0.7 - 1.4 mg/dl
Cholesterol	250.0 mg/dl	00 - 200 mg/dl
Triglyceride	110.0 mg/dl	0 - 200 mg/dl
HDL Cholesterol	40.0 mg/dl	30.0 - 90.0 mg/dl
LDL Cholesterol	188.0 mg/dl	00 - 130 mg/dl
V.L.D.L.	22.0 mg/dl	23 - 45 mg/dl
CHOLESTEROL/HDL RATIO	6.3 : 1	upto - 5.0
LDL/HDL RATIO	4.7 : 1	upto - 3.0
Serum Bilirubin(Total)	0.86 mg/dl	0.1 - 1.2 mg/dl
Serum Bilirubin (Direct)	0.34 mg/dl	0.0 - 0.4 mg/dl
Serum Bilirubin(Indirect)	0.52 mg/dl	UPTO - 0.8 mg/dl
S.G.P.T	95.6 U/L	00 - 45.0 U/L

All biochemistry done by fully automated system Diasys respons 910.

All Reference ranges are age and sex matched. Reference limit mentioned herein are in accordance with the literature provided along with the kit. Which may change in chemistry or the kit.

DR. APARNA MONDAL.
M.B.B.S., M.D (Pathology)
(Regd. No. 57881)

DR. SWARUP GHOSH
M.B.B.S., M.D (Pathology)
(Regd. No. 52140)



ANUBIKSHAN

Diagnostic Centre

Near Asansol District Hospital(Main Gate)
S.B. Gorai Road, Asansol-713301
Email ID : anubikshan.dc@gmail.com
website: www.anubikshan.com

PATIENT ID: 2022K9025 NAME: PIJUSH MISHRA AGE: 47 YR MALE
ADVISED BY: Dr. .M.O., BANK OF BARODA.,
DATE OF RECEIPT : 12/11/2022 DELIVERY DATE : 12/11/2022 TIME : 07:00 PM

BIO CHEMISTRY REPORT

TEST	RESULT	NORMAL RANGE
S.G.O.T	67.5 U/L	00 - 35.0 U/L
Alkaline Phosphatase	75.6 U/L	40 - 130 U/L
Total Protein	7.4 gm/dl	6.6 - 8.8 gm/dl
Albumin	4.2 gm/dl	3.5 - 5.2 gm/dl
Globulin	3.2 gm/dl	2.3 - 3.5 gm/dl
A : G	1.2:1	upto - 2.5:1
G.G.T	25 U/L	00 - 55 U/L

BUN/CREATININE RATIO:-

19:1

All biochemistry done by fully automated system Diasys respons 910.

All Reference ranges are age and sex matched. Reference limit mentioned herein are in accordance with the literature provided along with the kit. Which may change in chemistry or the kit.

DR. APARNA MONDAL.
M.B.B.S., M.D (Pathology)
(Regd. No. 57881)

DR. SWARUP GHOSH
M.B.B.S., M.D (Pathology)
(Regd. No. 52140)

Phone : 0341-2221195, Mobile : 9732362727, 7872772680



Pathology Department

REPORT ON EXAMINATION OF

GLYCOSYLATED HEMOGLOBIN

PATIENT'S NAME: - PIJUSH MISHRA	AGE: - 43 YEAR	SEX:- MALE
REF. BY DR.:- M.O. BANK OF BARODA.	DATE: - 12-11-2022	

HbA1C

<u>TEST</u>	<u>RESULT</u>	<u>NORMAL RANGE</u>
HbA1C	4.3 %	NON-DIABETIC - (<6%)
		GOOD CONTROL-(6.0%-7%)
		FAIR CONTROL- (7.1%-8%)
		POOR CONTROL- (>8%)

Alert: - Poor control may develop long term complications such as Retinopathy, Nephropathy, Neuropathy and Cardiopathy etc.

Comment: - MBG is a value calculated from HbA1c and indicator of average more or less glucose Level over past three months.

DR. APARNA MONDAL.
M.B.B.S., M.D (Pathology)
(Regd. No. 57881)

DR. SWARUP GHOSH
M.B.B.S., M.D (Pathology)
(Regd. No. 52140)



PATIENT ID: 2022K9025 NAME: PIJUSH MISHRA AGE: 47 YR MALE
ADVISED BY: Dr. .M.O., BANK OF BARODA.,
DATE OF RECEIPT : 12/11/2022 DELIVERY DATE : 12/11/2022 TIME : 07:00 PM

URINE ROUTINE EXAMINATION

PHYSICAL EXAMINATION

Colour : WATERY
S.P.Gravity : 1.010
Appearance : CLEAR
Sediment : NIL

CHEMICAL EXAMINATION

pH : 6.0
Protein : NIL
Sugar : NIL
Blood : NIL

MICROSCOPICAL EXAMINATION

R.B.C : NIL
Pus Cells : 0-1/HPF
Epithelial Cells : 1-2/HPF
Casts : NOT FOUND
Crystals : NOT FOUND
Bacteria : NOT FOUND
Others : NOT FOUND

All Reference ranges are age and sex matched. Reference limit mentioned herein are in accordance with the literature provided along with the kit. Which may change in chemistry or the kit.

DR. APARNA MONDAL.
M.B.B.S., M.D (Pathology)
(Regd. No. 57881)

DR. SWARUP GHOSH
M.B.B.S., M.D (Pathology)
(Regd. No. 52140)

Test Report



PIJUSH MISHRA

PID NO: P2242200021861
Age: 45.0 Year(s) Sex: Male



Reference: Dr.BANK OF BARODA

Sample Collected At:
Anubikshan Diagnostic Centre
Near Asansol District Hospital Main Gate,
Asansol : 713301
**Processing Location:-MHL ASANSOL
LAB West Apar Garden
G.T.Road,Asansol-713304**

VID: 220224000018845

Registered On:
12/11/2022 04:09 PM
Collected On:
12/11/2022 4:09PM
Reported On:
12/11/2022 05:00 PM

Investigation	Observed Value	Unit	Biological Reference Interval
Thyroid panel-1 (T3/T4/TSH) (Serum,ECLIA)			
T3 (Total)	107.5	ng/dL	84.63-201.8
T4 (Total)	6.13	µg/dL	5.13-14.06
TSH(Ultrasonensitive)	<u>5.41</u>	µIU/mL	0.54-5.3

INTERPRETATION

TSH	T3 / FT3	T4 / FT4	Suggested Interpretation for the Thyroid Function Tests Pattern
Within Range	Decreased	Within Range	• Isolated Low T3-often seen in elderly & associated Non-Thyroidal illness. In elderly the drop in T3 level can be upto 25%.
Raised	Within Range	Within Range	•Isolated High TSHespecially in the range of 4.7 to 15 mIU/ml is commonly associated with Physiological & Biological TSH Variability. •Subclinical Autoimmune Hypothyroidism •Intermittent T4 therapy for hypothyroidism •Recovery phase after Non-Thyroidal illness"
Raised	Decreased	Decreased	•Chronic Autoimmune Thyroiditis •Post thyroidectomy,Post radioiodine •Hypothyroid phase of transient thyroiditis"
Raised or within Range	Raised	Raised or within Range	•Interfering antibodies to thyroid hormones (anti-TPO antibodies) •Intermittent T4 therapy or T4 overdose •Drug interference- Amiodarone, Heparin,Beta blockers,steroids, anti-epileptics"
Decreased	Raised or within Range	Raised or within Range	•Isolated Low TSH -especially in the range of 0.1 to 0.4 often seen in elderly & associated with Non-Thyroidal illness •Subclinical Hyperthyroidism •Thyroxine ingestion"
Decreased	Decreased	Decreased	•Central Hypothyroidism •Non-Thyroidal illness •Recent treatment for Hyperthyroidism (TSH remains suppressed)"
Decreased	Raised	Raised	•Primary Hyperthyroidism (Graves' disease),Multinodular goitre, Toxic nodule •Transient thyroiditis:Postpartum, Silent (lymphocytic), Postviral (granulomatous,subacute, DeQuervain's),Gestational thyrotoxicosis with hyperemesis gravidarum"
Decreased or within Range	Raised	Within Range	•T3 toxicosis •Non-Thyroidal illness

- References:** 1. Interpretation of thyroid function tests. Dayan et al. THE LANCET • Vol 357 • February 24, 2001
2. Laboratory Evaluation of Thyroid Function, Indian Thyroid Guidelines, JAPI, January 2011,vol. 59

-- End of Report --

Results relate only to the sample as received. Refer to conditions of reporting overleaf *Am*

† This test was outsourced to Metropolis Healthcare Ltd. Mumbai Page 2 of 2 Dr. Satabdi.Mitra M.D (Pathology)



PIJUSH MISHRA

PID NO: P2242200021861
Age: 45.0 Year(s) Sex: Male



Reference: Dr.BANK OF BARODA
Sample Collected At:
Anubikshan Diagnostic Centre
Near Asansol District Hospital Main Gate,
Asansol : 713301
Processing Location:-MHL ASANSOL
LAB West Apcar Garden
G.T.Road,Asansol-713304


Test Report
VID: 220224000018845
Registered On:
12/11/2022 04:09 PM
Collected On:
12/11/2022 4:09PM
Reported On:
12/11/2022 05:00 PM

Investigation	Observed Value	Unit	Biological Reference Interval
PSA- Prostate Specific Antigen (Serum,ECLIA)	1.65	ng/mL	Conventional for all ages: 0 - 4 40 - 49 yrs: 0 - 2.5

Interpretation: Prostate-specific antigen (PSA) is a glycoprotein that is produced by the prostate gland, the lining of the urethra, and the bulbourethral gland. PSA exists in serum mainly in two forms, complexed to alpha-1-anti-chymotrypsin (PSA-ACT complex) and unbound (free PSA). Increases in prostatic glandular size and tissue damage caused by benign prostatic hypertrophy, prostatitis, or prostate cancer may increase circulating PSA levels. Transient increase in PSA can also be seen following per rectal digital or sonological examinations.

Comments: Patients on Biotin supplement may have interference in some immunoassays.

Reference: Arch Pathol Lab Med—Vol 141, November 2017. With individuals taking high dose Biotin (more than 5 mg per day) supplements, at least 8-hour wait time before blood draw is recommended.



Results relate only to the sample as received. Refer to conditions of reporting overleaf.

Sm
Dr. Satabdi.Mitra
M.D (Pathology)

† This test was outsourced to Metropolis Healthcare Ltd. Mumbai

Dr. Rajib Banerjee

B.Sc., B.H.M.S., DOS (Kol)
Consultant Homoeopathic Physician
and optometric Eye Specialist

ADDRESS :

1 No. Mohishila Colony
Bottala Bazar
Asansol - 3
Mob. : 9832197360

Rx

Pijush Mishra

Rt. Eye		Lt. Eye	
Sph	Cyl	Sph	Cyl
∅	∅	∅	∅
Near Add. →	∅	Near Add. →	∅

VA $\left\{ \begin{array}{l} \text{Gle (D)} \\ \text{Gle (D)} \end{array} \right.$

Near Vis - N9

with woglan -

VA $\left\{ \begin{array}{l} \text{Gle} \\ \text{Gle} \end{array} \right.$

Near Vis - N6

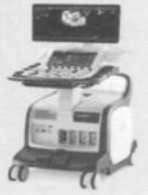CV - Normal

RMJ
12/11/22



Chamber
Balananda Homoeo Clinic
Khejurtala More
Mohishila - 2, Asansol

Morning : 8.00 a.m. to 9.00 a.m.
Evening : 6.00 p.m. to 9.30 p.m.
Saturday Evening Closed
& Sunday Morning Closed



ELECTRO CARDIO GRAM FORMAT

PATIENT NAME:- PIJUSH MISHRA	
AGE:- 45 YRS	GENDER:- MALE
REF BY DR:- M.O.BANK OF BARODA	DATE:- 12.11.2022

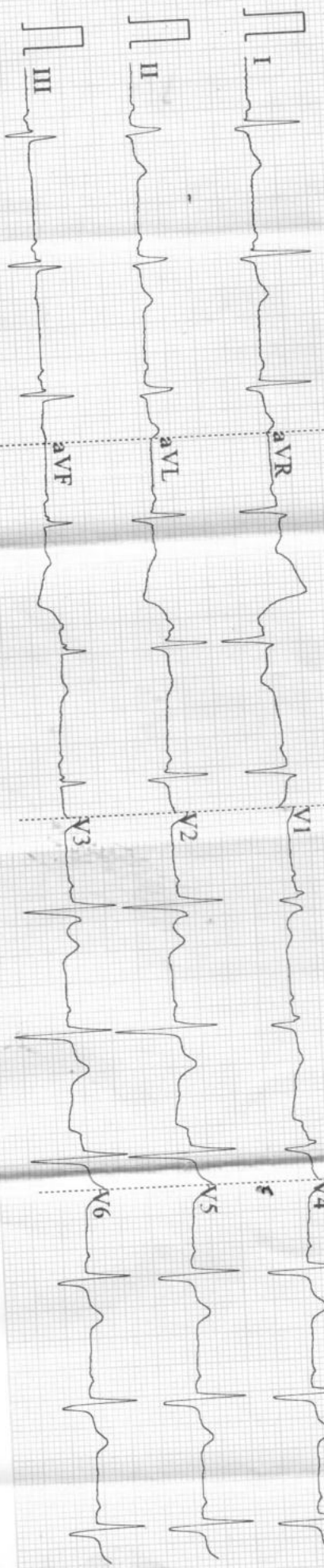
- ❖ **RATE** :- 70
- ❖ **AXIS** :- normal
- ❖ **P- WAVE** :- normal
- ❖ **P-R** :- normal
- ❖ **QRS** :- normal
- ❖ **ST - T** :- no change
- ❖ **T - WAVE** :-

➤ **IMPRESSION :-** within normal limits

[Signature]
Dr. Sunil Gupta
48372
WB

Dr. SUNIL GUPTA
MBBS MD (Medicine)
Reg No WBMC 48372

ID: 176 12-11-2022 09:54:40 AM



0.67~35Hz AC50 25mm/s 10mm/mV 67

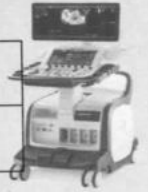V1.0 SEMIP V1.7

CARDIART

BPL



PATIENT'S NAME:- PIJUSH MISRA	AGE:- 47 YEARS	SEX:- MALE
REFERRED BY DR:- M.O. BANK OF BARODA.	DATE:- 17.11.2022	



Transthoracic Echo 2-D/M-Mode, Echo Report

2-D/ M-Mode Measurements :(mm.)

	Observed Values(mm)	Normal Values(mm)
Aortic root diameter	30.40	20 – 36 mm
Left Atrium Size	38.00	19 – 40 mm

	End Diastolic(mm)	End Systolic(mm)	Normal Values(mm)
Interventricular Septum	9.88	15.96	ED=6-10
Left Ventricle Size	53.20	32.68	ED=37-53; ES=22-40
Posterior Wall Thickness	10.64	19.00	ED=5-10

LV Ejection Fraction (%)	68.43 %	55 – 80%
--------------------------	---------	----------

❖ FINDINGS :-

1. No LV Regional Wall Motion Abnormality, Global LVEF is 68.43%.
2. Normal Cardiac chambers dimension.
3. All valves normal.
4. Normal L.V. Compliance.
5. No intracardiac clot/veg.
6. No pericardial effusion.
7. Normal RV systolic function.

❖ IMPRESSION:-

❖ **NORMAL 2D ECHOCARDIOGRAPHY.**

DR. KAUSHIK SUR.
(M.B.B.S., M.D., D.M)

(Sr. Consultant Interventional Cardiologist
(Regd. No: - WB-62545)

PATIENT'S NAME: - PIJUSH MISRA

AGE:- 47 YEAR SEX:- MALE

REF BY DR: - M.O. BANK OF BARODA.

DATE:- 17.11.2022

2D ECHO DONE BY :-

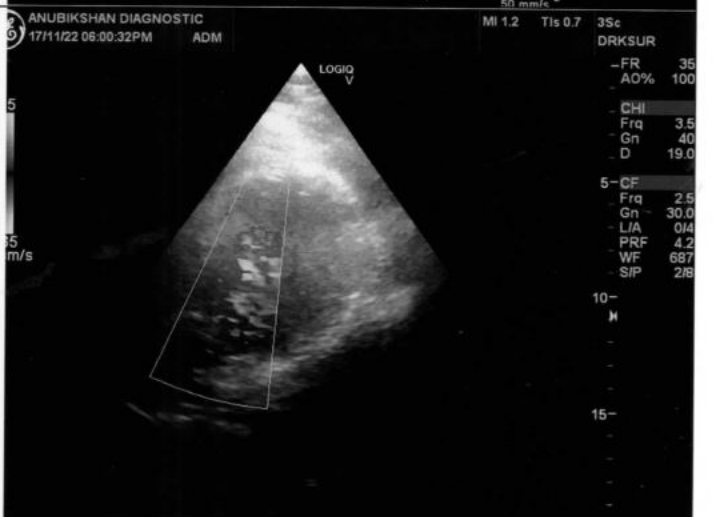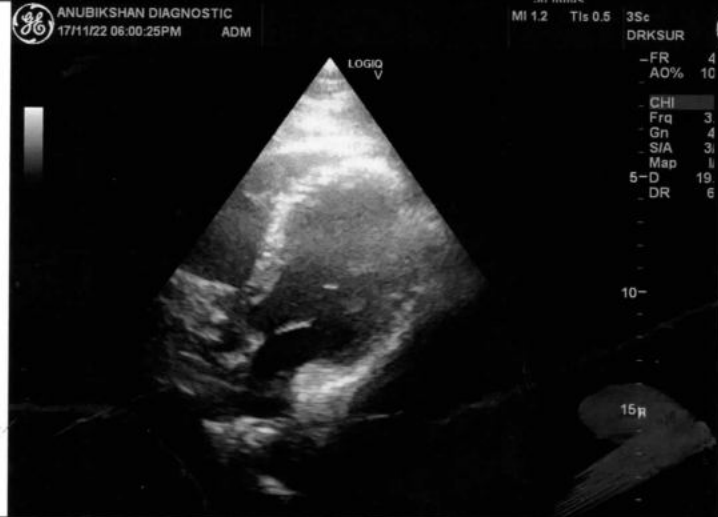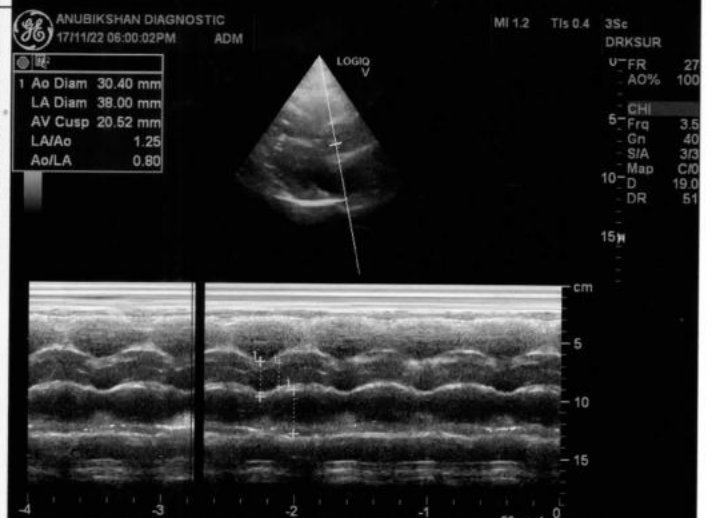
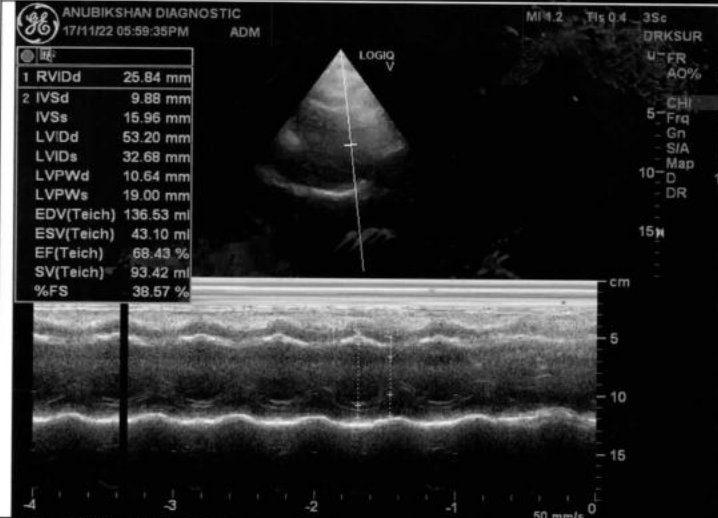
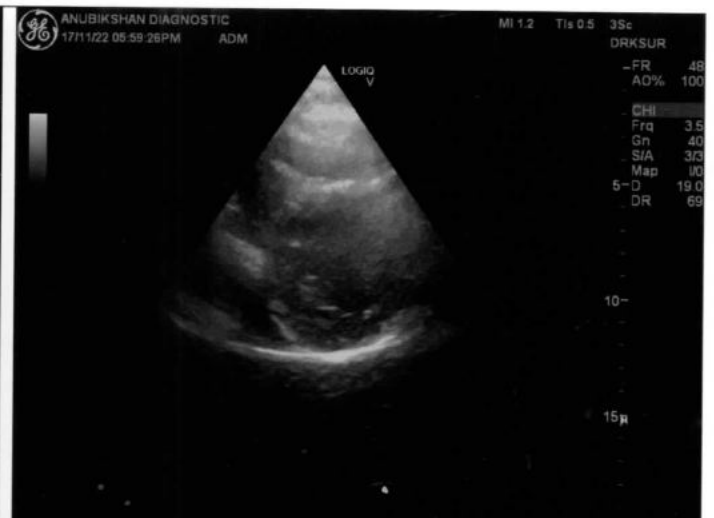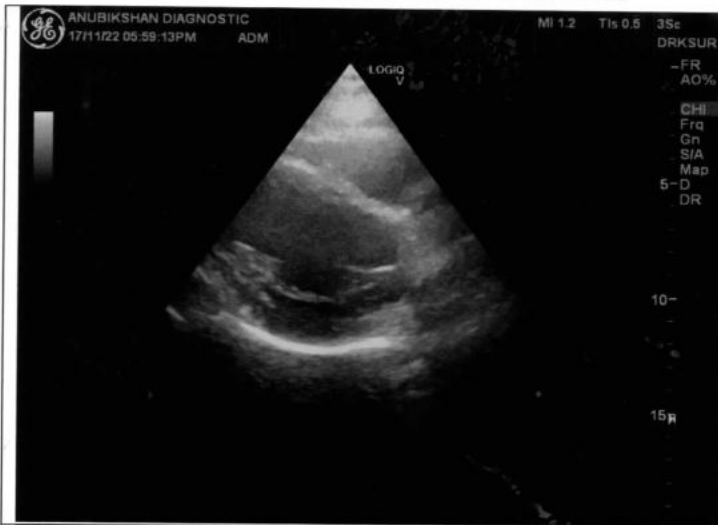DR. KAUSHIK SUR (MD, DM) (CARDIOLOGIST)

ANUBIKSHAN DIAGNOSTIC CENTRE

NEAR ASANSOL DISTRICT HOSPITAL (MAIN GATE)
S.B.GORAI ROAD (EAST), PIN - 713301

LANDLINE: - 0341-3590332 // MOB - 7872772680

E-mail add: - anubikshan.dc@gmail.com



PATIENT'S NAME: - PIJUSH MISRA

AGE:- 47 YEAR SEX:- MALE

REF BY DR: - M.O. BANK OF BARODA.

DATE:- 17.11.2022

2D ECHO DONE BY :-

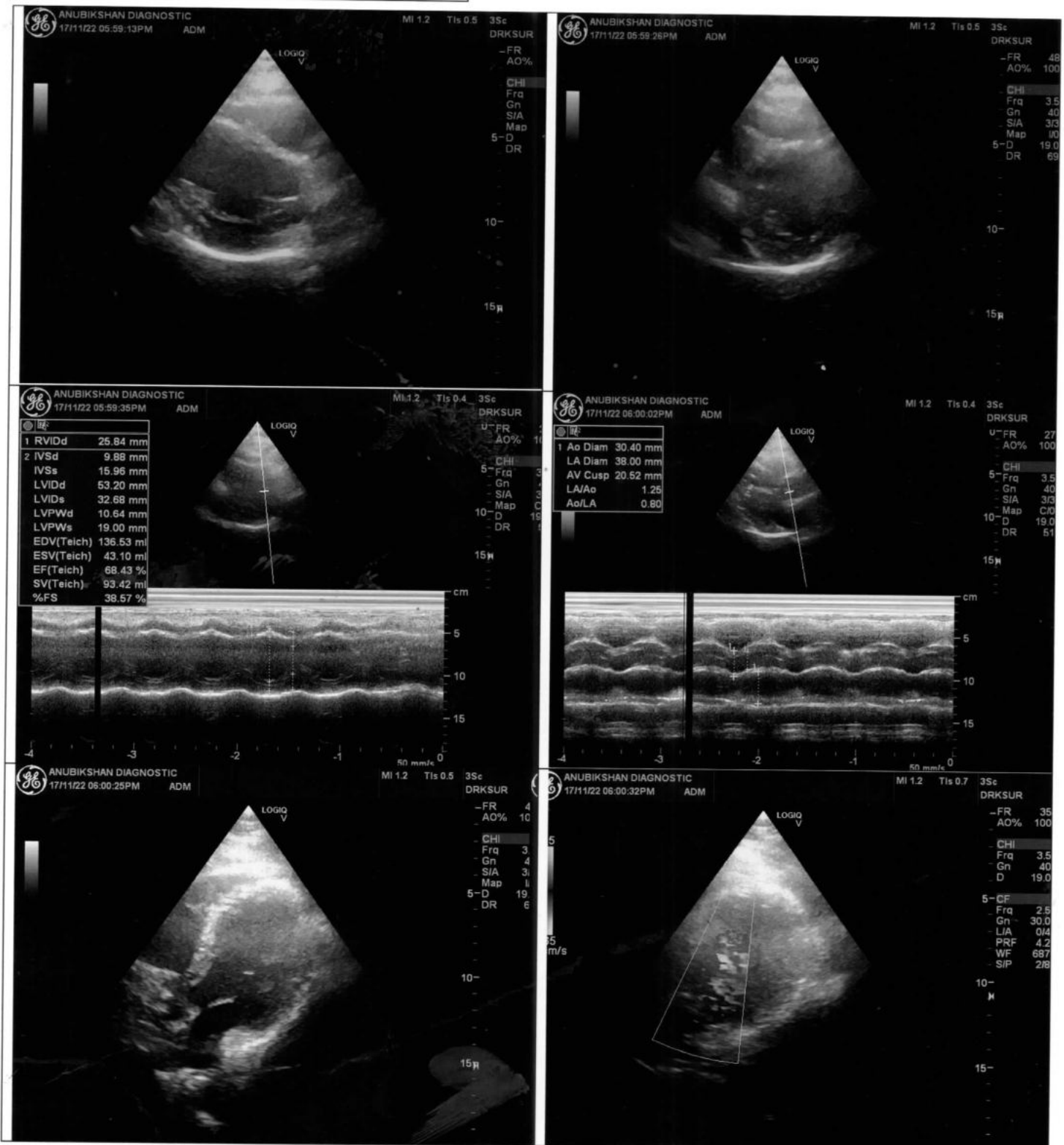
DR. KAUSHIK SUR (MD, DM) (CARDIOLOGIST)

ANUBIKSHAN DIAGNOSTIC CENTRE

NEAR ASANSOL DISTRICT HOSPITAL (MAIN GATE)
S.B.GORAI ROAD (EAST), PIN - 713301

LANDLINE: - 0341-3590332 // MOB - 7872772680

E-mail add: - anubikshan.dc@gmail.com





PATIENT'S NAME: - PIJUSH MISHRA AGE: - 47 YEAR GENDER: - MALE

REFERRED BY DR.:- BANK OF BARODA. DATE: - 18.11.2022

U.S.G OF WHOLE ABDOMEN

LIVER

Mild to moderate fatty changes in liver. (Measure:- 144.36 mm.)

PORTA VEIN

Portal vein at porta hepatis measures:- 7.04 mm. in diameter.
The appearance of porta is normal.

GALL BLADDER

Normal shape, size and position of the Gall Bladder is seen.
No calculus or any intraluminal mass is seen.

COMMON BILEDUCT

Common bile duct is not dilated (1.18 mm.)
No calculus or any intraluminal echogenicity.

PANCREAS

Normal echo-texture of the pancreas is seen. No space occupying lesion is seen.
Its relation with the anatomical landmark is normal.

SPLEEN

Normal dimension of the spleen is seen. It shows normal echo-texture.
No space occupying lesion is seen in the spleen.(Measure:- 95.77 mm.)

RIGHT KIDNEY

Both the kidneys are normal in shape, size, margin and axis.
Cortico medullary differentiation is normal.
No calculi opacity or any hydronephrotic changes noted.
(Rt. Kidney Measure:- 105.13 mm. and Lt. Kidney Measure:- 111.28 mm. in length.)

URINARY BLADDER

Normal shape and size of the urinary bladder is seen.
No intraluminal echo is noted.

PROSTATE

Normal shape & size. (Measure: - 30.97 mm x 27.00 mm x 31.16 mm = 13.64 ml)

➤ IMPRESSION :-

➤ Mild to moderate fatty changes in liver otherwise normal study.

ADVICE

Clinical co-relation.

DR. DIPANKAR DASGUPTA.
(M.B.B.S., D.M.R.D)
(Regd.No:- WB-34374)

PATIENT'S NAME:- PIJUSH MISHRA

AGE:- 43 YEAR SEX:- MALE

REF BY DR:- BANK OF BARODA.

DATE:- 18.11.2022

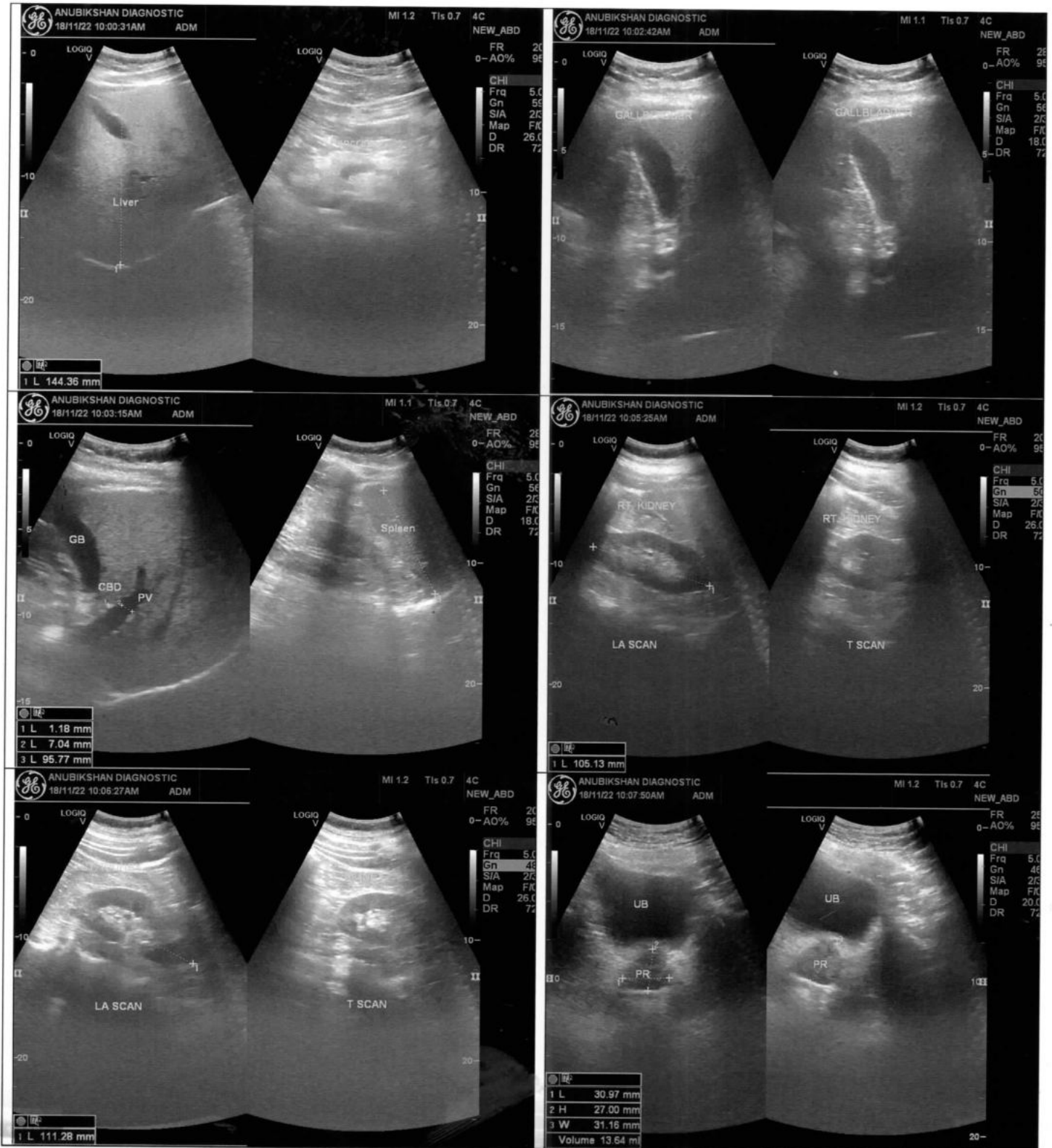
U.S.G. OF WHOLE ABDOMEN

ANUBIKSHAN DIAGNOSTIC CENTRE

**NEAR ASANSOL DISTRICT HOSPITAL (MAIN GATE)
S.B.GORAI ROAD (EAST), PIN - 713301**

LANDLINE: - 0341-3590332 // MOB - 7872772680

E- mail ID: - anubikshan.dc@gmail.com





PATIENT'S NAME: - PIJUSH MISHRA

AGE: - 43 YEAR

GENDER: - MALE

REFERED BY DR: - M.O. BANK OF BARODA.

DATE: - 12.11.2022

REPORT

CHEST X – RAY P A VIEW

Soft tissue around chest and bony cage --- normal.

No active lung lesion in either field.

Cardiac configuration normal.

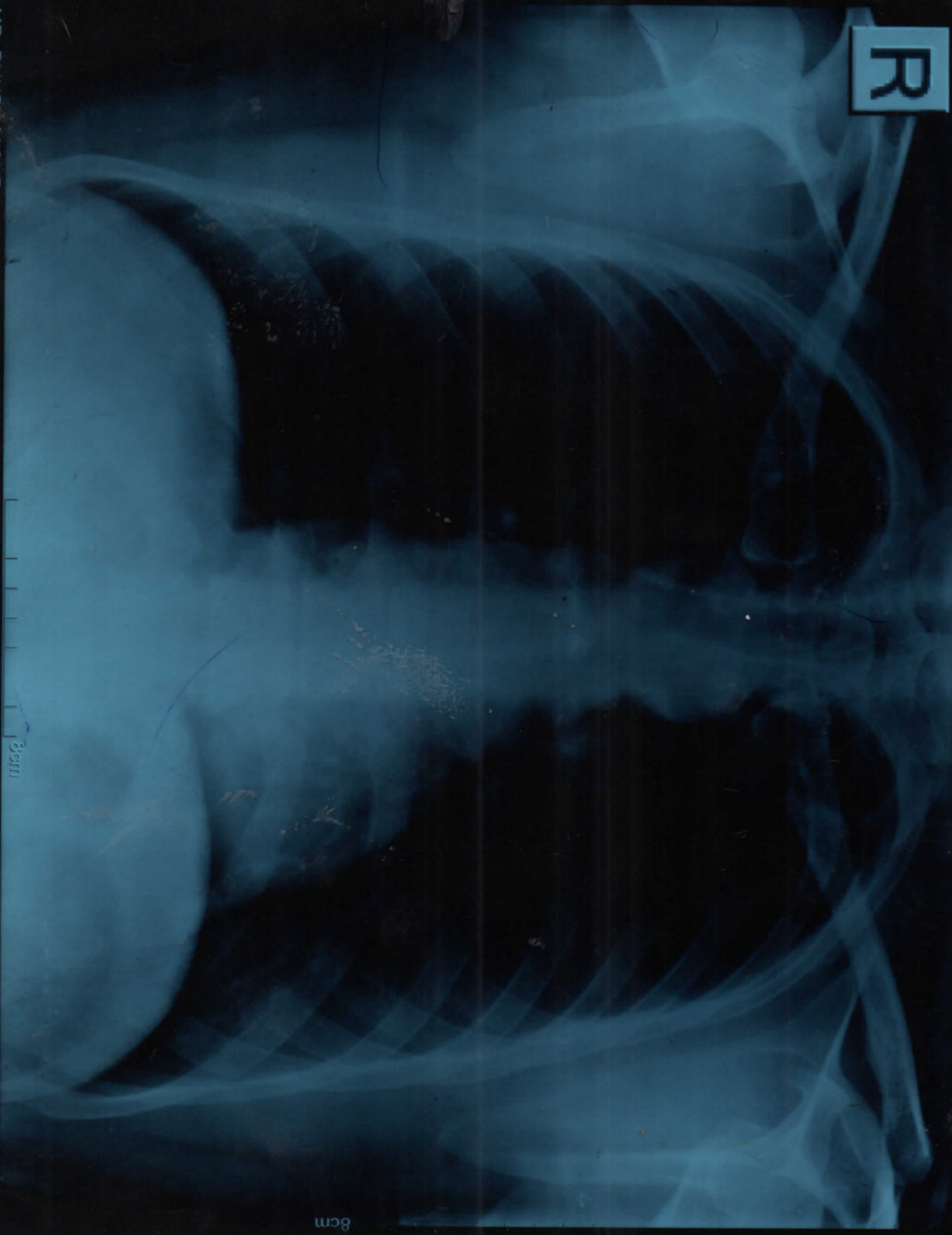
Pleural recesses are clear.

I M P R E S T I O N

✓ **NORMAL SKIAGRAM OF CHEST.**

DR. DIPANKAR DASGUPTA.
(M.B.B.S., D.M.R.D)
(Regd.No:- WB-34374)

R



MR. PUJUSH MISHRA 43Y Male
NEW ASANSOL X RAY CLINIC. MOB-9434236862

Self
12/11/2022