

Facilities:
All clinical Biomedical & Hematology Investigations
including Bone Marrow Examination
VPT, Podiascan & Complete Foot Care (First Time in Purvanchal)
All Hormonal Investigation by Chemiluminescent Method
Visceral Fat by (AB-140) Ambulatory BP Monitoring
CGMS & Insulin Pump Available
PFT, 2D-ECHO (Color Doppler), Holter, TMT, Cardiac-3 available
VIA, VILI, Colposcopy available
Special Endocrinological Investigation Protocols.

ISO 9001:2008 Certified
Mobile: 9389994334, 9554572190, 9453837595



Panacea Pathology Clinical Reference Lab

Persistence, Preparedness and Precision
EQAS (CMC Vellore Attached) & IQAS System
पूर्वांचल की सर्वोत्तम गुणवत्ता वाली पैथोलॉजी

PATIENT NAME : BABLU KUMAR JAISWAL	AGE/GENDER : 39YRS/MALE
REFD BY DR. : ARCO FEMI HEALTHCARE LTD.	RECEIVED DATE :21-03-2023 (09:00AM)
SAMPLE : BLOOD & URINE	REPORT DATE :21-03-2023 (07:00PM)

PATHOLOGY REPORT

COMPLETE BLOOD COUNT (CBC)

TEST	LAB TEST VALUES	NORMAL RANGE
HEMOGRAM		
HEMOGLOBIN (FLOW CYTOMETRY)	16.2	13 – 16 gm/dl
TOTAL LEUCOCYTE COUNT (TLC)	3,800	4000 – 11000
RBC COUNT	5.15	3.5 – 5.5
PCV (HCT)	49.2	37 – 47
MCV	95.5	80 – 95
MCH	31.5	28 – 34
MCHC	32.9	30 – 36
PLATELET COUNT	1,87,000	1,50,000 – 4,00,000
E.S.R. (WINTROBE FIRST HOURS)	10.0	20 mm/1 st hr
DIFFERENTIAL LEUCOCYTE		
NEUTROPHILS	47	40 – 75%
LYMPHOCYTES	40	20 – 45%
EOSINOPHILS	07	1 – 6%
MONOCYTES	06	2 – 8%
BASOPHILS	00	< 2 %

RANDOM/FASTING BLOOD SUGAR

TEST	LAB TEST VALUES	NORMAL RANGE
RBS/FBS		
RANDOM BLOOD SUGAR		125-140 mg/dl
FASTING BLOOD SUGAR	77.2	70-125 mg/dl

GLYCOSYLATED HEMOGLOBIN (HBA1C)

TEST	LAB TEST VALUES	NORMAL RANGE
HBA1C	5.3	Normal : <5.97 % Good Control : 5.97 – 6.81% Fair Control : 6.81 – 7.65% Poor Control : >7.65%

PAGE 1

Lab Technician

M.D., Pathology

Timing : 8.00 a.m. to 9.00 p.m. (Sunday 8.00 a.m. to 3.00 p.m.)

This Report is not valid for medico legal purpose

Note: These tests have technical limitations. Clinico-pathological interpretation is necessary. In case of any disparity test may be repeated immediately.

Address : 36/44 FK Kabir Nagar, Durgakund, Varanasi – 221005

Email: dramishra@gmail.com, drpallaviojha@gmail.com Website: panaceahospital.org

Facilities:
 All clinical Biomedical & Hematology Investigations
 including Bone Marrow Examination
 VPT, Podiascan & Complete Foot Care (First Time in Purvanchal)
 All Hormonal Investigation by Chemiluminescent Method
 Visceral Fat by (AB-140) Ambulatory BP Monitoring
 CGMS & Insulin Pump Available
 PFT, 2D-ECHO (Color Doppler), Holter, TMT, Cardiac-3 available
 VIA, VILI, Colposcopy available
 Special Endocrinological Investigation Protocols.

ISO 9001:2008 Certified
 Mobile: 9389994334, 9554572190, 9453837595



Panacea Pathology Clinical Reference Lab

Persistence, Preparedness and Precision
 EQAS (CMC Vellore Attached) & IQAS System
 पूर्वांचल की सर्वोत्तम गुणवत्ता वाली पैथोलॉजी

PATIENT NAME : BABLU KUMAR JAISWAL	AGE/GENDER : 39YRS/MALE
REFD BY DR. : ARCO FEMI HEALTHCARE LTD.	RECEIVED DATE :21-03-2023 (09:00AM)
SAMPLE : BLOOD & URINE	REPORT DATE :21-03-2023 (07:00PM)

PATHOLOGY REPORT

LIPID PROFILE, SERUM

TEST	LAB TEST VALUES	NORMAL RANGE
BLOOD CHEMISTRY		
TOTAL CHOLESTEROL (SERUM)	174.0	Desirable:- < 200 mg/dl Borderline:- 200 – 239 mg/dl High:- > 240 mg/dl
TRIGLYCERIDES (SERUM)	168.0	35 – 170 mg/dl
HDL CHOLESTEROL (SERUM)	46.0	35.30 – 79.50 mg/dl
LDL CHOLESTEROL (SERUM)	94.4	< 130 mg/dl
VLDL	33.6	< 40 mg/dl
CHOLESTROL/HDL RATIO	3.78	< 3.0 Low Risk Ratio 3.0 – 5.0 Avg Risk > 5.0 High Risk
LDL/HDL RATIO	2.05	< 3 Ratio

BLOOD GROUP

TEST	LAB TEST VALUES
BLOOD GROUP ABO & RH FACTOR	
BLOOD GROUP	"B"
RH FACTOR	POSITIVE

LIVER PROFILE TEST, SERUM

TEST	LAB TEST VALUES	NORMAL RANGE
BIO CHEMISTRY		
TOTAL BILIRUBIN	0.68	0.0 – 1.1 mg/dl
DIRECT BILIRUBIN	0.25	0.0 – 0.2 mg/dl
INDIRECT BILIRUBIN	0.43	< 0.90 mg/dl
SGOT (AST)	24.0	0 – 52 mg/dl
SGPT (ALT)	26.0	0 – 39 mg/dl
GGT (GYT)	23.0	< 55 U/L

THYROID PROFILE (T3, T4, TSH)

TEST	LAB TEST VALUES	NORMAL RANGE
THYROID FUNCTION TEST		
T3	1.12	0.60 – 1.81 ng/ml
T4	7.56	4.50 – 10.90 ug/dl
TSH	2.14	0.39 – 6.10 uIU/mL

PAGE 2

Lab Technician

M.D., Pathology

Timing : 8.00 a.m. to 9.00 p.m. (Sunday 8.00 a.m. to 3.00 p.m.)

This Report is not valid for medico legal purpose

Note: These tests have technical limitations. Clinico-pathological interpretation is necessary. In case of any disparity test may be repeated immediately.

Address : 36/44 FK Kabir Nagar, Durgakund, Varanasi – 221005

Email: dramishra@gmail.com, drpallaviojha@gmail.com Website: panaceahospital.org

Facilities:
 All clinical Biomedical & Hematology Investigations
 including Bone Marrow Examination
 VPT, Podiascan & Complete Foot Care (First Time in Purvanchal)
 All Hormonal Investigation by Chemiluminescent Method
 Visceral Fat by (AB-140) Ambulatory BP Monitoring
 CGMS & Insulin Pump Available
 PFT, 2D-ECHO (Color Doppler), Holter, TMT, Cardiac-3 available
 VIA, VILI, Colposcopy available
 Special Endocrinological Investigation Protocols.

ISO 9001:2008 Certified
 Mobile: 9389994334, 9554572190, 9453837595



Panacea Pathology Clinical Reference Lab

Persistence, Preparedness and Precision
 EQAS (CMC Vellore Attached) & IQAS System
 पूर्वांचल की सर्वोत्तम गुणवत्ता वाली पैथोलॉजी

PATIENT NAME : BABLU KUMAR JAISWAL	AGE/GENDER : 39YRS/MALE
REFD BY DR. : ARCO FEMI HEALTHCARE LTD.	RECEIVED DATE :21-03-2023 (09:00AM)
SAMPLE : BLOOD & URINE	REPORT DATE :21-03-2023 (07:00PM)

PATHOLOGY REPORT

RENAL & KIDNEY PROFILE, SERUM

TEST	LAB TEST VALUES	NORMAL RANGE
RENAL FUNCTION TESTS		
BLOOD UREA NITROGEN (BUN)	10.4	10 – 50 mg/dl
SERUM CREATININE	0.97	0.60 – 1.60 mg/dl
URIC ACID	3.56	3.60 – 7.70 mg/dl
ALKALINE PHOSPHATASE (ALP)	72.0	142 – 353 mg/dl
TOTAL PROTIENS	7.54	0 – 39 mg/dl
ALBUMIN	4.24	3.8 – 5.4 mg/dl
SERUM GLOBULIN	3.30	2.1 – 3.5 mg/dl
CALCIUM	9.02	8.80 – 10.20
PHOSPHORUS	3.04	2.50 – 5.00
SERUM SODIUM NA+	137.6	135.00 – 155.00 mEq/Ltr
SERUM POTASIUM K+	4.32	3.60 – 5.50 mEq/Ltr
ICALCIUM	1.24	1.10 – 1.35 mmol/L
SERUM CHLORIDE CL+	105.9	98.00 – 110.00 mEq/Ltr

URINE ROUTINE EXAMINATION

TEST	LAB TEST VALUES	NORMAL RANGE
PHYSICAL EXAMINATION		
QUANTITY	30	ML
COLOUR	STRAW	PALE YELLOW
APPEARANCE	CLEAR	CLEAR
SPECIFIC GRAVITY	1.010	1.01 – 1.03
PH	6.0	4.7 – 7.5
CHEMICAL EXAMINATION		
GLUCOSE	Not Detected	Not Detected
PROTEIN	NIL	Not Detected
MICROSCOPIC EXAMINATION		
PUS CELLS	NIL	0-5
RBC	Not Detected	Not Detected
EPITHELIAL CELLS	01-05	0-5
CASTS	Not Detected	Not Detected
CRYSTALS	Not Detected	Not Detected
BACTERIA	Not Detected	Not Detected

----- End of Report -----

Lab Technician

M.D., Pathology

Timing : 8.00 a.m. to 9.00 p.m. (Sunday 8.00 a.m. to 3.00 p.m.)

This Report is not valid for medico legal purpose

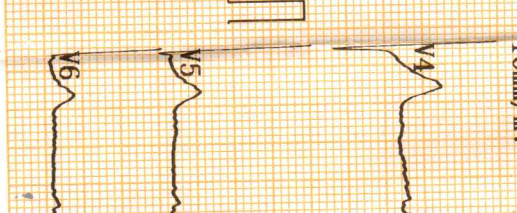
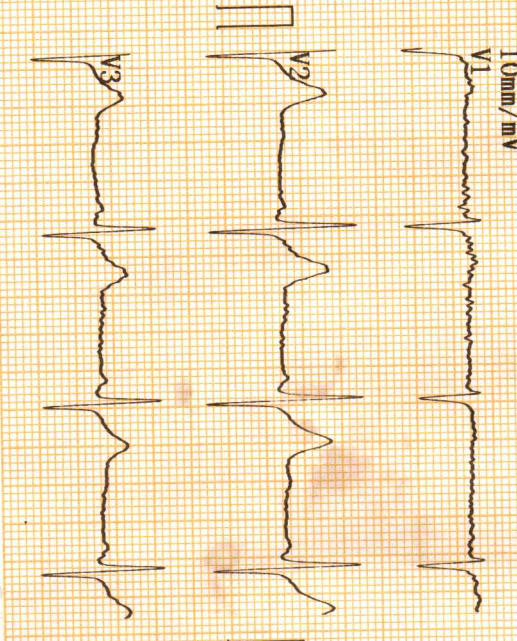
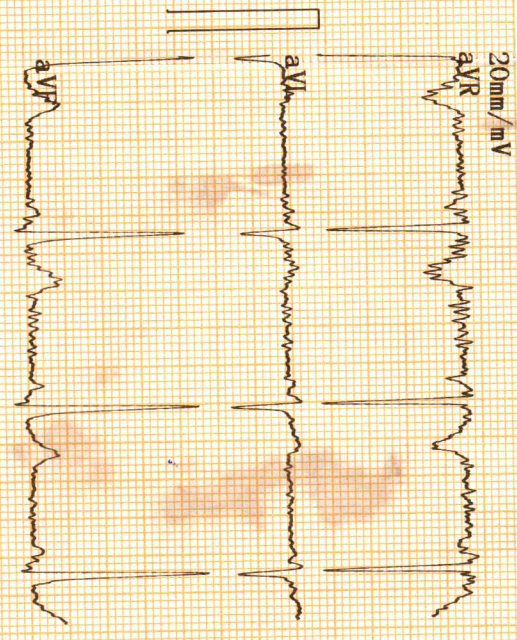
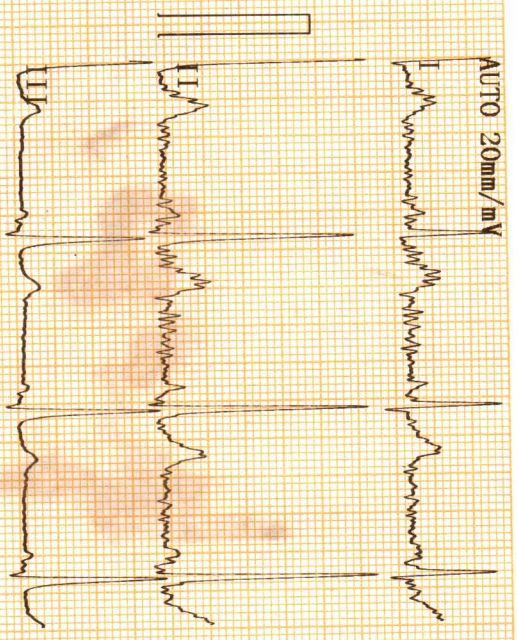
Note: These tests have technical limitations. Clinico-pathological interpretation is necessary. In case of any disparity test may be repeated immediately.

Address : 36/44 FK Kabir Nagar, Durgakund, Varanasi – 221005

Email: dramishra@gmail.com, drpallaviojha@gmail.com Website: panaceahospital.org

25mm/s ACS50Hz+EMG35Hz+DFT

CARDIART



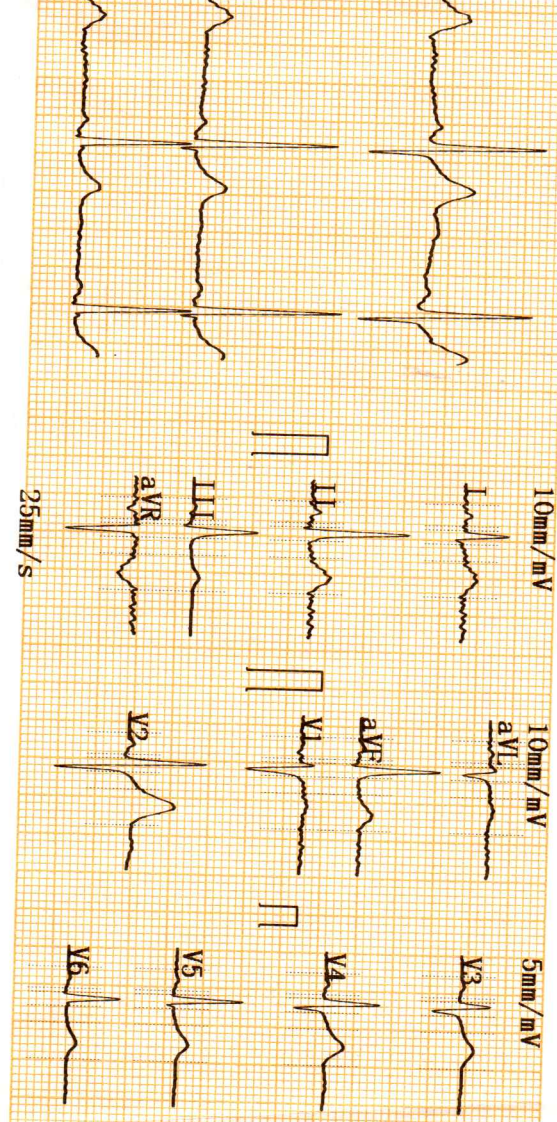
AUTO 20mm/mV

20mm/mV

10mm/mV

10mm/mV

BPL



2022-03-21 10:22

ID :
 Name :
 Sex :
 Height :
 SYS :
 DIA :
 HR : 66 bpm
 PR Interval : 143 ms
 P Duration : 120 ms
 QRS Duration : 75 ms
 T Duration : 193 ms
 QT/QTc : 359/377 ms
 P/QRS/T Axis : 74.9/74.4/58.1 deg
 R(V5)/S(V1) : 1.83/0.71 mV
 R(V5)+S(V1) : 2.54 mV

<< Conclusions >>

Normal Sinus Rhythm;
 Cardiac electric axis normal;

Age :
 Weight : kg **Report need physician confirm**

CARDIART

Physician

Palla
 DR. PALLAVI MISHRA
 MBBS-MD (GENERAL MEDICINE)
 MCI Reg. No. 52033



Call Now - 1800-123-3070

PANACEA HOSPITAL

A shelter for many hearts A Home for many lives

(An ISO 9001:2008 Certified Organisation)

Lab Attached with CMC Vellore Under EQAS Scheme

PATIENT'S NAME : BABLOO KUMAR JAISWAL

AGE/SEX: 39 Y/M

REF. BY : Dr. ASHUTOSH MISHRA(MD)

Tuesday, March 21, 2023


Echo - Cardiography

MITRAL VALVE Doppler	AML - normal morphology MV Flow - E - 0.7 A-0.5 E/A=1.25	PML - normal morphology MVA - 3.0 cm ² Mitral Regurgitation - No
TRICUSPID VALVE Doppler	Normal TV Flow -No	Tricuspid Regurgitation - No
PULMONARY VALVE Doppler	Normal PV Flow -No	Pulmonary Regurgitation - No
AORTIC VALVE Doppler	Trileaflet-No AV Flow - no	Aortic Regurgitation - no
MEASUREMENT	Aorta - 26.8 (20-38) mm IVS ed - 14.3 (6 -12) mm LVID ed - 49.7 (35 - 55) mm LVPW ed - 12.0 (6 -12) mm OA - 7 (> 5) mm	LA - 35.4 (24-32) mm IVS es -15.4 (6 - 12) mm LVID es - 34.3 (24 - 40) mm LVPW es - 13.7 (6 -12) mm EPSS - 4 (< 9) mm


CONCLUSION All cardiac chamber dimensions are WNL
No valvular abnormalities
Good LV systolic function present Modified Simpson's method (4C, 2C) (LVEF-59%)
No diastolic dysfunction present (E/A = 1.25) by tissue Doppler (E/e'=6.2)
No RWMA
No pericardial effusion
Intact IAS / IV
No PAH
No intra cardiac mass /thrombus /vegetation

IMPRESSION

Normal Echocardiogram


Niraj Mishra
Physician Assistant
(PIIRE)

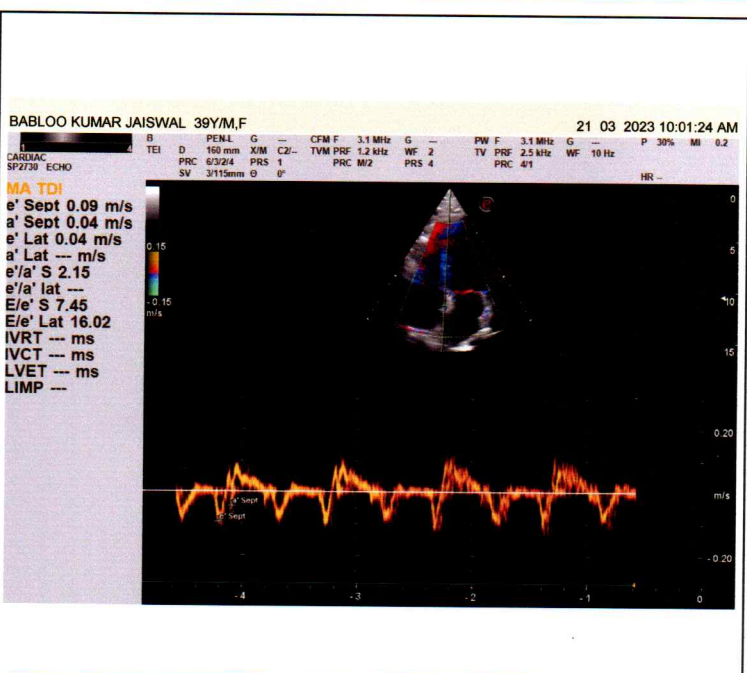
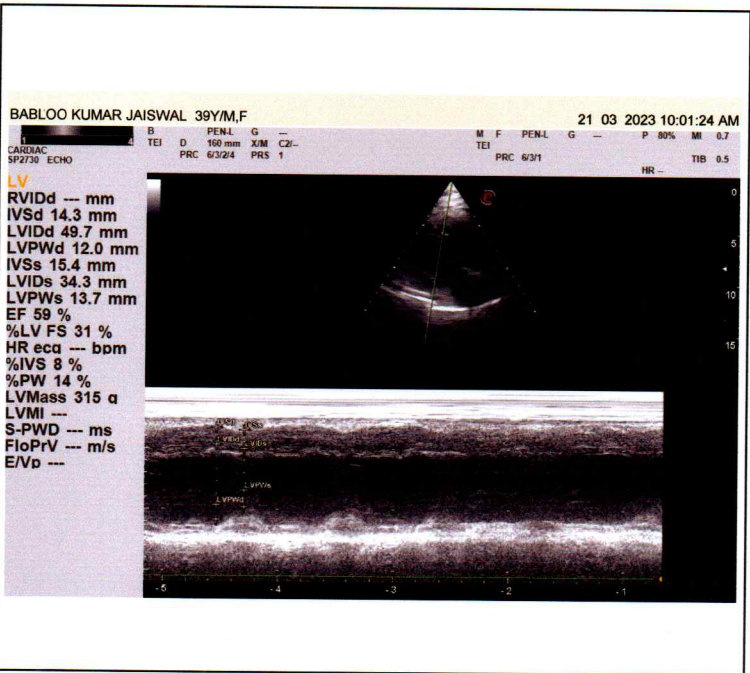
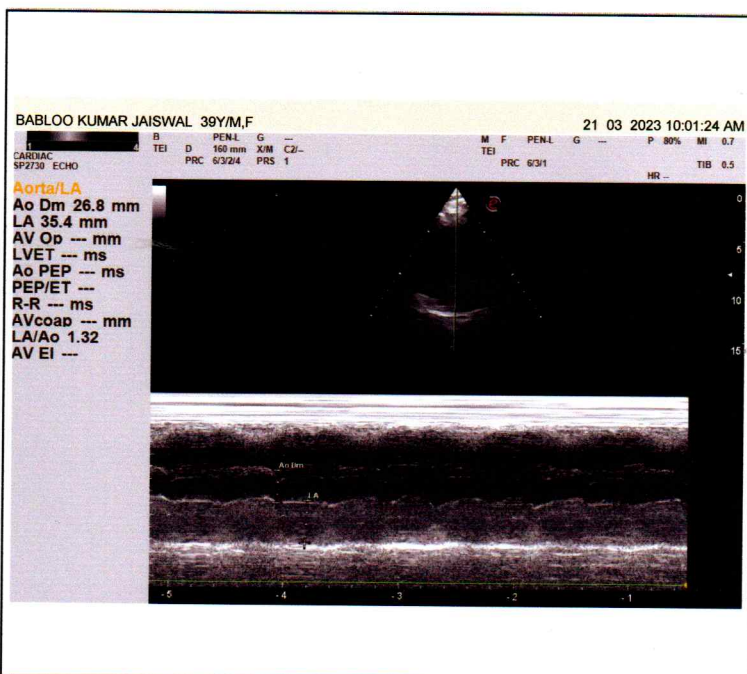
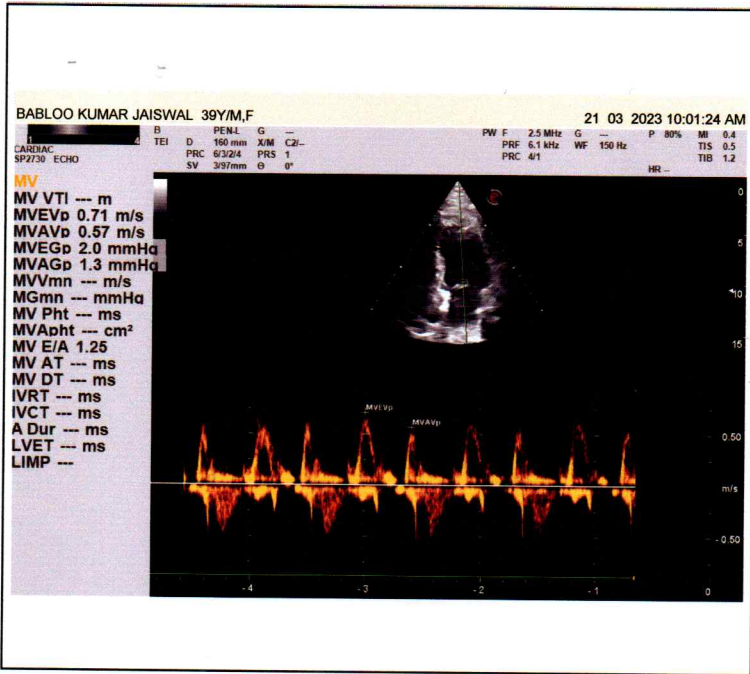
DR. PALLAVI MISHRA
MBBS, MD (GENERAL MEDICINE)
MCI Reg. No. 5292333


Dr. Pallavi Mishra
MBBS, MD (MED) Lucknow
Echocardiography Specialist, MIAE
Non-invasive cardiologist
Women Cardiologist
Diabetocardiologist

Address : Kabir Nagar (Near Sanjay Shiksha Niketan), Durgakund, Varanasi

Mobile : 9554572190 / 9453837595 / Recpn. 9389994334

E-mail : dramishra@gmail.com, drpallaviojha@gmail.com, Website: www.piire.org





Call Now - 1800-123-3070

PANACEA HOSPITAL

A shelter for many hearts A Home for many lives


(An ISO 9001:2008 Certified Organisation)

Lab Attached with CMC Vellore Under EQAS Scheme

PATIENT'S NAME : BABLOO KUMAR JAISWAL	AGE/SEX: 39 Y/M
REF. BY : Dr. ASHUTOSH MISHRA(MD)	Tuesday, March 21, 2023

U/S. WHOLE ABDOMEN

- LIVER** : Liver is normal in size, **Diffuse increased echogenicity of liver parenchyma - Grade I fatty liver.** Intra hepatic biliary radicals are normal. Portal venous channels are normal.
- G. B.** : Gall bladder is normal in size, lumen is clear. Wall thickness normal.
- C.B.D.** : C.B.D. is normal in caliber.
- PANCREAS** : Pancreas is normal in size, shape and echotexture. No evidence of any inflammatory disease or mass.
- SPLEEN** : Spleen is normal in size, shape and echotexture.
- Rt. KIDNEY** : Normal in size, shape and echotexture. Renal sinus is normal
Cortico medullary differentiation is normal. P. C. system is normal.
- Lt. KIDNEY** : Normal in size, shape and echotexture. Renal sinus is normal
Cortico medullary differentiation is normal. P. C. system is normal.
- URI. BLADDER** : Urinary bladder is normal in size, position. Wall thickness normal.
- PROSTATE** : Prostate is normal in size.
No ascites & retro peritoneal lymphadenopathy seen.
- IMPRESSION** : **Grade I fatty liver.**

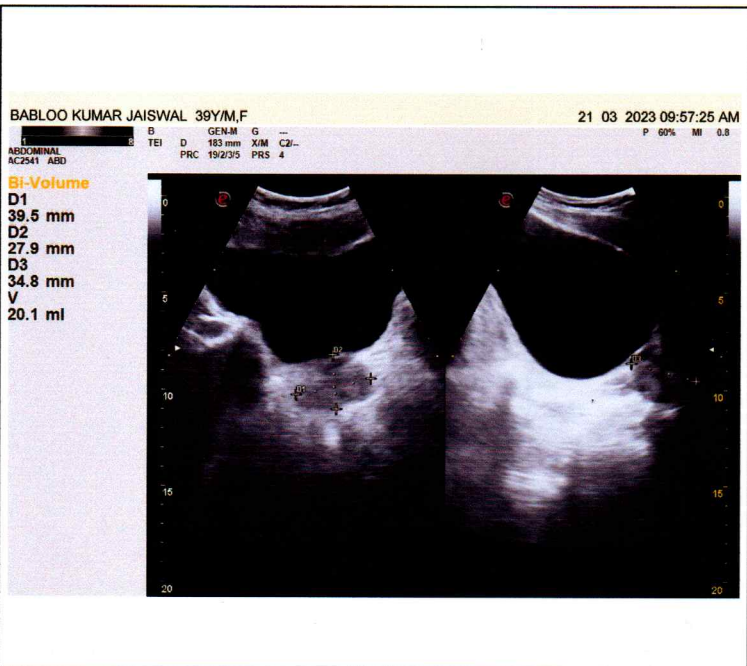
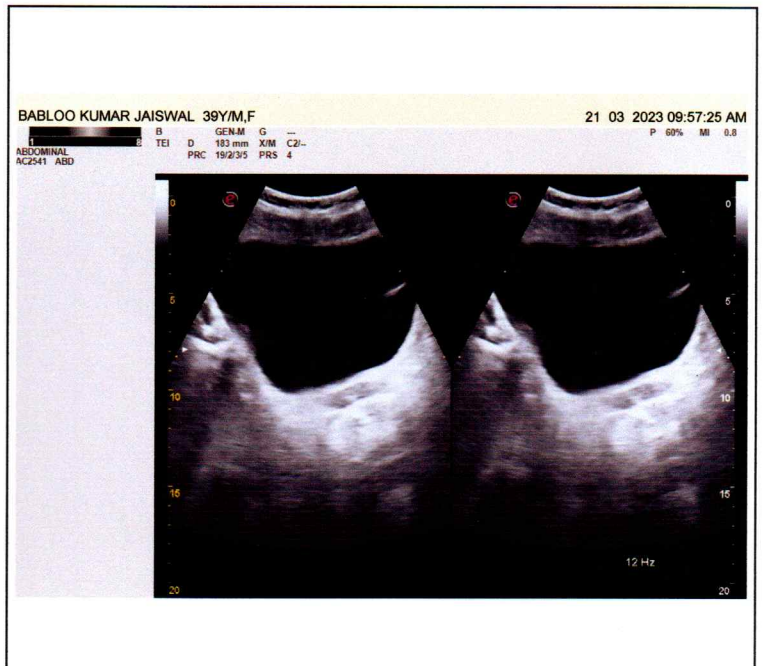
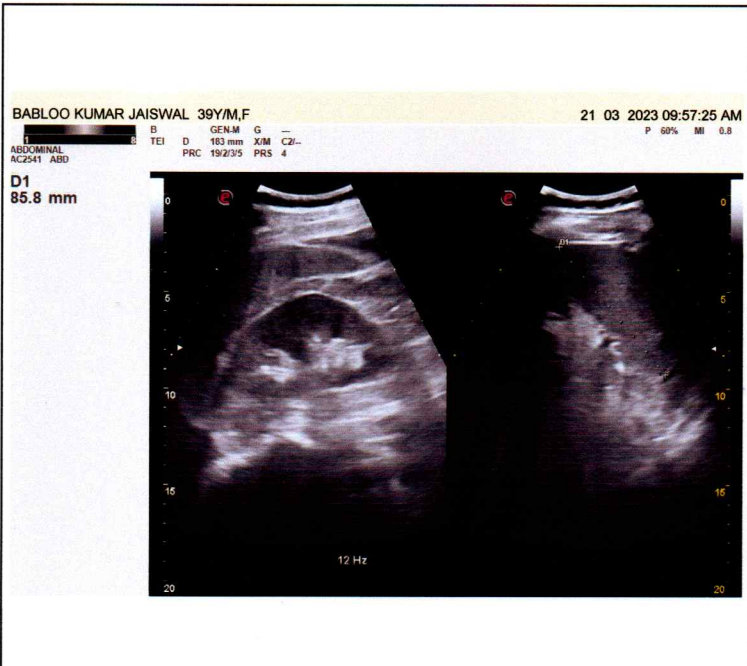
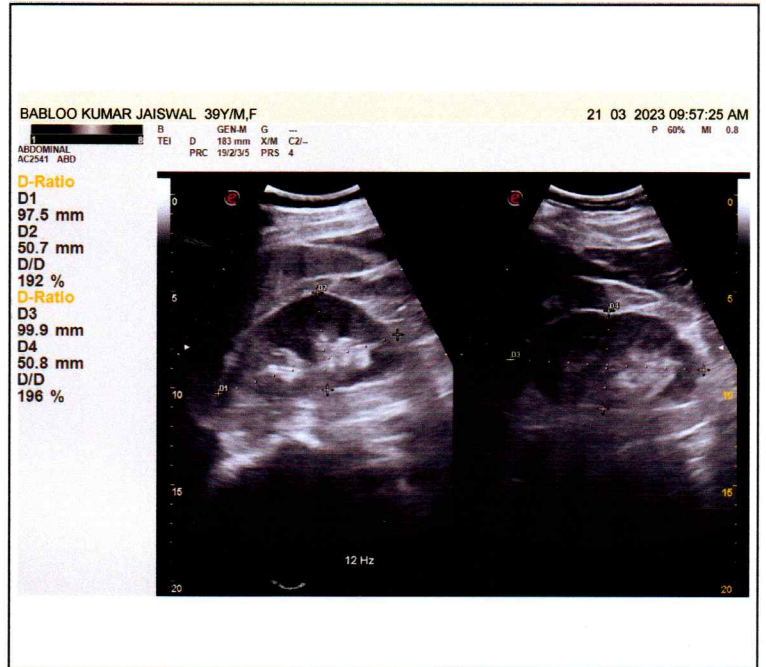
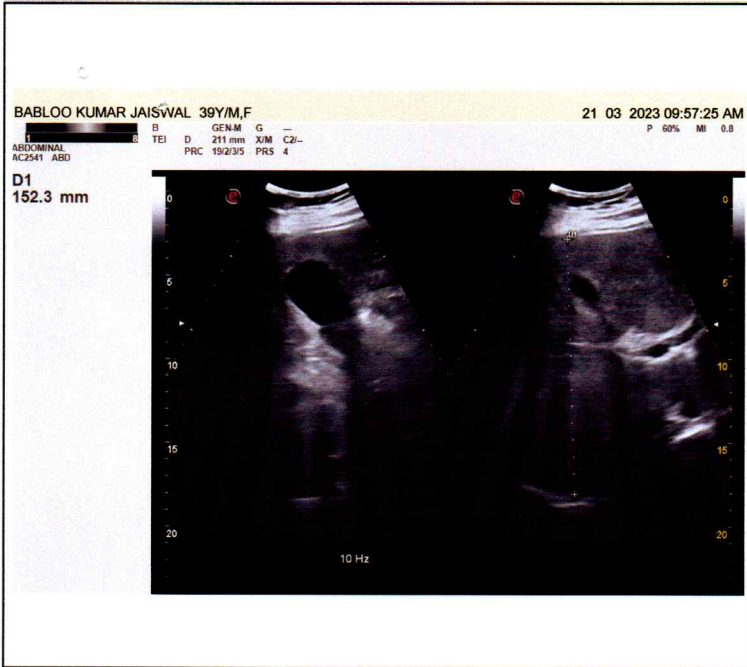

DR. R. TIWARI
(M.B.B.S, M.D.(KGMU, LKO)
(RADIODIAGNOSIS).


Thanks for reference.

Address : Kabir Nagar (Near Sanjay Shiksha Niketan), Durgakund, Varanasi

Mobile : 9554572190 / 9453837595 / Recpn. 9389994334

E-mail : dramishra@gmail.com, drpallaviojha@gmail.com, Website: www.piire.org





Call Now - 1800-123-3070

PANACEA HOSPITAL

A shelter for many hearts A Home for many lives

(An ISO 9001:2008 Certified Organisation)

Lab Attached with CMC Vellore Under EQAS Scheme

PATIENT'S NAME : BABLOO KUMAR JAISWAL
REF. BY : Dr. ASHUTOSH MISHRA(MD)


AGE/SEX: 39 Y/M
Tuesday, March 21, 2023

X-RAY CHEST (PA VIEW)

- Bilateral visualized lung fields appear normal.
- Trachea appears normal in position.
- Both hila appear normal in size and are symmetrical.
- Cardiac shadow within normal limits.
- Both CP angles appear clear.
- Bony rib cage and soft tissue shadows appear normal.

IMPRESSION

- **No obvious abnormality noted in the chest radiograph.**

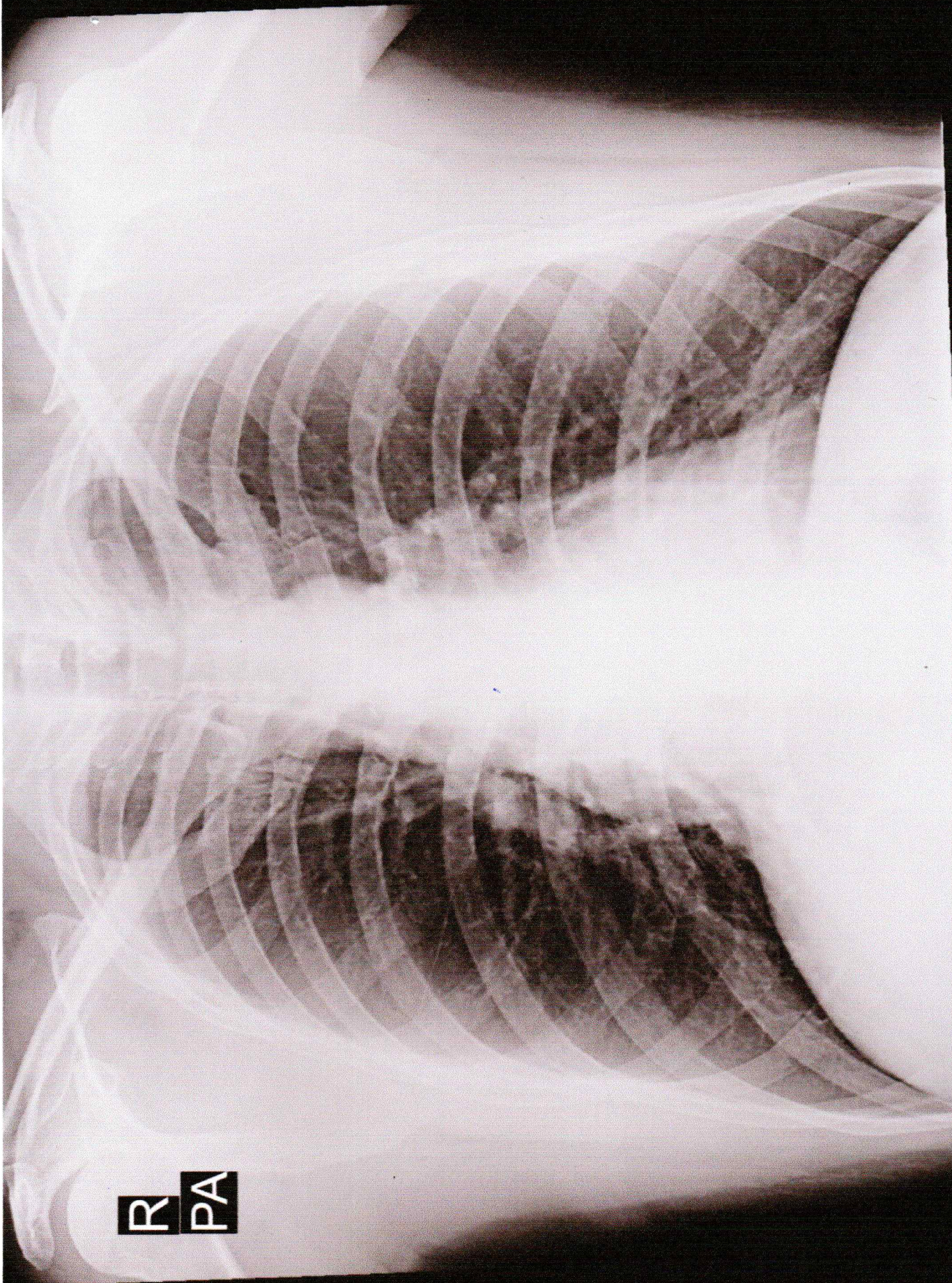

DR. R. K. TIWARI
M.B.B.S, M.D.(KGMU,LKO)
(RADIOLOGIST)

Thanks for reference.

Address : Kabir Nagar (Near Sanjay Shiksha Niketan), Durgakund, Varanasi

Mobile : 9554572190 / 9453837595 / Recpn. 9389994334

E-mail : dramishra@gmail.com, drpallaviojha@gmail.com, Website: www.piire.org



R
PA

BABLOO KUMAR JAISWAL 39YM 4125 O CHEST P.A. 21-Mar-23 10:18 AM

PANACEA HOSPITAL, KABIR NAGAR, DURGAKUND, VARANASI