

ID: 003574

Female
5 Years
cm

mmHg
kg

Letka R.

Diagnosis Information:

HR	96	bpm
P	95	ms
PR	158	ms
QRS	83	ms
QTc	359/429	ms
PQRST	60-23/60	°
RV5/SV1	0.150/0.607	mV

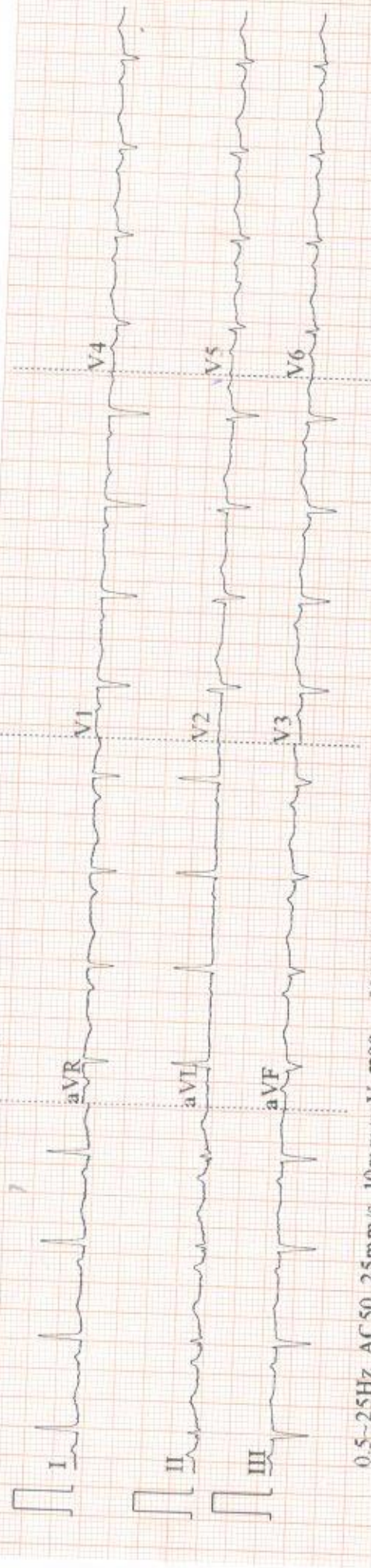
Report Confirmed by:



V1	V2	V3	V4
		Standard	

Standard	L I	L II	L III	L III Inspiration

ID: 003574 10-02-2024 10:52:11 AM



0.5-25Hz AC50 25mm/s 10mm/mV ♡99 V1.0 SEMP V1.7 DDRC-AGILUS
ALCO W CE

NAME : MR. LATHA	AGE: 51/F	DATE: 10/02/2024
------------------	-----------	------------------

CHEST X-RAY REPORT

CHEST X-RAY PA VIEW : Trachea central
 No cardiomegaly
 Normal vascularity
 No parenchymal lesion.
 Costophrenic and cardiophrenic angles clear

➤ **IMPRESSION** : Normal Chest Xray

ELECTRO CARDIOGRAM : NSR: 96/minute
 No evidence of ischaemia

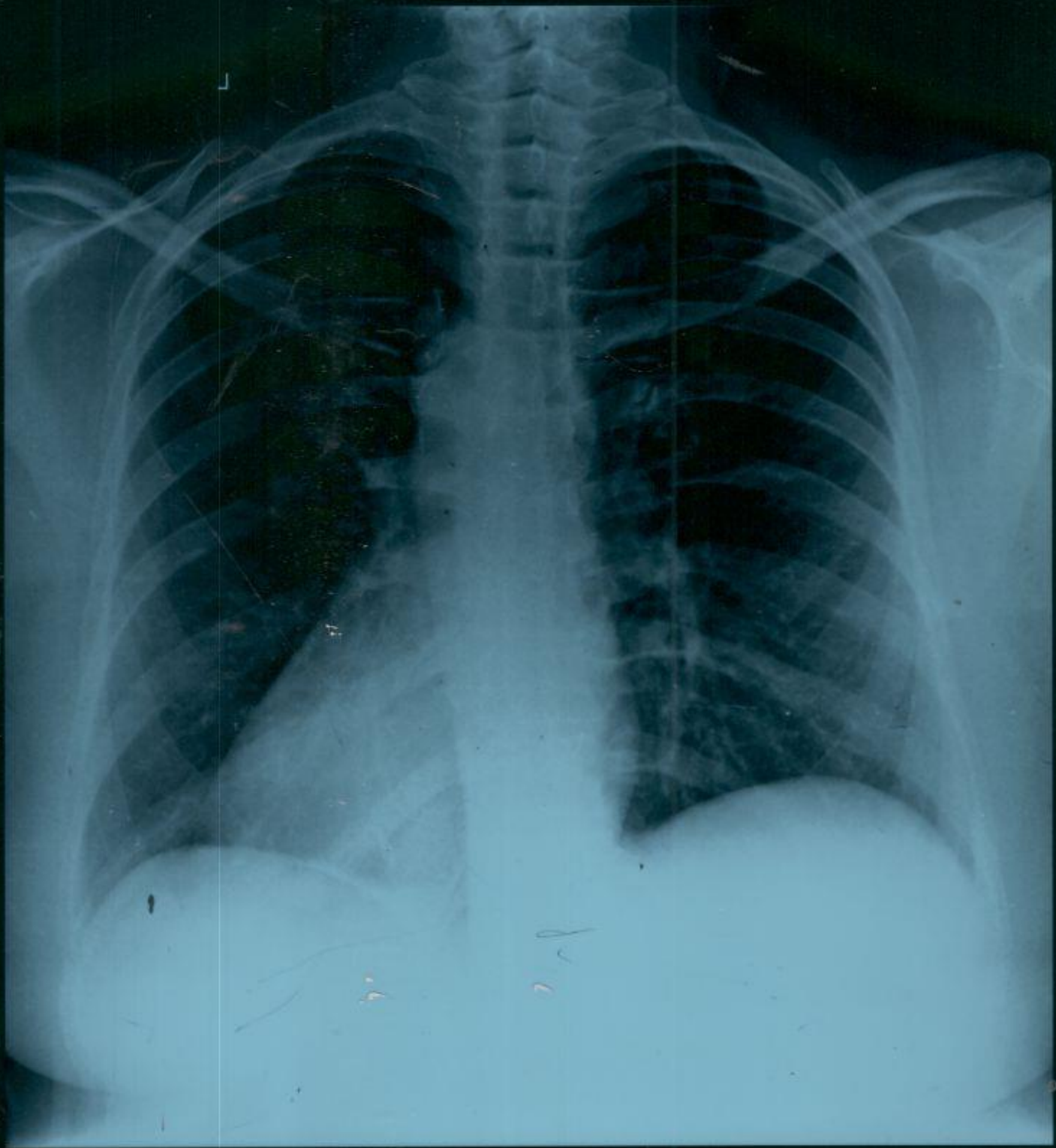
➤ **IMPRESSION** : Normal Ecg.



Serim Lopez
 DR. SERIN LOPEZ, MBBS
 Reg. No. 77656
 MEDICAL OFFICER
 DDRC AGILUS PATHLABS LTD.
 Aster Square, Medical College, P.O, TVM

Company name: MEDIWHEEL

DR SERIN LOPEZ MBBS
 Reg No 77656
DDRC AGILUS PATHLABS LTD



LATHA R 51Y F 21012024 CHEST-PA XB003274 ne
DPRC AGILUS

FROM,

NAME: R. LATHA
COMPANY NAME: BANK OF BARODA
DATE: 10.02.2024

TO
DDRC AGILUS PATHLABS LTD
ULLOOR
TRIVANDRUM

RESPECTED SIR/MAM,

**I AM NOT INTERESTED TO DO STOOL/MOTION TEST AS
PART OF MY HEALTH CHECKUP.**

THANKS & REGARDS

SIGN:

Handwritten signature of R. Latha in black ink, written over a horizontal line.

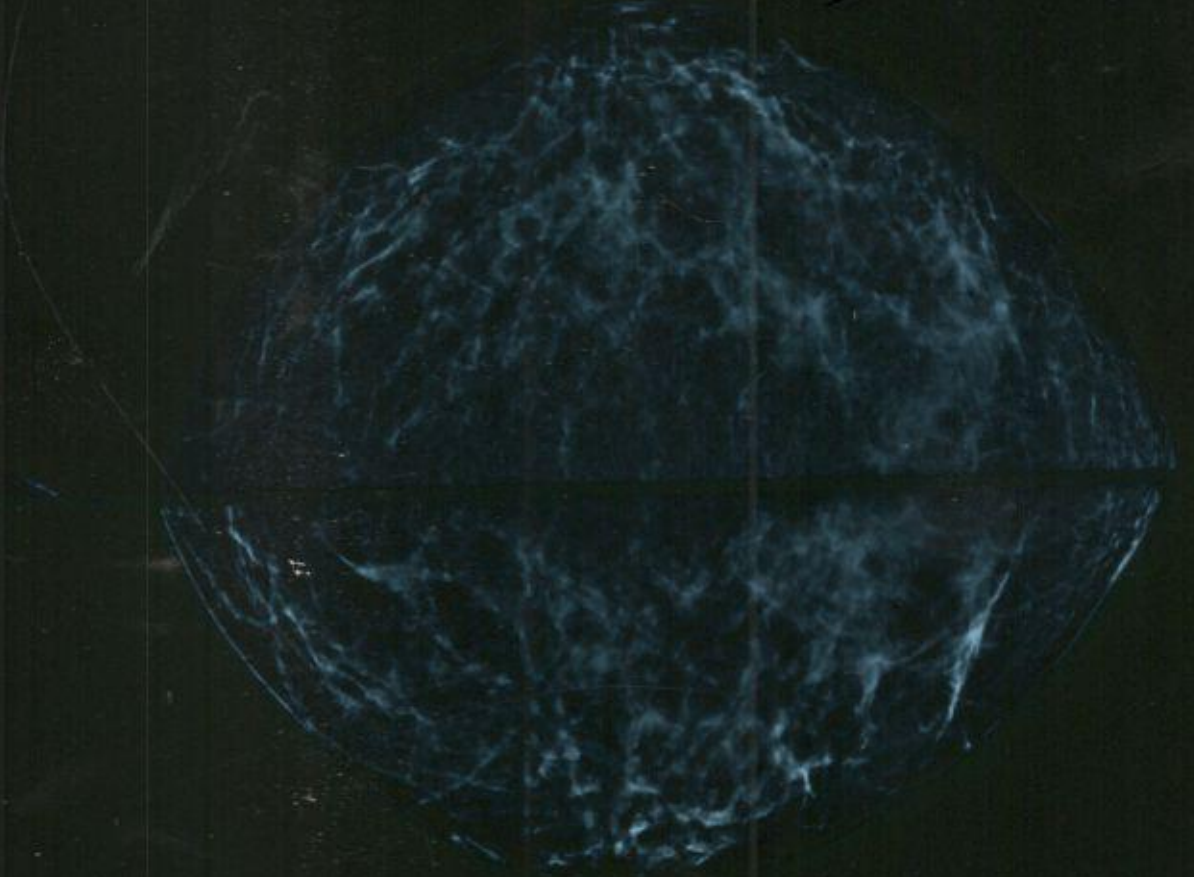
R-mj

L-mlo



DDRC AGILUS
LATHA R. 51Y F 2/10/2024 MAMMOGRAPHY- MLO XB003574

R-cc



L-cc

DDRC AGILUS
MRS LATHA R 51Y F 2/10/2024 MAMMOGRAPHY - CC - XB003574

MAMMOGRAM REPORT (BOTH) RADIOLOGY DIVISION

Acc no:4182XB003574	Name: Mrs. Latha R	Age: 51 y	Sex: Female	Date:10.02.24
---------------------	--------------------	-----------	-------------	---------------

(i) **INDICATION** :- Screening

(ii) **BREAST COMPOSITION** :-

RIGHT :Heterogeneously dense breast which may obscure small masses

LEFT : Heterogeneously dense breast which may obscure small masses

(iii) **OBSERVATION**:-

RIGHT :- No mass / asymmetry / architectural distortion / significant calcifications. Suggestion of a few axillary lymphnodes.

LEFT :- No mass / asymmetry / architectural distortion / significant calcifications. Suggestion of a few axillary lymphnodes.

(iv) **COMPARISON WITH THE PREVIOUS STUDIES** :- No previous breast imaging

(v) **ULTRASOUND FINDINGS** :-

RIGHT : Breast composition - Heterogeneous background echotexture.

Scattered areas of mild coarsening, hypoechogenicity of glandular elements and hyperechogenicity of periglandular stromal elements noted. Small cyst measuring 3.9 x 1.7 mm noted at about 7 O' clock position - likely representing fibrocystic breast disease. No mass / intramammary duct dilation. Nipple areolar complex normal. A few morphologically benign axillary lymphnodes noted, largest measuring .1.4 x 0.8 cm.

LEFT :- Breast composition - Heterogeneous background echotexture.

Scattered areas of mild coarsening, hypoechogenicity of glandular elements and hyperechogenicity of periglandular stromal elements noted - ? Nature. ? Due to mild fibroadenotic changes. No mass / cysts / intramammary duct dilation. Nipple areolar complex normal. A few morphologically benign axillary lymphnodes noted, largest measuring 1.9 x 0.8 cm.

(vi) **IMPRESSION** :-

RIGHT :- BIRADS assessment category - Benign
BIRADS numeric code - 2

LEFT :- BIRADS assessment category - Negative / Benign.
BIRADS numeric code - 1/ 2.

(vii) **RECOMMENDATIONS** :- Routine mammography screening.

Dr. Nisha Unni MD , DNB (RD)
Consultant radiologist.

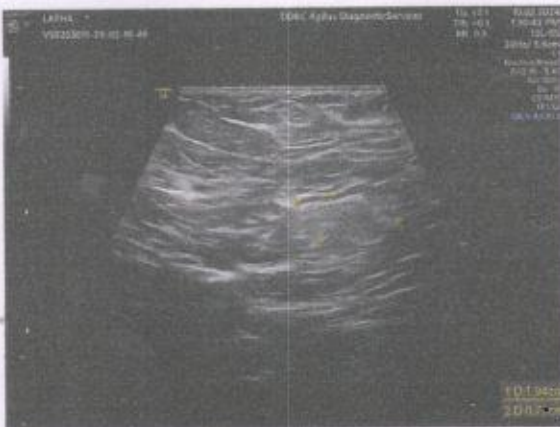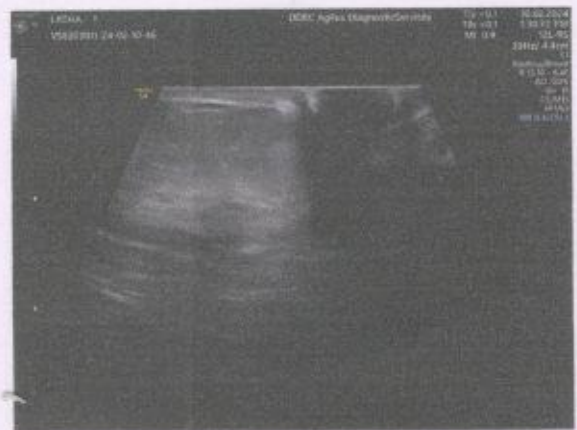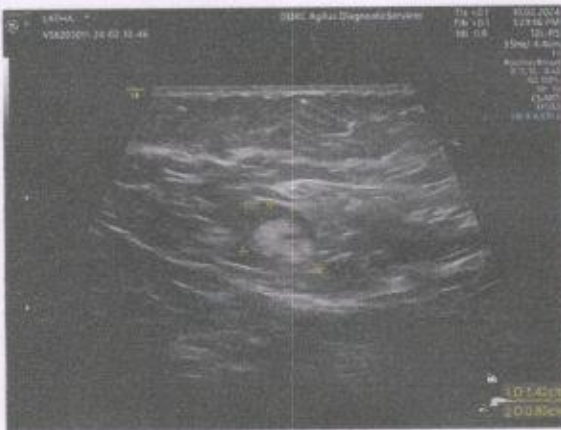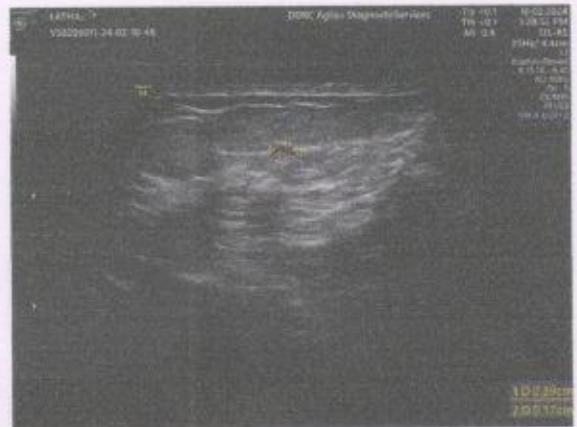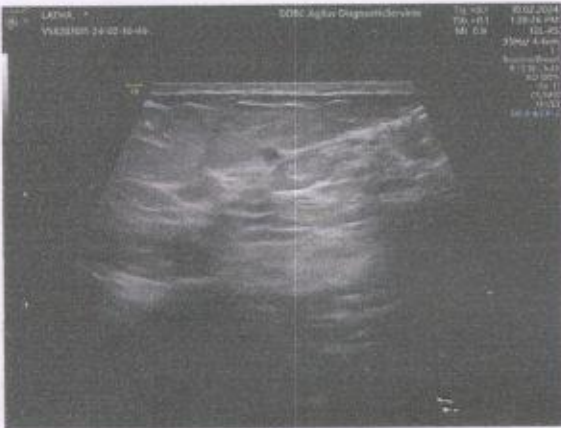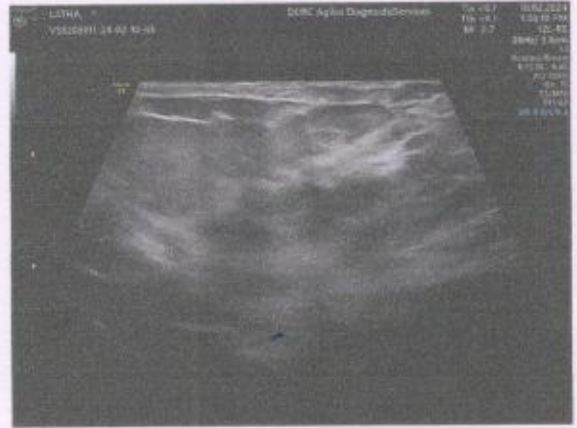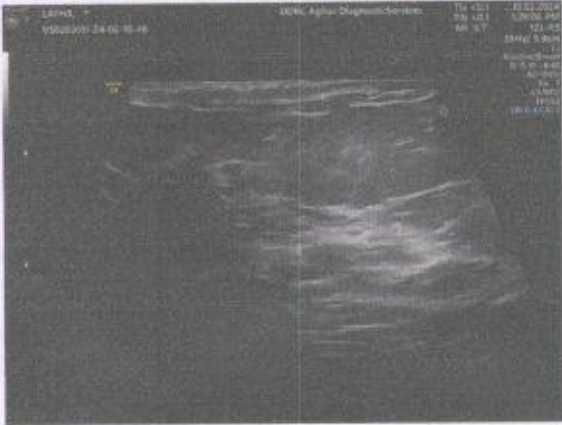Thanks, your feedback will be appreciated.

(Please bring relevant investigation reports during all visits).

Because of technical and technological limitations complete accuracy cannot be assured on imaging.

Suggested correlation with clinical findings and other relevant investigations consultations , and if required repeat imaging recommended in the event of controversies. AR

(For appointments please contact **9496005190** between 9 am – 5.30 pm).



RADIOLOGY DIVISION

Acc no:4182XB003574	Name: Mrs. Latha R	Age: 51 y	Sex: Female	Date:10.02.24
---------------------	--------------------	-----------	-------------	---------------

US SCAN WHOLE ABDOMEN (TAS + TVS)

LIVER is normal in size (15 cm). Margins are regular. Hepatic parenchyma shows normal echogenicity. No focal lesions seen. No dilatation of intrahepatic biliary radicles. CBD is not dilated. Portal vein is normal in caliber (11.1 mm).

GALL BLADDER is partially distended and lumen clear. No calculi / polyp noted. Wall thickness is normal. No pericholecystic fluid seen.

SPLEEN is normal in size (9.5 cm) and parenchymal echotexture. No focal lesion seen.

PANCREAS Head and body visualized, appears normal in size and shows increased parenchymal echotexture. Pancreatic duct is not dilated.

RIGHT KIDNEY is normal in size (10.4 x 4.4 cm) and shows normal parenchymal echotexture. Cortico medullary differentiation is maintained. Parenchymal thickness is normal. No echogenic focus with shadowing suggestive of renal calculi seen. No dilatation of pelvicalyceal system seen. Ureter is not dilated. Perinephric spaces are normal.

LEFT KIDNEY is normal in size (10.4 x 4.4 cm) and shows normal parenchymal echotexture. Cortico medullary differentiation is maintained. Parenchymal thickness is normal. No echogenic focus with shadowing suggestive of renal calculi seen. No dilatation of pelvicalyceal system seen. Ureter is not dilated. Perinephric spaces are normal.

PARAAORTIC AREA No retroperitoneal lymphadenopathy or mass seen.

URINARY BLADDER is distended, normal in wall thickness, lumen clear.

UTERUS measures 6.9 x 3.4 x cm. **Myometrial echopattern is inhomogeneous. Possibility of an exophytic subserous fibroid measuring 2 x 1.9 cm noted in right lateral wall. Endometrial thickness is 4.7 mm. Nabothian cysts noted in cervix largest measuring 1.7 x 1.1 cm. Echogenic debris noted in some of them. No internal vascularity.**

Both ovaries are normal. Right ovary measures 2.2 x 0.9 cm. Left ovary measures 2.1 x 0.9 cm. No adnexal mass seen. No fluid in pouch of Douglas.

No ascites or pleural effusion.

Gaseous distension of bowel loops noted. No obvious bowel wall thickening seen sonologically.

CONCLUSION:-

➤ **Uterine fibroid.**


Dr. Nisha Unni MD, DNB (RD)
Consultant radiologist.

Thanks for referral. Your feedback will be appreciated.

(Please bring relevant investigation reports during all visits)

Because of technical and technological limitations complete accuracy cannot be assured on imaging.

Suggested correlation with clinical findings and other relevant investigations consultations, and if required repeat imaging recommended in the event of controversies. AR

(For appointments / any clarification of report please contact 9496005190 between 9 am – 5.30 pm).

Corp. Office : Express House, Second Floor, Opp. Pothys Silks, Banerjee Road, Kaloor -682017

Contact :- 93334 93334, Web :- www.ddrcagilus.com Email :- info.ddrc@agilus.in

ECHO REPORT

SRD No :XB003574	Name:LATHA.R	Age:51Y	Sex:F	Date: 10/02/2024
------------------	--------------	---------	-------	------------------

Left Ventricle:-

	Diastole	Systole
IVS	1.06cm	1.20cm
LV	4.30cm	2.89cm
LVPW	1.13cm	1.41cm

EF -69% FS- 32%

AO	LA
3.44cm	3.66cm

PV - 0.87m/s
AV - 1.28m/s
MVE - 0.89m/s
MVA - 0.68m/s
E/A - 1.30

IMPRESSION:-

- Normal chambers dimension
- No RWMA
- Good LV systolic function
- No diastolic dysfunction
- No AS,AR,MR,MS,TR,PAH
- IAS/IVS intact.No clots/effussion/coarctation



Dr. SAJITH. K
MD,DNB
CONSULTANT CARDIOLOGIST
Reg.No: 19436

Dr. Sajith K
Consultant Cardiologist

DDRCagilus Pathlabs Limited.

Corp. Office : Express House, Second Floor, Opp. Pothys Silks, Banerjee Road, Kaloor -682017

Contact :- 93334 93334, Web :- www.ddrcagilus.com Email :- info.ddrc@agilus.in

PATIENT NAME : MRS LATHA R

REF. DOCTOR : SELF

CODE/NAME & ADDRESS : CA00010147 -

MEDIWHEEL ARCOFEMI HEALTHCARE LIMITED
F701A, LADO SARAI, NEW DELHI,SOUTH DELHI,
DELHI,
SOUTH DELHI 110030
8800465156ACCESSION NO : **4182XB003574**

PATIENT ID : MRSLF1002734182

CLIENT PATIENT ID:

ABHA NO :

AGE/SEX : 51 Years Female

DRAWN :

RECEIVED : 10/02/2024 09:45:06

REPORTED : 13/02/2024 13:54:27

Test Report Status **Final**

Results

Biological Reference Interval Units

MEDIWHEEL HEALTH CHECKUP ABOVE 40(F)2DECHO**PHYSICAL EXAMINATION**

PHYSICAL EXAMINATION

REPORT GIVEN

**DR NISHA UNNI, MBBS,MD**
(RD),DNB (Reg.No:50162)
Consultant Radiologist

Page 1 Of 10



View Details



View Report

PERFORMED AT :DDRC AGILUS PATHLABS LIMITED
ASTER SQUARE BUILDING, ULLOOR,
MEDICAL COLLEGE P.O
TRIVANDRUM, 695011
KERALA, INDIA

Tel : 93334 93334, Fax : CIN - U85190MH2006PTC161480

Email : customercare.ddrc@agilus.in



Patient Ref. No. 66600007811595

PATIENT NAME : MRS LATHA R
REF. DOCTOR : SELF
CODE/NAME & ADDRESS : CA00010147 -

 MEDIWHEEL ARCOFEMI HEALTHCARE LIMITED
 F701A, LADO SARAI, NEW DELHI, SOUTH DELHI,
 DELHI,
 SOUTH DELHI 110030
 8800465156

ACCESSION NO : 4182XB003574
PATIENT ID : MRSLF1002734182
CLIENT PATIENT ID:
ABHA NO :
AGE/SEX : 51 Years Female
DRAWN :
RECEIVED : 10/02/2024 09:45:06
REPORTED : 13/02/2024 13:54:27
Test Report Status Final
Results
Units
MEDIWHEEL HEALTH CHECKUP ABOVE 40(F)2DECHO
ECG WITH REPORT
REPORT
REPORT GIVEN
2D - ECHO WITH COLOR DOPPLER
REPORT
REPORT GIVEN
USG ABDOMEN AND PELVIS
REPORT
REPORT GIVEN
CHEST X-RAY WITH REPORT
REPORT
REPORT GIVEN
MAMMOGRAPHY -BOTH
REPORT
REPORT GIVEN
HAEMATOLOGY
MEDIWHEEL HEALTH CHECKUP ABOVE 40(F)2DECHO
GLYCOSYLATED HEMOGLOBIN(HBA1C), EDTA WHOLE BLOOD
HBA1C
7.6 High

Non-diabetic Adult < 5.7

Pre-diabetes 5.7 - 6.4

%


**DR NISHA UNNI, MBBS,MD
(RD),DNB (Reg.No:50162)
Consultant Radiologist**

**DR.VAISHALI RAJAN, MBBS DCP
(Pathology)
(Reg No - TCC 27150)
HOD - HAEMATOLOGY**

**DR.HARI SHANKAR, MBBS MD
(Reg No - TCMC:62092)
HEAD - Biochemistry &
Immunology**


View Details



View Report

Page 2 Of 10

PERFORMED AT :

 DDRC AGILUS PATHLABS LIMITED
 ASTER SQUARE BUILDING, ULLOOR,
 MEDICAL COLLEGE P.O
 TRIVANDRUM, 695011
 KERALA, INDIA
 Tel : 93334 93334, Fax : CIN - U85190MH2006PTC161480
 Email : customercare.ddrc@agilus.in

Patient Ref. No. 66600007811595

PATIENT NAME : MRS LATHA R

REF. DOCTOR : SELF

CODE/NAME & ADDRESS : CA00010147 -
 MEDIWHEEL ARCOFEMI HEALTHCARE LIMITED
 F701A, LADO SARAI, NEW DELHI,SOUTH DELHI,
 DELHI,
 SOUTH DELHI 110030
 8800465156

ACCESSION NO : **4182XB003574**
PATIENT ID : MRSLF1002734182
CLIENT PATIENT ID:
ABHA NO :

AGE/SEX : 51 Years Female
DRAWN :
RECEIVED : 10/02/2024 09:45:06
REPORTED : 13/02/2024 13:54:27

Test Report Status	Final	Results	Units
--------------------	-------	---------	-------

MEAN PLASMA GLUCOSE	171.4 High	Diabetes diagnosis: > or = 6.5 Therapeutic goals: < 7.0 Action suggested : > 8.0 (ADA Guideline 2021) < 116.0	mg/dL
---------------------	-------------------	---	-------

BLOOD COUNTS,EDTA WHOLE BLOOD

HEMOGLOBIN	10.2 Low	12.0 - 15.0	g/dL
RED BLOOD CELL COUNT	4.97 High	3.80 - 4.80	mil/ μ L
WHITE BLOOD CELL COUNT	7.89	4.0 - 10.0	thou/ μ L
PLATELET COUNT	402	150 - 410	thou/ μ L

RBC AND PLATELET INDICES

HEMATOCRIT	34.7 Low	36.0 - 46.0	%
MEAN CORPUSCULAR VOL	69.8 Low	83.0 - 101	fL
MEAN CORPUSCULAR HGB.	20.5 Low	27.0 - 32.0	pg
MEAN CORPUSCULAR HEMOGLOBIN CONCENTRATION	29.4 Low	31.50 - 34.50	g/dL
RED CELL DISTRIBUTION WIDTH	16.6 High	11.60 - 14.0	%
MENTZER INDEX	14.0		
MEAN PLATELET VOLUME	8.8	6.80 - 10.90	fL

WBC DIFFERENTIAL COUNT

SEGMENTED NEUTROPHILS	55	40.0 - 80.0	%
LYMPHOCYTES	28	20.0 - 40.0	%
MONOCYTES	5	2.0 - 10.0	%
EOSINOPHILS	12 High	1.0 - 6.0	%
BASOPHILS	0	0.0 - 1.0	%
ABSOLUTE NEUTROPHIL COUNT	4.38	2.0 - 7.0	thou/ μ L

DR.VAISHALI RAJAN, MBBS DCP
 (Pathology)
 (Reg No - TCC 27150)
 HOD - HAEMATOLOGY

DR.HARI SHANKAR, MBBS MD
 (Reg No - TCMC:62092)
 HEAD - Biochemistry &
 Immunology



View Details



View Report

PERFORMED AT :

DDRC AGILUS PATHLABS LIMITED
 ASTER SQUARE BUILDING, ULLOOR,
 MEDICAL COLLEGE P.O
 TRIVANDRUM, 695011
 KERALA, INDIA
 Tel : 93334 93334, Fax : CIN - U85190MH2006PTC161480
 Email : customercare.ddrc@agilus.in



Patient Ref. No. 66600007811595

PATIENT NAME : MRS LATHA R

REF. DOCTOR : SELF

CODE/NAME & ADDRESS : CA00010147 -
MEDIWHEEL ARCOFEMI HEALTHCARE LIMITED
F701A, LADO SARAI, NEW DELHI, SOUTH DELHI,
DELHI,
SOUTH DELHI 110030
8800465156

ACCESSION NO : **4182XB003574**
PATIENT ID : MRSLF1002734182
CLIENT PATIENT ID:
ABHA NO :

AGE/SEX : 51 Years Female
DRAWN :
RECEIVED : 10/02/2024 09:45:06
REPORTED : 13/02/2024 13:54:27

Test Report Status	Final	Results	Units	
ABSOLUTE LYMPHOCYTE COUNT		2.21	1.0 - 3.0	thou/μL
ABSOLUTE MONOCYTE COUNT		0.39	0.20 - 1.0	thou/μL
ABSOLUTE EOSINOPHIL COUNT		0.92 High	0.02 - 0.50	thou/μL
ABSOLUTE BASOPHIL COUNT		0.00		thou/μL
NEUTROPHIL LYMPHOCYTE RATIO (NLR)		2.0		

ERYTHROCYTE SEDIMENTATION RATE (ESR), EDTA BLOOD

SEDIMENTATION RATE (ESR) 14 0 - 20 mm at 1 hr

SUGAR URINE - POST PRANDIAL

SUGAR URINE - POST PRANDIAL NOT DETECTED NOT DETECTED

SUGAR URINE - FASTING

SUGAR URINE - FASTING NOT DETECTED NOT DETECTED

IMMUNOHAEMATOLOGY

MEDIWHEEL HEALTH CHECKUP ABOVE 40(F)2DECHO

ABO GROUP & RH TYPE, EDTA WHOLE BLOOD

ABO GROUP TYPE B
RH TYPE NEGATIVE

METHOD : COLUMN AGGLUTINATION TECHNOLOGY

Interpretation(s)



DR.VAISHALI RAJAN, MBBS DCP
(Pathology)
(Reg No - TCC 27150)
HOD - HAEMATOLOGY



DR.HARI SHANKAR, MBBS MD
(Reg No - TCMC:62092)
HEAD - Biochemistry &
Immunology



View Details



View Report

Page 4 Of 10

PERFORMED AT :

DDRC AGILUS PATHLABS LIMITED
ASTER SQUARE BUILDING, ULLOOR,
MEDICAL COLLEGE P.O
TRIVANDRUM, 695011
KERALA, INDIA
Tel : 93334 93334, Fax : CIN - U85190MH2006PTC161480
Email : customercare.ddrc@agilus.in



Patient Ref. No. 66600007811595

PATIENT NAME : MRS LATHA R

REF. DOCTOR : SELF

CODE/NAME & ADDRESS : CA00010147 -
MEDIWHEEL ARCOFEMI HEALTHCARE LIMITED
F701A, LADO SARAI, NEW DELHI, SOUTH DELHI,
DELHI,
SOUTH DELHI 110030
8800465156

ACCESSION NO : **4182XB003574**
PATIENT ID : MRSLF1002734182
CLIENT PATIENT ID:
ABHA NO :

AGE/SEX : 51 Years Female
DRAWN :
RECEIVED : 10/02/2024 09:45:06
REPORTED : 13/02/2024 13:54:27

Test Report Status	Final	Results	Units
--------------------	-------	---------	-------

ABO GROUP & RH TYPE, EDTA WHOLE BLOOD-Blood group is identified by antigens and antibodies present in the blood. Antigens are protein molecules found on the surface of red blood cells. Antibodies are found in plasma. To determine blood group, red cells are mixed with different antibody solutions to give A,B,O or AB.

Disclaimer: "Please note, as the results of previous ABO and Rh group (Blood Group) for pregnant women are not available, please check with the patient records for availability of the same."

The test is performed by both forward as well as reverse grouping methods.

BIO CHEMISTRY

MEDIWHEEL HEALTH CHECKUP ABOVE 40(F)2DECHO

BLOOD UREA NITROGEN (BUN), SERUM

BLOOD UREA NITROGEN	11	Adult(<60 yrs) : 6 to 20	mg/dL
---------------------	----	--------------------------	-------

BUN/CREAT RATIO

BUN/CREAT RATIO	15.7		
-----------------	------	--	--

CREATININE, SERUM

CREATININE	0.70	18 - 60 yrs : 0.6 - 1.1	mg/dL
------------	------	-------------------------	-------

GLUCOSE, POST-PRANDIAL, PLASMA

GLUCOSE, POST-PRANDIAL, PLASMA	190 High	Diabetes Mellitus : > or = 200. Impaired Glucose tolerance/ Prediabetes : 140 - 199. Hypoglycemia : < 55.	mg/dL
--------------------------------	-----------------	--	-------

GLUCOSE FASTING, FLUORIDE PLASMA

FBS (FASTING BLOOD SUGAR)	133 High	Diabetes Mellitus : > or = 126. Impaired fasting Glucose/ Prediabetes : 101 - 125. Hypoglycemia : < 55.	mg/dL
---------------------------	-----------------	--	-------



DR. HARI SHANKAR, MBBS MD
(Reg No - TCMC:62092)
HEAD - Biochemistry &
Immunology



DR. VAISHALI RAJAN, MBBS DCP
(Pathology)
(Reg No - TCC 27150)
HOD - HAEMATOLOGY

Page 5 Of 10



View Details



View Report

PERFORMED AT :

DDRC AGILUS PATHLABS LIMITED
ASTER SQUARE BUILDING, ULLOOR,
MEDICAL COLLEGE P.O
TRIVANDRUM, 695011
KERALA, INDIA
Tel : 93334 93334, Fax : CIN - U85190MH2006PTC161480
Email : customercare.ddrc@agilus.in



Patient Ref. No. 66600007811595

PATIENT NAME : MRS LATHA R		REF. DOCTOR : SELF	
CODE/NAME & ADDRESS : CA00010147 - MEDIWHEEL ARCOFEMI HEALTHCARE LIMITED F701A, LADO SARAI, NEW DELHI,SOUTH DELHI, DELHI, SOUTH DELHI 110030 8800465156		ACCESSION NO : 4182XB003574	AGE/SEX : 51 Years Female
		PATIENT ID : MRSLF1002734182	DRAWN :
		CLIENT PATIENT ID:	RECEIVED : 10/02/2024 09:45:06
		ABHA NO :	REPORTED :13/02/2024 13:54:27

Test Report Status	Final	Results	Units
--------------------	-------	---------	-------

Comments

Kindly correlate clinically.
Kindly contact lab within 24 hrs if clinically not correlated.

LIVER FUNCTION TEST WITH GGT

BILIRUBIN, TOTAL	0.86	General Range : < 1.1	mg/dL
BILIRUBIN, DIRECT	0.34	General Range : < 0.3	mg/dL
BILIRUBIN, INDIRECT	0.52	General Range : <0.85	mg/dL
TOTAL PROTEIN	7.6	Ambulatory : 6.4 - 8.3 Recumbant : 6 - 7.8	g/dL
ALBUMIN	4.3	20-60yrs : 3.5 - 5.2	g/dL
GLOBULIN	3.3	General Range : 2 - 3.5 Premature Neonates : 0.29 - 1.04	g/dL
ALBUMIN/GLOBULIN RATIO	1.3	General Range : 1.1 - 2.5	RATIO
ASPARTATE AMINOTRANSFERASE (AST/SGOT)	17	Adults : < 33	U/L
ALANINE AMINOTRANSFERASE (ALT/SGPT)	16	Adults : < 34	U/L
ALKALINE PHOSPHATASE	64	Adult (<60yrs) : 35 - 105	U/L
GAMMA GLUTAMYL TRANSFERASE (GGT)	12	Adult (female) : < 40	U/L

TOTAL PROTEIN, SERUM

TOTAL PROTEIN	7.6	Ambulatory : 6.4 - 8.3 Recumbant : 6 - 7.8	g/dL
---------------	-----	---	------

URIC ACID, SERUM

URIC ACID	4.1	Adults : 2.4-5.7	mg/dL
-----------	-----	------------------	-------

DR.HARI SHANKAR, MBBS MD
(Reg No - TCMC:62092)
HEAD - Biochemistry & Immunology



View Details



View Report

PERFORMED AT :

DDRC AGILUS PATHLABS LIMITED
ASTER SQUARE BUILDING, ULLOOR,
MEDICAL COLLEGE P.O
TRIVANDRUM, 695011
KERALA, INDIA
Tel : 93334 93334, Fax : CIN - U85190MH2006PTC161480
Email : customercare.ddrc@agilus.in



Patient Ref. No. 66600007811595

PATIENT NAME : MRS LATHA R

REF. DOCTOR : SELF

CODE/NAME & ADDRESS : CA00010147 -
MEDIWHEEL ARCOFEMI HEALTHCARE LIMITED
F701A, LADO SARAI, NEW DELHI, SOUTH DELHI,
DELHI,
SOUTH DELHI 110030
8800465156

ACCESSION NO : **4182XB003574**
PATIENT ID : MRSLF1002734182
CLIENT PATIENT ID:
ABHA NO :

AGE/SEX : 51 Years Female
DRAWN :
RECEIVED : 10/02/2024 09:45:06
REPORTED : 13/02/2024 13:54:27

Test Report Status	Final	Results	Units
--------------------	-------	---------	-------

BIOCHEMISTRY - LIPID

MEDIWHEEL HEALTH CHECKUP ABOVE 40(F)2DECHO

LIPID PROFILE, SERUM

CHOLESTEROL	201	Desirable : < 200 Borderline : 200-239 High : >or= 240	mg/dL
TRIGLYCERIDES	124	Normal : < 150 High : 150-199 Hypertriglyceridemia : 200-499 Very High : > 499	mg/dL
HDL CHOLESTEROL	71	General range : 40-60	mg/dL
LDL CHOLESTEROL, DIRECT	110	Optimum : < 100 Above Optimum : 100-129 Borderline High : 130-159 High : 160-189 Very High : >or= 190	mg/dL
NON HDL CHOLESTEROL	130	Desirable : < 130 Above Desirable : 130 -159 Borderline High : 160 - 189 High : 190 - 219 Very high : > / = 220	mg/dL
VERY LOW DENSITY LIPOPROTEIN CHOL/HDL RATIO	24.8 2.8	</= 30.0 Low Risk : 3.3 - 4.4 Average Risk : 4.5 - 7.0 Moderate Risk : 7.1 - 11.0 High Risk : > 11.0	mg/dL
LDL/HDL RATIO	1.6	Desirable/Low Risk - 0.5-3 Borderline/Moderate Risk- 3.1-6 High Risk- >6.0	

DR. HARI SHANKAR, MBBS MD
(Reg No - TCMC:62092)
HEAD - Biochemistry & Immunology

DR. ALISHA ALIYAR MBBS, M.D
Pathology (Reg No: TCMC62966)
CONSULTANT PATHOLOGIST



View Details



View Report

PERFORMED AT :

DDRC AGILUS PATHLABS LIMITED
ASTER SQUARE BUILDING, ULLOOR,
MEDICAL COLLEGE P.O
TRIVANDRUM, 695011
KERALA, INDIA
Tel : 93334 93334, Fax : CIN - U85190MH2006PTC161480
Email : customercare.ddrc@agilus.in



Patient Ref. No. 66600007811595

PATIENT NAME : MRS LATHA R

REF. DOCTOR : SELF

CODE/NAME & ADDRESS : CA00010147 -

MEDIWHEEL ARCOFEMI HEALTHCARE LIMITED
F701A, LADO SARAI, NEW DELHI, SOUTH DELHI,
DELHI,
SOUTH DELHI 110030
8800465156

ACCESSION NO : 4182XB003574

PATIENT ID : MRSLF1002734182

CLIENT PATIENT ID:

ABHA NO :

AGE/SEX : 51 Years Female

DRAWN :

RECEIVED : 10/02/2024 09:45:06

REPORTED : 13/02/2024 13:54:27

Test Report Status **Final**

Results

Units

HISTOPATHOLOGY

MEDIWHEEL HEALTH CHECKUP ABOVE 40(F)2DECHO

CYTOLOGY - CS (PAP SMEAR)

CYTOLOGY - CS (PAP SMEAR)

CERVICAL CYTOLOGY REPORT (2014 BETHESDA SYSTEM)

CR No: 210/2/24

SPECIMEN TYPE: Conventional pap smear.

SPECIMEN ADEQUACY: Satisfactory for evaluation. Transformation zone components are seen.
Metaplastic squamous and endocervical cells seen.

GENERAL CATEGORIZATION: Negative for intraepithelial lesion or malignancy.

INTERPRETATION/RESULT: Negative for intraepithelial lesion or malignancy.

OTHER MALIGNANT NEOPLASM: Nil

EDUCATIONAL NOTES AND SUGGESTIONS: Nil

SPECIALISED CHEMISTRY - HORMONE

MEDIWHEEL HEALTH CHECKUP ABOVE 40(F)2DECHO

THYROID PANEL, SERUM

T3	100.00	Adult : 80-200	ng/dL
T4	8.37	Adults : 4.5-12.1	µg/dl
TSH 3RD GENERATION	1.230	Non-Pregnant : 0.4-4.2	µIU/mL
		Pregnant Trimester-wise :	
		1st : 0.1 - 2.5	
		2nd : 0.2 - 3	
		3rd : 0.3 - 3	



DR. HARI SHANKAR, MBBS MD
(Reg No - TCMC:62092)
HEAD - Biochemistry &
Immunology



DR. ALISHA ALIYAR MBBS, M.D
Pathology (Reg No: TCMC62966)
CONSULTANT PATHOLOGIST

Page 8 Of 10



View Details



View Report

PERFORMED AT :

DDRC AGILUS PATHLABS LIMITED
ASTER SQUARE BUILDING, ULLOOR,
MEDICAL COLLEGE P.O
TRIVANDRUM, 695011
KERALA, INDIA
Tel : 93334 93334, Fax : CIN - U85190MH2006PTC161480
Email : customercare.ddrc@agilus.in



Patient Ref. No. 666000007811595

PATIENT NAME : MRS LATHA R

REF. DOCTOR : SELF

CODE/NAME & ADDRESS : CA00010147 -

MEDIWHEEL ARCOFEMI HEALTHCARE LIMITED
F701A, LADO SARAI, NEW DELHI, SOUTH DELHI,
DELHI,
SOUTH DELHI 110030
8800465156

ACCESSION NO : **4182XB003574**

PATIENT ID : MRSLF1002734182

CLIENT PATIENT ID:

ABHA NO :

AGE/SEX : 51 Years Female

DRAWN :

RECEIVED : 10/02/2024 09:45:06

REPORTED : 13/02/2024 13:54:27

Test Report Status	Final	Results	Units
--------------------	-------	---------	-------

CLINICAL PATH - URINALYSIS

MEDIWHEEL HEALTH CHECKUP ABOVE 40(F)2DECHO

PHYSICAL EXAMINATION, URINE

COLOR	YELLOW
APPEARANCE	CLEAR

CHEMICAL EXAMINATION, URINE

PH	5.0	4.7 - 7.5
SPECIFIC GRAVITY	1.021	1.003 - 1.035
PROTEIN	NEGATIVE	NOT DETECTED
GLUCOSE	NEGATIVE	NOT DETECTED
KETONES	NEGATIVE	NOT DETECTED
BLOOD	DETECTED (++) IN URINE	NOT DETECTED
BILIRUBIN	NEGATIVE	NOT DETECTED
UROBILINOGEN	NORMAL	NORMAL
METHOD : DIPSTICK		
NITRITE	NEGATIVE	NOT DETECTED

MICROSCOPIC EXAMINATION, URINE

RED BLOOD CELLS	2 - 3	NOT DETECTED	/HPF
WBC	1-2	0-5	/HPF
EPITHELIAL CELLS	1-2	0-5	/HPF
CASTS	NEGATIVE		
CRYSTALS	NEGATIVE		
REMARKS	NIL		

METHOD : AUTOMATED ANALYSER, MICROSCOPY



DR.VAISHALI RAJAN, MBBS DCP
(Pathology)
(Reg No - TCC 27150)
HOD - HAEMATOLOGY



DR.HARI SHANKAR, MBBS MD
(Reg No - TCMC:62092)
HEAD - Biochemistry &
Immunology

Page 9 Of 10



View Details



View Report

PERFORMED AT :

DDRC AGILUS PATHLABS LIMITED
ASTER SQUARE BUILDING, ULLOOR,
MEDICAL COLLEGE P.O
TRIVANDRUM, 695011
KERALA, INDIA
Tel : 93334 93334, Fax : CIN - U85190MH2006PTC161480
Email : customercare.ddrc@agilus.in



Patient Ref. No. 66600007811595

PATIENT NAME : MRS LATHA R
REF. DOCTOR : SELF
CODE/NAME & ADDRESS : CA00010147 -

 MEDIWHEEL ARCOFEMI HEALTHCARE LIMITED
 F701A, LADO SARAI, NEW DELHI, SOUTH DELHI,
 DELHI,
 SOUTH DELHI 110030
 8800465156

ACCESSION NO : 4182XB003574
PATIENT ID : MRSLF1002734182
CLIENT PATIENT ID:
ABHA NO :
AGE/SEX : 51 Years Female
DRAWN :
RECEIVED : 10/02/2024 09:45:06
REPORTED : 13/02/2024 13:54:27
Test Report Status Final
Results
Units

DR.VAISHALI RAJAN, MBBS DCP
(Pathology)
(Reg No - TCC 27150)
HOD - HAEMATOLOGY

Page 10 Of 10



View Details



View Report

PERFORMED AT :

 DDRC AGILUS PATHLABS LIMITED
 ASTER SQUARE BUILDING, ULLOOR,
 MEDICAL COLLEGE P.O
 TRIVANDRUM, 695011
 KERALA, INDIA
 Tel : 93334 93334, Fax : CIN - U85190MH2006PTC161480
 Email : customercare.ddrc@agilus.in

Patient Ref. No. 66600007811595