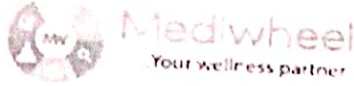

Health Check up Booking Confirmed Request(22D31743),Package Code-PKG10000367, Beneficiary Code-319416

1 message

Mediwheel <wellness@mediwheel.in>
To: shreeramhospital.corphead@gmail.com
Cc: customercare@mediwheel.in

Thu, Aug 22, 2024 at 3:30 PM



011-41195959

Hi **Shree Ram multispeciality Hospital,**

The following booking has been confirmed. It is requested to honor the said booking & provide priority services to our client

Hospital Package Name : Mediwheel Full Body Annual Plus Above 50 Male

Patient Package Name : Mediwheel Full Body Health Checkup Male Above 40

Hospital Address : Gate No.1, Basant Vihar, near Railway Under Bridge, Gondwara Chowk, Gudhiyari, Raipur, Chhattisgarh- 492001

Contact Details : 8895818525

Appointment Date : 24-08-2024

Confirmation Status : Booking Confirmed

Preferred Time : 8:30am

Member Information		
Booked Member Name	Age	Gender
Lokanath Sa	67 year	Male

We request you to facilitate the employee on priority.

Thanks,
Mediwheel Team

Please Download Mediwheel App



You have received this mail because your e-mail ID is registered with **Arcofemi Healthcare Limited** This is a system-generated e-mail please don't reply to this message.

Please visit to our [Terms & Conditions](#) for more informaion. [Click here to unsubscribe.](#)



भारत सरकार
भारत सरकार



आधार

ଭାରତୀୟ ବିଶିଷ୍ଟ ପରିଚୟ ପ୍ରାଧିକରଣ

ଭାରତ ସରକାର

Unique Identification Authority of India
Government of India

ନାମାଙ୍କନ କ୍ରମାଙ୍କ/ Enrolment No.: 2189/77577/28126


To
ଲୋକନାଥ ସା
LOKANATH SA
S/O Gorekh Sa
GADARAMAL
Gadaramal
Nilaji
Nuapada Odisha - 766108
8018177943

Download Date: 07/10/2017

Generation Date: 07/09/2017

Signature Not Verified

Digitally signed by LOKANATH SA
Unique Identification Authority of India on
Date: 2017.10.07 11:15:57
IST



ଆପଣଙ୍କ ଆଧାର ସଂଖ୍ୟା / Your Aadhaar No. :

4745 3142 6708

ମୋ ଆଧାର, ମୋ ପରିଚୟ



ଭାରତ ସରକାର

Government of India



ଲୋକନାଥ ସା
LOKANATH SA
ଜନ୍ମ ତାରିଖ / DOB: 28/05/1957
ପୁରୁଷ / MALE



4745 3142 6708

ମୋ ଆଧାର, ମୋ ପରିଚୟ



Shree Ram Multispeciality Hospital (SRMH)

Lokah Samasta Sukhino Bhavantu

EXAMINATION OF EYES:- (BY OPHTHALMOLOGIST)


Patient Name Mr. Loknath Shah

Date 24/8/24

Sex/ Age G. 7/M

UHID.....

EXTERNAL EXAMINATION					N
SQUINT					NG
NYSTAGMUS					
COLOUR VISION					NORMAL
FUNDUS : (RE):-					WNL (Hazy) (LE):- Hazy WNL
INDIVIDUAL COLOUR IDENTIFICATION					Good
DISTANT VISION:(RE):-					6/36 EG. NIG (LE):- 5/60 EG. NIG
NEAR VISION:(RE):-					NG (LE):- NG
NIGHT BLINDNESS					NAD
	SPH	CYL	AXIS	ADD	
RIGHT					
LEFT					
REMARKS:- BG Cataract					



Near Railway Under Bridge, Basant Vihar Gate No. 1, Gondwara Chowk

Gudhiyari, Raipur (Chhattisgarh)

☎ 0771-43 43 161, 0771-43 40 162, 📞 8404 8404 79

✉ shreeramhospital.op@gmail.com 🌐 www.srmhraipur.com





Shree Ram Multispeciality Hospital (SRMH)

Lokah Samasta Sukhino Bhavantu

OPD - ID : 02024-2025-0000001
UH-ID : SRMH-2408883

PT. TYPE : NEW REGISTRATION
PRINT DATE : 24/08-2024 / 01:15

TOKEN NO. : 5

PATIENT NAME	: MR LOKANATH SA	DEPARTMENT	: ENT
AGE / SEX	: 67-Y 0-M 0-D / MALE	DOB	: none
CONSULT-DATE	: 24-AUG-2024 - 11:24 AM		
MOB-NO	: 8895818525	COMPANY NAME	: MEDIWHEEL
GUARDIAN NAME	: GOREKH SA	OPD PAID FEE	: 0.00
ADDRESS	: NILAJI GASARAMAL NUAPADA NILAJI		
Weight :	Temp :	B.P. :	Pulse :
			SPO2 :

Please indicate whether you are presently suffering from anyone of the following symptoms:

	Yes	No
Ears, Nose, Mouth, Throat		

- Ear pain 0 0
- Ear itch 0 0
- Ear drainage 0 0
- Dizziness/ Loss of balance 0 0
- Loss of Hearing 0 0
- Popping Noise 0 0
- Tinnitus 0 0
- Nosebleeds 0 0
- Post-nasal Drip 0 0
- Sinus pain 0 0
- Sinus pressure 0 0
- Nasal congestion 0 0
- Loss of smell/taste 0 0
- Hoarseness 0 0
- Sore Throat 0 0
- Throat tickle 0 0
- Dry Mouth / Throat 0 0
- Throat clearing 0 0
- Snoring 0 0

Present chief complaints:- *No Present Complaints.*

Dr. Signature

FOLLOW-UP DATE : ADVICE
FOR ADMISSION

YES	NO
-----	----



Ⓧ Near Railway Under Bridge, Basant Vihar Gate No. 1, Gondwara Chowk, Gudhiyari, Raipur (Chhattisgarh)

☎ 0771-43 43 161, 0771-43 40 162, 📞 8404 8404 79
✉ shreeramhospital.op@gmail.com 🌐 www.srmhraipur.com



www.srmhraipur.com



Shree Ram Multispeciality Hospital (SRMH)

Lokah Samasta Sukhino Bhavantu

OPD - ID : 02024 - 2025-0000001
UH-ID : SRMH-2408083

PT. TYPE : FREE OPD
PRINT DATE : 24-08-2024 / 12:58:14



6873043

PATIENT NAME	: MR. LOKANATH SA	OPD-DATE	: 24-Aug-2024 - 12:58 PM
AGE / SEX	: 67-Y 2-M 29-D / <input checked="" type="checkbox"/> MALE	DEPARTMENT	: GENERAL MEDICINE
DOB	: 28-05-1957	CONSULTANT	: DR. AJIT KUMAR
MOB-NO	: 8895818525	COMPANY NAME	: MEDIWHEEL
GUARDIAN NAME	: S/o GOREKH SA	OPD PAID FEE	: 0.00
ADDRESS	: NILAJI GASARAMAL NUAPADA NILAJI, RAIPUR, C.G.		


Weight : 89.8kg Height : 5.7' Temp : 97.8° B.P. : 150/91 Pulse : 88 B/M SPO2 : 97%

📍 Near Railway Under Bridge, Basant Vihar Gate No. 1, Gondwara Chowk, Gudhiyari, Raipur (Chhattisgarh)

☎ 0771-43 43 161, 0771-43 40 162, 📞 8404 8404 79

✉ shreeramhospital.op@gmail.com 🌐 www.srmhraipur.com

✉ shreeramhospital.op@gmail.com 🌐 www.srmhraipur.com





Shree Ram Multispeciality Hospital (SRMH)

Lokah Samasta Sukhino Bhavantu

PT. NAME : MR. LOKANATH SA
MOBILE NO : 8895818525 TEST NO 620
DOCTOR : DR. AJIT KUMAR
REFERRED BY : SELF

AGE / SEX : 67Y 2M 29D/FEMALE
UH ID NO. : SRMH-2408883
COLLECTION : 24-08-2024
REPORTING : 24-Aug-2024

HAEMATOLOGY

TEST NAME	RESULT	UNIT	NORMAL VALUES
CBC (COMPLETE BLOOD COUNT)			
HAEMOGLOBIN (Hb)	11.5	gm%	13.5 - 17.5
TOTAL RBC COUNT	4.68	Million/cumm	4.5 - 5.9
HAEMATOCRIT (PCV)	34.6	%	41.5 - 50.4
RBC INDICES			
MCV	77.1	fl	78 - 96
MCH	26.5	pg	27 - 32
MCHC	31.8	%	33 - 37
RDW	14.4	%	11 - 16
TOTAL WBC COUNT (TLC)	9200	/cumm	4000 - 11000
DIFFERENTIAL COUNT			
NEUTROPHILS	64	%	40 - 70
LYMPHOCYTES	28	%	22 - 48
EOSINOPHILS	03	%	0 - 6
MONOCYTES	05	%	2 - 10
BASOPHILS	00	%	-
PLATELET COUNT	2.08	/cumm	1.50 - 4.50
PCT	0.14	%	0.10 - 0.28
MPV(MEAN PLATELET VOLUME)	8.5	µm3	8 - 11
PDW	13.4	%	11 - 18

-- End Of Report --

LAB TECHNICIAN

Note : This Report is not for medicolegal purpose

Dr. Dhananjay Prasad
MBBS, MD (Pathologist)

📍 Near Railway Under Bridge, Basant Vihar Gate No. 1, Gondwara Chowk, Gudhiyari, Raipur (Chhattisgarh)

☎ 0771-43 43 161, 0771-43 40 162, 📞 8404 8404 79

✉ shreeramhospital.op@gmail.com 🌐 www.srmhraipur.com

24/7
Emergency Services





Shree Ram Multispeciality Hospital (SRMH)

L o k a h S a m a s t a S u k h i n o B h a v a n t u

PT. NAME : MR. LOKANATH SA
MOBILE NO : 8895818525 TEST NO 620
DOCTOR : DR. AJIT KUMAR
REFERRED BY : SELF

AGE / SEX : 67Y 2M 29D/FEMALE
UH ID NO. : SRMH-2408883
COLLECTION : 24-08-2024
REPORTING : 24-Aug-2024

HAEMATOLOGY

TEST NAME	RESULT	UNIT	NORMAL VALUES
BLOOD GROUPING AND RH TYPING			
BLOOD GROUP	"B"		-
RH FACTOR	POSITIVE		-

-- End Of Report --

LAB TECHNICIAN

Note : This Report is not for medicolegal purpose

Dr. Dhananjay Prasad
MBBS, MD (Pathologist)

📍 Near Railway Under Bridge, Basant Vihar Gate No. 1, Gondwara Chowk,
Gudhiyari, Raipur (Chhattisgarh)

☎ 0771-43 43 161, 0771-43 40 162, 📞 8404 8404 79

✉ shreeramhospital.op@gmail.com 🌐 www.srmhraipur.com





Shree Ram Multispeciality Hospital (SRMH)

Lokah Samasta Sukhino Bhavantu

PT. NAME : MR. LOKANATH SA
MOBILE NO : 8895818525 TEST NO 620
DOCTOR : DR. AJIT KUMAR
REFERRED BY : SELF

AGE / SEX : 67Y 2M 29D/FEMALE
UH ID NO. : SRMH-2408883
COLLECTION : 24-08-2024
REPORTING : 24-Aug-2024

BIOCHEMISTRY

TEST NAME	RESULT	UNIT	NORMAL VALUES
<u>CREATININE</u>			
CREATININE	0.92	mg / dl	0.6 - 1.2
<u>URIC ACID</u>			
URIC ACID	5.63	mg/dL	2.5 - 6.8

HAEMATOLOGY

TEST NAME	RESULT	UNIT	NORMAL VALUES
<u>ESR (ERYTHROCYTE SEDIMENTATION RATE)</u>			
ESR	15	mm at end of 1 h	0 - 20

-- End Of Report --

LAB TECHNICIAN

Note : This Report is not for medicolegal purpose

Dr. Dhyanjay Prasad
MBBS, MD (Pathologist)

📍 Near Railway Under Bridge, Basant Vihar Gate No. 1, Gondwara Chowk, Gudhiyari, Raipur (Chhattisgarh)

☎ 0771-43 43 161, 0771-43 40 162, 📞 8404 8404 79

✉ shreeramhospital.op@gmail.com 🌐 www.srmhraipur.com

✉ shreeramhospital.op@gmail.com 🌐 www.srmhraipur.com

24x7
Emergency
Services





Shree Ram Multispeciality Hospital (SRMH)

L o k a h S a m a s t a S u k h i n o B h a v a n t u

PT. NAME : MR. LOKANATH SA
MOBILE NO : 8895818525 TEST NO 620
DOCTOR : DR. AJIT KUMAR
REFERRED BY : SELF

AGE / SEX : 67Y 2M 29D/FEMALE
UH ID NO. : SRMH-2408883
COLLECTION : 24-08-2024
REPORTING : 24-Aug-2024

BIOCHEMISTRY

TEST NAME	RESULT	UNIT	NORMAL VALUES
HbA1c -Glycosylated hemoglobin			
HbA1c -Glycosylated hemoglobin	7.93	%	Normal Range : <6% Good Control : 6-7% fair Control : 7-8% Unsatisfactory Control : 8-10% Poor Control : >10% -
Estimated average plasma glucose	205.0	mg/dl	80 - 120

-- End Of Report --

LAB TECHNICIAN

Note : This Report is not for medicolegal purpose



Dr. Dhananjay Prasad
MBBS, MD (Pathologist)

📍 Near Railway Under Bridge, Basant Vihar Gate No. 1, Gondwara Chowk,
Gudhiyari, Raipur (Chhattisgarh)

☎ 0771-43 43 161, 0771-43 40 162, 📞 8404 8404 79

✉ shreeramhospital.op@gmail.com 🌐 www.srmhraipur.com

☎ 0771-43 43 161, 0771-43 40 162, 📞 8404 8404 79

✉ shreeramhospital.op@gmail.com 🌐 www.srmhraipur.com





Shree Ram Multispeciality Hospital (SRMH)

Lokah Samasta Sukhino Bhavantu

PT. NAME : MR. LOKANATH SA
 MOBILE NO : 8895818525 TEST NO 620
 DOCTOR : DR. AJIT KUMAR
 REFERED BY : SELF

AGE / SEX : 67Y 2M 29D/FEMALE
 UH ID NO. : SRMH-2408883
 COLLECTION : 24-08-2024
 REPORTING : 24-Aug-2024

TEST NAME	BIOCHEMISTRY		
	RESULT	UNIT	NORMAL VALUES
LIVER FUNCTION TEST (LFT)			
BILIRUBIN TOTAL	0.52	mg/dL	0.2 - 1
BILIRUBIN DIRECT	0.23	mg / dl	0.1 - 0.6
BILIRUBIN INDIRECT	0.29	mg / dl	0.1 - 0.4
SGOT	35.2	U / L	0 - 46
SGPT	31.6	U / L	0 - 40
ALKALINE PHOSPHATASE	201.5	U / L	0 - 240
TOTAL PROTEIN	6.32	g / dl	6 - 8
ALBUMIN	3.67	g/dl	3.5 - 5.0
GLOBULIN	2.65	g / dl	2 - 3.5
A/G RATIO	1.38		1 - 2.5

Clinical Significance

Alanine transaminase (ALT)

ALT is an enzyme found in the liver that helps your body metabolize protein. When the liver is damaged, ALT is released into the bloodstream and levels increase.

Aspartate transaminase (AST)

AST is an enzyme that helps metabolize alanine, an amino acid. Like ALT, AST is normally present in blood at low levels. A increase in AST levels may indicate liver damage or disease or muscle damage.

Alkaline phosphatase (ALP)

ALP is an enzyme in the liver, bile ducts and bone. Higher-than-normal levels of ALP may indicate liver damage or disease, such as a blocked bile duct, or certain bone diseases.

Albumin and total protein

Albumin is one of several proteins made in the liver. Your body needs these proteins to fight infections and to perform other functions. Lower-than-normal levels of albumin and total protein might indicate liver damage or disease.

Bilirubin.

Bilirubin is a substance produced during the normal breakdown of red blood cells. Bilirubin passes through the liver and is excreted in stool. Elevated levels of bilirubin (jaundice) might indicate liver damage or disease or certain types of anemia.

-- End Of Report --

LAB TECHNICIAN

Dr. Dhananjay Prasad
MBBS, MD (Pathologist)

Note : This Report is not for medicolegal purpose

📍 Near Railway Under Bridge, Basant Vihar Gate No. 1, Gondwara Chowk, Gudhiyari, Raipur (Chhattisgarh)

☎ 0771-43 43 161, 0771-43 40 162, 📞 8404 8404 79

✉ shreeramhospital.op@gmail.com 🌐 www.srmhraipur.com

✉ shreeramhospital.op@gmail.com 🌐 www.srmhraipur.com





Shree Ram Multispeciality Hospital (SRMH)

Lokah Samasta Sukhino Bhavantu

PT. NAME : MR. LOKANATH SA
 MOBILE NO : 8895818525 TEST NO 620
 DOCTOR : DR. AJIT KUMAR
 REFERED BY : SELF

AGE / SEX : 67Y 2M 29D/FEMALE
 UH ID NO. : SRMH-2408883
 COLLECTION : 24-08-2024
 REPORTING : 24-Aug-2024

BIOCHEMISTRY

TEST NAME	RESULT	UNIT	NORMAL VALUES
BLOOD SUGAR - FASTING AND PP			
BLOOD SUGAR FASTING	164.5	mg/dL	70 - 120
BLOOD SUGAR PP	337.6	mg/dL	80 - 140

CLINICAL PATHOLOGY

TEST NAME	RESULT	UNIT	NORMAL VALUES
URINE SUGAR FASTING AND PP			
URINE SUGAR FASTING	Present (+)		Absent -
URINE SUGAR PP	Present (+++)		Absent -

-- End Of Report --

LAB TECHNICIAN

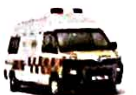Dr. Dhananjay Prasad
 MBBS, MD (Pathologist)

Note : This Report is not for medicolegal purpose

📍 Near Railway Under Bridge, Basant Vihar Gate No. 1, Gondwara Chowk, Gudhiyari, Raipur (Chhattisgarh)

☎ 0771-43 43 161, 0771-43 40 162, 📞 8404 8404 79

✉ shreeramhospital.op@gmail.com 🌐 www.srmhraipur.com





Shree Ram Multispeciality Hospital (SRMH)

L o k a h S a m a s t a S u k h i n o B h a v a n t u

Mr.LOKANATH SA

Sample Collected At :

Registered : 24 Aug,24 01:39PM

Age: 67 Years

Ref By : Dr.AJIT KUMAR

Collected : 24 Aug,24 01:30PM

Sex:-Male

UH ID NO. – SRMH -2408883

Reported : 25 Aug,24 11:45AM


GAMAMA GLUTAMYL TRANSFERASE (GGT)

INVESTIGATION	RESULT	REFERENCE VALUE	UNIT
GAMMA – GLUTAMYL TRANSFERASE (GGT) , SERUM	16.3	12.00-18.00	U/L

GENDER	-	NORMAL RANGE(U/L)
MALE	-	12.00-18.00
FEMALE	-	6.00-29.00

COMMENTS:-

Gamma – Glutamyl Transferase (Ggt) Is An Enzyme That Is Found In Many Organs Throughtout The Body , With The Highest Concentrations Found In The Liver .Ggt Is Elevated In The Blood In Most Diseases That Cause Damage To The Liver Or Bile Ducts ,This Test Measures The Level Of Ggt In A Blood Samle.

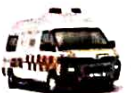
 DR. DHANANJAY PRASAD
 (MD Pathology)

📍 Near Railway Under Bridge, Basant Vihar Gate No. 1, Gondwara Chowk, Gudhiyari, Raipur (Chhattisgarh)

☎ 0771-43 43 161, 0771-43 40 162, 📞 8404 8404 79

✉ shreeramhospital.op@gmail.com 🌐 www.srmhraipur.com

24/7
Emergency
Services





Shree Ram Multispeciality Hospital (SRMH)

Lokah Samasta Sukhino Bhavantu

Mr LOKANATH SA
Age: 67 Years Sex: Male


Sample Collected At:
Ref. By: Dr. AJIT KUMAR (MD)
UH ID NO. - SRMH - 2408883

Registered: 24 Aug, 24 01:40 PM
Collected: 24 Aug, 24 01:25 PM
Reported: 24 Aug, 24 06:51 PM

BUN / Creatinine Ratio PANAL

Investigation	Observed Value	Unit	Biological Reference Interval
BUN			
BUN	16.5	mg/dL	7.00 - 20.00
Serum Creatinine	0.92	mg/dL	0.55 - 1.20
BUN / Creatinine Ratio	17.93		10:1 - 20:1

Blood urea nitrogen (BUN) is a waste product produced when the liver breaks down protein. The kidneys then filter it out of the blood and eliminate it through urine. Creatinine is a waste product created by the breakdown of phosphocreatine, a molecule stored in muscle tissue. The kidneys filter creatinine from the blood, and its levels in the body reflect the efficiency of the kidney's excretory function. therefore, BUN and creatinine are useful markers in assessing kidney health because they help doctors evaluate the kidney's filtration rate.

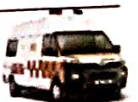

Dr. D. Prasad
M.D (Pathologist)

📍 Near Railway Under Bridge, Besant Vihar Gate No. 1, Gondwara Chowk,
Gudhiyari, Raipur (Chhattisgarh)

☎ 0771-43 43 161, 0771-43 40 162, 📞 8404 8404 79

✉ shreeramhospital.op@gmail.com 🌐 www.srmhraipur.com





Shree Ram Multispeciality Hospital (SRMH)

L o k a h S a m a s t a S u k h i n o B h a v a n t u

Mr LOKANATH SA
Age: 67 Years Sex: Male

Sample Collected At:
Ref. By: Dr. AJIT KUMAR (MD)
UH ID NO. – SRMH - 2408883

Registered: 24 Aug, 24 01:40 PM
Collected: 24 Aug, 24 01:25 PM
Reported: 24 Aug, 24 06:51 PM


TFT

Thyroid Function Test (TFT)

Investigation	Observed Value	Unit	Biological Reference Interval
THYROID SERUM HORMONS			
Serum Triiodothyronine (T3)	0.95	ng/mL	0.89 - 1.87
Serum thyroxine (T4)	9.54	ug/dL	5.1 - 14.28
Thyroid Stimulating Hormone (TSH)	1.05	μIU/mL	0.66 - 5.67

Comments:-

- (i) Ethnicity, iodine intake, gender, age, body mass index and Exercise influences the reference range of Thyroid hormones and serum TSH concentrations.
- (ii) Changes in Thyroid Hormones (especially T3) and TSH may be seen as early as 24 hours after the onset of non-thyroidal illness. (Poor nutrition/starvation, sepsis, burns, malignancy, myocardial infarction, post-surgery, and with chronic liver and renal disease)
- (iii) Serum total T4 and T3 concentrations increase to approximately 150% of non-pregnant values – this occurs during the first half of pregnancy and is maintained thereafter until parturition. Free T4 concentrations also change during pregnancy: in the first trimester a transient rise is often observed.
- (iv) Measurement of FT4 and FT3 is best avoided in patients receiving heparin therapy. (When indicated, blood sample should be taken 10 hours after the last injection of heparin, and analyzing it without delay, can reduce the risk of artifactual hyperthyroxaemia.)
- (v) Phenytoin, carbamazepine and furosemide cause artifactual increase in free T4 (FT4) and decrease in total T4.



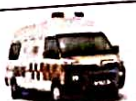Dr. D. Prasad
M.D. (Pathologist)

Near Railway Under Bridge, Basant Vihar Gate No. 1, Gondwara Chowk, Gudhiyari, Raipur (Chhattisgarh)

☎ 0771-43 43 161, 0771-43 40 162, 📞 8404 8404 79

✉ shreeramhospital.op@gmail.com 🌐 www.srmhraipur.com

24/7
Emergency
Services



Shree Ram Multispeciality Hospital (SRMH)

Lokah Samasta Sukhino Bhavantu

PT. NAME : MR. LOKANATH SA
MOBILE NO : 8895818525 TEST NO 620
DOCTOR : DR. AJIT KUMAR
REFERRED BY : SELF

AGE / SEX : 67Y 2M 29D/FEMALE
UH ID NO. : SRMH-2408883
COLLECTION : 24-08-2024
REPORTING : 24-Aug-2024

CLINICAL PATHOLOGY

TEST NAME	RESULT	UNIT	NORMAL VALUES
URINE ROUTINE AND MICROSCOPY			
PHYSICAL EXAMINATION			
QUANTITY	20	ml	-
COLOUR	Yellow		Pale Yellow -
APPEARANCE	Clear		Clear -
REACTION	Acitic		Acitic -
CHEMICAL EXAMINATION			
ALBUMIN	Trace(+)		Absent -
SUGAR	Present (+)		Absent -
KETONE	Absent		Absent -
BILE SALT	Absent		Absent -
BILE PIGMENT	Absent		Absent -
MICROSCOPIC EXAMINATION			
PUS CELLS	4-6	/hpf	2 - 5
EPITHELIAL CELLS	2-4	/hpf	1 - 5
RBC	Nil	/hpf	0 - 3
CAST	Nil	/lpf	Nil -
YEAST	Nil		Nil -
CRYSTAL	Nil	/lpf	Nil -
BACTERIA	Nil		Nil -
OTHERS	-		-

-- End Of Report --

LAB TECHNICIAN

Note : This Report is not for medicolegal purpose

Dr. Dhananjay Prasad
MBBS, MD (Pathologist)

© Near Railway Under Bridge, Basant Vihar Gate No. 1, Gondwara Chowk,
Gudhiyari, Raipur (Chhattisgarh)

© 0771 42 42 161 0771 42 40 162 ☎ 9404 9404 70





Shree Ram Multispeciality Hospital (SRMH)

Lokah Samasta Sukhino Bhavantu

PT. NAME : MR. LOKANATH SA
MOBILE NO : 8895818525 TEST NO 620
DOCTOR : DR. AJIT KUMAR
REFERRED BY : SELF

AGE / SEX : 67Y 2M 29D/FEMALE
UH ID NO. : SRMH-2408883
COLLECTION : 24-08-2024
REPORTING : 24-Aug-2024


BIOCHEMISTRY

TEST NAME	RESULT	UNIT	NORMAL VALUES
LIPID PROFILE			
CHOLESTEROL	238.4	mg / dl	150 - 220
SERUM TRYGLYCERIDE	163.5	mg / dl	60 - 165
HDL	32.1	mg / dl	35 - 80
LDL	206.3	mg/dL	90 - 160
VLDL	32.7	mg/dL	20 - 50
CHOLESTEROL / HDL RATIO	7.42	mg/dL	3.5 - 5.5
LDL/HDL Ratio	6.42	mg / dl	2.5 - 3.5
TRIGLYCERIDES / HDL RATIO	5.09	mg / dl	2.0 - 4.0

-- End Of Report --

LAB TECHNICIAN

Note : This Report is not for medicolegal purpose



Dr. Dhananjay Prasad
MBBS, MD (Pathologist)

📍 Near Railway Under Bridge, Basant Vihar Gate No. 1, Gondwara Chowk, Gudhiyari, Raipur (Chhattisgarh)

☎ 0771-43 43 161, 0771-43 40 162, 📞 8404 8404 79

✉ shreeramhospital.op@gmail.com 🌐 www.srmhraipur.com





DATE- 24-Aug-24

PATIENT NAME MR. LOKHNATH SA .
AGE/SEX 67 YEAR / MALE
REF. BY SHREE RAM MULTISPECIALITY HOSPITAL

SONOGRAPHY OF THE ABDOMEN

PROCEDURE DONE BY ULTRASOUND MACHINE Canon Apilo a450 (4D COLOR DOPPLER)

LIVER : The liver is normal in size, shape & contour with **raised echotexture**. No evidence of any Focal lesion or mass seen. The intrahepatic biliary ducts are normal. The CBD is normal in course, caliber & contour. Hepatic & portal vein appear normal in morphology.

GALL BLADDER : Well distended & shows normal wall thickness. No obvious intraluminal calculus.

PANCREAS : It is normal echogenicities and size, shape. Pancreatic duct is normal.

SPLEEN : Spleen is normal size, shape and position. No focal lesion seen.

KIDNEY : Right kidney measures cm.
Left kidney measures cm.
Both Kidneys are normal size, shape and position.
Renal parenchymal echogenicities are normal.,
No evidence of any calculus or pelvicalyceal dilation.

URINARY BLADDER: UB is well distended . No evidence of mass /calculus. **Mild thickened urinary bladder wall with max. thickness 6.2 mm.**

PROSTATE : It is normal in size, shape & smooth outlines.

RETRO PERITONEUM : No evidence of lymphadenopathy / mass.

FREE FLUID : No free fluid seen in abdomen & peritoneal cavity.
Mild gaseous distended bowel loops seen.

IMPRESSION:

- Fatty liver Grade- I
- Mild thickened urinary bladder wall.- Likely cystitis (Advice- Urine R/M)
- Mild gaseous distended bowel loops seen

Needs clinical correlation & other investigations.


DR. Yatendra Nath Singh
DMRD, UNB; EDiR
Consultant Radiologist

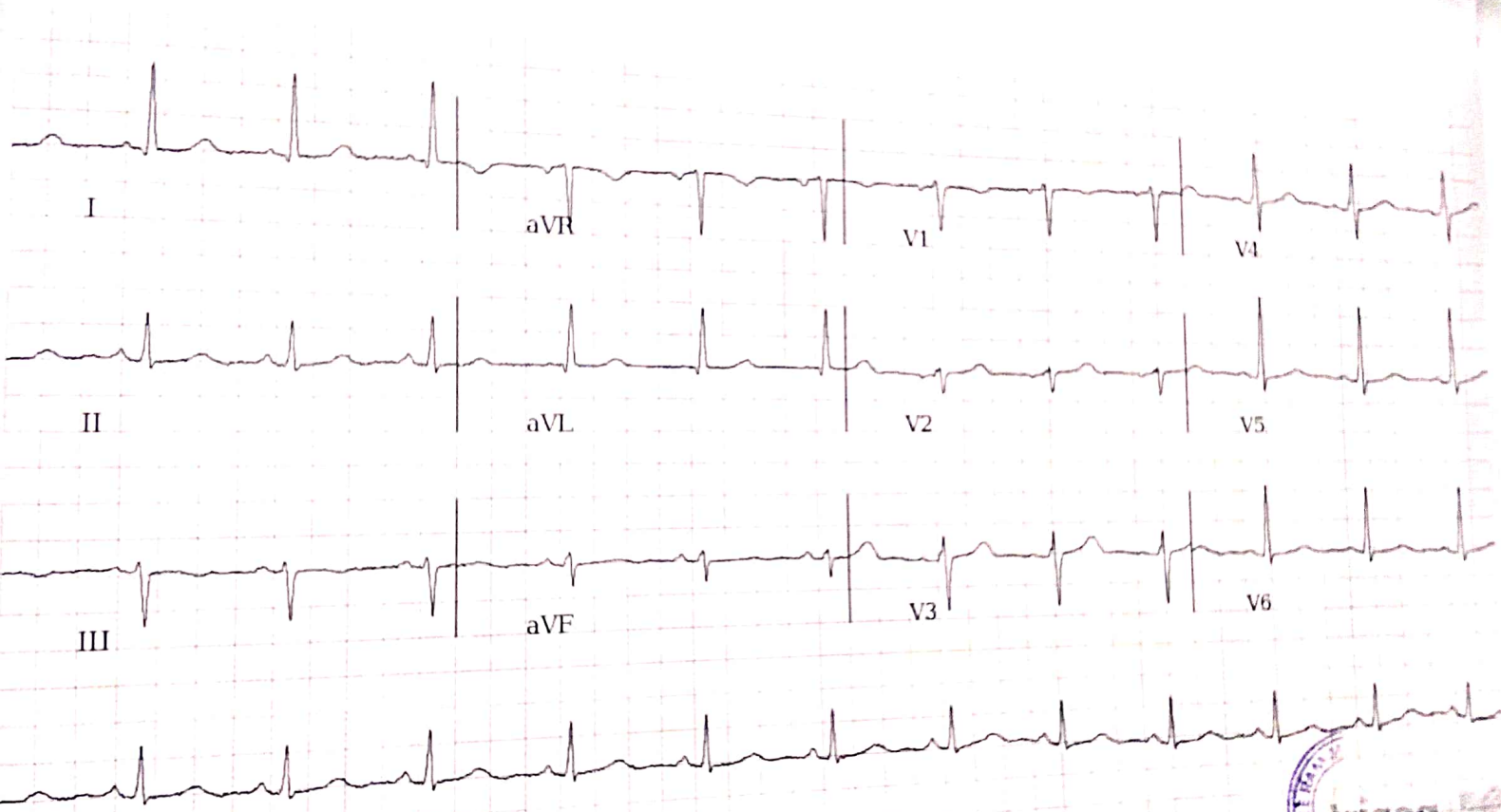
Investigations have their limitation, solitary radiological / pathological and other investigations never confirm the final diagnosis of disease. They only help in diagnosing the disease in correlation to symptom and other related test please interpret accordingly.

Kindly Note:-

- The report and films are not valid for medico – legal purpose.
- Please Intimate us if any typing mistakes and send the report for correction within 7 days.
- पुराना यंत्रों का उपयोग करने से होने वाले त्रुटिपूर्ण रिपोर्टों का उपयोग न करें, संप्रति रायपुर (छ.ग.)

सही जाँच ही सही ईलाज का 3

Dr. Lokanath



II




25.0 mm/s 10.0 mm/mV

0.5-40Hz. 50Hz

ECG-3000-71-4 3. 200 1.1.0. VCard 4 by Thcop-8.6.0

*Clinical interpretation of the ECG REPORT may be affected by the FILTER settings





Shree Ram Multispeciality Hospital (SRMH)

L o k a h S a m a s t a S u k h i n o B h a v a n t u

ECHOCARDIOGRAPHY REPORT

Name	Mr. Lokanath Sa	Age / Sex	67 years / Male
Date	24-08-2024	UHID no	2408883

PULMOANRY VELOCITY ; 0.76 m/s

AORTIC VELOCITY : 0.89 m/s

TRICUSPID VELOCITY : 1.99 m/s

PASP : 18 mmHg + RAP

M-Measurement Value


Aorta	2.7	LVEDD	4.9
LA	3.5	IVSD	1.0
LVEF	>60%	LVPWD	1.0

FINAL IMPRESSION

- S/P CABG
- Normal Cardiac Chambers & Dimension
- No RWMA
- Normal LV Systolic Function
- LVEF >60%
- Trace TR / MR, PASP 18 mmHg + RAP
- No Clot/PE / Vegetation

Dr. Nikhil Motiramani

(MBBS, MD,DM Card)


Dr. Ajay Halbai
(MBBS, MD)



📍 Near Railway Under Bridge, Basant Vihar Gate No. 1, Gondwara Chowk
Gudhiyari, Raipur (Chhattisgarh)

☎ 0771 40 40 40 0771 40 40 40 0771 40 40 40

24/7



Shree Ram Multispeciality Hospital (SRMH)

L o k a h S a m a s t a S u k h i n o B h a v a n t u

Department of Radiology

NAME -; Mr. Lokanth Sa	AGE - 67 YEAR /M
REF.BY -; SHREE RAM MULTI SPECIALITY HOSPITAL	DATE - 24/08/2024

X – RAY CHEST PA VIEW.

FINDINGS:

- Bilateral lung parenchyma is clear.
- Both apices free.
- Trachea in mid line.
- C T ratio within normal limits.
- Both hila are normal.
- Both costo & cardiophrenic angles are clear.
- Bony cage normal.
- Soft tissue appears normal.

IMPRESSION :

No significant abnormality detected.



DR ANAND BANSAL

MD DNB RADIODIAGNOSIS

CONSULTANT RADIOLOGIST

CGMC 2015/6359

📍 Near Railway Under Bridge, Basant Vihar Gate No. 1, Gondwara Chowk,
Gudhiyari, Raipur (Chhattisgarh)

☎ 0771-43 43 161, 0771-43 40 162, 📞 8404 8404 79

✉ shreeramhospital.op@gmail.com 🌐 www.srmhraipur.com

24/7
Emergency
Services



