



भारतीय विशिष्ट पहचान प्राधिकरण


Unique Identification Authority of India

पता:

W/O सचिन कुमार, 40-सी, ईडी - ब्लॉक, पीतमपुरा,
पीतमपुरा, उत्तर पश्चिमी,
दिल्ली - 110034

Address:

W/O Sachin Kumar, 40-C, ED -Block,
Pitampura, Pitampura, North West Delhi,
Delhi - 110034



QR Code with Photograph

4416 2210 7844

VID : 9104 2608 8718 8665

1947



help@uidai.gov.in



www.uidai.gov.in

Sach



भारत सरकार
Government of India



प्रीती दलाल
Preeti Dalal
जन्म तिथि/DOB: 26/02/1983
महिला/ FEMALE

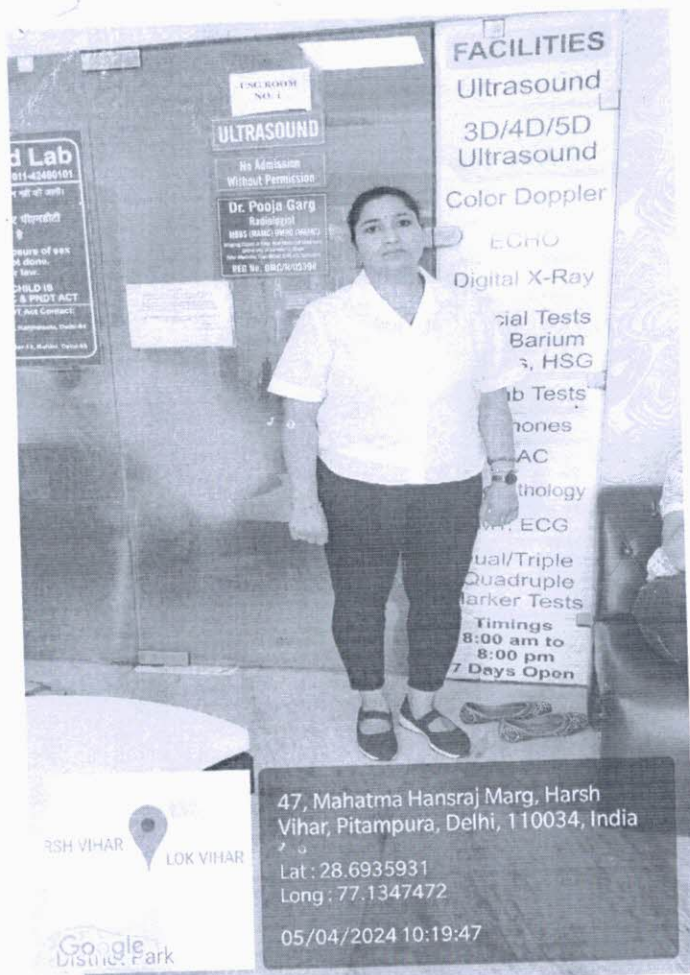
4416 2210 7844

VID : 9104 2608 8718 8665

मेरा आधार, मेरी पहचान


Dr. NITIN AGARWAL
MBBS, MD
Regn. No. DMC-R-1436

ONEPLUS ULTRASOUND LAB
47 Harsh Vihar, Pitam Pura,
Delhi-110034
Ph. 011-42480101, 9599913051
E-mail onepusul@gmail.com



Pooja

[Signature]
DR. NITIN AGARWAL
MBBS, MD
Regn. No. DMC-R-1436

ONEPLUS ULTRASOUND LAB
47 Harsh Vihar, Pitam Pura,
Delhi-110034
Ph. 011-42480101, 9599913051
E-mail onepusul@gmail.com

ONEPLUS ULTRASOUND LAB

47, HARSH VIHAR, PITAMPURA, DELHI- 110034

Ms. PREETI DALAL
 ID : 2546
 Age : 47/F
 Ref. by : MEDWHEEL
 Indication1 :
 Indication2 :
 Indication3 :
 COMMENTS : Short PR Interval To be Ruled Out Sinus Rhythm.

Recorded : 5-4-2024 11:13
 Medication1 :
 Medication2 :
 Medication3 :

[Signature]

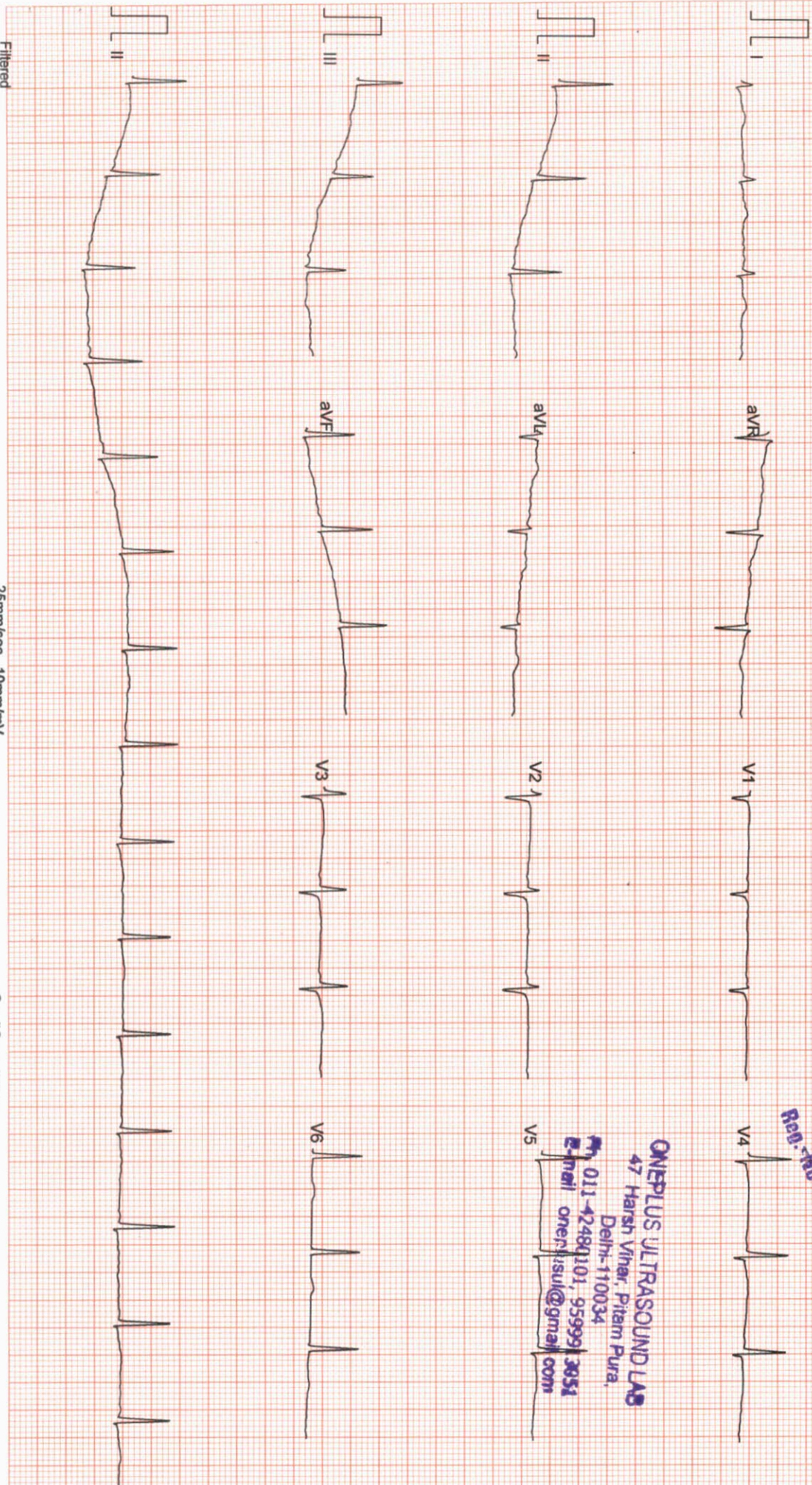
BPM : 90
 BP : 134/92
 P Axis : -29 deg
 QRS Axis : 78 deg
 T Axis : -22 deg

P duration : 90 msec
 PR duration : 103 msec
 QRS duration : 93 msec
 QT interval : 333 msec
 QTc interval : 385 msec

Unconfirmed Report Reviewed By:
 Cardiologist

Dr. P. K. Gupta, MD
 Reg. No. 101071

ONEPLUS ULTRASOUND LAB
 47 Harsh Vihar, Pitam Pura,
 Delhi-110034
 Phone: 011-42480101, 959993851
 E-mail: onepplus@gmail.com



Filtered

25mm/sec 10mm/mV

CardiCom, INDIA

ONEPLUS ULTRASOUND LAB

47, HARSH VIHAR PITAMPURA DELHI 110034

Ms. PREETI DALAL
 ID : 984
 Age : 41/F
 Ref by : MEDIVHEEL
 Indication1 :
 Indication2 :
 Indication3 :

Recorded : 5-4-2024 11:16
 Hwht : 160/86

TREADMILL TEST SUMMARY REPORT
 Protocol : BRUCE
 History :
 Medication1 :
 Medication2 :
 Medication3 :

PHASE	PHASE TIME	STAGE TIME	SPEED (Km./Hr.)	GRADE (%)	H.R. (BPM)	B.P. (mmHg)	RPP X100	II	ST LEVEL (mm) V2	V5	NETS
SUPINE					89	134/92	119	0.1	0.2	0.0	
STANDING					102	134/92	136	-0.1	0.2	0.0	
HYPERVENT	0:01	0:01			97	134/92	129	-0.1	0.2	0.0	
STAGE 1	2:59	2:59	2.70	10.00	124	134/92	166	-0.8	0.3	0.1	4.80
STAGE 2	5:59	2:59	4.00	12.00	151	150/94	226	-0.9	-0.2	-0.5	7.10
STAGE 3	6:29	0:29	5.40	14.00	158	160/96	252	-1.1	-0.1	-0.6	7.57
PEAK EXER	6:34	0:34			155	160/96	248	-1.2	-0.1	-0.5	7.65
RECOVERY	2:59	2:59	0.00	0.00	105	136/92	142	-0.4	-0.1	-0.5	

RESULTS

Exercise Duration : 6:34 Minutes
 Max Heart Rate : 158 bpm 88 % of target heart rate 179 bpm
 Max Blood Pressure : 160/96 mmHg
 Max Work Load : 7.65 METS
 Reason of Termination :

IMPRESSIONS

Regular for vehicle riding

Dr. P.K. GUPTA
 MBBS, MD
 Cardiologist

[Signature]

ONEPLUS ULTRASOUND LAB
 47 Harsh Vihar, Pitam Pura,
 Delhi-110034
 Ph. 011-42480101, 9599913051
 E-mail onecplus@gmail.com

ONEPLUS ULTRASOUND LAB

SUPINE
PRETEST

ST @ 10mm/mV
80ms PostJ

Ms. PREETI DALAL

ID : 984


AGE/SEX : 41/F

RECORDED : 5-4-2024 11:16

RATE : 89 BPM

B.P. : 134/92 mmHg

RAW E.C.G.



ONEPLUS ULTRASOUND LAB
47 Harsh Vihar, Pitam Pura,
Delhi-110034
Ph. 011-42460101, 9599913951
E-mail onerplusul@gmail.com

Filtered

25mm/sec 10mm/mV

CardiCom, INDIA Ph.:091-731-2620740, Tele/Fax:091-731-2431214

ONEPLUS ULTRASOUND LAB

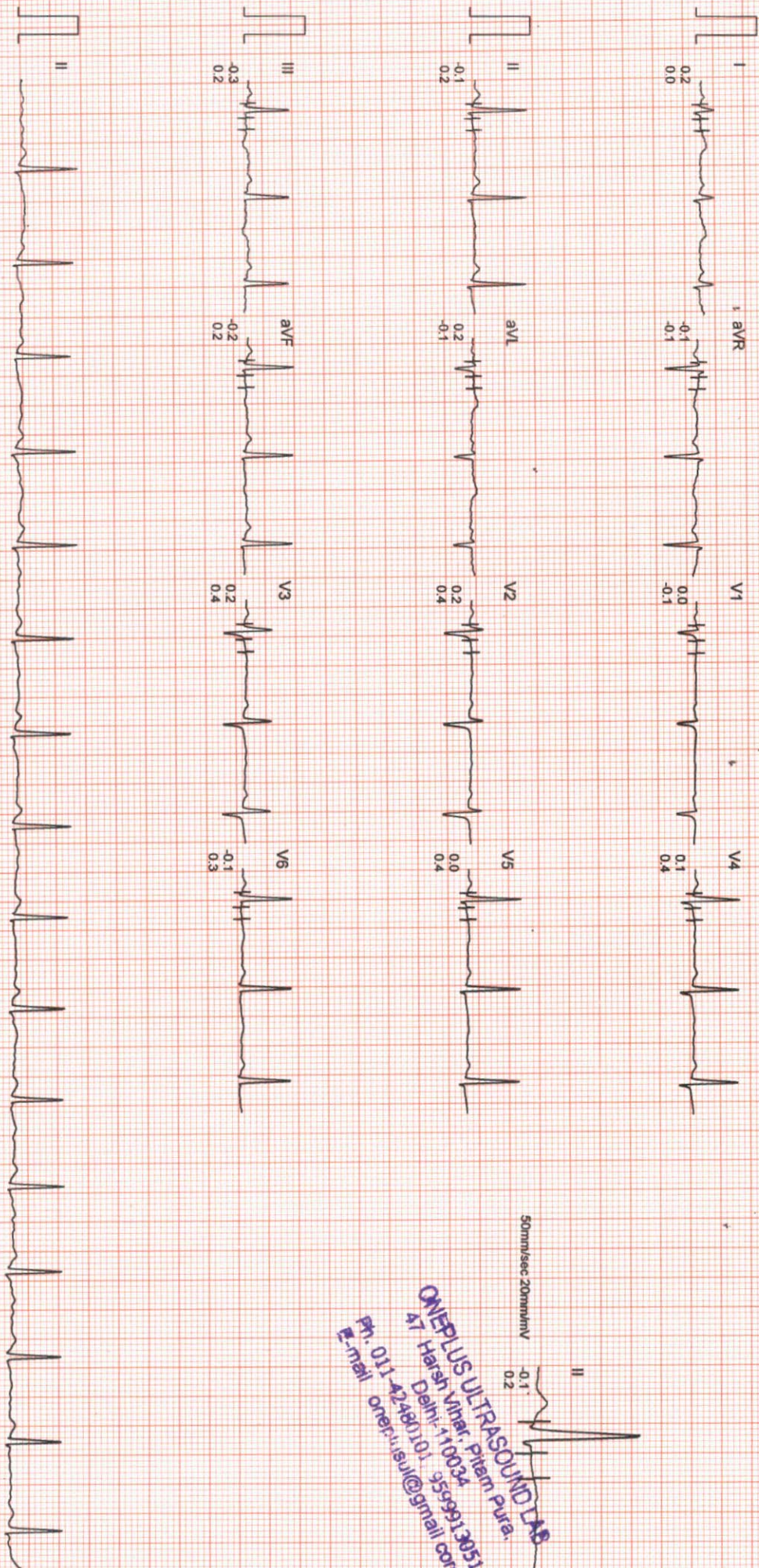
STANDING
PRETEST

ST @ 10mm/mV
80ms PostJ

Ms. PREETI DALAL
I.D. : 984
AGE/SEX : 41/F
RECORDED : 5-4-2024 11:16

RATE : 102 BPM
B.P. : 134/92 mmHg

LINKED MEDIAN



ONEPLUS ULTRASOUND LAB
47 Harsh Vihar, Pitam Pura,
Delhi-110034
Ph. 011-42481101, 3599913051
E-mail: onep.usul@gmail.com

Filtered

Computer Corrected Baseline

25mm/sec 10mm/mV

CardiCom, INDIA Ph.:091-731-2620740, TeleFax:091-731-2431214

ONEPLUS ULTRASOUND LAB

HYPERVENTILATION
PRETEST

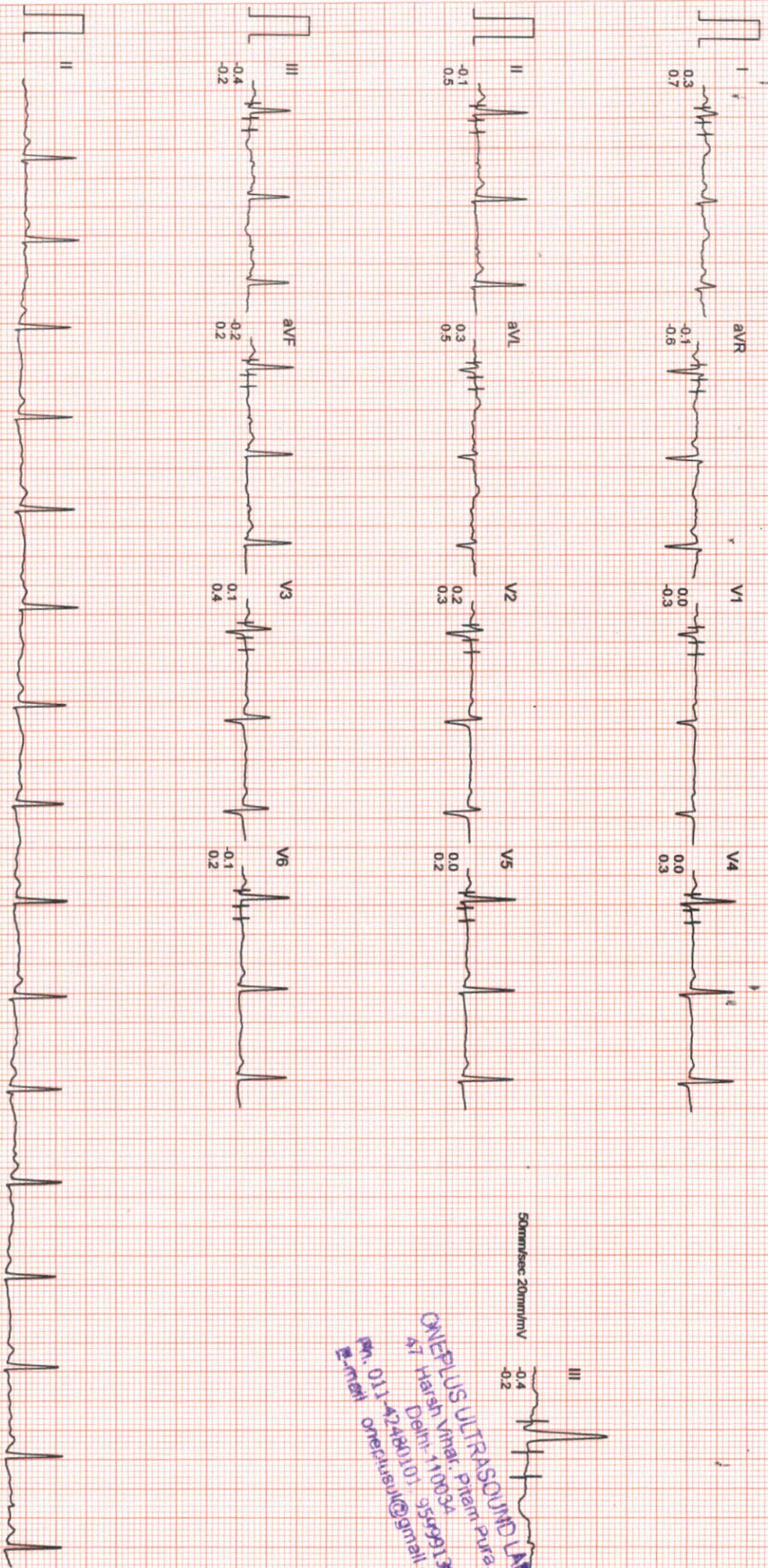
ST @ 10mm/mV
80ms PostJ

Ms. PREETI DALAL
I.D. : 984
AGE/SEX : 41/F
RECORDED : 5-4-2024 11:16

RATE : 97 BPM
B.P. : 134/92 mmHg

STAGE TIME : 0:01

LINKED MEDIAN



50mm/sec 20mm/mV

ONEPLUS ULTRASOUND LAB
47 Harsh Vihar, Pitam Pura,
Delhi-110034
Ph. 011-4248010, 9599913851
E-mail: onepplus@gmail.com

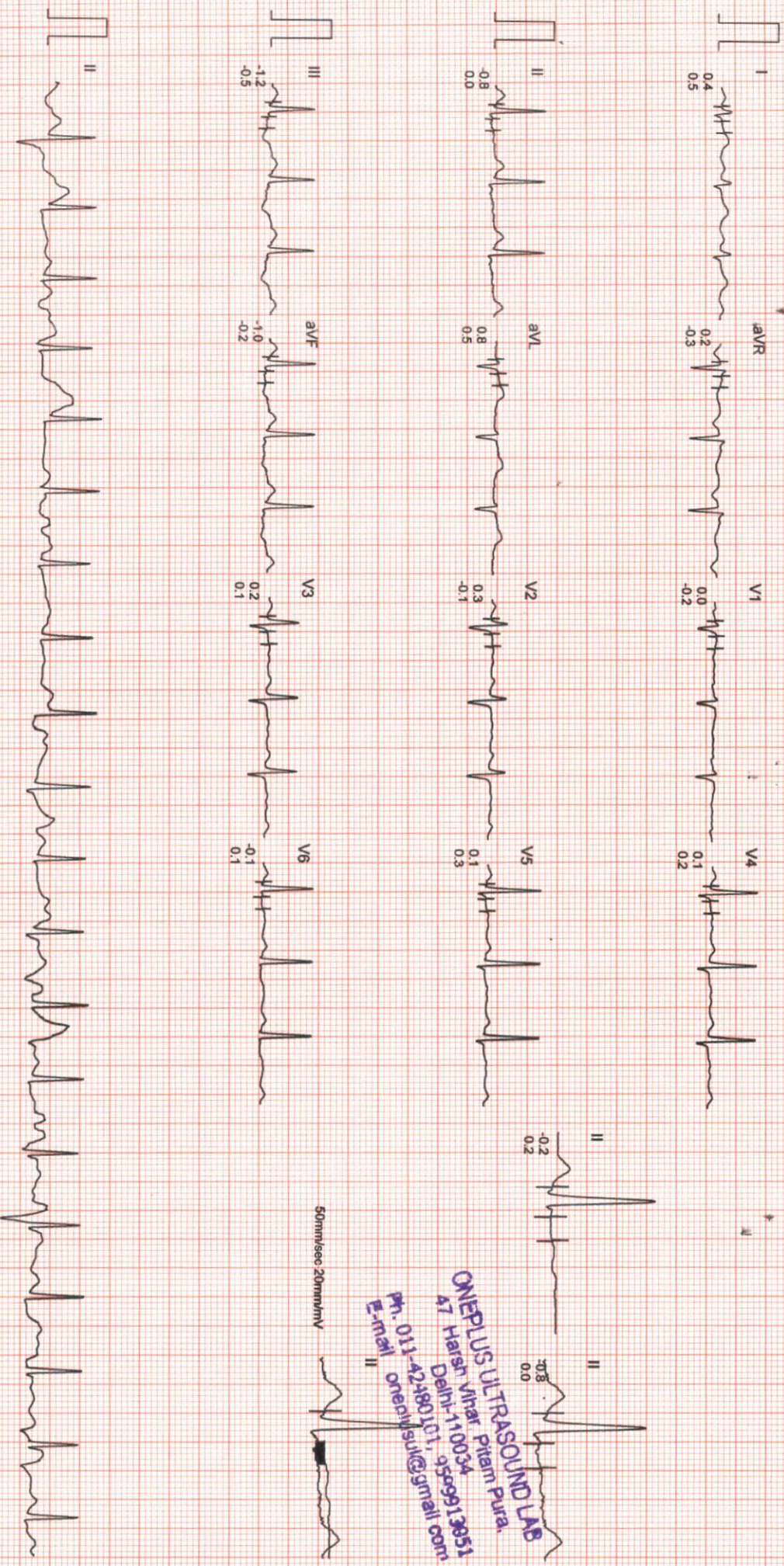
ONEPLUS ULTRASOUND LAB

Ms. PREETI DALAL
I.D. : 984
AGE/SEX : 41/F
RECORDED : 5-4-2024 11:16

RATE : 124 BPM
B.P. : 134/92 mmHg

Manual Protocol2
EXERCISE 1
PHASE TIME : 2:59
STAGE TIME : 2:59

ST @ 10mm/mV
80ms PostJ
SPEED : 2.7 Km./Hr.
GRADE : 10.0 %
LINKED MEDIAN



ONEPLUS ULTRASOUND LAB
47 Harsr Vihar, Pitampura,
Delhi-110034
Ph. 011-42480111, 95509913851
Email: oneplusultrasound@gmail.com
Ernakul II

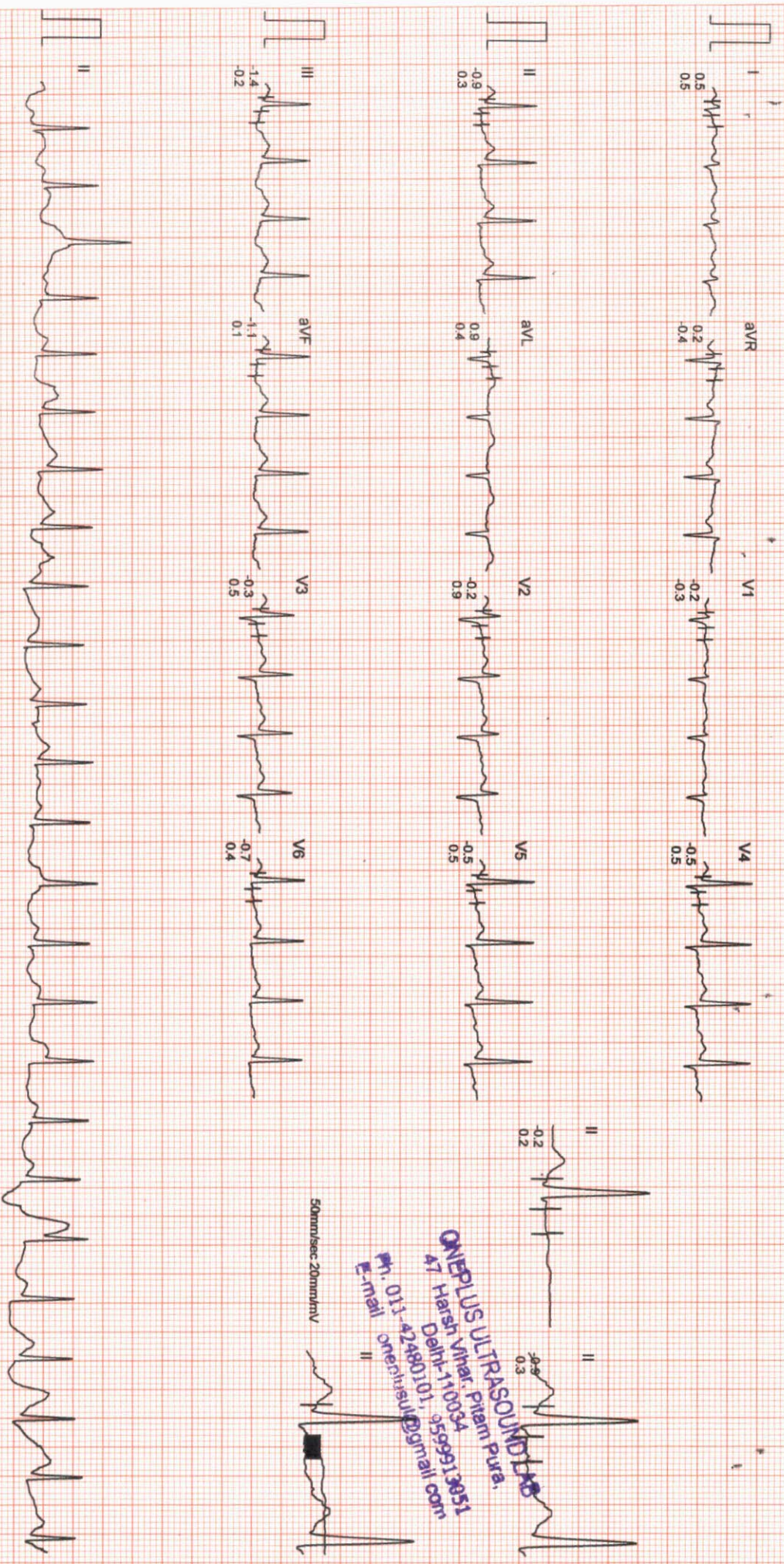
ONEPLUS ULTRASOUND LAB

Ms. PREETI DALAL
I.D. : 984
AGE/SEX : 41/F
RECORDED : 5-4-2024 11:16

RATE : 151 BPM
B.P. : 150/94 mmHg

Manual Protocol2
EXERCISE 2
PHASE TIME : 5:59
STAGE TIME : 2:59

ST @ 10mm/mV
80ms PostJ
SPEED : 4.0 Km./Hr.
GRADE : 12.0 %
LINKED MEDIAN



ONEPLUS ULTRASOUND LAB
47 Harsh Vihar, Piram Pura,
Delhi-110034
Ph. 011-2480101, 9559913951
E-mail: oneplusul@gmail.com

ONEPLUS ULTRASOUND LAB

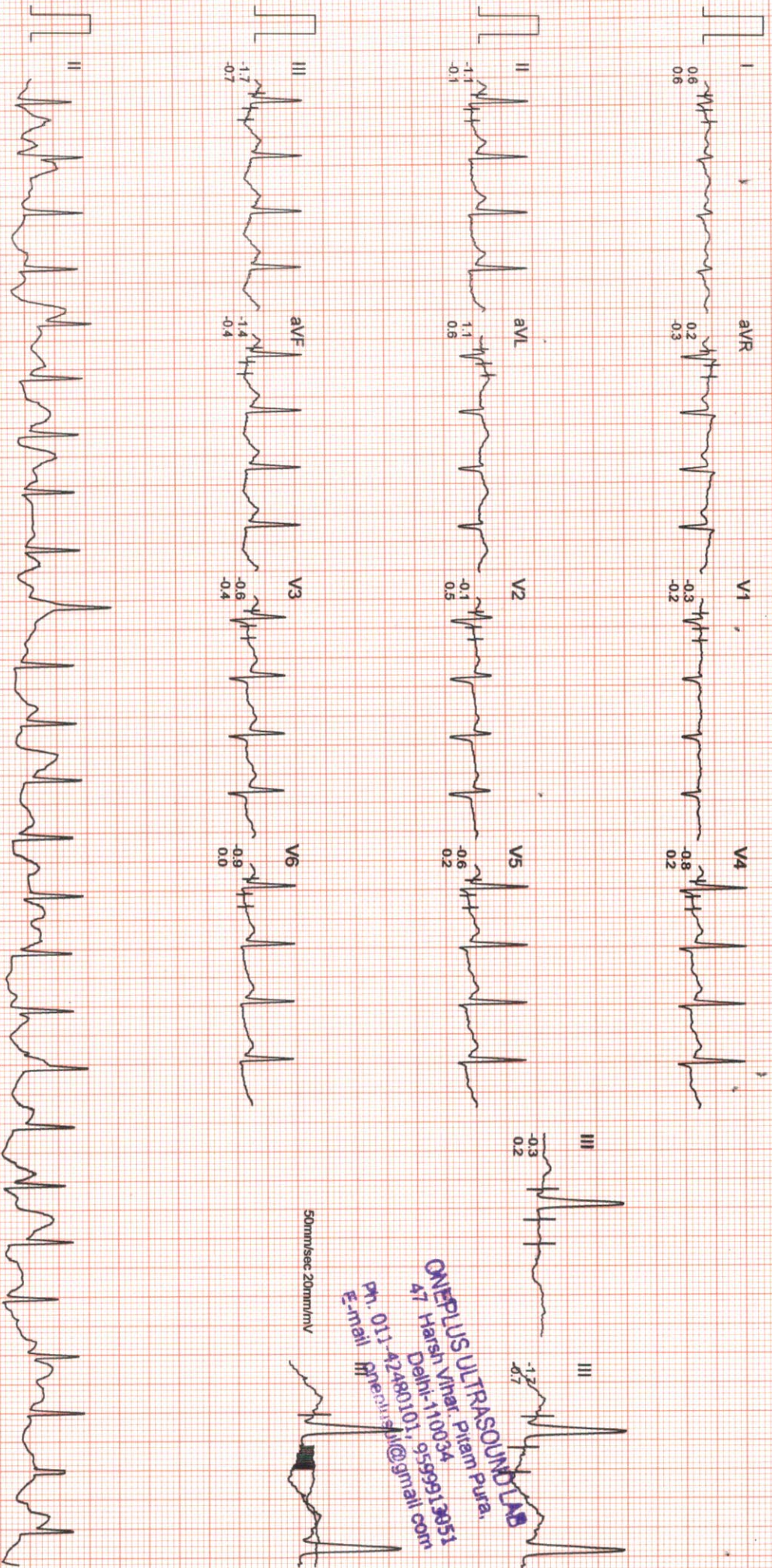
Ms. PREETI DALAL
ID : 984
AGE/SEX : 41/F
RECORDED : 5-4-2024 11:16

RATE : 158 BPM
B.P. : 160/96 mmHg

BRUCE
EXERCISE 3
PHASE TIME : 6:29
STAGE TIME : 0:29

ST @ 10mm/mV
80ms PostJ
SPEED : 5.4 Km./Hr.
GRADE : 14.0 %

LINKED MEDIAN



50mm/sec 20mm/mV

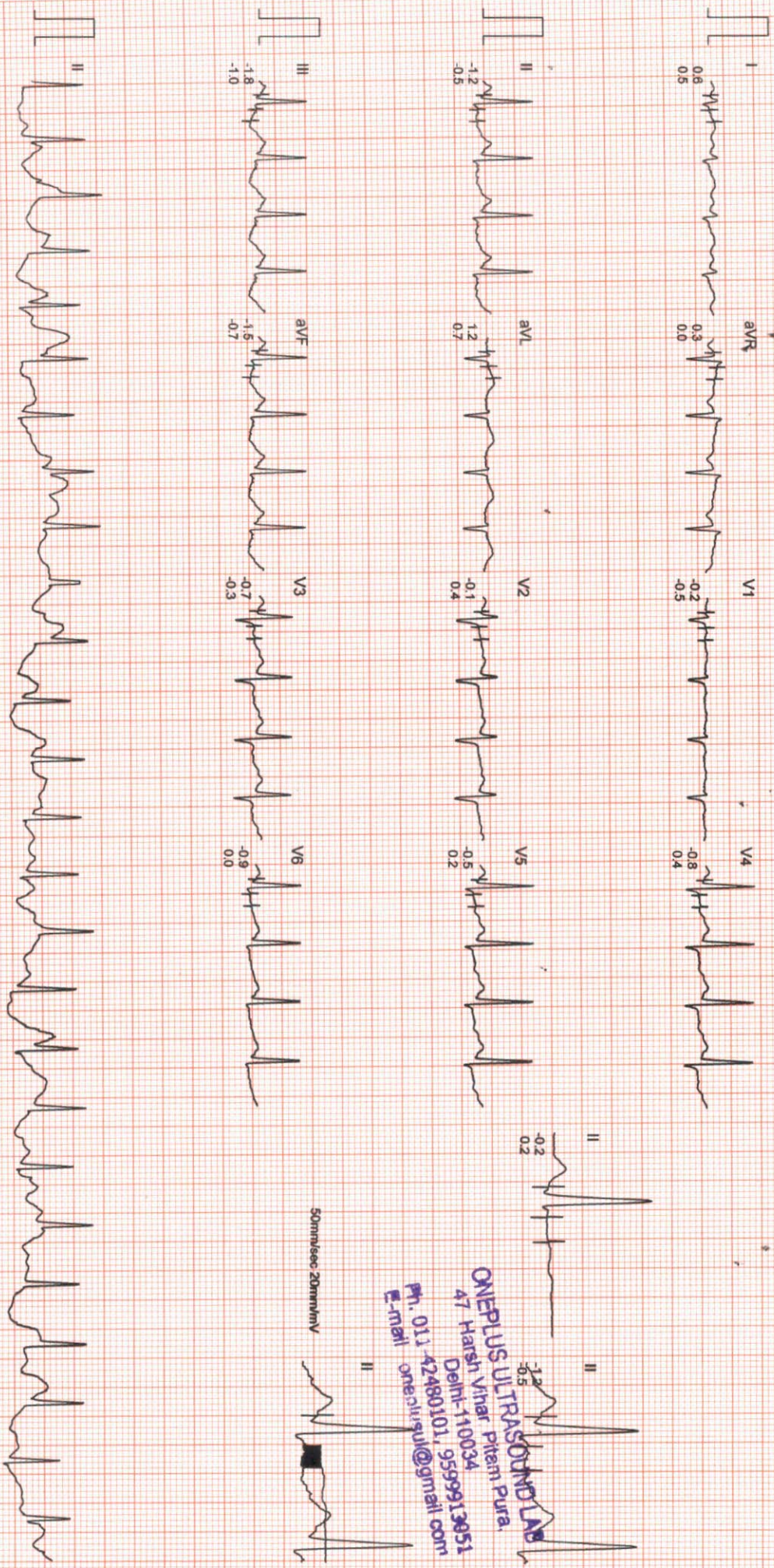
ONEPLUS ULTRASOUND LAB
4/7, Hareesh Vihar, Pitam Pura,
Delhi-110034
Ph. 011-42480101, 955656513951
E-mail: preetis101@gmail.com

ONEPLUS ULTRASOUND LAB

Ms. PREETI DALAL
I.D. : 984
AGE/SEX : 41/F
RECORDED : 5-4-2024 11:16

Manual Protocol2
PEAK EXER
PHASE TIME : 6:34
STAGE TIME : 0:34

ST @ 10mm/mV
80ms PostJ
SPEED : 5.4 Km./Hr.
GRADE : 14.0 %
LINKED MEDIAN



ONEPLUS ULTRASOUND LAB
47 Harsh Vihar Pitam Pura,
Delhi-110034
Ph. 011-42480101, 9599913851
E-mail oneplusul@gmail.com

ONEPLUS ULTRASOUND LAB

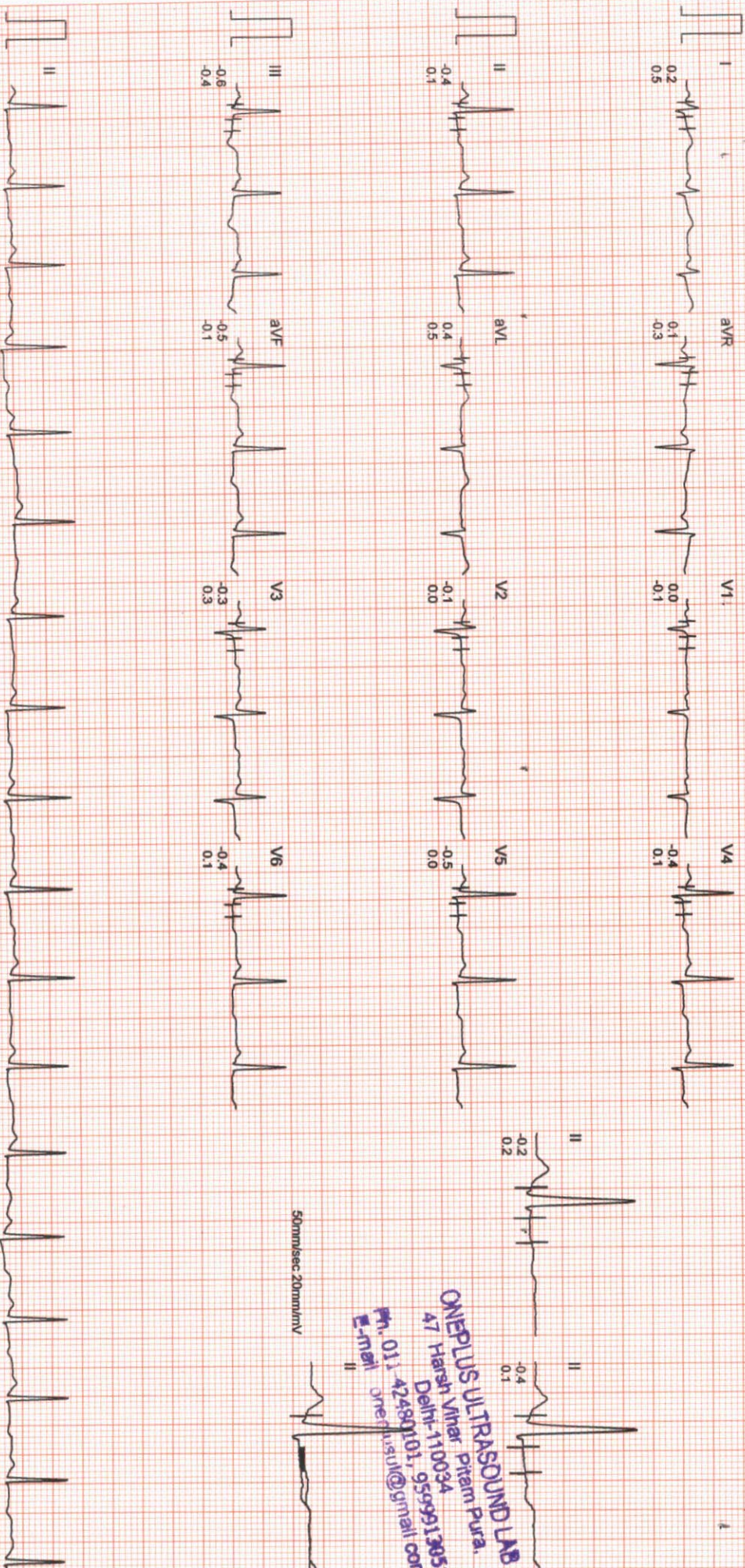
Ms. PREETI DALAL
I.D. : 984
AGE/SEX : 41/F
RECORDED : 5-4-2024 11:16

RATE : 105 BPM
B.P. : 136/92 mmHg

Manual Protocol
RECOVERY
PHASE TIME : 2:59

ST @ 10mm/mV
80ms PostJ
SPEED : 0.0 Km./Hr.
GRADE : 0.0 %

LINKED MEDIAN



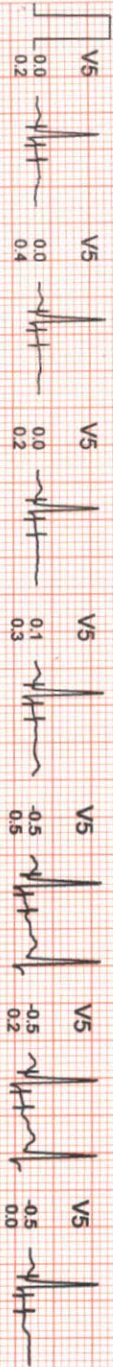

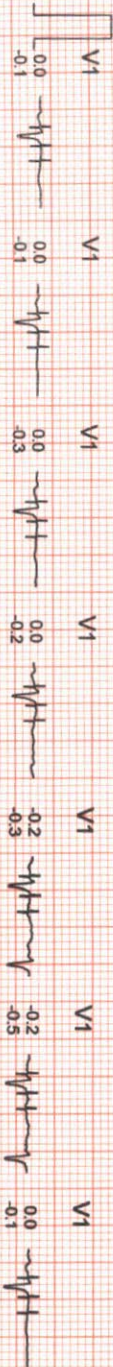
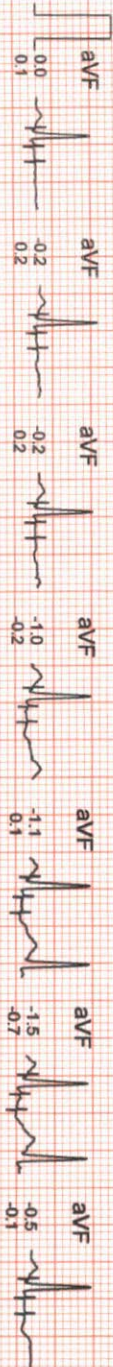
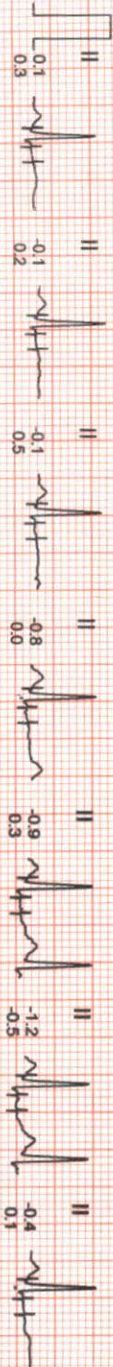

50mmsec 20mm/mV

ONEPLUS ULTRASOUND LAB
47 Harsh Vihar Pitam Pura,
Delhi-110034
Ph. 011-4280101, 9599913051
E-mail onepusul@gmail.com

ONEPLUS ULTRASOUND LAB

AVG E.C.G.

STAGE	HR	BP	SpO2
SUPINE	89 bpm	134/92	80ms PostU
STANDING	102 bpm	134/92	80ms PostU
HYPERVENT	97 bpm	134/92	80ms PostU
STAGE 1	2:59	2.7kmph	10.0%
STAGE 2	5:59	4.0kmph	12.0%
PEAK EXERCISE	6:34	5.4kmph	14.0%
RECOVERY	2:59	0.0kmph	0.0%



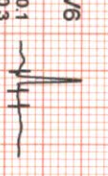
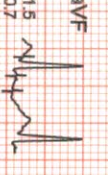
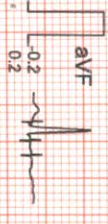
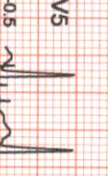
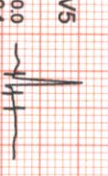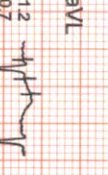



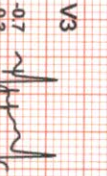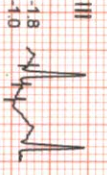
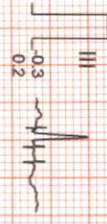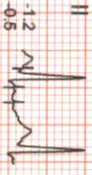
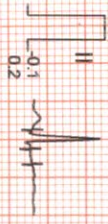
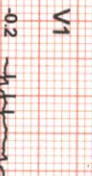
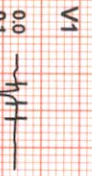
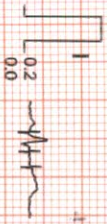
ONEPLUS ULTRASOUND LAB
 47 Harsih Vihar, Pitam Pura
 Delhi-110024
 Ph. 011-42480101, 656869138951
 Email: onepulslab@gmail.com

STANDING
 0.0kmph
 0.0%
 102 bpm
 B.P. 134/92
 80ms PostU

PEAK EXERCISE
 6:34
 0:34
 5.4kmph
 14.0%
 155 bpm
 B.P. 160/96
 80ms PostU

STANDING
 0.0kmph
 0.0%
 102 bpm
 B.P. 134/92
 80ms PostU

PEAK EXERCISE
 6:34
 0:34
 5.4kmph
 14.0%
 155 bpm
 B.P. 160/96
 80ms PostU



ONEPLUS ULTRASOUND LAB
 471 Harsit Vihar, Pitam Pura,
 Delhi-110032
 9549913951
 Ph. 011-42490101
 Email: onepplusul@gmail.com

Name	: Mrs. PREETI DALAL	Age/Sex	: 41 YRS/Female
Ref. By	: Dr. MEDIWHEEL	Lab No	: 012404050020
Date	: 05-Apr-2024	Patient ID	: LSHHI133399

ULTRASOUND EXAMINATION----WHOLE ABDOMEN

Liver is enlarged in size (16.2 cm) and normal in outline with altered echopattern. Diffuse increase in echogenicity of liver parenchyma is noted, suggestive of fatty infiltration (grade I). No abscess or mass lesion seen. Hepatic veins, portal vein, IVC and aorta are normal. Intrahepatic biliary radicles are not dilated. CBD is normal in caliber.

Gall bladder is well distended with anechoic lumen. Wall thickness is normal.

Both kidneys are normal in size, shape, position, outline and echopattern. Corticomedullary differentiation is maintained. No pelvicalyceal dilation or calculus or mass lesion is seen.

Renal measurements are --

Rt. Kidney – 9.6 x 4.0 cm.

Lt. kidney – 10.0 x 4.6 cm.

Spleen is normal in size and echotexture. No mass lesion seen.

Pancreas is normal in size, outline and echotexture.

Urinary bladder is normal in shape and position. No evidence of intravesical stone or mass seen.

Uterus is normal in size (measures 8.9 x 5.3 x 4.1 cm), position and echopattern. No mass seen.

Uterine cavity is empty. **Endometrial thickness** is 12.4 mm.

Both ovaries appear normal in size, shape and echopattern. No tubo-ovarian mass seen.

No abnormal bowel wall thickening seen in right iliac fossa.
No free fluid seen anywhere in abdomen.

IMPRESSION: Fatty infiltration of liver (grade I) with hepatomegaly.


DR. RASHMI BANSAL
RADIOLOGIST
REG. NO. DMC/R/10067



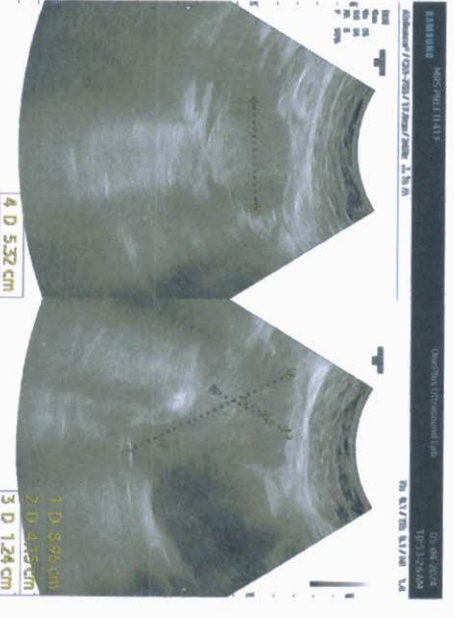
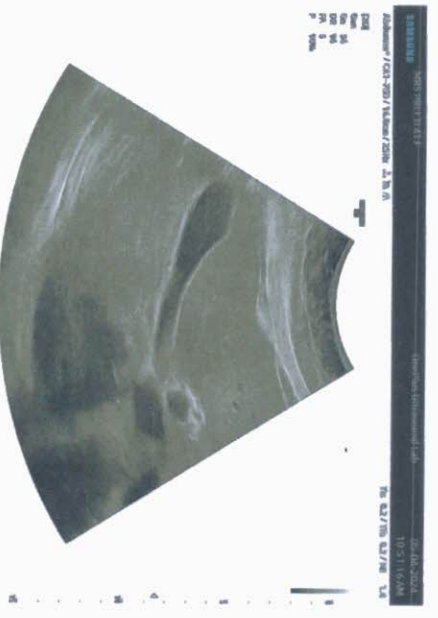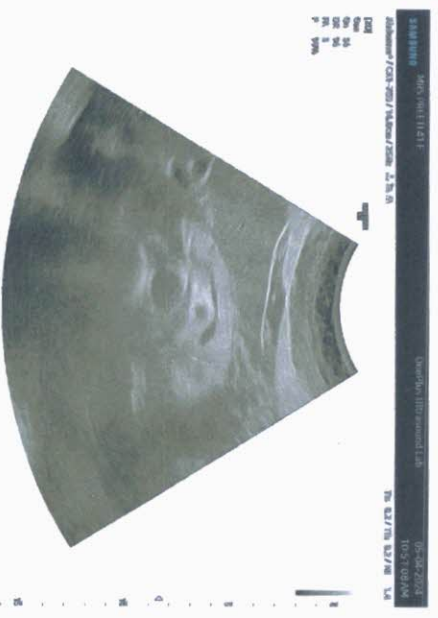

Dr. RASHMI BANSAL
Radiologist
Reg. No. DMC/R/10067

Type By : darshita

47, Harsh Vihar, Pitampura, Delhi-34 ☎ 011-4248 0101, 9599913051

✉ Email: oneplusul@gmail.com 🌐 www.oneplusul.in

- Clinical correlation is essential for final diagnosis. • If test results are unsatisfactory please contact personally or on phone.
- This report is for perusal of doctors only. • All disputes are subject to Delhi jurisdiction only. • Not for medico legal case.
- All congenital anomalies in a foetus may not be diagnosed in routine obstetric ultrasound.



Name	: Mrs. PREETI DALAL	Age/Sex	: 41 YRS/Female
Ref. By	: Dr. MEDIWHEEL	Lab No	: 012404050020
Date	: 05-Apr-2024	Patient ID	: LSHHI133399

X-ray-Chest PA view

Bony cage and soft tissues are normal.

Cardiothoracic ratio is normal.

Mediastinum is normal.


Both hila are normal.

Both costophrenic angles are clear.

Both domes of diaphragm are normal.

Lung fields are clear. No parenchymal lesion seen.

IMPRESSION: Normal Study.


DR. POOJA GARG
RADIOLOGIST
REG NO- DMC/R/03398

Dr. POOJA GARG
M.B.S., D.M.R.D
Reg No DMC/R/03398
Radiologist

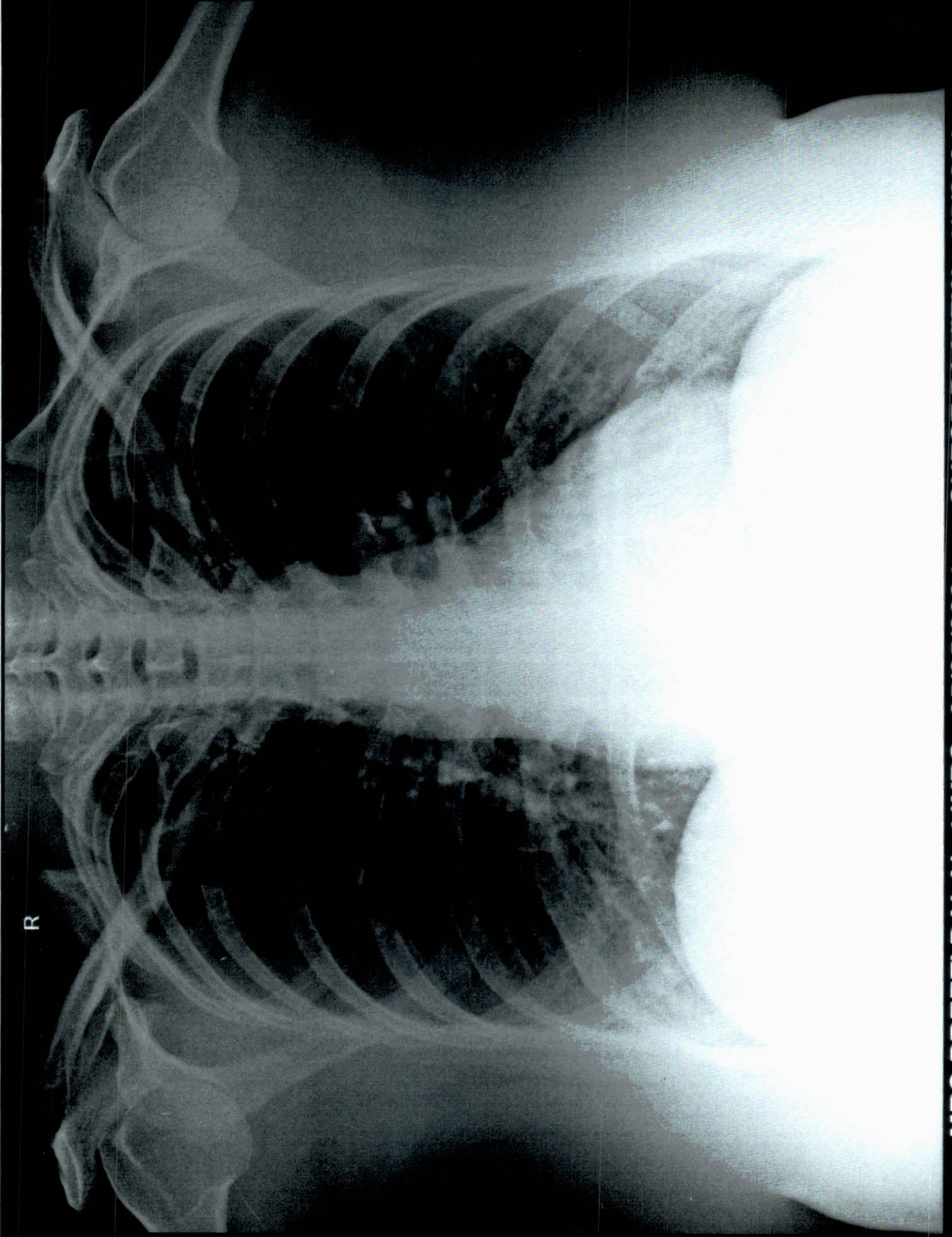
Type By : darshita

47, Harsh Vihar, Pitampura, Delhi-34 ☎ 011-4248 0101, 9599913051

✉ Email: oneplusul@gmail.com 🌐 www.oneplusul.in

- Clinical correlation is essential for final diagnosis. • If test results are unsatisfactory please contact personally or on phone.
- This report is for perusal of doctors only. • All disputes are subject to Delhi jurisdiction only. • Not for medico legal case.
- All congenital anomalies in a foetus may not be diagnosed in routine obstetric ultrasound.

R



MRS PREETI DALAL 41YRS 05/05/2024 CHEST PA VIEW 4/5/2024

ONEPLUS ULTRASOUND LAB,47-HARSH VIHAR,PITAMPURA



OnePLUS
Ultrasound Lab
— QUALITY FIRST... ALWAYS! —



NABL
MC - 6036

Dr. Nitin Agarwal

Pathologist & Director
MBBS, MD, FAGE
Ex. Chief of Lab
Dr. Lal Path labs.

Dr. Pooja (Garg) Agarwal

Radiologist & Director
MBBS (MAMC) DMRD (MAMC)
Imaging Expert In Fetal And Maternal Medicine,
University of Barcelona, Spain
Fetal Medicine Foundation (UK) Accreditation



NAME	:Mrs. PREETI DALAL	Barcode No	:10168871
AGE/GENDER	:41 YRS/Female	SPECIMEN DATE	:05/Apr/2024 09:26AM
PATIENT ID	:133399	SPECIMEN RECEIVED	:05/Apr/2024 10:24AM
REFERRED BY	:Dr. MEDIWHEEL	REPORT DATE	:05/Apr/2024 03:19PM
CENTRE NAME	:ONEPLUS ULTRASOUND LAB	LAB NO.	:012404050020

Test Name	Result	Unit	Ref. Range
-----------	--------	------	------------

HAEMATOLOGY

MediWheel Health Checkup >40 Female

Sample Type:EDTA Blood

ESR
Modified Westergrens Method

10 mm in 1st hr upto 13.6

Comments:

Increased

- In most infections, anaemias, injection of foreign proteins, auto-immune disorders, conditions accompanied by hyperglobunemia and hypercholesterolaemia.
- A rising ESR suggests a progressive disease.

Decreased

- In polycythemia, congestive heart failure.

Glycosylated Hemoglobin (HbA1c)
HPLC

5.4 % Non Diabetic adults <5.7
Prediabetic (at risk) 5.7-6.4
Diabetes >6.4

Estimated average blood glucose (eag)
CALCULATED

108

Reference range (mg/dl):

90 - 120:Excellent control, 121 - 150:Good Control, 151 - 180:Average Control, 181 - 210:Action Suggested

>211:Panic value

Checked By.

Dr. NITIN AGARWAL
MBBS, MD
Regn. No. DMC-R-1436

DR. NITIN AGARWAL
MBBS,MD(PATHOLOGIST)

47, Harsh Vihar, Pitampura, Delhi-34 ☎ 011-4248 0101, 9599913051

✉ Email: oneplusul@gmail.com 🌐 www.oneplusul.in



OnePLUS
Ultrasound Lab
— QUALITY FIRST... ALWAYS! —

Dr. Nitin Agarwal

Pathologist & Director
MBBS, MD, FAGE
Ex. Chief of Lab
Dr. Lal Path labs.

Dr. Pooja (Garg) Agarwal

Radiologist & Director
MBBS (MAMC) DMRD (MAMC)
Imaging Expert In Fetal And Maternal Medicine,
University of Barcelona, Spain
Fetal Medicine Foundation (UK) Accreditation



NAME	:Mrs. PREETI DALAL	Barcode No	:10168871
AGE/GENDER	:41 YRS/Female	SPECIMEN DATE	:05/Apr/2024 09:26AM
PATIENT ID	:133399	SPECIMEN RECEIVED	:05/Apr/2024 10:24AM
REFERRED BY	:Dr. MEDIWHEEL	REPORT DATE	:05/Apr/2024 03:19PM
CENTRE NAME	:ONEPLUS ULTRASOUND LAB	LAB NO.	:012404050020

Test Name	Result	Unit	Ref. Range
-----------	--------	------	------------

HAEMATOLOGY

BLOOD GROUP (ABO)

Forward and Reverse grouping (Slide & Tube)

B
POSITIVE

Rh typing

NOTE :

- * Apart from major A,B,H antigens which are used for ABO grouping and Rh typing, many minor blood group antigens exist. Agglutination may also vary according to titre of antigen and antibody.
- * So before transfusion, reconfirmation of blood group as well as cross-matching is needed.
- * Presence of maternal antibodies in newborns, may interfere with blood grouping.
- * Auto agglutination (due to cold antibody, falciparum malaria, sepsis, internal malignancy etc.) may also cause erroneous result.

Checked By.

Dr. NITIN AGARWAL
MBBS, MD
Regn. No. DMC-R-1436

DR. NITIN AGARWAL
MBBS,MD(PATHOLOGIST)

47, Harsh Vihar, Pitampura, Delhi-34 ☎ 011-4248 0101, 9599913051

✉ Email: oneplusul@gmail.com 🌐 www.oneplusul.in



NAME	:Mrs. PREETI DALAL	Barcode No	:10168871
AGE/GENDER	:41 YRS/Female	SPECIMEN DATE	:05/Apr/2024 09:26AM
PATIENT ID	:133399	SPECIMEN RECEIVED	:05/Apr/2024 10:24AM
REFERRED BY	:Dr. MEDIWHEEL	REPORT DATE	:05/Apr/2024 03:19PM
CENTRE NAME	:ONEPLUS ULTRASOUND LAB	LAB NO.	:012404050020

Test Name	Result	Unit	Ref. Range
-----------	--------	------	------------

HAEMATOLOGY

CBC

Haemoglobin Non cyanide Hb analysis	10.7	g/dl	12.0-15.0
Total Leucocyte Count Electrical Impedance	7500	/cumm	4000-10000
Differential leucocyte count			
Neutrophils Electrical Impedance & Microscopic	58.9	%	40-80
Lymphocyte Electrical Impedance & Microscopic	34.60	%	20-40
Monocytes Electrical Impedance & Microscopic	4.00	%	2-10
Eosinophils Electrical Impedance & Microscopic	2.0	%	1-6
Basophils Electrical Impedance & Microscopic	0.5	%	0-2
RBC Count Electrical Impedance	4.10	million/cumm	4.5 - 5.5
Hematocrit(PCV) Flow Cytometry	32.6	%	36-46
MCV Calculated	79.8	fl	83-101
MCH Calculated	26.1	pg	27-32
MCHC Calculated	32.7	g/dL	31.5-34.5
RDW-CV Calculated	15.2	%	11.4-14.0
Platelet count Electrical Impedance	283000	/cumm	150000-410000

BIOCHEMISTRY

Sample Type:Fluoride F Blood sugar fasting GOD-POD	92	mg/dl	70-100 mg/dl
---	----	-------	--------------

Checked By.

Dr. NITIN AGARWAL
MBBS, MD
Regn. No. DMC-R-1436


DR. NITIN AGARWAL
MBBS,MD(PATHOLOGIST)

47, Harsh Vihar, Pitampura, Delhi-34 ☎ 011-4248 0101, 9599913051

✉ Email: oneplusul@gmail.com 🌐 www.oneplusul.in



NAME	:Mrs. PREETI DALAL	Barcode No	:10168871
AGE/GENDER	:41 YRS/Female	SPECIMEN DATE	:05/Apr/2024 09:26AM
PATIENT ID	:133399	SPECIMEN RECEIVED	:05/Apr/2024 10:24AM
REFERRED BY	:Dr. MEDIWHEEL	REPORT DATE	:05/Apr/2024 03:19PM
CENTRE NAME	:ONEPLUS ULTRASOUND LAB	LAB NO.	:012404050020

Test Name	Result	Unit	Ref. Range
Sample Type:Fluoride PP			
Blood sugar pp GOD-POD	83	mg/dL	70.0-140.0
Sample Type:Serum			
Bun (blood urea nitrogen) Calculated	10.70	mg/dl	8.9-21.6
Uric Acid, serum Uricase- PAP	4.4	mg/dl	3.5-7.2
Creatinine, serum Enzymatic	0.7	mg/dl	0.71-1.16
LFT(LIVER FUNCTION TEST)			
Bilirubin Total Modified tab	0.52	mg/dl	0.1-0.9
Bilirubin Conjugated Diazotied sulfanilic acid	0.23	mg/dl	0-0.4
Bilirubin Unconjugated Calculated	0.29	mg/dl	up to 0.7
SGOT (AST) Tris buffer	23	U/L	0-46
SGPT (ALT) Tris buffer	28	U/L	0-49
Alkaline phosphatase Amp buffer	68	U/L	40-129
GAMMA GT Szasz Method	26	U/L	10-45
Total Protein Biuret	7.5	gm/dl	6.60 - 8.70
Albumin serum BCG	4.1	g/dL	3.0-5.2
Globulin Calculated	3.40	gm/dl	1.8-3.4
Albumin/Globulin Ratio Calculated	1.21		1.10 - 2.50
LIPID PROFILE			
Cholesterol CHOD-PAP	224	mg/dl	50-200

Checked By.

Dr. NITIN AGARWAL
MBBS, MD
Regn. No. DMC-R-1436



DR. NITIN AGARWAL
MBBS,MD(PATHOLOGIST)

47, Harsh Vihar, Pitampura, Delhi-34 ☎ 011-4248 0101, 9599913051

✉ Email: oneplusul@gmail.com 🌐 www.oneplusul.in



OnePLUS
Ultrasound Lab
— QUALITY FIRST... ALWAYS! —



NABL
MC - 6036

Dr. Nitin Agarwal

Pathologist & Director
MBBS, MD, FAGE
Ex. Chief of Lab
Dr. Lal Path labs.

Dr. Pooja (Garg) Agarwal

Radiologist & Director
MBBS (MAMC) DMRD (MAMC)
Imaging Expert In Fetal And Maternal Medicine,
University of Barcelona, Spain
Fetal Medicine Foundation (UK) Accreditation



NAME	:Mrs. PREETI DALAL	Barcode No	:10168871
AGE/GENDER	:41 YRS/Female	SPECIMEN DATE	:05/Apr/2024 09:26AM
PATIENT ID	:133399	SPECIMEN RECEIVED	:05/Apr/2024 10:24AM
REFERRED BY	:Dr. MEDIWHEEL	REPORT DATE	:05/Apr/2024 03:19PM
CENTRE NAME	:ONEPLUS ULTRASOUND LAB	LAB NO.	:012404050020

Test Name	Result	Unit	Ref. Range
Triglycerides GPO-PAP	91	mg/dL	25-150
HDL Cholesterol Selective Inhibition	46	mg/dL	40 - 60
LDL cholesterol Calculated	160	mg/dL	<130
VLDL cholesterol Calculated	18.2	mg/dL	5-40
Cholesterol/HDL Ratio Calculated	4.9		Low Risk 3.3-4.97 Average Risk 4.4-7.1 Moderate Risk 7.1-11.0 High Risk >11.0
LDL/HDL Ratio Calculated	3.5		0 - 3.55

LDL Cholesterol	Total Cholesterol	HDL Cholesterol
<100 Optimal	<200 Desirable	<40 Low
100-129 Near optimal	200-239 Borderline high	>60 High
130-159 Borderline high	>240 High	
160-189 High		
>190 Very high		

According to NCEP, ATP-III Guidelines

	BUN/Creatinine ratio		
UREA UREASE-GLDH	23.00	mg/dl	15-45
Bun (blood urea nitrogen) Calculated	10.75	mg/dl	8.9-21.6
CREATININE ENZYMATIC	0.70	mg/dl	0.30-1.10
Bun/Creatinine Ratio Calculated	15.36		10.0 - 20.0

Checked By.

Dr. NITIN AGARWAL
MBBS, MD
Regn. No. DMC-K-1436

DR. NITIN AGARWAL
MBBS, MD (PATHOLOGIST)

47, Harsh Vihar, Pitampura, Delhi-34 ☎ 011-4248 0101, 9599913051

✉ Email: oneplusul@gmail.com 🌐 www.oneplusul.in



OnePLUS
Ultrasound Lab
— QUALITY FIRST... ALWAYS! —

Dr. Nitin Agarwal

Pathologist & Director
MBBS, MD, FAGE
Ex. Chief of Lab
Dr. Lal Path labs.

Dr. Pooja (Garg) Agarwal

Radiologist & Director
MBBS (MAMC) DMRD (MAMC)
Imaging Expert In Fetal And Maternal Medicine,
University of Barcelona, Spain
Fetal Medicine Foundation (UK) Accreditation



NAME	:Mrs. PREETI DALAL	Barcode No	:10168871
AGE/GENDER	:41 YRS/Female	SPECIMEN DATE	:05/Apr/2024 09:26AM
PATIENT ID	:133399	SPECIMEN RECEIVED	:05/Apr/2024 10:24AM
REFERRED BY	:Dr. MEDIWHEEL	REPORT DATE	:05/Apr/2024 03:19PM
CENTRE NAME	:ONEPLUS ULTRASOUND LAB	LAB NO.	:012404050020

Test Name	Result	Unit	Ref. Range
-----------	--------	------	------------

ENDOCRINOLOGY

THYROID PROFILE(T3,T4,TSH)

Triiodothyronine total [t3] ECLIA	0.85	ng/dl	0.52-1.9
Thyroxine total [t4] ECLIA	6.50	µg/dl	4.8-11.6
TSH (Thyroid Stimulating Hormone) Enzyme linked fluorescent assay	1.31	µIU/ml	0.25-5.0

AGE WISE VARIATION IN TSH

AGE	TSH(µIU/ml)	AGE	TSH(µIU/ml)
1-4 weeks	1.00 - 19.0	16-20 yrs	0.25 - 5.0
1-12 mths	1.70 - 9.1	21 - 80 yrs	0.25 - 5.0
1-5 yrs	0.80 - 8.2	I st trimester	0.25 - 5.0
6-10 yrs	0.25 - 5.0	II nd trimester	0.50 - 5.0
11-15 yrs	0.25 - 5.0	II rd trimester	0.4 - 6.0

Reference ranges - Interpretation of Diagnostic tests - (Jacques Wallach)

1. Primary hypothyroidism is accompanied by depressed serum T3 and T4 values and elevated serum TSH level.
2. Primary hyperthyroidism is accompanied by elevated serum T3 and T4 levels along with depressed TSH values.
3. Slightly elevated T3 levels may be found in pregnancy and estrogen therapy, while depressed levels may be encountered in severe illness, renal failure and during therapy with drugs like propranolol and propyl thiouracil.
4. Although elevated TSH levels are nearly always indicative of primary hypothyroidism, and may be seen in secondary thyrotoxicosis

Checked By.

Dr. NITIN AGARWAL
MRBS MD
Regn. No. DMC-K-1436

DR. NITIN AGARWAL
MBBS,MD(PATHOLOGIST)

47, Harsh Vihar, Pitampura, Delhi-34 ☎ 011-4248 0101, 9599913051

✉ Email: oneplusul@gmail.com 🌐 www.oneplusul.in

- Clinical correlation is essential for final diagnosis. • If test results are unsatisfactory please contact personally or on phone.
- This report is for perusal of doctors only. • All disputes are subject to Delhi jurisdiction only. • Not for medico legal case.
- All congenital anomalies in a foetus may not be diagnosed in routine obstetric ultrasound.



NAME	:Mrs. PREETI DALAL	Barcode No	:10168871
AGE/GENDER	:41 YRS/Female	SPECIMEN DATE	:05/Apr/2024 09:26AM
PATIENT ID	:133399	SPECIMEN RECEIVED	:05/Apr/2024 10:24AM
REFERRED BY	:Dr. MEDIWHEEL	REPORT DATE	:05/Apr/2024 03:19PM
CENTRE NAME	:ONEPLUS ULTRASOUND LAB	LAB NO.	:012404050020

Test Name	Result	Unit	Ref. Range
-----------	--------	------	------------

CLINICAL PATHOLOGY
URINE ROUTINE (Strip/microscopy)

Sample Type:Urine

Physical examination

Colour	PALE YELLOW	PALE YELLOW
Transparency	CLEAR	CLEAR
Sp.gravity	1.015	1.005-1.030
BROMOTHYMOL BLUE		
pH	6.00	5.0-8.0
Double Indicators Test		
Reaction	ACIDIC	ACIDIC

Chemical examination

Urine protein	NIL	NIL
Protein Ionization		
Urine sugar	NIL	NIL
Oxidation Reaction		
Bilirubin, urine	NEGATIVE	NEGATIVE
Urobilinogen	NORMAL	NORMAL
P-Aminobenzoic Acid and Phenazopyridine Reaction		
Ketones	NEGATIVE	NEGATIVE
Acetoacetate and Dichlorobenzene Reaction		

Microscopic examination

Pus cells.	2-3	/HPF	1-2
Microscopy			
Epithelial cells	10-15	/HPF	0-5
Microscopy			
R.B.C.	NIL	/HPF	NIL
Microscopy			
Casts	NIL	/HPF	NIL
Microscopy			
Crystals	NIL	/HPF	NIL
Microscopy			
Bacteria	NIL	/HPF	NIL
Microscopy			

Checked By.


DR. NITIN AGARWAL
MBBS,MD(PATHOLOGIST)

Dr. NITIN AGARWAL
MBBS, MD
Regn. No. 011-42480101, 9599913051
MC - 6036

47, Harsh Vihar, Pitampura, Delhi-34

Email: oneplusul@gmail.com www.oneplusul.in



OnePLUS
Ultrasound Lab
— QUALITY FIRST... ALWAYS! —



NABL
MC - 6036

Dr. Nitin Agarwal

Pathologist & Director
MBBS, MD, FAGE
Ex. Chief of Lab
Dr. Lal Path labs.

Dr. Pooja (Garg) Agarwal

Radiologist & Director
MBBS (MAMC) DMRD (MAMC)
Imaging Expert In Fetal And Maternal Medicine,
University of Barcelona, Spain
Fetal Medicine Foundation (UK) Accreditation



NAME	:Mrs. PREETI DALAL	Barcode No	:10168871
AGE/GENDER	:41 YRS/Female	SPECIMEN DATE	:05/Apr/2024 09:26AM
PATIENT ID	:133399	SPECIMEN RECEIVED	:05/Apr/2024 10:24AM
REFERRED BY	:Dr. MEDIWHEEL	REPORT DATE	:05/Apr/2024 03:19PM
CENTRE NAME	:ONEPLUS ULTRASOUND LAB	LAB NO.	:012404050020

Test Name	Result	Unit	Ref. Range
Others.	NIL		NIL

*** End Of Report ***

Checked By.

Dr. NITIN AGARWAL
MBBS, MD
Regn. No. DMC-R-1436

DR. NITIN AGARWAL
MBBS,MD(PATHOLOGIST)

47, Harsh Vihar, Pitampura, Delhi-34 ☎ 011-4248 0101, 9599913051

✉ Email: oneplusul@gmail.com 🌐 www.oneplusul.in

- Clinical correlation is essential for final diagnosis. • If test results are unsatisfactory please contact personally or on phone.
- This report is for perusal of doctors only. • All disputes are subject to Delhi jurisdiction only. • Not for medico legal case.
- All congenital anomalies in a foetus may not be diagnosed in routine obstetric ultrasound.