

Sex: M Birth date: / mmHg

Weight: kg

Medication:

Symptoms:

History:

Heart rate: 80 bpm

R interval: 198 ms

RS duration: 80 ms

FT/QTc(E) interval: 356/392 ms

1/QRS/T axis: 64/72/43 degrees

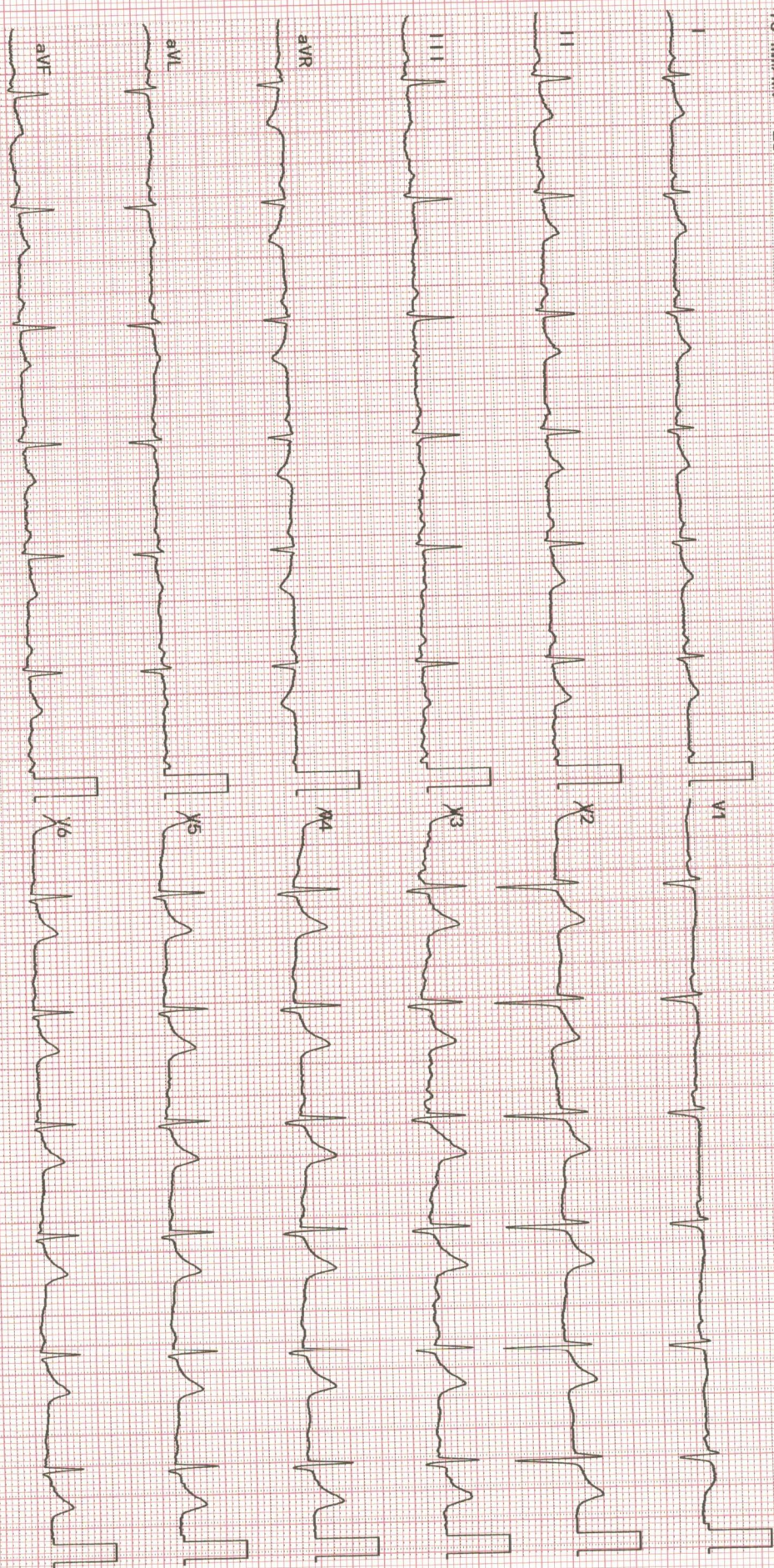
V5/SV1 amplitude: 0.79/0.51 mV

V5+SV1 amplitude: 1.30 mV

10 mm/mV 25 mm/s Filter: H50 D 35 Hz

10 mm/mV

Unconfirmed Report
Reviewed by:





NABH



NABL



No.1



Care Par Excellence
Jayanagar, Bangalore

Out Patient Record

Patient Name : Mr.R RAGHAVENDRA B

UHID : UHJA24000265

Age / Sex : 40 Years / Male

OP NO/Reg Dt : 06-04-2024 09:12 AM

Spouse / Father Name : ASHA B.M

Department :

Address : , , Bengaluru Urban, Karnataka, INDIA,

Referred By :

Consultant : Dr.Preventive Health Check Up

KMC No. :

Complaints / Findings / Observations :

Wt - 87.6

HT - 176cm

Bp - 106/60mmHg

SpO2 - 98%

PR 76b/min

Investigations:

Treatment / Care of Plan / Provisional Diagnosis :

Follow Up Advice :

Signature of the Doctor



NABH



NABL



No.1

**UNITED
HOSPITAL**Care Par Excellence
Jayanagar, Bangalore

Patient name :	Mr. RAGHAVENDRA B	Date :	06/04/24
Age :	46 years GENDER: MALE	Patient ID :	24000265
Ref by :	DR. CMO	OP/ IP :	HEALTH CHECKUP

2D- ECHOCARDIOGRAPHY**M - MODE AND DOPPLER MEASUREMENTS**

(c.m)	(c.m)	(cm/sec)		
AO : 3.0 (2.5-3.7)	LVIDD : 5.6 (3.5-5.5)	MV EV : 92.6	AV : 70.3	MR : NORMAL
LA : 2.5 (1.9-4.0)	LVIDS : 3.7 (2.4-4.2)	AV : 107		AR : NORMAL
RA : 2.3 (<4.4)	IVSD : 0.8 (0.6-1.1)	PV : 125		PR : NORMAL
RV : 2.2 (<3.5)	IVSS : 1.1 (0.9-1.2)	TV EV : ----	AV : ----	TR : TRIVIAL TR
TAPSE: 1.8 (>1.6)	LVPWD : 0.8 (0.6-1.1)	Diastolic Function : NO LVDD		
	LVPWS : 1.0 (0.9-1.2)			
	EF : 60%			

DESCRIPTIVE FINDINGS

Left Ventricle	: NORMAL
Right Ventricle	: NORMAL
Left Atrium	: NORMAL
Right Atrium	: NORMAL
Wall motion analysis	: NO RWMA
Mitral Valve	: NORMAL
Aortic Valve	: NORMAL
Tricuspid Valve	: NORMAL, TRIVIAL TR, JET GRDT-15mmHg
Pulmonary Valve	: NORMAL
IAS	: INTACT
IVS	: INTACT
Pericardium	: NORMAL
Other Findings	: IVC NORMAL AND COLLAPSING

IMPRESSION:

NORMAL CHAMBER DIMENSIONS
 NORMAL LV SYSTOLIC FUNCTION EF : 60%
 NORMAL LV DIASTOLIC FUNCTION
 NO PULMONARTERY HYPERTENSION
 NO REGIONAL WALL MOTION ABNORMALITIES
 NO CLOTS/ PERICARDIAL EFFUSION /VEGETATION


DR. RAHUL S PATIL
 CONSULTANT CARDIOLOGIST



NABH



NABL



No.1

**UNITED
HOSPITAL**Care Par Excellence
Jayanagar, Bangalore**DEPARTMENT OF RADIODIAGNOSIS**

Name	Raghavendra R B	Date	06/04/24
Age	40 years	Hospital ID	UHJA24000256
Sex	Male	Ref.	Healthcheck

ULTRASOUND ABDOMEN AND PELVIS**FINDINGS:**

Liver is enlarged in size (15.6 cms) and shows mild increased echopattern. No intra or extra hepatic biliary duct dilatation. No focal lesions. **Portal vein** is normal in size, course and caliber. **CBD** is not dilated.

Gall bladder is normal without evidence of calculi, wall thickening or pericholecystic fluid.

Pancreas - Visualized part of the pancreatic head and body appears normal in size, contour and echogenicity. Rest of the pancreas is obscured by bowel gas.

Spleen is normal in size, shape, contour and echopattern. No focal lesion.

Right Kidney is normal in size (9.4 x 3.6 cms), position, shape and echopattern. Corticomedullary differentiation is maintained. No calculus or hydronephrosis.

Left Kidney is normal in size (9.9 x 4.5 cms), position, shape and echopattern. Corticomedullary differentiation is maintained. No calculus or hydronephrosis.

Retroperitoneum - Visualized aorta appeared normal. No obvious enlarged para-aortic nodes.

Urinary Bladder is distended, normal in contour and wall thickness. No evidence of calculi.

Prostate is normal in echopattern and size, measures ~ 12.9 cc.

No ascites or pleural effusion. Appendix could not be localized. No RIF probe tenderness.

IMPRESSION:

- **Mild hepatomegaly with mild fatty infiltration (Grade I).**
- **No other definite sonological abnormality detected.**

Dr. Elluru Santosh Kumar
Consultant Radiologist



NABH



NABL



No.1



**UNITED
HOSPITAL**

Care Par Excellence
Jayanagar, Bangalore

DEPARTMENT OF RADIODIAGNOSIS

Name	Raghavendra R B	Date	06/04/24
Age	40 years	Hospital ID	UHJA24000256
Sex	Male	Ref.	Health check

RADIOGRAPH OF THE CHEST (PA – VIEW)

FINDINGS:

Bilateral lung fields are normal.

Bilateral costo-phrenic angles are normal.

Cardia and mediastinal contours are normal.

Bilateral cervical ribs are seen. The bony thorax is grossly normal.

IMPRESSION:

- No significant radiographic abnormality.

Dr. Elluru Santosh Kumar
Consultant Radiologist