



Pathology Department



Patient's name : NIRUPABEN JAYESH PARMAR
 Age/Sex : 50 Years/Female
 Referred by : MEDI WHEEL
 Collection Time : 11:01

Reg. ID : P-6860-23
 Accession : 24700
 Order Dt/time : 23/03/2024 11:01

Complete Blood Count

Sample Type: EDTA

Test Name	Result	Units	Biological Reference Interval
Blood Counts			
Haemoglobin :	11.9	Gms%	12.5 - 16.0
Total R.B.C. :	5.00	mill/c.mm	4.2 - 5.4
Total W. B. C. :	5580	/cu mm	4000 - 10500
Platelet Count :	223000	/cu.mm	1,50,000 - 4,50,000
Differential Count			
Neutrophils :	60	%	40 - 70
Lymphocytes :	35	%	20 - 40
Eosinophils :	03	%	1 - 4
Monocytes :	02	%	2 - 6
Basophils :	00	%	0 - 01
Blood Indices			
P. C. V :	38.2	%	37 - 47
M. C. V. :	76.5	fl	78 - 100
M.C.H :	23.7	pg	27 - 31
M. C. H. C :	31.0	%	32 - 36
R.D.W :	14.7	%	11.5 - 14.0
E.S.R.(Westergren Method)			
After one hour :	10	mm/hr	3 - 12

TESTS DONE ON FULLY AUTOMATED HEMATOLOGY ANALYZER.

Dr. Gayatri M. Mehta
 M. D. (Patho)

Reg. No. G-32215

DR GAYATRI MEHTA
 MD(PATHOLOGY)

DR. ANAND D. PARIKH
 MD(PATHOLOGY)

LAB USE ONLY (Entered by : GM Enter Date/Time:23/03/2024 7:08:00 PM) (Verify by : GM Verify Date/Time:23/03/2024 7:08:00 PM)



Vidhi Diagnostics | Pathology Department

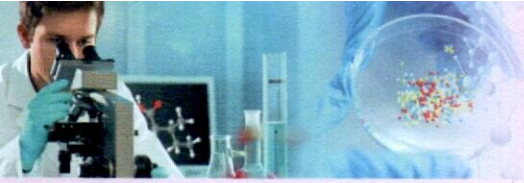L-86, Swatantra Senani Nagar, Opp. Akhbarnagar Petrol Pump, Nr. Akhbarnagar Circle, Nava-Vadaj, Ahmedabad - 380 013.

M. - Pathology : 8849893954, Ph. : 079-27621406, M. 98799 29406, 98250 09406, E-mail : vidhidiagnostics@gmail.com, Web. : www.vidhidiagnostics.com

Time (Pathology) : Mon. to Sat. 8.30 am to 8.00 pm, Sunday 9 am to 12 Noon

Pathology means science behind medicine

CT SCAN & CBCT FACILITY NOW AVAILABLE



Pathology Department



Patient's name : NIRUPABEN JAYESH PARMAR
Age/Sex : 50 Years/Female
Referred by : MEDI WHEEL
Collection Time : 11:01

Reg. ID : P-6860-23
Accession : 24700
Order Dt/time : 23/03/2024 11:01

Blood Group

Sample Type: EDTA sample.

Test Name	Result
BG :	" AB "
RH :	POSITIVE
Remarks	Done by forward grouping method.

Blood Glucose

Sample Type: Serum

Test Name	Result	Units	Biological Reference Interval
Fasting Blood Glucose :	88.1	mg/dl	70 - 110
Urine Sugar :	NIL		Absent
<i>GOD-POD Method.</i>			

Blood Glucose

Sample Type: Serum

Test Name	Result	Units	Biological Reference Interval
Post Prandial Blood Glucose After 2hr. :	125.5	mg/dl	80 - 140
Urine Sugar :	NIL		Absent
<i>GOD-POD Method.</i>			

Dr. Gayatri M. Mehta
M. D. (Patho)

DR GAYATRI MEHTA
MD(PATHOLOGY)

Reg. No. G-32215

DR. ANAND D. PARIKH
MD(PATHOLOGY)

LAB USE ONLY (Entered by :GM Enter Date/Time:23/03/2024 7:09:00 PM) (Verify by :GM Verify Date/Time:23/03/2024 7:09:00 PM)



Vidhi Diagnostics | Pathology Department

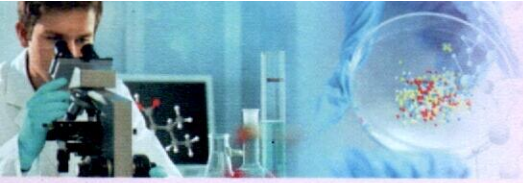L-86, Swatantra Senani Nagar, Opp. Akhbarnagar Petrol Pump, Nr. Akhbarnagar Circle, Nava-Vadaj, Ahmedabad - 380 013.

M. - Pathology : 8849893954, Ph. : 079-27621406, M. 98799 29406, 98250 09406, E-mail : vidhidiagnostics@gmail.com, Web. : www.vidhidiagnostics.com

Time (Pathology) : Mon. to Sat. 8.30 am to 8.00 pm, Sunday 9 am to 12 Noon

Pathology means science behind medicine

CT SCAN & CBCT FACILITY NOW AVAILABLE



Creating life in Gujarat



Pathology Department

Patient's name : NIRUPABEN JAYESH PARMAR
Age/Sex : 50 Years/Female
Referred by : MEDI WHEEL
Collection Time : 11:01

Reg. ID : P-6860-23
Accession : 24700
Order Dt/time : 23/03/2024 11:01

HbA1C

Sample Type: EDTA

Table with 4 columns: Test Name, Result, Units, Biological Reference Interval. Row 1: HbA1C : 5.3 % Non-diabetic: 4.2-6.2, Pre-diabetic : 6.3-7.2, Diabetic : 7.3-8.2. Row 2: Mean Blood Glucose of Last 03 months. : 105.41 mg/dl

Comment

*As per the new 2009 update of American Diabetes Association regarding HbA1C & Mean Blood Glucose relationship.

NOTE:

This test is used to monitor diabetic patients compliance with the therapeutic regimen and loge It's level is proportional to both the average blood glucose concentration and the life span of the red blood cells (RBC) in circulation. HbA1c values are free of day to day glucose fluctuations and are unaffected by exercise or recent food intake.

Dr. Gayatri M. Mehta
M. D. (Patho)

DR GAYATRI MEHTA
MD(PATHOLOGY)

DR. ANAND D. PARIKH
MD(PATHOLOGY)

LAB USE ONLY (Entered by :GM Enter Date/Time:23/03/2024 7:08:00 PM) (Verify by :GM Verify Date/Time:23/03/2024 7:08:00 PM)



Vidhi Diagnostics | Pathology Department

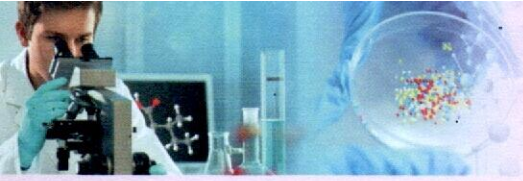L-86, Swatantra Senani Nagar, Opp. Akharnagar Petrol Pump, Nr. Akharnagar Circle, Nava-Vadaj, Ahmedabad - 380 013.

M. - Pathology : 8849893954, Ph. : 079-27621406, M. 98799 29406, 98250 09406, E-mail : vidhidiagnostics@gmail.com, Web. : www.vidhidiagnostics.com


Time (Pathology) : Mon. to Sat. 8.30 am to 8.00 pm, Sunday 9 am to 12 Noon

Pathology means science behind medicine

CT SCAN & CBCT FACILITY NOW AVAILABLE



Pathology Department



Patient's name : NIRUPABEN JAYESH PARMAR
Age/Sex : 50 Years/Female
Referred by : MEDI WHEEL
Collection Time : 11:01

Reg. ID : P-6860-23
Accession : 24700
Order Dt/time : 23/03/2024 11:01

Lipid Profile

Sample Type: Serum

Test Name	Result	Units	Biological Reference Interval
S. Cholesterol : Oxidase-esterase method.	197	mg/dl	0 - 200
S. Triglyceride : Enzymatic Colorimetry method	106.5	mg/dL	0 - 200
S. HDL - Cholesterol : Serum by Enzymatic method.	47.9	mg/dL	35 - 65
S. LDL - Cholesterol : Serum by Enzymatic method	127.8	mg/dL	0 - 130
S. VLDL - Cholesterol :	21.3	mg/dL	0 - 30
S. Chole/HDL.Ratio :	4.11		1 - 6
S. LDL / HDL Cholesterol Ratio :	2.67		0 - 3.5

Dr. Gayatri M. Mehta
M. D. (Patho)

Reg. No. G-32215

DR GAYATRI MEHTA
MD(PATHOLOGY)

DR. ANAND D. PARIKH
MD(PATHOLOGY)

LAB USE ONLY (Entered by :GM Enter Date/Time:23/03/2024 7:08:00 PM) (Verify by :GM Verify Date/Time:23/03/2024 7:08:00 PM)



Vidhi Diagnostics | Pathology Department

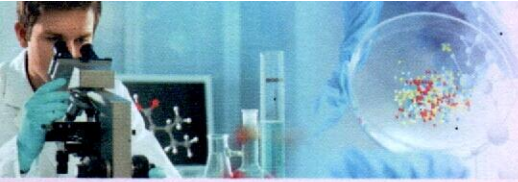
L-86, Swatantra Senani Nagar, Opp. Akhbarnagar Petrol Pump, Nr. Akhbarnagar Circle, Nava-Vadaj, Ahmedabad - 380 013.

M. - Pathology : 8849893954, Ph. : 079-27621406, M. 98799 29406, 98250 09406, E-mail : vidhidiagnostics@gmail.com, Web. : www.vidhidiagnostics.com

Time (Pathology) : Mon. to Sat. 8.30 am to 8.00 pm, Sunday 9 am to 12 Noon

Pathology means science behind medicine

CT SCAN & CBCT FACILITY NOW AVAILABLE



Creating Life in Gujarat

Patient's name : NIRUPABEN JAYESH PARMAR
Age/Sex : 50 Years/Female
Referred by : MEDI WHEEL
Collection Time : 11:01

Reg. ID : P-6860-23
Accession : 24700
Order Dt/time : 23/03/2024 11:01

BIOCHEMISTRY

Sample type :Serum

Test Name	Result	Units	Biological Reference Interval
Urea, (Serum by GLDH method) :	12.8	mg/dl	10 - 50
S.Uric acid, (Serum by Uricase method) :	3.6	mg/dl	2.6-6.0
Bun :	6	mg/dl	6-20
Creatinine, (Serum by Enzymatic reaction) :	0.64	mg/dl	0.5-1.2
S.G.P.T (ALT) : (Serum by IFCC method)	39.0	U/L	0 - 40
S.G.O.T (AST) : (Serum by IFCC method)	40.4	U/L	0 - 37
ALK.PHOSPHATASE : (Serum by PNP method)	97	U/L	35-104
G.G.T :	25.7	U/L	8 - 78
<u>BILIRUBIN</u>			
Total :	1.21	mg/dl	Up to 1.2
Direct :	0.43	mg/dl	0-0.7
Indirect :	0.78	mg/dl	0 - 0.5
<u>SERUM PROTEINS</u>			
Total Protein (Serum by Biuret method) :	7.06	gms/dl	6.4 - 8.5
Albumin (Serum by BCG method) :	4.07	gms/dl	3.97-4.94
Globulins :	2.99	gms/dl	2.3 - 3.5
A/G Ratio :	1.361		0.9 - 2.9

Dr. Gayatri M. Mehta
M. D. (Patho)
Reg. No. G-32215

DR GAYATRI MEHTA
MD(PATHOLOGY)

DR. ANAND D. PARIKH
MD(PATHOLOGY)

LAB USE ONLY (Entered by :GM Enter Date/Time:23/03/2024 7:07:00 PM) (Verify by :GM Verify Date/Time:23/03/2024 7:07:00 PM)



Vidhi Diagnostics | Pathology Department

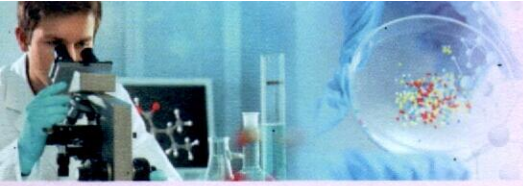L-86, Swatantra Senani Nagar, Opp. Akhbar Nagar Petrol Pump, Nr. Akhbar Nagar Circle, Nava-Vadaj, Ahmedabad - 380 013.

M. - Pathology : 8849893954, Ph. : 079-27621406, M. 98799 29406, 98250 09406, E-mail : vidhidiagnostics@gmail.com, Web. : www.vidhidiagnostics.com

Time (Pathology) : Mon. to Sat. 8.30 am to 8.00 pm, Sunday 9 am to 12 Noon

Pathology means science behind medicine

CT SCAN & CBCT FACILITY NOW AVAILABLE



Creating life in samples

Pathology Department

Patient's name : NIRUPABEN JAYESH PARMAR
Age/Sex : 50 Years/Female
Referred by : MEDI WHEEL
Collection Time : 11:01

Reg. ID : P-6860-23
Accession : 24700
Order Dt/time : 23/03/2024 11:01

Thyroid Function Test

Sample Type: Serum

Test Name	Result	Units	Biological Reference Interval
TOTAL T3 :	1.57	ng/ml	1.07 - 1.86
TOTAL T4 :	10.00	µg/dL	6.09 - 12.23
TSH(Ultra sensitive) :	3.18	µIU/mL	0.4001 - 4.049

Dr. Gayatri M. Mehta
M. D. (Patho)

Reg. No. G-32215

DR GAYATRI MEHTA
MD(PATHOLOGY)

DR. ANAND D. PARIKH
MD(PATHOLOGY)

LAB USE ONLY (Entered by :AP Enter Date/Time:23/03/2024 5:41:00 PM) (Verify by :GM Verify Date/Time:23/03/2024 6:08:00 PM)



Vidhi Diagnostics | Pathology Department

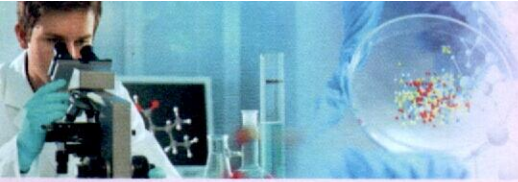L-86, Swatantra Senani Nagar, Opp. Akhbarnagar Petrol Pump, Nr. Akhbarnagar Circle, Nava-Vadaj, Ahmedabad - 380 013.

M. - Pathology : 8849893954, Ph. : 079-27621406, M. 98799 29406, 98250 09406, E-mail : vidhidiagnostics@gmail.com, Web. : www.vidhidiagnostics.com

Time (Pathology) : Mon. to Sat. 8.30 am to 8.00 pm, Sunday 9 am to 12 Noon

Pathology means science behind medicine

CT SCAN & CBCT FACILITY NOW AVAILABLE



Pathology Department



Patient's name : NIRUPABEN JAYESH PARMAR
 Age/Sex : 50 Years/Female
 Referred by : MEDI WHEEL
 Collection Time : 11:01

Reg. ID : P-6860-23
 Accession : 24700
 Order Dt/time : 23/03/2024 11:01

Urine Analysis

Sample Type: Urine

Test Name	Result	Units	Biological Reference Interval
Physical Examination			
Quantity :	30	ml	0 - 500 ml
Colour :	Pale Yellow		Pale Yellow
Transparency :	Slight Turbid.		Clear
Reaction :	Acidic		4.6 - 8.0
Specific Gravity :	1.020		1.016 - 1.022
Sediment :	Present		
Chemical Examination			
Albumin :	Present (Faint Trace)		Absent
Sugar :	NIL		Absent
Acetone :	Absent		Absent
Bile Salts :	Absent		Absent
Bile Pigments :	Absent		Absent
Urobilogen :	Absent		Absent
Nitrites :	Absent		Absent
Microscopic Examination			
Red blood Cells :	2-3	/h.p.f	Absent
Pus Cells :	1-2	/h.p.f	Absent
Epithelial Cells :	1-2	/h.p.f	< 10.0
Amorphous :	Absent	/h.p.f	Absent
Bacteria :	Absent	/h.p.f	Absent
Crystals :	Absent	/h.p.f	Absent
Casts :	Absent	/h.p.f	Absent
Fungus :	Not seen	/h.p.f	Absent

Dr. Gayatri M. Mehta
 M.D. (Pathology)

Reg. No. G-32215

DR GAYATRI MEHTA
 MD(PATHOLOGY)



(Entered by :GM

Enter Date/Time:23/03/2024 7:12:00 PM)

(Verify by :GM

Verify Date/Time:23/03/2024 7:12:00 PM)

DR. ANAND D. PARIKH
 MD(PATHOLOGY)

Vidhi Diagnostics | Pathology Department

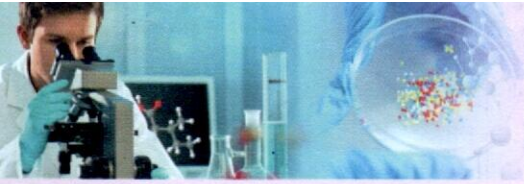L-86, Swatantra Senani Nagar, Opp. Akhbar Nagar Petrol Pump, Nr. Akhbar Nagar Circle, Nava-Vadaj, Ahmedabad - 380 013.

M. - Pathology : 8849893954, Ph. : 079-27621406, M. 98799 29406, 98250 09406, E-mail : vidhidiagnostics@gmail.com, Web. : www.vidhidiagnostics.com

Time (Pathology) : Mon. to Sat. 8.30 am to 8.00 pm, Sunday 9 am to 12 Noon

Pathology means science behind medicine

CT SCAN & CBCT FACILITY NOW AVAILABLE



Pathology Department

VIDHI[®]
DIAGNOSTICS

Creating Life in Gujarat

Patient's name : NIRUPABEN JAYESH PARMAR
Age/Sex : 50 Years/Female
Referred by : MEDI WHEEL
Collection Time : 11:01

Reg. ID : P-6860-23
Accession : 24700
Order Dt/time : 23/03/2024 11:01

Stool Examination

SAMPLE NOT RECEIVED

Dr. Gayatri M. Mehta
M. D. (Patho)

DR GAYATRI MEHTA
MD(PATHOLOGY)

Reg. No. G-32215

DR. ANAND D. PARIKH
MD(PATHOLOGY)

LAB USE ONLY (Entered by :GM Enter Date/Time:23/03/2024 7:11:00 PM) (Verify by :GM Verify Date/Time:23/03/2024 7:11:00 PM)



Vidhi Diagnostics | Pathology Department

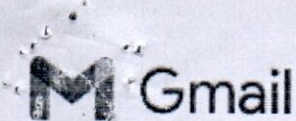
L-86, Swatantra Senani Nagar, Opp. Akhbarnagar Petrol Pump, Nr. Akhbarnagar Circle, Nava-Vadaj, Ahmedabad - 380 013.

M. - Pathology : 8849893954, Ph. : 079-27621406, M. 98799 29406, 98250 09406, E-mail : vidhidiagnostics@gmail.com, Web. : www.vidhidiagnostics.com

Time (Pathology) : Mon. to Sat. 8.30 am to 8.00 pm, Sunday 9 am to 12 Noon

Pathology means science behind medicine

CT SCAN & CBCT FACILITY NOW AVAILABLE



vidhi diagnostics <vidhidiagnostics@gmail.com>

Health Check up Booking Request(bobE12400), Beneficiary Code-125130

1 message

Mediwheel <wellness@mediwheel.in>

1 March 2024 at 11:13

To: vidhidiagnostics@gmail.com

Cc: customercare@mediwheel.in



Mediwheel
...Your wellness partner

011-41195959

Dear VIDHI DIAGNOSTICS

We have received a booking request with the following details. Provide your confirmation by clicking on the Yes button.

You confirm this booking? Yes No

Name : MS. PARMAR NIRUPABEN JAYESH

Hospital Package Name : Mediwheel Full Body Health Checkup Female Above 40

Name of Diagnostic/Hospital : VIDHI DIAGNOSTICS

Address of Diagnostic/Hospital- : L-86 Swatantra - Senani Nagar , Opp- Akhbarnagar Bus Terminals, New Wadaj , Ahmedabad -13

Appointment Date : 23-03-2024

Member Information

Booked Member Name	Age	Gender
MS. PARMAR NIRUPABEN JAYESH	50 year	Female

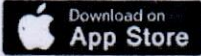
Tests included in this Package -

- Mammography
- Stool Test
- Gynae Consultation
- Thyroid Profile
- ESR
- Blood Glucose (Fasting)
- General Physician Consultation
- TMT OR 2D ECHO
- Blood Group
- Blood Glucose (Post Prandial)
- Chest X-ray
- ECG
- USG Whole Abdomen
- Eye Check-up consultation
- Urine Sugar Fasting
- Urine Sugar PP
- Dental Consultation

- Urine analysis
- CBC
- Lipid Profile
- Kidney Profile
- Liver profile

Thanks,
Mediwheel Team

Please Download Mediwheel App



You have received this mail because your e-mail ID is registered with **Arcofemi Healthcare Limited** This is a system-generated e-mail please don't reply to this message.

Please visit to our Terms & Conditions for more informaion. Click here to unsubscribe.

@ 2024 - 25, Arcofemi Healthcare Pvt Limited.(Mediwheel)

Dr. Dinesh S. Modh

M.D., D.M.R.E. (Radiodiagnosis)
Consultant Radiologist & Sonologist
Ex. Junior Lecturer, B.J. Medical College, Civil Hospital, A'bad.



DATE: 23/03/2024		
NAME: Nishuaben J. Parmar		
AGE: 50 yrs / female		
MEDICAL EXAMINATION:-		
HEIGHT: 157cm	WEIGHT: 57kg	
BP: 106/78 mmHg	PULSE: 60 per min	
SPO2: 98	TEMPERATURE: (N)	
RS: (N)	CVS: (N)	
ASYMTOMATIC		
HISTORY: No H/O DM, HTN, Thyroid or TB		
EYE CHECK-UP:-	RIGHT	LEFT
DISTANCE:	6/6	6/6
NEAR:	N/G with specs	N/G with specs
COLOR VISION:	Normal	Normal
DENTAL CHECK-UP:	Normal	
ADV: HE/SHE IS MEDICALLY FIT		

Dr. Vidhi D. Modh
MBBS
Reg. No. G-74540


ISO 9001:2015 Certified Diagnostics Center
Vidhi Imaging Center

L-86, Swatantra Senani Nagar, Opp. Indian Oil Petrol Pump, Akhbar Nagar Circle, Nava Vadaj, Ahmedabad - 380 013.

Phone : (Radiology) 079-2762 1406 | M. 98799 29406, 98250 09406 | Time (Radiology) : Mon. to Sat. 9 am to 2 pm, 5 to 9 pm, Sunday 9 am to 12 Noon
E-mail : vidhidiagnostics@gmail.com, Website : www.vidhidiagnostics.com

Multislice CT Scan | CBCT-Dental Scan | Live 3D-4D Sonography | Colour Doppler | Echo Cardiography | Interventional Radiology | Maxillofacial Radiology | Fetal Medicine
Digital X-Ray | Digital Mammography | Digital OPG/TMJ | ECG/TMT/PFT/EEG/EMG | Audiometry | Pathology Laboratory | Health Check Up Plans | Pre Employment Check Up

CT SCAN & CBCT FACILITY NOW AVAILABLE



Vidhi Diagnostics
 L-86, Suratnra-Genani Nagar,
 Opp. Akharnagar Bus Terminal,
 Nr. Akharnagar Circle,
 New Wadaj, Ahmedabad-13.

<< Analysis Result >>

** normal ECG **
Sinus rhythm

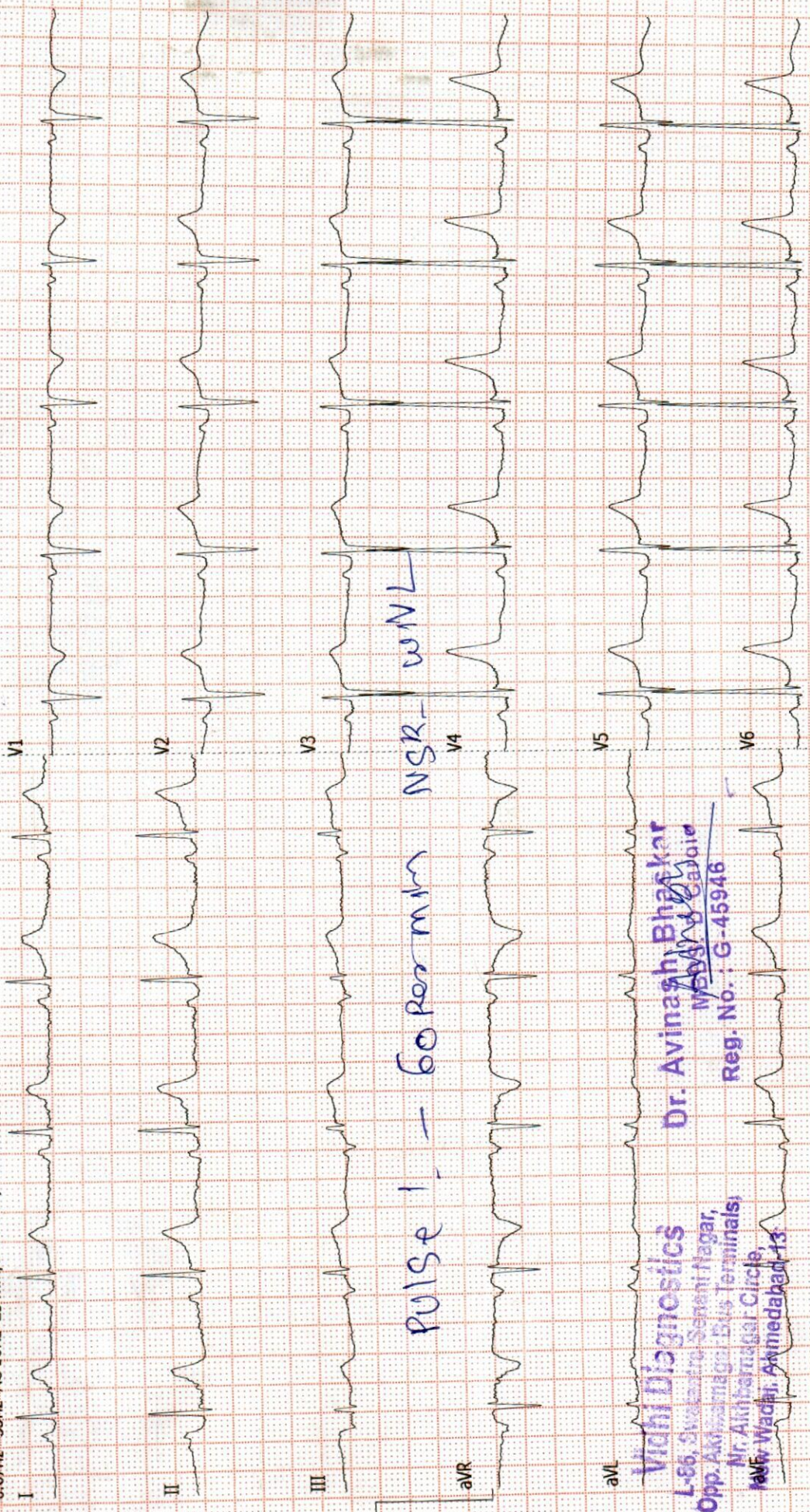
HR : 61 bpm
PR : 162 ms
QRS : 82 ms
QT/QTc : 408/410 ms
P/QRS/T : 27/44/53 deg.
RV5/SV1 : 0.404/-0.437 mv

ID: 13175
Name: niirupa
Age: 50yrs
Sex: Female
Hospital: **Dr. Avinash Bhaskar**
Dr. D. Carajo

Reg. No. : G-45946
RV5+SV1: 0.841 mv

Need to be confirmed by doctor. Doctor Name: _____

0.67Hz - 35Hz AC 50Hz 25 mm/s 20 mm/mv



Pulse! - 60 per min NSR - wNL

Vichi Diagnostics
Dr. Avinash Bhaskar
M.B.B.S., D.C.C. (Cardio)
Reg. No. : G-45946

L-86, Sulekhtra, Senani Nagar,
Opp. Akhbarnagar Bus Terminal,
Mr. Akhbarnagar Circle,
JAVE Wadaj, Akmedabad-380013

Dr. Dinesh S. Modh

M.D., D.M.R.E. (Radiodiagnosis)

Consultant Radiologist & Sonologist

Ex. Junior Lecturer, B.J. Medical College, Civil Hospital, A'bad.



Patient's name : NIRUPABEN JAYESH PARMAR
Reg. ID : R-14859-23
Referred by : MEDI WHEEL

Age/Sex : 50 Years/Female
Accession : 24718
Date : 23/03/2024

X-RAY CHEST (PA VIEW)

Both lung fields appear normal.
No e/o consolidation or cavitations is seen.
Both costo-phrenic angles appear clear.
Cardiac size is within normal limits.
Both domes of diaphragm appear normal.
Bony thoracic cage appears normal.

Thanks for reference.

Dr. Dinesh S. Modh
MD DMRE (Radiodiagnosis)
DR DINESH S. MODH
M.D. DMRE(RADIODIAGNOSIS)

ISO 9001:2015 Certified Diagnostics Center

Vidhi Imaging Center

L-86, Swatantra Senani Nagar, Opp. Indian Oil Petrol Pump, Akhbar Nagar Circle, Nava Vadaj, Ahmedabad - 380 013.

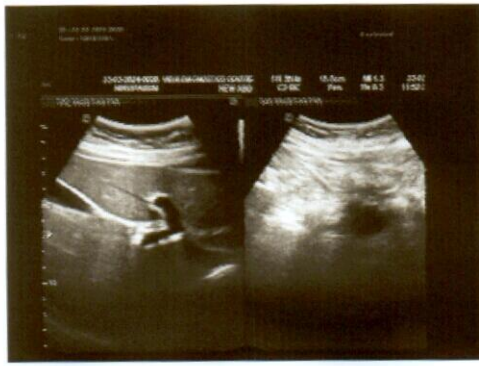
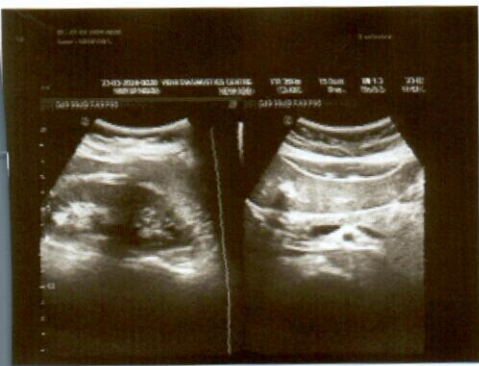
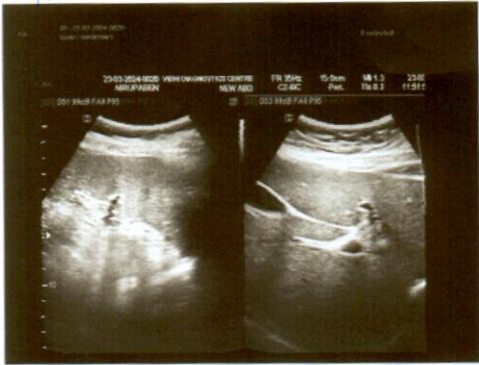
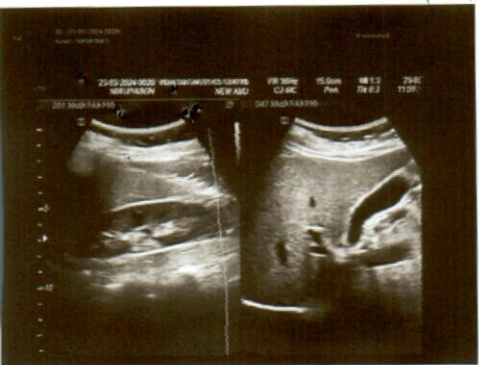Phone : (Radiology) 079-2762 1406 | M. 98799 29406, 98250 09406 | Time (Radiology) : Mon. to Sat. 9 am to 2 pm, 5 to 9 pm, Sunday 9 am to 12 Noon

E-mail : vidhidiagnostics@gmail.com, Website : www.vidhidiagnostics.com

Multislice CT Scan | CBCT-Dental Scan | Live 3D-4D Sonography | Colour Doppler | Echo Cardiography | Interventional Radiology | Maxillofacial Radiology | Fetal Medicine
Digital X-Ray | Digital Mammography | Digital OPG/TMJ | ECG/TMT/PFT/EEG/EMG | Audiometry | Pathology Laboratory | Health Check Up Plans | Pre Employment Check Up

CT SCAN & CBCT FACILITY NOW AVAILABLE

Wimper



Dr. Dinesh S. Modh

M.D., D.M.R.E. (Radiodiagnosis)

Consultant Radiologist & Sonologist

Ex. Junior Lecturer, B.J. Medical College, Civil Hospital, A'bad.



Patient's name : NIRUPABEN JAYESH PARMAR
Reg. ID : R-14859-23
Referred by : MEDI WHEEL

Age/Sex : 50 Years/Female
Accession : 24718
Date : 23/03/2024

USG ABDOMEN

LIVER:- Liver appears normal in size & show normal echo texture. No evidence of diffuse or focal lesion is seen. IHBR appear normal. Portal vein and CBD appear normal. No e/o calculus is seen in bile duct.

GALL BLADDER:- Gall bladder is distended & appears normal. No evidence of calculus or cholecystitis is seen.

SPLEEN:- Spleen appears normal in size & shows normal echo texture. No evidence of diffuse or focal lesion is seen.

PANCREAS:- Pancreas appears normal size and echo pattern. No e/o diffuse or focal lesion is seen. Main pancreatic duct appears normal.

KIDNEY:- Both Kidneys appear normal in size & echo texture.

No e/o hydronephrosis/ hydroureter or calculus is seen on both sides.

Cortico-medullary differentiation is maintained on either side.

Both suprarenal regions appear normal.

No evidence of pre & para aortic lymphadenopathy is seen.

RIF & BOWEL LOOPS (By high frequency probe):-Normal.

No evidence of free fluid is seen in abdomen.

No evidence of dilated or thickened bowel loops is seen.

Urinary bladder:-appears normal. No e/o calculus or mass lesion is seen.

Both adnexal regions appear normal.

No e/o free fluid is seen in pouch of Douglas.

Thanks for reference.

Dr. Dinesh S. Modh

M.D. DMRE (Radiodiagnosis)

DR DINESH S. MODH 25

M.D. DMRE(RADIODIAGNOSIS)

ISO 9001:2015 Certified Diagnostics Center

Vidhi Imaging Center

L-86, Swatantra Senani Nagar, Opp. Indian Oil Petrol Pump, Akhbarnagar Circle, Nava Vadaj, Ahmedabad - 380 013.

Phone : (Radiology) 079-2762 1406 | M. 98799 29406, 98250 09406 | Time (Radiology) : Mon. to Sat. 9 am to 2 pm, 5 to 9 pm, Sunday 9 am to 12 Noon
E-mail : vidhidiagnostics@gmail.com, Website : www.vidhidiagnostics.com

Multislice CT Scan | CBCT-Dental Scan | Live 3D-4D Sonography | Colour Doppler | Echo Cardiography | Interventional Radiology | Maxillofacial Radiology | Fetal Medicine
Digital X-Ray | Digital Mammography | Digital OPG/TMJ | ECG/TMT/PFT/EEG/EMG | Audiometry | Pathology Laboratory | Health Check Up Plans | Pre Employment Check Up

CT SCAN & CBCT FACILITY NOW AVAILABLE

Dr. Dinesh S. Modh

M.D., D.M.R.E. (Radiodiagnosis)
Consultant Radiologist & Sonologist
Ex. Junior Lecturer, B.J. Medical College, Civil Hospital, A'bad.



Patient's name : NIRUPABEN JAYESH PARMAR
Reg. ID : R-14859-23
Referred by : MEDI WHEEL

Age/Sex : 50 Years/Female
Accession : 24718
Date : 23/03/2024

2D- ECHO REPORT

FINAL CONCLUSION:

LV IS NORMAL SIZE. GOOD LV SYSTOLIC FUNCTION NO RWMA.
LVEF - 60%. NO CONCENTRIC LVH.
NORMAL LV COMPLANCE.
LA IS NORMAL SIZE. NO LA CLOT.
RV IS NORMAL SIZE. GOOD RV SYSTOLIC FUNCTION.
RA IS NORMAL SIZE.
MITRAL VALVE IS NORMAL. NO MS. NO MR . NO MVP.
AORTIC VALVE IS NORMAL. NO AS. NO AR.
TRICUSPID VALVE IS NORMAL. NO TR. RVSP-24 mmHg. NO PAH.

NO CLOT, NO VEGETATION, NO PERICARDIAL EFFUSION.

DIMENSIONS:

AORTA	2.5 C.M
LEFT ATRIUM	2.7 C.M
LVDD	4.1 C.M.
IVSD	1.0 C.M
PWD	1.0 C.M
LVDS	2.6 C.M.

COLOUR DOPPLER FINDING:

STRUCTURE	VELOCITY m/sec
	Max
PULMONARY VALVE	0.7
MITRAL VALVE	E : 0.7 A: 0.4
AORTIC VALVE	1.0

Dr. Avinash Bhaskar
MBBS, D. Cardio
DR AVINASH BHASKAR
CLINICAL CARDIOLOGIST
9924836431

ISO 9001:2015 Certified Diagnostics Center

Vidhi Imaging Center

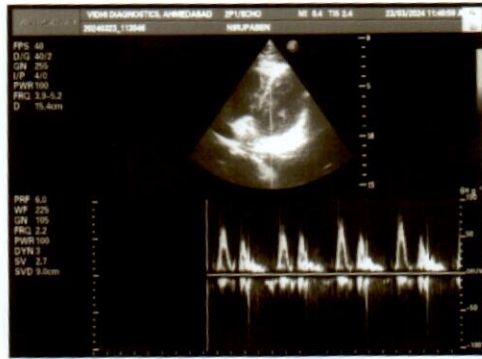
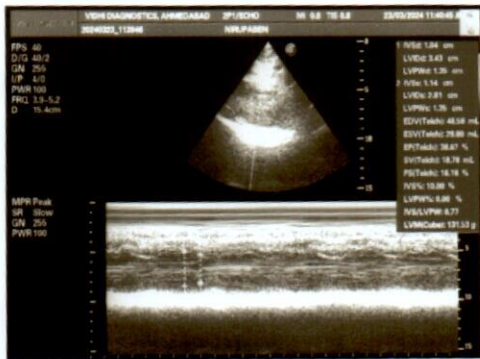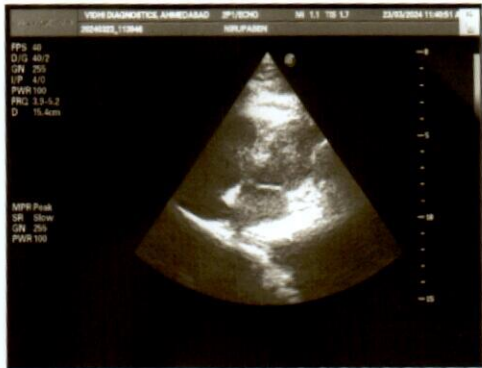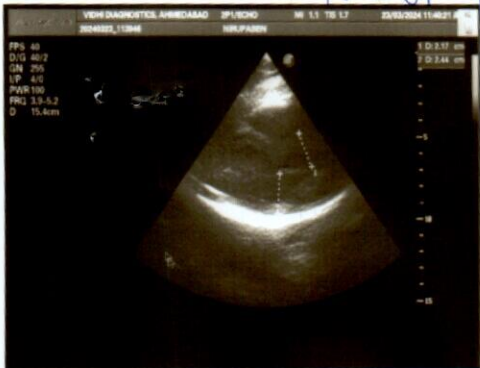L-86, Swatantra Senani Nagar, Opp. Indian Oil Petrol Pump, Akhbarnagar Circle, Nava Vadaj, Ahmedabad - 380 013.

Phone : (Radiology) 079-2762 1406 | M. 98799 29406, 98250 09406 | Time (Radiology) : Mon. to Sat. 9 am to 2 pm, 5 to 9 pm, Sunday 9 am to 12 Noon
E-mail : vidhidiagnostics@gmail.com, Website : www.vidhidiagnostics.com

Multislice CT Scan | CBCT-Dental Scan | Live 3D-4D Sonography | Colour Doppler | Echo Cardiography | Interventional Radiology | Maxillofacial Radiology | Fetal Medicine
Digital X-Ray | Digital Mammography | Digital OPG/TMJ | ECG/TMT/PFT/EEG/EMG | Audiometry | Pathology Laboratory | Health Check Up Plans | Pre Employment Check Up

CT SCAN & CBCT FACILITY NOW AVAILABLE

7/10/04



Dr. Dinesh S. Modh

M.D., D.M.R.E. (Radiodiagnosis)

Consultant Radiologist & Sonologist

Ex. Junior Lecturer, B.J. Medical College, Civil Hospital, A'bad.



Patient's name : NIRUPABEN JAYESH PARMAR
Reg. ID : R-14859-23
Referred by : MEDI WHEEL

Age/Sex : 50 Years/Female
Accession : 24718
Date : 23/03/2024

DIGITAL MAMMOGRAPHY

Digital mammography was done on Siemens mammomat-3000.

Reason for exam: - Screening.

Bilateral digital cranio-caudal and medio-lateral oblique views were taken.
The breast tissue is homogeneously dense with fibro-fatty tissue on both sides.
No masses, no architectural distortion, no suspicious calcifications, no asymmetries or other abnormalities are seen.
No e/o radio-opaque or radiolucent mass lesion is seen.
No e/o skin thickening is seen.
Nipple and sub-areolar tissue appear normal.
Axillary tail appears normal.

USG:-Normal.

Assessment:-Negative (BI-RADS category-1)

BI-RADS category

- 0- incomplete
- 1- Negative
- 2- Benign
- 3- Probably benign
- 4- Suspicious abnormality.
- 5- Highly suggestive of malignancy
- 6- Known biopsy-proven malignancy.

The false negative mammography is approximately 10%. Management of palpable abnormality must be based upon clinical grounds.

Thanks for reference.


Dr. Dinesh S. Modh
MD DMRE (Radiodiagnosis)
G-23825
M.D. DMRE (RADIO DIAGNOSIS)

ISO 9001:2015 Certified Diagnostics Center

Vidhi Imaging Center

L-86, Swatantra Senani Nagar, Opp. Indian Oil Petrol Pump, Akhbarnagar Circle, Nava Vadaj, Ahmedabad - 380 013.

Phone : (Radiology) 079-2762 1406 | M. 98799 29406, 98250 09406 | Time (Radiology) : Mon. to Sat. 9 am to 2 pm, 5 to 9 pm, Sunday 9 am to 12 Noon
E-mail : vidhidiagnostics@gmail.com, Website : www.vidhidiagnostics.com

Multislice CT Scan | CBCT-Dental Scan | Live 3D-4D Sonography | Colour Doppler | Echo Cardiography | Interventional Radiology | Maxillofacial Radiology | Fetal Medicine
Digital X-Ray | Digital Mammography | Digital OPG/TMJ | ECG/TMT/PFT/EEG/EMG | Audiometry | Pathology Laboratory | Health Check Up Plans | Pre Employment Check Up

CT SCAN & CBCT FACILITY NOW AVAILABLE