



Creating life in Sangra



Pathology Department

Patient's name : ANIL KUMAR
Age/Sex : 28 Years/Male
Referred by : MEDI WHEEL
Collection Time : 09:54

Reg. ID : P-6844-23
Accession : 24673
Order Dt/time : 23/03/2024 09:54

Complete Blood Count

Sample Type: EDTA

Table with 4 columns: Test Name, Result, Units, Biological Reference Interval. Rows include Blood Counts (Haemoglobin, R.B.C., W.B.C., Platelet Count), Differential Count (Neutrophils, Lymphocytes, Eosinophils, Monocytes, Basophils), Blood Indices (P.C.V., M.C.V., M.C.H., M.C.H.C., R.D.W.), and E.S.R. (Westergren Method).

TESTS DONE ON FULLY AUTOMATED HEMATOLOGY ANALYZER.

Dr. Gayatri M. Mehta

M. D. (Patho)

Reg. No. G-32215

DR GAYATRI MEHTA
MD(PATHOLOGY)

DR. ANAND D. PARIKH
MD(PATHOLOGY)

LAB USE ONLY (Entered by :GM Enter Date/Time:23/03/2024 5:53:00 PM) (Verify by :GM Verify Date/Time:23/03/2024 5:53:00 PM)



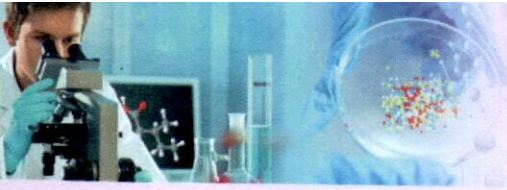Vidhi Diagnostics | Pathology Department

L-86, Swatantra Senani Nagar, Opp. Akhbarnagar Petrol Pump, Nr. Akhbarnagar Circle, Nava-Vadaj, Ahmedabad - 380 013.

Pathology : 8849893954, Ph. : 079-27621406, M. 98799 29406, 98250 09406, E-mail : vidhidiagnostics@gmail.com, Web. : www.vidhidiagnostics.com
Time (Pathology) : Mon. to Sat. 8.30 am to 8.00 pm, Sunday 9 am to 12 Noon

Pathology means science behind medicine

CT SCAN & CBCT FACILITY NOW AVAILABLE



Creating Life in Progress

VIDHI
DIAGNOSTICS



Pathology Department

Patient's name : ANIL KUMAR
Age/Sex : 28 Years/Male
Referred by : MEDI WHEEL
Collection Time : 09:54

Reg. ID : P-6844-23
Accession : 24673
Order Dt/time : 23/03/2024 09:54

Blood Group

Sample Type: EDTA sample.

Test Name	Result
BG :	" O "
RH :	NEGATIVE
Remarks :	Done by forward grouping method.

Blood Glucose

Sample Type: Serum

Test Name	Result	Units	Biological Reference Interval
Fasting Blood Glucose :	<u>149.9</u>	mg/dl	70 - 110
Urine Sugar :	<u>Present (+)</u>		Absent
<i>GOD-POD Method.</i>			

Blood Glucose

Sample Type: Serum

Test Name	Result	Units	Biological Reference Interval
Post Prandial Blood Glucose After 2hr. :	<u>236.7</u>	mg/dl	80 - 140
Urine Sugar :	<u>Present (++++)</u>		Absent
<i>GOD-POD Method.</i>			

Dr. Gayatri M. Mehta

M. D. (Patho)
Reg. No. G-32215

DR GAYATRI MEHTA
MD(PATHOLOGY)

DR.ANAND D.PARIKH
MD(PATHOLOGY)

LAB USE ONLY (Entered by :GM Enter Date/Time:23/03/2024 6:34:00 PM) (Verify by :GM Verify Date/Time:23/03/2024 6:34:00 PM)



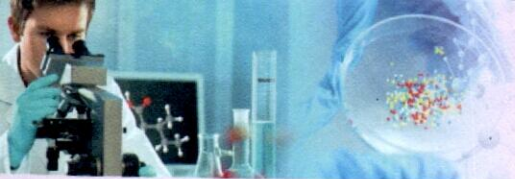Vidhi Diagnostics | Pathology Department

L-86, Swatantra Senani Nagar, Opp. Akhbarnagar Petrol Pump, Nr. Akhbarnagar Circle, Nava-Vadaj, Ahmedabad - 380 013.

M. - Pathology : 8849893954, Ph. : 079-27621406, M. 98799 29406, 98250 09406, E-mail : vidhidiagnostics@gmail.com, Web. : www.vidhidiagnostics.com
Time (Pathology) : Mon. to Sat. 8.30 am to 8.00 pm, Sunday 9 am to 12 Noon

Pathology means science behind medicine

CT SCAN & CBCT FACILITY NOW AVAILABLE



Creating Life in Progress



Pathology Department

Patient's name : ANIL KUMAR
Age/Sex : 28 Years/Male
Referred by : MEDI WHEEL
Collection Time : 09:54

Reg. ID : P-6844-23
Accession : 24673
Order Dt/time : 23/03/2024 09:54

HbA1C

Sample Type: EDTA

Test Name	Result	Units	Biological Reference Interval
HbA1C :	<u>8.2</u>	%	Non-diabetic: 4.2-6.2 Pre-diabetic : 6.3-7.2 Diabetic : 7.3-8.2
Mean Blood Glucose of Last 03 months.	-10990.378	mg/dl	

Comment *As per the new 2009 update of American Diabetes Association regarding HbA1C & Mean Blood Glucose relationship.

NOTE: This test is used to monitor diabetic patients compliance with the therapeutic regimen and logo It's level is proportional to both the average blood glucose concentration and the life span of the red blood cells (RBC) in circulation. HbA1c values are free of day to day glucose fluctuations and are unaffected by exercise or recent food intake.

Dr. Gayatri M. Mehta
M. D. (Patho)
Reg. No. G-32215

DR GAYATRI MEHTA
MD(PATHOLOGY)

DR. ANAND D. PARIKH
MD(PATHOLOGY)

LAB USE ONLY (Entered by :GM Enter Date/Time:23/03/2024 6:34:00 PM) (Verify by :GM Verify Date/Time:23/03/2024 6:34:00 PM)



Vidhi Diagnostics | Pathology Department

L-86, Swatantra Senani Nagar, Opp. Akhbarnagar Petrol Pump, Nr. Akhbarnagar Circle, Nava-Vadaj, Ahmedabad - 380 013.

M. - Pathology : 8849893954, Ph. : 079-27621406, M. 98799 29406, 98250 09406, E-mail : vidhidiagnostics@gmail.com, Web. : www.vidhidiagnostics.com

Time (Pathology) : Mon. to Sat. 8.30 am to 8.00 pm, Sunday 9 am to 12 Noon

Pathology means science behind medicine

CT SCAN & CBCT FACILITY NOW AVAILABLE



Creating life in
Pathology

Pathology Department

Patient's name : ANIL KUMAR
Age/Sex : 28 Years/Male
Referred by : MEDI WHEEL
Collection Time : 09:54

Reg. ID : P-6844-23
Accession : 24673
Order Dt/time : 23/03/2024 09:54

Lipid Profile

Sample Type: Serum

Test Name	Result	Units	Biological Reference Interval
S. Cholesterol : Oxidase-esterase method.	150	mg/dl	0 - 200
S. Triglyceride : Enzymatic Colorimetry method	129.8	mg/dL	0 - 200
S. HDL - Cholesterol : Serum by Enzymatic method.	<u>23.6</u>	mg/dL	35 - 65
S. LDL - Cholesterol : Serum by Enzymatic method	100.44	mg/dL	0 - 130
S. VLDL - Cholesterol :	25.96	mg/dL	0 - 30
S. Chole/HDL.Ratio :	<u>6.36</u>		1 - 6
S. LDL / HDL Cholesterol Ratio :	<u>4.26</u>		0 - 3.5

Dr. Gayatri M. Mehta
M. D. (Patho)

Reg. No. G-32215

DR GAYATRI MEHTA
MD(PATHOLOGY)

DR. ANAND D. PARIKH
MD(PATHOLOGY)

LAB USE ONLY (Entered by :GM Enter Date/Time:23/03/2024 6:35:00 PM) (Verify by :GM Verify Date/Time:23/03/2024 6:35:00 PM)



Vidhi Diagnostics | Pathology Department


L-86, Swatantra Senani Nagar, Opp. Akhbarnagar Petrol Pump, Nr. Akhbarnagar Circle, Nava-Vadaj, Ahmedabad - 380 013.

M. - Pathology : 8849893954, Ph. : 079-27621406, M. 98799 29406, 98250 09406, E-mail : vidhidiagnostics@gmail.com, Web. : www.vidhidiagnostics.com

Time (Pathology) : Mon. to Sat. 8.30 am to 8.00 pm, Sunday 9 am to 12 Noon

Pathology means science behind medicine

CT SCAN & CBCT FACILITY NOW AVAILABLE



Creating life in samples



Pathology Department

Patient's name : ANIL KUMAR
 Age/Sex : 28 Years/Male
 Referred by : MEDI WHEEL
 Collection Time : 09:54

Reg. ID : P-6844-23
 Accession : 24673
 Order Dt/time : 23/03/2024 09:54

BIOCHEMISTRY

Sample type :Serum

Test Name	Result	Units	Biological Reference Interval
Urea , (Serum by GLDH method) :	27.5	mg/dl	10 - 50
S.Uric acid , (Serum by Uricase method) :	6.3	mg/dl	3.4 - 7.0
Bun :	12.9	mg/dl	6-20
Creatinine , (Serum by Enzymatic reaction) :	0.56	mg/dl	0.5-1.2
S.G.P.T (ALT) : (Serum by IFCC method)	55.3	U/L	0 - 40
S.G.O.T (AST) : (Serum by IFCC method)	26.3	U/L	0 - 37
ALK.PHOSPHATASE : (Serum by PNP method)	129	U/L	40-129
G.G.T :	57.2	U/L	8 - 78
<u>BILIRUBIN</u>			
Total :	0.78	mg/dl	Up to 1.2
Direct :	0.40	mg/dl	0-0.7
Indirect :	0.38	mg/dl	0 - 0.5
<u>SERUM PROTEINS</u>			
Total Protein (Serum by Biuret method) :	7.17	gms/dl	6.4 - 8.5
Albumin (Serum by BCG method) :	4.18	gms/dl	3.97-4.94
Globulins :	2.99	gms/dl	2.3 - 3.5
A/G Ratio :	1.398		0.9 - 2.9

Dr. Gayatri M. Mehta
 M. D: (Patho)
 Reg. No. G-32215
 DR GAYATRI MEHTA
 MD(PATHOLOGY)

DR.ANAND D.PARIKH
 MD(PATHOLOGY)

LAB USE ONLY (Entered by :GM Enter Date/Time:23/03/2024 6:33:00 PM) (Verify by :GM Verify Date/Time:23/03/2024 6:33:00 PM)



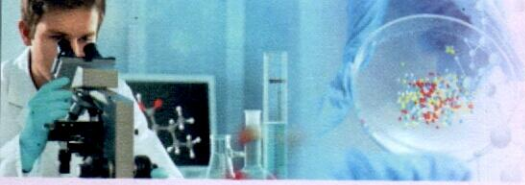Vidhi Diagnostics | Pathology Department

L-86, Swatantra Senani Nagar, Opp. Akhbarnagar Petrol Pump, Nr. Akhbarnagar Circle, Nava-Vadaj, Ahmedabad - 380 013.

M. - Pathology : 8849893954, Ph. : 079-27621406, M. 98799 29406, 98250 09406, E-mail : vidhidiagnostics@gmail.com, Web. : www.vidhidiagnostics.com
 Time (Pathology) : Mon. to Sat. 8.30 am to 8.00 pm, Sunday 9 am to 12 Noon

Pathology means science behind medicine

CT SCAN & CBCT FACILITY NOW AVAILABLE



Creating life in Science

VIDHI[®]
DIAGNOSTICS

Pathology Department

Patient's name : ANIL KUMAR
Age/Sex : 28 Years/Male
Referred by : MEDI WHEEL
Collection Time : 09:54

Reg. ID : P-6844-23
Accession : 24673
Order Dt/time : 23/03/2024 09:54

Thyroid Function Test

Sample Type: Serum

Test Name	Result	Units	Biological Reference Interval
TOTAL T3 :	1.46	ng/ml	1.1 - 1.84
TOTAL T4 :	7.50	µg/dL	6.09 - 12.23
TSH(Ultra sensitive) :	1.39	µIU/mL	0.4001 - 4.049

Dr. Gayatri M. Mehta

M. D. (Patho)

Reg. No. G-32215

DR GAYATRI MEHTA
MD(PATHOLOGY)

DR. ANAND D. PARIKH
MD(PATHOLOGY)

LAB USE ONLY (Entered by :GM Enter Date/Time:23/03/2024 5:54:00 PM) (Verify by :GM Verify Date/Time:23/03/2024 6:04:00 PM)



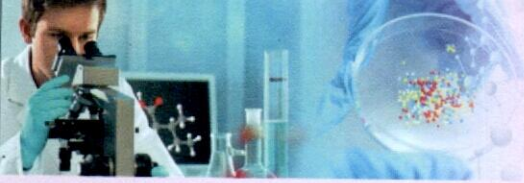Vidhi Diagnostics | Pathology Department

L-86, Swatantra Senani Nagar, Opp. Akhbaragar Petrol Pump, Nr. Akhbaragar Circle, Nava-Vadaj, Ahmedabad - 380 013.

M. - Pathology : 8849893954, Ph. : 079-27621406, M. 98799 29406, 98250 09406, E-mail : vidhidiagnostics@gmail.com, Web. : www.vidhidiagnostics.com
Time (Pathology) : Mon. to Sat. 8.30 am to 8.00 pm, Sunday 9 am to 12 Noon

Pathology means science behind medicine

CT SCAN & CBCT FACILITY NOW AVAILABLE



Creating Life in Progress



Pathology Department

Patient's name : ANIL KUMAR
Age/Sex : 28 Years/Male
Referred by : MEDI WHEEL
Collection Time : 09:54

Reg. ID : P-6844-23
Accession : 24673
Order Dt/time : 23/03/2024 09:54

Urine Analysis

Sample Type: Urine

Test Name	Result	Units	Biological Reference Interval
Physical Examination			
Quantity :	30	ml	0 - 500 ml
Colour :	Pale Yellow		Pale Yellow
Transparency :	Slight Turbid.		Clear
Reaction :	Acidic		4.6 - 8.0
Specific Gravity :	1.030		1.016 - 1.022
Sediment :	Present		
Chemical Examination			
Albumin :	Present (Faint Trace)		Absent
Sugar :	Present (+)		Absent
Acetone :	Absent		Absent
Bile Salts :	Absent		Absent
Bile Pigments :	Absent		Absent
Urobilogen :	Absent		Absent
Nitrites :	Absent		Absent
Microscopic Examination			
Red blood Cells :	1-2	/h.p.f	Absent
Pus Cells :	1-2	/h.p.f	Absent
Epithelial Cells :	2-3	/h.p.f	< 10.0
Amorphous :	Absent	/h.p.f	Absent
Bacteria :	Absent	/h.p.f	Absent
Crystals :	Absent	/h.p.f	Absent
Casts :	Absent	/h.p.f	Absent
Fungus :	Not seen	/h.p.f	Absent

Dr. Gayatri M. Mehta

M. D. (Patho)

Reg. No. G-32215

DR. GAYATRI MEHTA
MD (PATHOLOGY)



DR. ANAND D. PARIKH
MD (PATHOLOGY)

ONLY (Entered by :GM Enter Date/Time:23/03/2024 5:55:00 PM) (Verify by :GM Verify Date/Time:23/03/2024 5:55:00 PM)

Vidhi Diagnostics | Pathology Department

L-86, Swatantra Senani Nagar, Opp. Akhbarnagar Petrol Pump, Nr. Akhbarnagar Circle, Nava-Vadaj, Ahmedabad - 380 013.

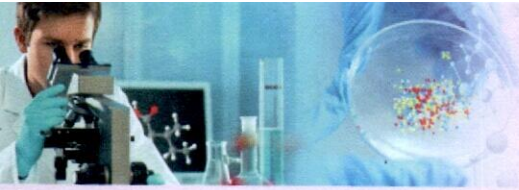M. - Pathology : 8849893954, Ph. : 079-27621406, M. 98799 29406, 98250 09406, E-mail : vidhidiagnostics@gmail.com, Web. : www.vidhidiagnostics.com

Time (Pathology) : Mon. to Sat. 8.30 am to 8.00 pm, Sunday 9 am to 12 Noon

Pathology means science behind medicine

CT SCAN & CBCT FACILITY NOW AVAILABLE





Creating life in Samples



Pathology Department

Patient's name : ANIL KUMAR	Reg. ID : P-6844-23
Age/Sex : 28 Years/Male	Accession : 24673
Referred by : MEDI WHEEL	Order Dt/time : 23/03/2024 09:54
Collection Time : 09:54	

Stool Examination

Sample Type: Stool

Test Name	Result	Units	Biological Reference Interval
-----------	--------	-------	-------------------------------

PHYSICAL EXAMINATION

Quantity	10 gms
Colour	Brown
Consistency	Solid
Mucus	Nil
Occult Blood	Negative
Peroxidase Reaction with o-Dianisidine	
Reaction	Acidic
pH Strip Method	

MICROSCOPIC EXAMINATION

Pus Cells	2 - 3/hpf
RBCs	Nil
Vegetable Cells	Absent
Trophozoites	Nil
Cysts	Nil
Ova	Nil
Fat Globules	Nil

----- End Of Report -----

Dr. Gayatri M. Mehta

M. D. (Patho)

Reg. No. G-32215

DR GAYATRI MEHTA
MD(PATHOLOGY)

DR. ANAND D. PARIKH
MD(PATHOLOGY)

LAB USE ONLY (Entered by :GM Enter Date/Time:23/03/2024 6:01:00 PM) (Verify by :GM Verify Date/Time:23/03/2024 6:01:00 PM)



Vidhi Diagnostics | Pathology Department

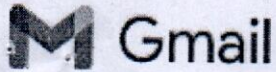
L-86, Swatantra Senani Nagar, Opp. Akhbarnagar Petrol Pump, Nr. Akhbarnagar Circle, Nava-Vadaj, Ahmedabad - 380 013.

M. - Pathology : 8849893954, Ph. : 079-27621406, M. 98799 29406, 98250 09406, E-mail : vidhidiagnostics@gmail.com, Web. : www.vidhidiagnostics.com

Time (Pathology) : Mon. to Sat. 8.30 am to 8.00 pm, Sunday 9 am to 12 Noon

Pathology means science behind medicine

CT SCAN & CBCT FACILITY NOW AVAILABLE



vidhi diagnostics <vidhidiagnostics@gmail.com>

Health Check up Booking Confirmed Request(bobE14131),Package Code-PKG10000474, Beneficiary Code-309963

Mediwheel <wellness@mediwheel.in>
 To: vidhidiagnostics@gmail.com
 Cc: customercare@mediwheel.in

20 March 2024 at 17:18



Mediwheel
 ...Your wellness partner

011-41195959

Hi **VIDHI DIAGNOSTICS**,

The following booking has been confirmed. It is requested to honor the said booking & provide priority services to our client

Hospital Package Name : Mediwheel Full Body Health Checkup Male Below 40

Patient Package Name : Mediwheel Full Body Health Checkup Male Below 40

Hospital Address : L-86 Swatantra - Senani Nagar , Opp- Akhbarnagar Bus Terminals, New Wadaj , Ahmedabad -13

Contact Details : 9782228003

Appointment Date : 23-03-2024

Confirmation Status : Booking Confirmed

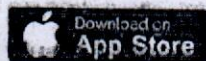Preferred Time : 8:00am

Member Information		
Booked Member Name	Age	Gender
MR. KUMAR ANIL	28 year	Male

We request you to facilitate the employee on priority.

Thanks,
 Mediwheel Team

Please Download Mediwheel App



You have received this mail because your e-mail ID is registered with **Arcofemi Healthcare Limited** This is a system-generated e-mail please don't reply to this message.





भारत सरकार



अनिल कुमार
Anil Kumar
 जन्म तिथि / DOB : 10/07/1995
 पुरुष / MALE
 Mobile No. 9571977535
2367 3083 1376
 VID : 9146 5131 8102 0343

मेरा आधार, मेरी पहचान

Vidhi Diagnostics
 I-86, Swatantra-Senani Nagar,
 Nr. Akhbarnagar Bus Terminals
 New Wadaj, Ahmedabad-13.

Dr. Dinesh S. Modh

M.D., D.M.R.E. (Radiodiagnosis)
Consultant Radiologist & Sonologist
Ex. Junior Lecturer, B.J. Medical College, Civil Hospital, A'bad.

VIDHI
DIAGNOSTICS



DATE: 23/3/2024		
NAME: Anil Kumar		
AGE: 28 yrs male		
MEDICAL EXAMINATION:-		
HEIGHT: 178 cm	WEIGHT: 77 kg	
BP: 122/78 mmHg	PULSE:	
SPO2: 98	TEMPRATURE: (N)	
RS: (N)	CVS: (N)	
ASYMTOMATIC		
HISTORY: No H/O DM, HTN, Thyroid or TB		
EYE CHECK-UP:-	RIGHT	LEFT
DISTANCE:	6/6 with specs	6/6 with specs
NEAR:	N/6	N/6
COLOR VISION:	(N)	(N)
DENTAL CHECK-UP:	} (N)	
ADV: HE/SHE IS MEDICALLY FIT		

Dr. Vidhi D. Modh
MBBS
Reg. No. G-74540

Vidhi Diagnostics
L-86, Swatantra-Senani Nagar,
Akhabarnagar Bus Terminals
Nr. Akhabarnagar Circle,
New Wadaj, Ahmedabad-13.

ISO 9001:2015 Certified Diagnostics Center
Vidhi Imaging Center

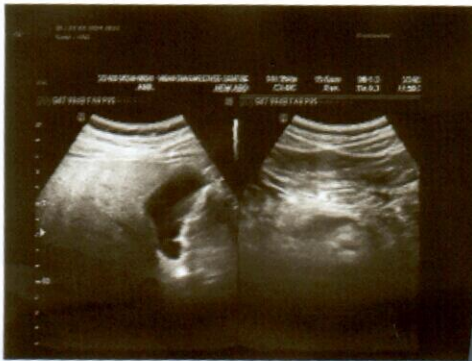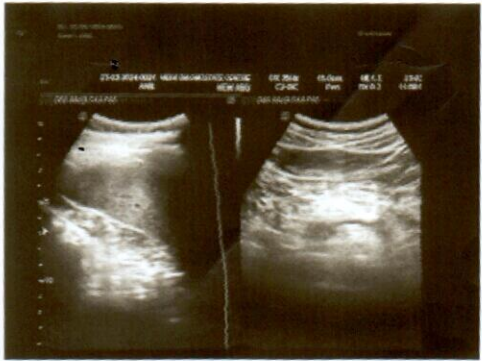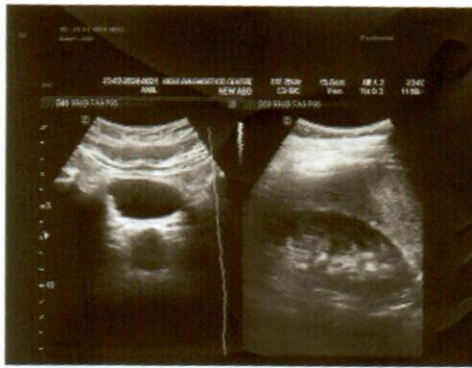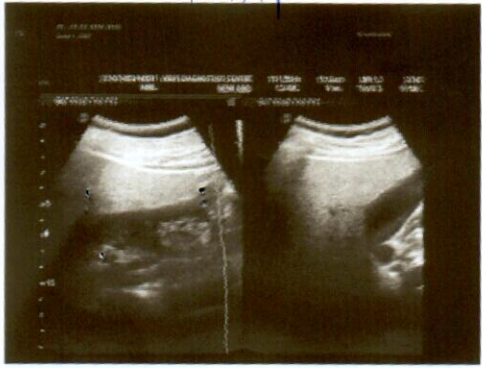L-86, Swatantra Senani Nagar, Opp. Indian Oil Petrol Pump, Akhabarnagar Circle, Nava Vadaj, Ahmedabad - 380 013.

Phone : (Radiology) 079-2762 1406 | M. 98799 29406, 98250 09406 | Time (Radiology) : Mon. to Sat. 9 am to 2 pm, 5 to 9 pm, Sunday 9 am to 12 Noon
E-mail : vidhidiagnostics@gmail.com, Website : www.vidhidiagnostics.com

Multislice CT Scan | CBCT-Dental Scan | Live 3D-4D Sonography | Colour Doppler | Echo Cardiography | Interventional Radiology | Maxillofacial Radiology | Fetal Medicine
Digital X-Ray | Digital Mammography | Digital OPG / TMJ | ECG / TMT / PFT / EEG / EMG | Audiometry | Pathology Laboratory | Health Check Up Plans | Pre Employment Check Up

CT SCAN & CBCT FACILITY NOW AVAILABLE

Am21



Dr. Dinesh S. Modh

M.D., D.M.R.E. (Radiodiagnosis)

Consultant Radiologist & Sonologist

Ex. Junior Lecturer, B.J. Medical College, Civil Hospital, A'bad.



Patient's name: ANILKUMAR
Reg. ID : R-14861-23
Referred by : Dr. MEDIWHEEL

Age/Sex : 28 Years/Male
Accession : 24720
Date : 23/03/2024

USG ABDOMEN

LIVER:- Liver appears normal in size & fatty echo texture grade1. No evidence of focal lesion is seen. IHBR appear normal. Portal vein and CBD appear normal. No e/o calculus is seen in bile duct.

GALL BLADDER:- Gall bladder is distended & appears normal. No evidence of calculus or cholecystitis is seen.

SPLEEN:- Spleen appears normal in size & shows normal echo texture. No evidence of diffuse or focal lesion is seen.

PANCREAS:- Pancreas appears normal size and echo pattern. No e/o diffuse or focal lesion is seen. Main pancreatic duct appears normal.

KIDNEY:- Both Kidneys appear normal in size & echo texture.

- No e/o calculus or hydronephrosis/ hydroureter is seen on both sides.

Cortico-medullary differentiation is maintained on both sides.

Both suprarenal regions appear normal.

No evidence of pre & para aortic lymphadenopathy is seen.

Both suprarenal regions appear normal.

No evidence of pre & para aortic lymphadenopathy is seen.

RIF & BOWEL LOOPS (By high frequency probe):- Normal.

No evidence of dilated or thickened bowel loops is seen.

No evidence of free fluid is seen in abdomen.

Urinary bladder:- appears normal. No e/o calculus or mass lesion is seen in bladder.

Prostate appears normal size and echopattern.

Thanks for reference.

Dr. Dinesh S. Modh
DR. DINESH S. MODH (Modh)
M.D. DMRE (Radiodiagnosis)
M.D. DMRE (RADIO DIAGNOSIS)
G-23825

Vidhi Diagnostics
L-86, Swatantra-Senani Nagar,
Nr. Akhbarnagar Bus Terminals
New Wadaj, Ahmedabad-13,

ISO 9001:2015 Certified Diagnostics Center

Vidhi Imaging Center

L-86, Swatantra Senani Nagar, Opp. Indian Oil Petrol Pump, Akhbarnagar Circle, Nava Vadaj, Ahmedabad - 380 013.

Phone : (Radiology) 079-2762 1406 | M. 98799 29406, 98250 09406 | Time (Radiology) : Mon. to Sat. 9 am to 2 pm, 5 to 9 pm, Sunday 9 am to 12 Noon

E-mail : vidhidiagnostics@gmail.com, Website : www.vidhidiagnostics.com

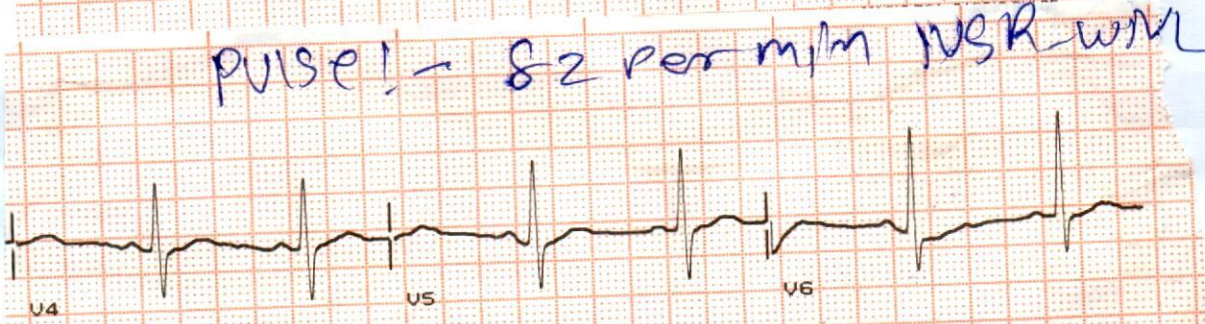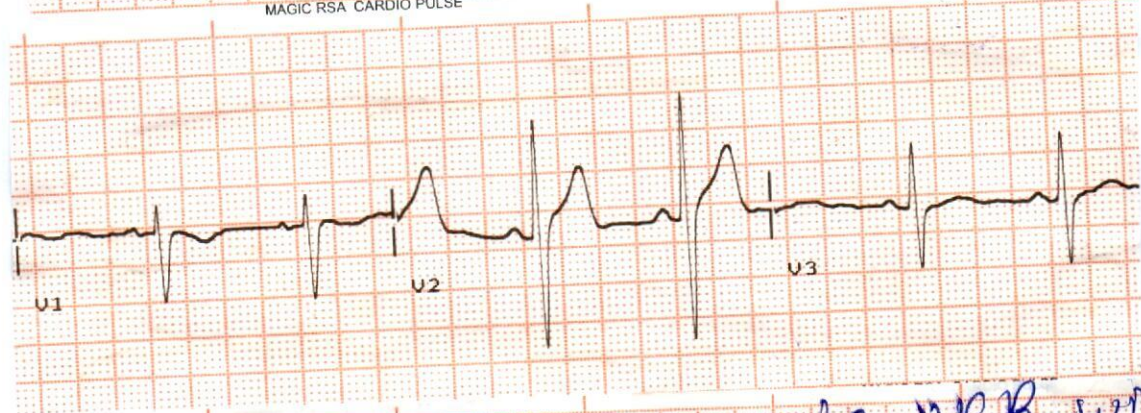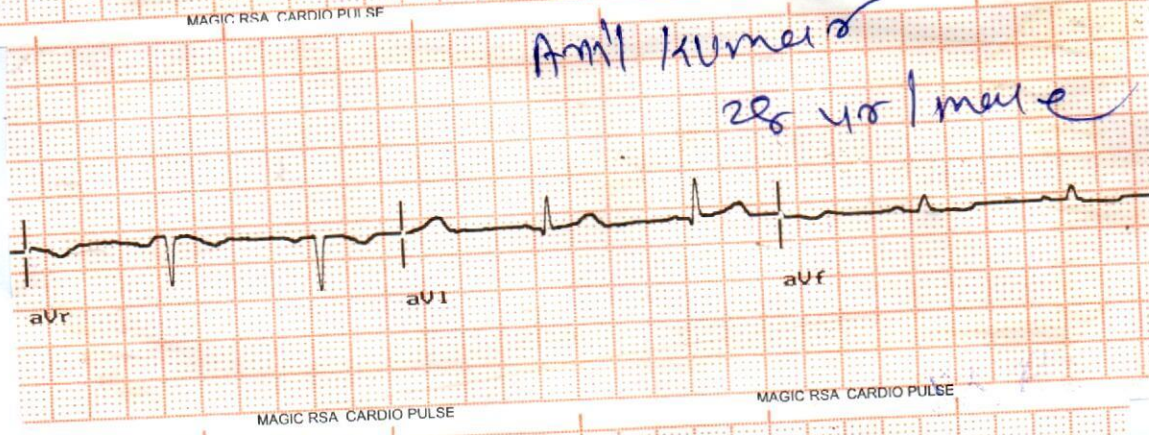
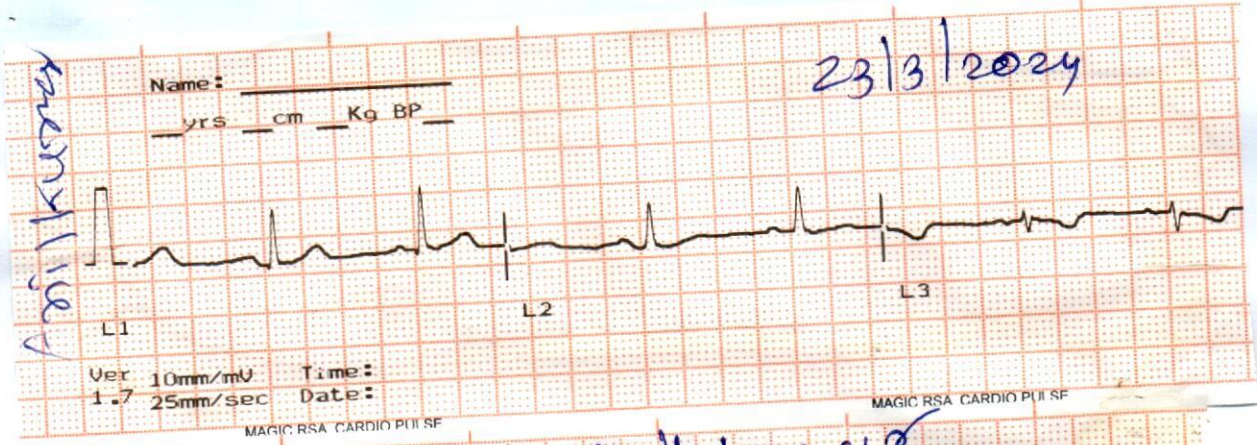
Multislice CT Scan | CBCT-Dental Scan | Live 3D-4D Sonography | Colour Doppler | Echo Cardiography | Interventional Radiology | Maxillofacial Radiology | Fetal Medicine
Digital X-Ray | Digital Mammography | Digital OPG / TMJ | ECG / TMT / PFT / EEG / EMG | Audiometry | Pathology Laboratory | Health Check Up Plans | Pre Employment Check Up

CT SCAN & CBCT FACILITY NOW AVAILABLE

Dr. Dinesh S. Modh

M.D., D.M.R.E. (Radiodiagnosis)
Consultant Radiologist & Sonologist
Ex. Junior Lecturer, B.J. Medical College, Civil Hospital, A'bad.

VIDHI[®] DIAGNOSTICS



Vidhi Diagnostics
L-86, Swatantra Senani Nagar,
Opp. Akhbarnagar Bus Terminal,
Nr. Akhbarnagar Circle,
New Wadaj, Ahmedabad-13.

Dr. Dinesh S. Modh
MBBS, D Cardia
Reg. No. : G-45946

ISO 9001:2015 Certified Diagnostics Center
Vidhi Imaging Center

L-86, Swatantra Senani Nagar, Opp. Indian Oil Petrol Pump, Akhbarnagar Circle, Nava Wadaj, Ahmedabad - 380 013.

Phone : (Radiology) 079-2762 1406 | M. 98799 29406, 98250 09406 | Time (Radiology) : Mon. to Sat. 9 am to 2 pm, 5 to 9 pm, Sunday 9 am to 12 Noon
E-mail : vidhidiagnostics@gmail.com, Website : www.vidhidiagnostics.com

Multislice CT Scan | CBCT-Dental Scan | Live 3D-4D Sonography | Colour Doppler | Echo Cardiography | Interventional Radiology | Maxillofacial Radiology | Fetal Medicine
Digital X-Ray | Digital Mammography | Digital OPG/TMJ | ECG/TMT/PFT/EEG/EMG | Audiometry | Pathology Laboratory | Health Check Up Plans | Pre Employment Check Up

CT SCAN & CBCT FACILITY NOW AVAILABLE

Dr. Dinesh S. Modh

M.D., D.M.R.E. (Radiodiagnosis)

Consultant Radiologist & Sonologist

Ex. Junior Lecturer, B.J. Medical College, Civil Hospital, A'bad.

VIDHI
DIAGNOSTICS



Patient's name : ANILKUMAR
Reg. ID : R-14861-23
Referred by : Dr. MEDIWHEEL

Age/Sex : 28 Years/Male
Accession : 24720
Date : 23/03/2024

X-RAY CHEST (PA VIEW)

Both lung fields appear normal.
No e/o consolidation or cavitations is seen.
Both costo-phrenic angles appear clear.
Cardiac size is with in normal limits.
Both domes of diaphragm appear normal.
Bony thoracic cage appears normal.

Thanks for reference.

Dr. Dinesh S. Modh
MD, DMRE (Radiodiagnosis)
DR DINESH S. MODH
M.D. DMRE (RADIO DIAGNOSIS)
G-23825

Vidhi Diagnostics

L-86, Swatantra Senani Nagar,
N. Akhbarnagar Bus Terminal
Nr. Akhbarnagar Circle,
New Wadaj, Ahmedabad-13.

ISO 9001:2015 Certified Diagnostics Center

Vidhi Imaging Center

L-86, Swatantra Senani Nagar, Opp. Indian Oil Petrol Pump, Akhbarnagar Circle, Nava Vadaj, Ahmedabad - 380 013.

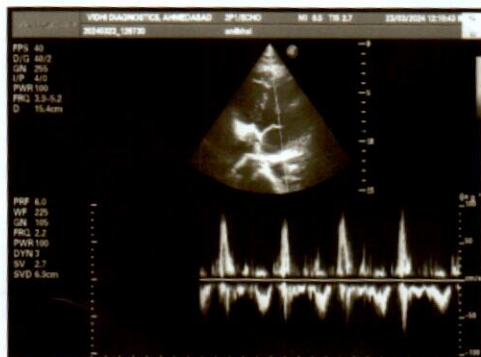
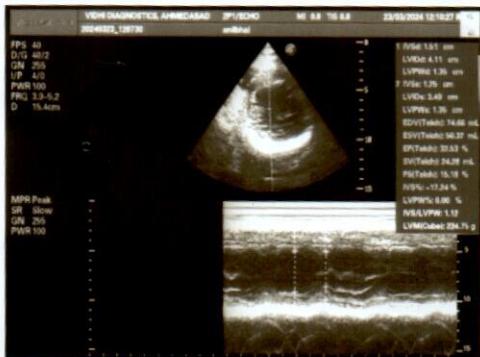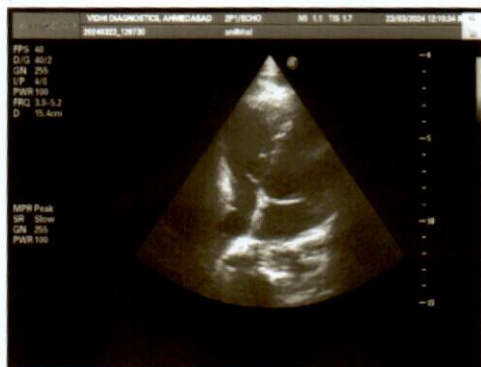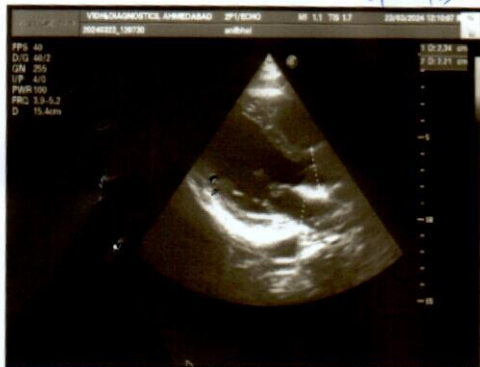Phone : (Radiology) 079-2762 1406 | M. 98799 29406, 98250 09406 | Time (Radiology) : Mon. to Sat. 9 am to 2 pm, 5 to 9 pm, Sunday 9 am to 12 Noon

E-mail : vidhidiagnostics@gmail.com, Website : www.vidhidiagnostics.com

Multislice CT Scan | CBCT-Dental Scan | Live 3D-4D Sonography | Colour Doppler | Echo Cardiography | Interventional Radiology | Maxillofacial Radiology | Fetal Medicine
Digital X-Ray | Digital Mammography | Digital OPG / TMJ | ECG / TMT / PFT / EEG / EMG | Audiometry | Pathology Laboratory | Health Check Up Plans | Pre Employment Check Up

CT SCAN & CBCT FACILITY NOW AVAILABLE

clm16ket 1



Dr. Dinesh S. Modh

M.D., D.M.R.E. (Radiodiagnosis)

Consultant Radiologist & Sonologist

Ex. Junior Lecturer, B.J. Medical College, Civil Hospital, A'bad.



Patient's name : ANILKUMAR
Reg. ID : R-14861-23
Referred by : Dr. MEDIWHEEL

Age/Sex : 28 Years/Male
Accession : 24720
Date : 23/03/2024

2D-ECHO REPORT

FINAL CONCLUSION:

LV IS NORMAL SIZE. GOOD LV SYSTOLIC FUNCTION NO RWMA.
LVEF - 60%. MILD CONCENTRIC LVH.
NORMAL LV COMPLIANCE.
LA IS NORMAL SIZE. NO LA CLOT.
RV IS NORMAL SIZE. GOOD RV SYSTOLIC FUNCTION.
RA IS NORMAL SIZE.
MITRAL VALVE IS NORMAL. NO MS. MILD MR (10%). NO MVP.
AORTIC VALVE IS NORMAL. NO AS. NO AR.
TRICUSPID VALVE IS NORMAL. NO TR. RVSP-20 mmHg. NO PAH.

NO CLOT, NO VEGETATION, NO PERICARDIAL EFFUSION.

DIMENSIONS:

AORTA	2.6 C.M
LEFT ATRIUM	2.7 C.M
LVDD	4.1 C.M.
IVSD	1.1 C.M
PWD	1.1 C.M
LVDS	2.6 C.M.

COLOUR DOPPLER FINDING:

STRUCTURE	VELOCITY m/sec
	Max
PULMONARY VALVE	0.7
MITRAL VALVE	E : 0.7 A: 0.4
AORTIC VALVE	1.0

Dr. Avinash Bhaskar
Cardio
Reg. No. : G-45946
DR AVINASH BHASKAR
CLINICAL CARDIOLOGIST
9924836431

Vidhi Diagnostics

L-86, Swatantra-Senani Nagar,
t. Akhbarnagar Bus Terminals
Nr. Akhbarnagar Circle,
New Wadaj, Ahmedabad-13.

ISO 9001:2015 Certified Diagnostics Center

Vidhi Imaging Center

L-86, Swatantra Senani Nagar, Opp. Indian Oil Petrol Pump, Akhbarnagar Circle, Nava Vadaj, Ahmedabad - 380 013.

Phone : (Radiology) 079-2762 1406 | M. 98799 29406, 98250 09406 | Time (Radiology) : Mon. to Sat. 9 am to 2 pm, 5 to 9 pm, Sunday 9 am to 12 Noon

E-mail : vidhidiagnostics@gmail.com, Website : www.vidhidiagnostics.com

Multislice CT Scan | CBCT-Dental Scan | Live 3D-4D Sonography | Colour Doppler | Echo Cardiography | Interventional Radiology | Maxillofacial Radiology | Fetal Medicine
Digital X-Ray | Digital Mammography | Digital OPG/TMJ | ECG/TMT/PFT/EEG/EMG | Audiometry | Pathology Laboratory | Health Check Up Plans | Pre Employment Check Up

CT SCAN & CBCT FACILITY NOW AVAILABLE