


S, a, L2

Name : Mr. K NEHRU Address : MYSORE Plan : ARCOFEMI MEDIWHEEL MALE AHC CREDIT PAN INDIA OP AGREEMENT	Age : 34 Y Sex : M	UHID :CMYS.0000060099  OP Number :CMYSOPV123551 Bill No :CMYS-OCR-22706 Date : 18.03.2024 08:55
---	---	---

Sno	Service Type/ServiceName	Department
1	ARCOFEMI - MEDIWHEEL - FULL BODY ANNUAL PLUS MALE - 2D ECHO - PAN INDIA - FY2324	
1	GAMMA GLUTAMYL TRANSFERASE (GGT)	
2	2D ECHO → R	
3	LIVER FUNCTION TEST (LFT)	
4	GLUCOSE, FASTING	
5	HEMOGRAM + PERIPHERAL SMEAR	
6	DIET CONSULTATION → P	
7	COMPLETE URINE EXAMINATION	
8	URINE GLUCOSE(POST PRANDIAL)	
9	PERIPHERAL SMEAR	
10	ECG	
11	RENAL PROFILE/RENAL FUNCTION TEST (RFT/KFT)	
12	DENTAL CONSULTATION	HA 170
13	GLUCOSE, POST PRANDIAL (PP), 2 HOURS (POST MEAL)	WT 77.8
14	URINE GLUCOSE(FASTING)	
15	HbA1c, GLYCATED HEMOGLOBIN	BP 130/80
16	X-RAY CHEST PA	
17	ENT CONSULTATION → P	
18	FITNESS BY GENERAL PHYSICIAN → P	
19	BLOOD GROUP ABO AND RH FACTOR	
20	LIPID PROFILE	
21	BODY MASS INDEX (BMI)	
22	OPHTHAL BY GENERAL PHYSICIAN	
23	ULTRASOUND - WHOLE ABDOMEN → P	
24	THYROID PROFILE (TOTAL T3, TOTAL T4, TSH)	

CERTIFICATE OF MEDICAL FITNESS

This is to certify that I have conducted the clinical examination

of C. Melina on 18/3/2024

After reviewing the medical history and on clinical examination it has been found that he/she is

	Tick
<ul style="list-style-type: none"> Medically Fit 	✓
<ul style="list-style-type: none"> Fit with restrictions/recommendations <p>Though following restrictions have been revealed, in my opinion, these are not impediments to the job.</p> <p>1.....</p> <p>2.....</p> <p>3.....</p> <p>However the employee should follow the advice/medication that has been communicated to him/her.</p> <p>Review after _____</p>	
<ul style="list-style-type: none"> Currently Unfit. Review after _____ recommended 	
<ul style="list-style-type: none"> Unfit 	

Dr. *Francis*
Medical Officer
The Apollo Clinic, Mysore.

Apollo Health and Lifestyle Limited's certificate is not meant for medico-legal purposes

REGD OFFICE: 110/NO.02, Ashoka Raghunath Chambers, 5th Floor, Begumpet, Hyderabad, Telangana - 500 016
 PH: No. 0421 4304 7777 | Fax No. 4304 7744 | Email ID: enquiry@apollohi.com | www.apollohi.com

APOLLO CLINICS NETWORK KARNATAKA
Bangalore: Saravahalli | Bellandur | Electronic City | Frasier Town | HSR Layout | Indira Nagar | JP Nagar | Kundalahalli |
Kuvempunagar: Saravahalli Road | **Mysore:** (VV Mohalla)
 Online appointments: www.apolloclinic.com

TO BOOK AN APPOINTMENT

1860 500 7788

Date : 18-03-2024
MR NO : CMYS.0000060099

Department : GENERAL
Doctor :

Name : Mr. K NEHRU
Age/ Gender : 34 Y / Male

Registration No :
Qualification :

Consultation Timing: 08:54

Height : 170	Weight : 77.8	BMI :	Waist Circum :
Temp :	Pulse :	Resp :	B.P : 130/80

General Examination /
Allergies History

Clinical Diagnosis & Management Plan

Came for regular health check
Blood test - normal
E conculsion
ECG - 100.
Urine test - normal
2D Echo - normal
ECC - normal
Hb - normal

Follow up date :

Doctor Signature
Apollo Clinic
23, 1st Floor,
Kalidasa Road, Mysore - 02
Ph : 0821-4006040/41

Date : 18-03-2024
MR NO : CMYS.0000060099

Department : GENERAL
Doctor :

Name : Mr. K NEHRU
Age/ Gender : 34 Y / Male

Registration No : H Praven Kumar R
Qualification : M.S. ENT

Consultation Timing: 08:54

Height : 170	Weight : 77.8	BMI :	Waist Circum :
Temp :	Pulse :	Resp :	B.P : 130/80

General Examination /
Allergies History

Clinical Diagnosis & Management Plan

Came for regular health check up

Ear - bilateral normal - @

nose - normal - @

oral cavity - normal - @

throat - @

to be normal



Follow up date :

Doctor Signature
Apollo Clinic
23, 1st Floor,
Kalidasa Road, Mysore - 02
Ph : 0821-4006040/41

Date : 18-03-2024
MR NO : CMYS.0000060099

Department : GENERAL Diabetics
Doctor : R. Acharya. B.P

Name : Mr. K NEHRU
Age/ Gender : 34 Y / Male

Registration No :
Qualification : M.Sc Nutrition & Dietetics
PhD

Consultation Timing: 08:54

IBW - 70kg

Height : 170	Weight : 77.8	BMI : 26.7 kg/m ²	Waist Circum :
Temp :	Pulse :	Resp :	B.P : 130/80

General Examination /
Allergies History

LDL - 106.93

Clinical Diagnosis & Management Plan

- ⇒ Advised low calorie diet with fiber rich foods.
- ⇒ Take small frequent meals, do not skip meals.
- ⇒ Include all variety of seasonal fruits, vegetables & green leafy vegetables.
- ⇒ Include nuts like Almonds, walnuts & dry-fruits like dried dates.
- ⇒ Include seeds like flaxseeds, hempin seeds, watermelon seeds, sunflower seeds & sesame seeds - 1-teaspoon each, dry roast.
- ⇒ Avoid maida, sugar, too much of salt, baking soda & creams.

Follow up date :

Doctor Signature
18/03/2024

- ⇒ Avoid Bakery products, chats, junk foods, deep fried foods, packed & processed foods

Date : 18-03-2024
MR NO : CMYS.0000060099

Department : GENERAL [opt-hol]
Doctor :

Name : Mr. K NEHRU
Age/ Gender : 34 Y / Male

Registration No :
Qualification :

Consultation Timing: 08:54

Height : 170	Weight : 77.8	BMI :	Waist Circum :
Temp : (N)	Pulse : 92/min	Resp : 20/min	B.P : 130/80

General Examination /
Allergies History

- NO -

Clinical Diagnosis & Management Plan

Not used to wear Spectacle.

No fresh complaints

H/O T.Y.D.M (HTN).

Not on any Treatment

vision.	(R)	(L)
Far	6/6	6/6
Near	N6	N6
Colour	(N)	(N)

Follow up date :

Doctor Signature

Apollo Clinic
23, 1st Floor,
Kalidasa Road, Mysore - 02
Ph : 0821-4006040/41

Date : 18-03-2024
MR NO : CMYS.0000060099

Department : GENERAL [Dental]
Doctor : Dr. Jyothishree

Name : Mr. K NEHRU

Registration No :

Age/ Gender : 34 Y / Male

Qualification :

Consultation Timing: 08:54

Height : 170	Weight : 77.8	BMI :	Waist Circum :
Temp :	Pulse :	Resp :	B.P : 130/80

General Examination /
Allergies History

Clinical Diagnosis & Management Plan

O/E

167 missing

Adv. Replacement

CA + +, SF + +

Adv. oral prophylaxis

OK with all Gen. spacing noted.

Adv. ortho intervention

Follow up date :


Doctor Signature

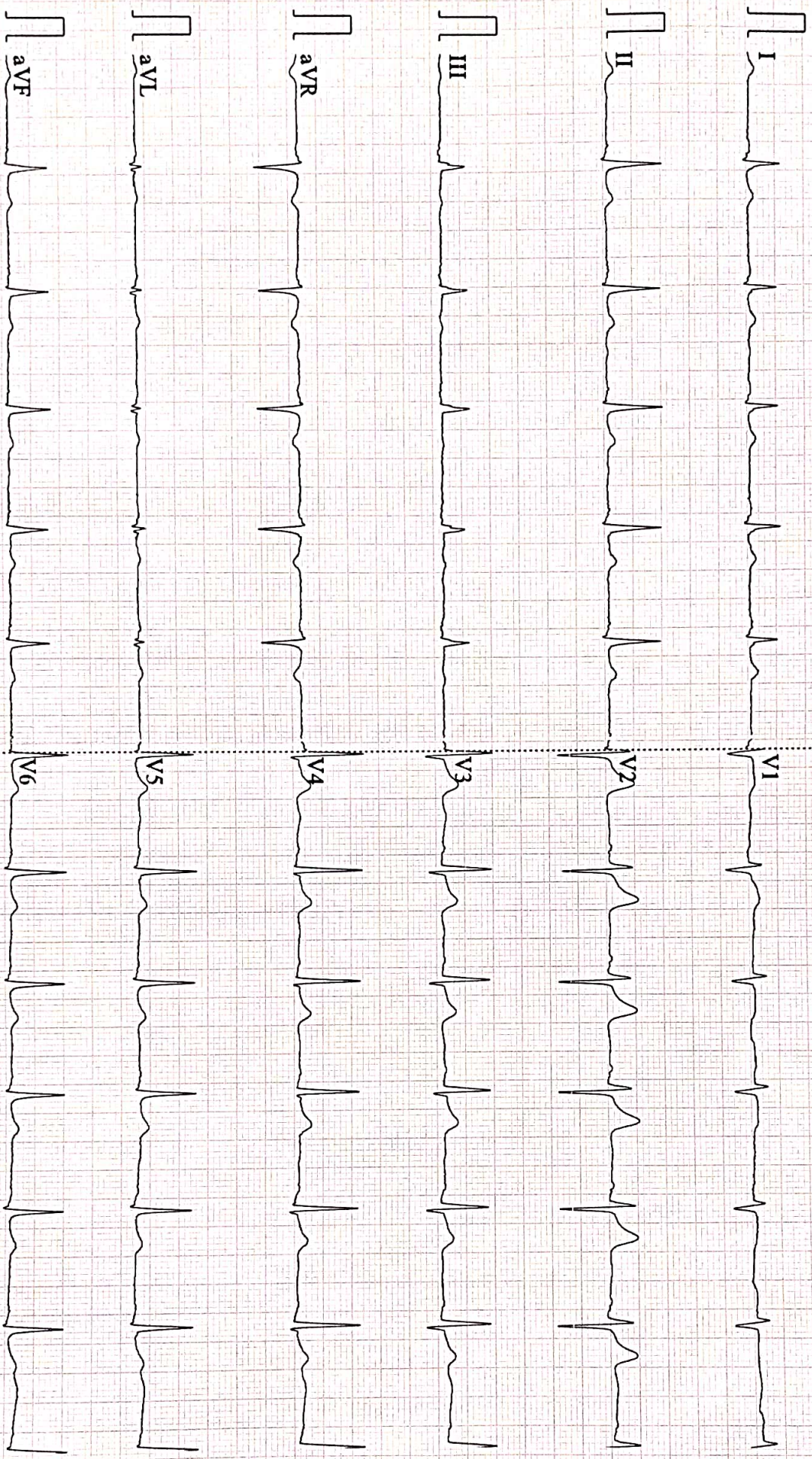
ID: 60099
MR K NEHRU
Male 34Years
170cm 77kg 130/80 mmHg

18-03-2024 09:29:50 AM

Diagnosis Information:

Unconfirmed Report.

Apollo Clinic
23, 1st Floor,
Kalidasa Road, Mysore - 02
Ph : 0821-4006040/41



0.5~45Hz AC50 25mm/s 10mm/mV 2*5.0s 72 CARDIART 8 D V1.43 Glasgow V28.6.0 APOLLO CLINIC MYSURU

Patient Name	: Mr. K NEHRU	Age	: 34 Y M
UHID	: CMYS.0000060099	OP Visit No	: CMYSOPV123551
Reported on	: 18-03-2024 16:36	Printed on	: 18-03-2024 16:37
Adm/Consult Doctor	:	Ref Doctor	: SELF

DEPARTMENT OF RADIOLOGY


X-RAY CHEST PA

Both lung fields and hila are normal .
No obvious active pleuro-parenchymal lesion seen .
Both costophrenic and cardiophrenic angles are clear .
Both diaphragms are normal in position and contour .
Thoracic wall and soft tissues appear normal.

IMPRESSION : NORMAL STUDY.

Printed on:18-03-2024 16:36

---End of the Report---


Dr. CHETAN HOLEPPAGOL
MBBS, DNB(RADIO DIAGNOSIS)
Radiology

Apollo Health and Lifestyle Limited

ICIN: U85110TG2000PLC115819
Regd Office: 110-62/62, Ashoka Raghupathi Chambers, 5th Floor, Begumpet, Hyderabad, Telangana - 500 016
Ph: No: (040) 4904 7777, Fax No: 4904 7744 | Email ID: enquiry@apollohl.com | www.apollohl.com

APOLLO CLINICS NETWORK KARNATAKA

Bangalore | Basavanagudi | Bellandur | Electronic City | Fraser Town | HSR Layout | Indira Nagar | JP Nagar | Kundalahalli |
Koramangala | Sarjapur Road | **Mysore** (VV Mohalla)

Online appointments: www.apolloclinic.com

TO BOOK AN APPOINTMENT

 **1860 500 7788**

Patient Name : Mr.K Nehru

Age & Sex: 34Yrs /Male

Date :18.03.2023

UHID No :600999

MORPHOLOGICAL DATA:

Left Atrium	Normal
Left Ventricle	Normal
Right Atrium	Normal
Right Ventricle	Normal
Interatrial septum	Intact
Interventricular septum	Intact
Aorta	Normal
Pulmonary artery	Normal
Mitral valve	Normal
Tricuspid valve	Normal
Aortic valve	Normal
Pulmonary valve	Normal
Pericardium	Normal

DIMENSIONS:

RVIDd	1.42cms
LVIDd	3.94cms
LVIDs	2.51cms
IVSd	0.83Cms
LVPWd	0.76Cms
AORTA	2.67cms
LA	3.32Cms
LVEF	65%

Apollo Health and Lifestyle Limited

(CIN : U65110TG2000PLC115819)

Regd. Office: 1-10-60-62, Ashoka Raghupathi Chambers, 5th Floor, Begumpet, Hyderabad, Telangana - 500 016

Ph. No: (040) 4904 7777 Fax No: 4904 7744 | E mail ID: enquiry@apollohl.com | www.apollohl.com

APOLLO CLINICS NETWORK KARNATAKA

Bangalore: Basavanagudi | Bellandur | Electronic City | Fraser Town | MSR Layout | Indra Nagar | JP Nagar | Kundalahalli | Koramangala | Sarjapur Road | Mysore (VV Mohalla)

Online appointments: www.apolloclinic.com

TO BOOK AN APPOINTMENT

 **1860 500 7788**

Patient Name : Mr.K Nehru

Age & Sex: 34Yrs /Male

Date :18.03.2023

UHID No :600999

DOPPLER DATA:

VALVES	Velocity (Cm/s)	Peak Gradient (mmHg)	Mean Gradient (mmHg)	Regurgitation
Mitral	E :0.57 A :0.40 E/A :1.44 E/e' :5.47	0.96		NIL
Tricuspid	E:0.56 A:0.40			TRIVIAL JET Grdt 13mmHg
Aortic	1.10	4.90		NIL
Pulmonary	0.95	3.58		NIL

IMPRESSION:

NORMAL VALVES AND CHAMBERS

NO RWMA

NORMAL LV FUNCTION

NO e/o CLOT/ VEGETATION/ PE

Dr GOWTHAM H.G

MD, DM CARDIOLOGY

Apollo Health and Lifestyle Limited

(CIN: U85110TG0000PLC115819)

Regd Office: 11D/60/62, Ashoka Raghupathi Chambers, 5th Floor, Begumpet, Hyderabad, Telangana - 500 016

Ph No: (040) 4904 7777 Fax No: 4904 7744 | Email ID: enquiry@apollohl.com | www.apollohl.com

APOLLO CLINICS NETWORK KARNATAKA

Bangalore: Basavanagudi | Bellandur | Electronic City | Fraser Town | HSR Layout | Indira Nagar | JP Nagar | Kundalahalli |

Koramangala | Sarjapur Road | Mysore (VV Mohalla)

Online appointments: www.apolloclinic.com

TO BOOK AN APPOINTMENT

1860 500 7788

Patient Name: Mr. K Nehru	Date: 18.03.2024	Referring Doctor: Self
Age / Sex :34yrs /Male	UHID :60099	
ULTRASONOGRAPHY – ABDOMEN & PELVIS		

LIVER: It is normal in size, outline and echotexture. No focal lesions seen. IHBR are not dilated. CBD and Portal vein are normal.

GALL BLADDER: It is distended and normal. No evidence of calculi.

SPLEEN: It is normal in size, outline and echopattern. No e/o focal lesions.

PANCREAS: It is normal in size, outline and echopattern.

RIGHT KIDNEY: It measures 10.5x5.2cm with parenchymal thickness of 1.6 cm. It is normal in size, outline and echotexture. No e/o calculus or hydronephrosis seen.

LEFT KIDNEY: It measures 10.0x5.1 cm with parenchymal thickness of 1.4 cm. It is normal in size, outline and echotexture. No e/o calculus or hydronephrosis seen.

URINARY BLADDER: It is well distended. The UB wall is normal. No e/o calculi.

PROSTATE: It is normal in size, outline and echotexture.

No e/o free fluid in the abdomen.

IMPRESSION: NORMAL STUDY.



Dr. Chetan H, DNB
Consultant Radiologist.

Apollo Health and Lifestyle Limited

(CIN: U85110TG2000PLC115819)

Regd. Office: 1-10-60-62, Ashoka Raghupathi Chambers, 5th Floor, Begumpet, Hyderabad, Telangana - 500 016

Ph No: 040 4904 7777 | Fax No: 4904 7744 | Email ID: enquiry@apollohi.com | www.apollohi.com

APOLLO CLINICS NETWORK KARNATAKA

Bangalore | Basavanagudi | Bellandur | Electronic City | Fraser Town | HSR Layout | Indira Nagar | JP Nagar | Kundalahalli | Koramangala | Sarjapur Road | Mysore (VV Mohalla)

Online appointments: www.apolloclinic.com

TO BOOK AN APPOINTMENT

1860 500 7788