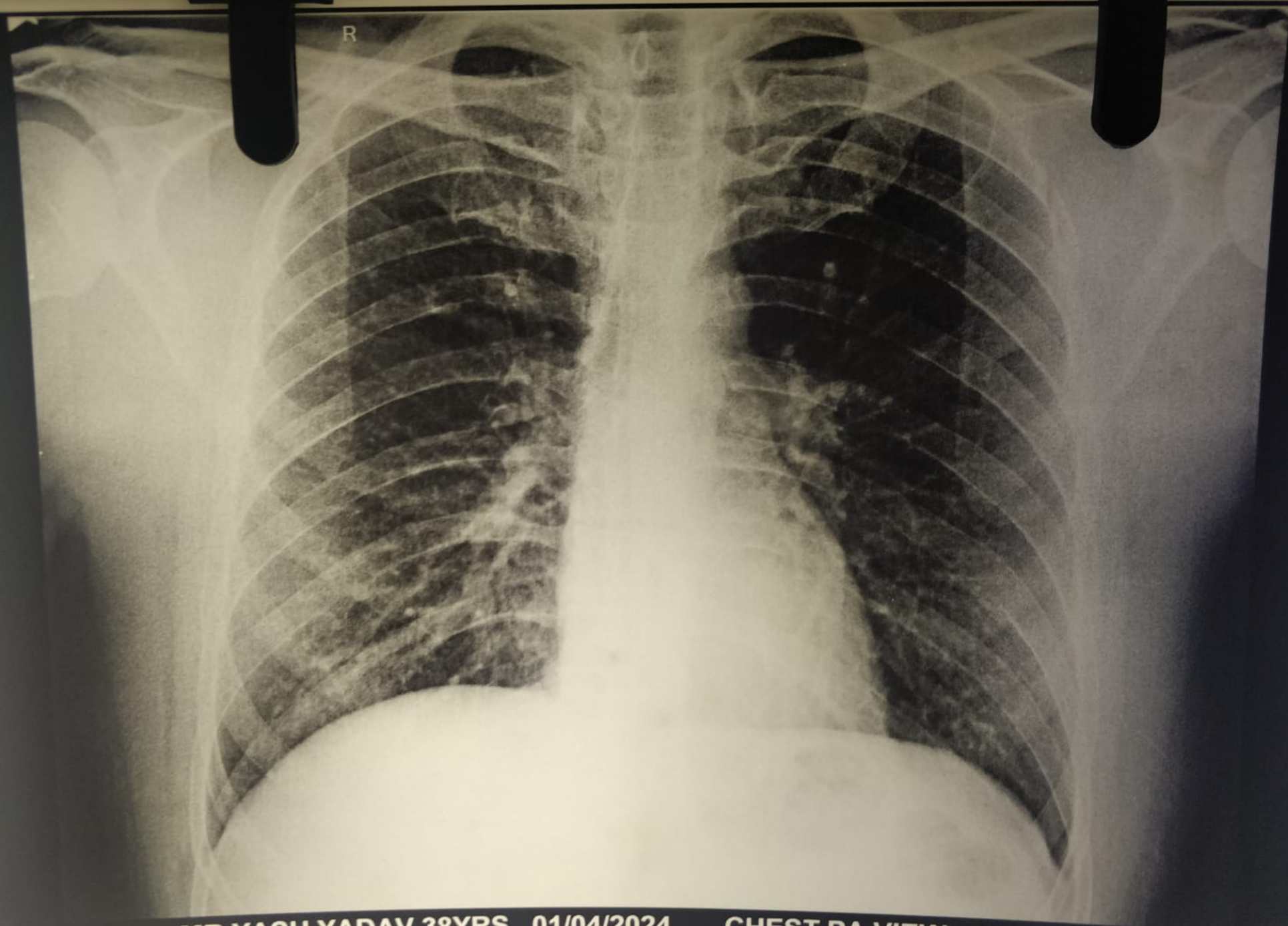



MR YASH YADAV 38YRS 01/04/2024 CHEST PA VIEW 4/1/2024
ONEPLUS ULTRASOUND LAB, 47-HARSH VIHAR, PITAMPURA


Transport Department-National Capital Territory of Delhi
Licence to drive vehicles throughout India

	LICENCE NO.	: P04082005445658	
	NAME	: YASH YADAV	
	Son of	: SH H P YADAV	
	ADDRESS	: WZ 259 MADI PUR VILL NEW DELHI 110063	
	DT. OF BIRTH	: 04/03/1986	
VEHICLE CLASS :		MCYL	26/08/2005
		LMV(NT)	26/08/2005
<i>Yash Yadav</i> (Holder's Signature)			
DT. OF ISSUE :		26/08/2005	
VALIDITY :		25/08/2025	
INV CARR NO. :		NA	
		<i>h.p.</i> Sig. Of Licencing Authority (WZ)	

Yash Yadav

h.p.
DR. NITIN AGARWAL
 MRBS, MD
 Regn. No. DMC-R-1436

ONE-PLUS ULTRASOUND LAB
 47 Harsh Vihar Pitam Pura,
 Delhi-110034
 Ph. 011-42480101, 9599913051
 E-mail: oneplusul@gmail.com



Handwritten signature in blue ink.

DI NITIN AGARWAL
MBBS, MD
Regn. No. DMCR-1436

ONEPLUS ULTRASOUND LAB
47 Harsh Vihar, Pitam Pura,
Delhi-110034
Ph. 011-42480101, 9599913051
E-mail oneplusul@gmail.com



NAME	:Mr. YASH YADAV	Barcode No	:10168494
AGE/GENDER	:38 YRS/Male	SPECIMEN DATE	:01/Apr/2024 09:24AM
PATIENT ID	:133074	SPECIMEN RECEIVED	:01/Apr/2024 09:38AM
REFERRED BY	:Dr. MEDIWHEEL	REPORT DATE	:01/Apr/2024 06:24PM
CENTRE NAME	:ONEPLUS ULTRASOUND LAB	LAB NO.	:012404010011

Test Name	Result	Unit	Ref. Range
-----------	--------	------	------------

HAEMATOLOGY

MediWheel Health checkup < 40 Female

Sample Type:EDTA Blood

Glycosylated Hemoglobin (HbA1c) HPLC	5.7	%	Non Diabetic adults <5.7 Prediabetic (at risk) 5.7-6.4 Diabetes >6.4
--	-----	---	--

Estimated average blood glucose (eag) CALCULATED	117		
--	-----	--	--

Reference range (mg/dl):

90 - 120:Excellent control, 121 - 150:Good Control, 151 - 180:Average Control, 181 - 210:Action Suggested
>211:Panic value

Checked By.

Dr. NITIN AGARWAL

MBBS, MD

Regn. No. DMC-R-1436

DR. NITIN AGARWAL
MBBS,MD(PATHOLOGIST)

47, Harsh Vihar, Pitampura, Delhi-34 ☎ 011-4248 0101, 9599913051

✉ Email: oneplusul@gmail.com 🌐 www.oneplusul.in

Page 1 of 8

- Clinical correlation is essential for final diagnosis. • If test results are unsatisfactory please contact personally or on phone.
- This report is for perusal of doctors only. • All disputes are subject to Delhi jurisdiction only. • Not for medico legal case.
- All congenital anomalies in a foetus may not be diagnosed in routine obstetric ultrasound.



OnePLUS
Ultrasound Lab
— QUALITY FIRST... ALWAYS! —

Dr. Nitin Agarwal

Pathologist & Director
MBBS, MD, FAGE
Ex. Chief of Lab
Dr. Lal Path labs.

Dr. Pooja (Garg) Agarwal

Radiologist & Director
MBBS (MAMC) DMRD (MAMC)
Imaging Expert In Fetal And Maternal Medicine,
University of Barcelona, Spain
Fetal Medicine Foundation (UK) Accreditation



ITDOSE INFOSYSTEMS PVT. LTD.

NAME	:Mr. YASH YADAV	Barcode No	:10168494
AGE/GENDER	:38 YRS/Male	SPECIMEN DATE	:01/Apr/2024 09:24AM
PATIENT ID	:133074	SPECIMEN RECEIVED	:01/Apr/2024 09:38AM
REFERRED BY	:Dr. MEDIWHEEL	REPORT DATE	:01/Apr/2024 06:24PM
CENTRE NAME	:ONEPLUS ULTRASOUND LAB	LAB NO.	:012404010011

Test Name	Result	Unit	Ref. Range
-----------	--------	------	------------

HAEMATOLOGY

BLOOD GROUP (ABO)

Forward and Reverse grouping (Slide & Tube)

B

Rh typing

POSITIVE

NOTE :

- * Apart from major A,B,H antigens which are used for ABO grouping and Rh typing, many minor blood group antigens exist. Agglutination may also vary according to titre of antigen and antibody.
- * So before transfusion, reconfirmation of blood group as well as cross-matching is needed.
- * Presence of maternal antibodies in newborns, may interfere with blood grouping.
- * Auto agglutination (due to cold antibody, falciparum malaria, sepsis, internal malignancy etc.) may also cause erroneous result.

Checked By.

Dr. NITIN AGARWAL

MBBS, MD

Regn. No. DMC-R-1436

DR. NITIN AGARWAL
MBBS,MD(PATHOLOGIST)

47, Harsh Vihar, Pitampura, Delhi-34 ☎ 011-4248 0101, 9599913051

✉ Email: oneplusul@gmail.com 🌐 www.oneplusul.in

Page 2 of 8

- Clinical correlation is essential for final diagnosis. • If test results are unsatisfactory please contact personally or on phone.
- This report is for perusal of doctors only. • All disputes are subject to Delhi jurisdiction only. • Not for medico legal case.
- All congenital anomalies in a foetus may not be diagnosed in routine obstetric ultrasound.



NAME	:Mr. YASH YADAV	Barcode No	:10168494
AGE/GENDER	:38 YRS/Male	SPECIMEN DATE	:01/Apr/2024 09:24AM
PATIENT ID	:133074	SPECIMEN RECEIVED	:01/Apr/2024 09:38AM
REFERRED BY	:Dr. MEDIWHEEL	REPORT DATE	:01/Apr/2024 06:24PM
CENTRE NAME	:ONEPLUS ULTRASOUND LAB	LAB NO.	:012404010011

Test Name	Result	Unit	Ref. Range
-----------	--------	------	------------

HAEMATOLOGY

CBC

Haemoglobin Non cyanide Hb analysis	13.9	g/dl	13.0-17.0
Total Leucocyte Count Electrical Impedance	6700	/cumm	4000-10000
Differential leucocyte count			
Neutrophils Electrical Impedance & Microscopic	54.5	%	40-80
Lymphocyte Electrical Impedance & Microscopic	39.60	%	20-40
Monocytes Electrical Impedance & Microscopic	3.00	%	2-10
Eosinophils Electrical Impedance & Microscopic	2.0	%	1-6
Basophils Electrical Impedance & Microscopic	0.9	%	0-2
RBC Count Electrical Impedance	4.50	million/cumm	4.5 - 5.5
Hematocrit(PCV) Flow Cytometry	42.3	%	40-50
MCV Calculated	94.6	fl	83-101
MCH Calculated	31.1	pg	27-32
MCHC Calculated	32.9	g/dL	31.5-34.5
RDW-CV Calculated	13.7	%	11.4-14.0
Platelet count Electrical Impedance	178000	/cumm	150000-410000


BIOCHEMISTRY

Sample Type:Fluoride F

Blood sugar fasting
GOD-POD

103 mg/dl

Dr. NITIN AGARWAL
MBBS, MD
Regn. No. DMC-R-1436


DR. NITIN AGARWAL
MBBS,MD(PATHOLOGIST)

Checked By.

47, Harsh Vihar, Pitampura, Delhi-34 ☎ 011-4248 0101, 9599913051

✉ Email: oneplusul@gmail.com 🌐 www.oneplusul.in

Page 3 of 8

- Clinical correlation is essential for final diagnosis. • If test results are unsatisfactory please contact personally or on phone.
- This report is for perusal of doctors only. • All disputes are subject to Delhi jurisdiction only. • Not for medico legal case.
- All congenital anomalies in a foetus may not be diagnosed in routine obstetric ultrasound.



NAME	:Mr. YASH YADAV	Barcode No	:10168494
AGE/GENDER	:38 YRS/Male	SPECIMEN DATE	:01/Apr/2024 09:24AM
PATIENT ID	:133074	SPECIMEN RECEIVED	:01/Apr/2024 09:38AM
REFERRED BY	:Dr. MEDIWHEEL	REPORT DATE	:01/Apr/2024 06:24PM
CENTRE NAME	:ONEPLUS ULTRASOUND LAB	LAB NO.	:012404010011

Test Name	Result	Unit	Ref. Range
-----------	--------	------	------------

Sample Type:Fluoride PP

Blood sugar pp GOD-POD	118	mg/dL	70.0-140.0
----------------------------------	-----	-------	------------

Sample Type:Serum

Bun (blood urea nitrogen) Calculated	12.60	mg/dl	8.9-21.6
--	-------	-------	----------

Uric Acid, serum Uricase- PAP	4.3	mg/dl	3.5-7.2
---	-----	-------	---------

Creatinine, serum Enzymatic	1	mg/dl	0.71-1.16
---------------------------------------	---	-------	-----------

LFT(LIVER FUNCTION TEST)

Bilirubin Total Modified tab	0.52	mg/dl	0.2-1.1
Bilirubin Conjugated Diazotied sulfanilic acid	0.23	mg/dL	0.11-0.42
Bilirubin Unconjugated Calculated	0.29	mg/dl	up to 0.7
SGOT (AST) Tris buffer	27	U/L	0-46
SGPT (ALT) Tris buffer	61	U/L	0-49
Alkaline phosphatase Amp buffer	94	U/L	40-129
GAMMA GT Szasz Method	27	U/L	10-45
Total Protein Biuret	6.8	gm/dl	6.60 - 8.70
Albumin serum BCG	3.9	g/dL	3.0-5.2
Globulin Calculated	2.90	gm/dl	1.8-3.4
Albumin/Globulin Ratio Calculated	1.34		1.10 - 2.50

LIPID PROFILE

Cholesterol CHOD-PAP	172	mg/dl	50-200
-------------------------	-----	-------	--------

Checked By.

Dr. NITIN AGARWAL
MBBS, MD
Regn. No. DMC-R-1436
DR. NITIN AGARWAL
MBBS,MD(PATHOLOGIST)

47, Harsh Vihar, Pitampura, Delhi-34 ☎ 011-4248 0101, 9599913051

✉ Email: oneplusul@gmail.com 🌐 www.oneplusul.in

Page 4 of 8

- Clinical correlation is essential for final diagnosis. • If test results are unsatisfactory please contact personally or on phone.
- This report is for perusal of doctors only. • All disputes are subject to Delhi jurisdiction only. • Not for medico legal case.
- All congenital anomalies in a foetus may not be diagnosed in routine obstetric ultrasound.



NAME	:Mr. YASH YADAV	Barcode No	:10168494
AGE/GENDER	:38 YRS/Male	SPECIMEN DATE	:01/Apr/2024 09:24AM
PATIENT ID	:133074	SPECIMEN RECEIVED	:01/Apr/2024 09:38AM
REFERRED BY	:Dr. MEDIWHEEL	REPORT DATE	:01/Apr/2024 06:24PM
CENTRE NAME	:ONEPLUS ULTRASOUND LAB	LAB NO.	:012404010011


Test Name	Result	Unit	Ref. Range
Triglycerides GPO-PAP	121	mg/dL	25-150
HDL Cholesterol Selective Inhibition	45	mg/dL	40 - 60
LDL cholesterol Calculated	103	mg/dL	<100
VLDL cholesterol Calculated	24.2	mg/dL	5-40
Cholesterol/HDL Ratio Calculated	3.8		Low Risk 3.3-4.97 Average Risk 4.4-7.1 Moderate Risk 7.1-11.0 High Risk >11.0
LDL/HDL Ratio Calculated	2.3		0 - 3.55

LDL Cholesterol	Total Cholesterol	HDL Cholesterol
<100 Optimal	<200 Desirable	<40 Low
100-129 Near optimal	200-239 Borderline high	>60 High
130-159 Borderline high	>240 High	
160-189 High		
>190 Very high		

According to NCEP, ATP-III Guidelines

BUN/Creatinine ratio

UREA UREASE-GLDH	27.00	mg/dl	15-45
Bun (blood urea nitrogen) Calculated	12.62	mg/dl	8.9-21.6
CREATININE ENZYMATIC	1.00	mg/dl	0.30-1.10
Bun/Creatinine Ratio Calculated	12.62		10.0 - 20.0

Dr. NITIN AGARWAL
MBBS, MD
Regn. No. DMC-R-1436

DR. NITIN AGARWAL
MBBS,MD(PATHOLOGIST)

Checked By.

47, Harsh Vihar, Pitampura, Delhi-34 ☎ 011-4248 0101, 9599913051

✉ Email: oneplusul@gmail.com 🌐 www.oneplusul.in

Page 5 of 8

- Clinical correlation is essential for final diagnosis. • If test results are unsatisfactory please contact personally or on phone.
- This report is for perusal of doctors only. • All disputes are subject to Delhi jurisdiction only. • Not for medico legal case.
- All congenital anomalies in a foetus may not be diagnosed in routine obstetric ultrasound.



OnePLUS
Ultrasound Lab
— QUALITY FIRST... ALWAYS! —

Dr. Nitin Agarwal

Pathologist & Director
MBBS, MD, FAGE
Ex. Chief of Lab
Dr. Lal Path labs.

Dr. Pooja (Garg) Agarwal

Radiologist & Director
MBBS (MAMC) DMRD (MAMC)
Imaging Expert In Fetal And Maternal Medicine,
University of Barcelona, Spain
Fetal Medicine Foundation (UK) Accreditation



NAME	:Mr. YASH YADAV	Barcode No	:10168494
AGE/GENDER	:38 YRS/Male	SPECIMEN DATE	:01/Apr/2024 09:24AM
PATIENT ID	:133074	SPECIMEN RECEIVED	:01/Apr/2024 09:38AM
REFERRED BY	:Dr. MEDIWHEEL	REPORT DATE	:01/Apr/2024 06:24PM
CENTRE NAME	:ONEPLUS ULTRASOUND LAB	LAB NO.	:012404010011

Test Name	Result	Unit	Ref. Range
-----------	--------	------	------------

ENDOCRINOLOGY

THYROID PROFILE(T3,T4,TSH)

Triiodothyronine total [t3] ECLIA	0.95	ng/dl	0.52-1.9
Thyroxine total [t4] ECLIA	7.80	µg/dl	4.4 - 10.8
TSH (Thyroid Stimulating Hormone) Enzyme linked fluorescent assay	2.40	µIU/ml	0.25-5.0

AGE WISE VARIATION IN TSH

AGE	TSH(µIU/ml)	AGE	TSH(µIU/ml)
1-4 weeks	1.00 - 19.0	16-20 yrs	0.25 - 5.0
1-12 mths	1.70 - 9.1	21 - 80 yrs	0.25 - 5.0
1-5 yrs	0.80 - 8.2	I st trimester	0.25 - 5.0
6-10 yrs	0.25 - 5.0	II nd trimester	0.50 - 5.0
11-15 yrs	0.25 - 5.0	II rd trimester	0.4 - 6.0

Reference ranges - Interpretation of Diagnostic tests - (Jacques Wallach)

1. Primary hypothyroidism is accompanied by depressed serum T3 and T4 values and elevated serum TSH level.
2. Primary hyperthyroidism is accompanied by elevated serum T3 and T4 levels along with depressed TSH values.
3. Slightly elevated T3 levels may be found in pregnancy and estrogen therapy, while depressed levels may be encountered in severe illness, renal failure and during therapy with drugs like propranolol and propyl thiouracil.
4. Although elevated TSH levels are nearly always indicative of primary hypothyroidism, and may be seen in secondary thyrotoxicosis

Checked By.

Dr. NITIN AGARWAL
MBBS, MD
Regn. No. DMC-11436
DR. NITIN AGARWAL
MBBS,MD(PATHOLOGIST)

47, Harsh Vihar, Pitampura, Delhi-34 ☎ 011-4248 0101, 9599913051

✉ Email: oneplusul@gmail.com 🌐 www.oneplusul.in

Page 6 of 8

- Clinical correlation is essential for final diagnosis. • If test results are unsatisfactory please contact personally or on phone.
- This report is for perusal of doctors only. • All disputes are subject to Delhi jurisdiction only. • Not for medico legal case.
- All congenital anomalies in a foetus may not be diagnosed in routine obstetric ultrasound.



NAME	:Mr. YASH YADAV	Barcode No	:10168494
AGE/GENDER	:38 YRS/Male	SPECIMEN DATE	:01/Apr/2024 09:24AM
PATIENT ID	:133074	SPECIMEN RECEIVED	:01/Apr/2024 06:07PM
REFERRED BY	:Dr. MEDIWHEEL	REPORT DATE	:01/Apr/2024 06:24PM
CENTRE NAME	:ONEPLUS ULTRASOUND LAB	LAB NO.	:012404010011

Test Name	Result	Unit	Ref. Range
-----------	--------	------	------------

CLINICAL PATHOLOGY

URINE ROUTINE (Strip/microscopy)

Sample Type:Urine

Physical examination

Colour	PALE YELLOW	PALE YELLOW
Transparency	CLEAR	CLEAR
Sp.gravity	1.015	1.005-1.030
BROMOTHYMOL BLUE		
pH	6.00	5.0-8.0
Double Indicators Test		
Reaction	ACIDIC	ACIDIC

Chemical examination

Urine protein	NIL	NIL
Protein Ionization		
Urine sugar	NIL	NIL
Oxidation Reaction		
Bilirubin, urine	NEGATIVE	NEGATIVE
Urobilinogen	NORMAL	NORMAL
P-Aminobenzoic Acid and Phenazopyridine Reaction		
Ketones	NEGATIVE	NEGATIVE
Acetoacetate and Dicholorobenzene Reaction		

Microscopic examination

Pus cells.	2-3	/HPF	0-2
Microscopy			
Epithelial cells	1-2	/HPF	NIL
Microscopy			
R.B.C.	NIL	/HPF	NIL
Microscopy			
Casts	NIL	/HPF	NIL
Microscopy			
Crystals	NIL	/HPF	NIL
Microscopy			
Bacteria	NIL	/HPF	NIL
Microscopy			

DR. NITIN AGARWAL
MBBS, MD
Regn. No. DMC-R-1436
[Signature]
DR. NITIN AGARWAL
MBBS,MD(PATHOLOGIST)

Checked By.

47, Harsh Vihar, Pitampura, Delhi-34 ☎ 011-4248 0101, 9599913051

✉ Email: oneplusul@gmail.com 🌐 www.oneplusul.in

Page 7 of 8

- Clinical correlation is essential for final diagnosis. • If test results are unsatisfactory please contact personally or on phone.
- This report is for perusal of doctors only. • All disputes are subject to Delhi jurisdiction only. • Not for medico legal case.
- All congenital anomalies in a foetus may not be diagnosed in routine obstetric ultrasound.



NAME	:Mr. YASH YADAV	Barcode No	:10168494
AGE/GENDER	:38 YRS/Male	SPECIMEN DATE	:01/Apr/2024 09:24AM
PATIENT ID	:133074	SPECIMEN RECEIVED	:01/Apr/2024 06:07PM
REFERRED BY	:Dr. MEDIWHEEL	REPORT DATE	:01/Apr/2024 06:24PM
CENTRE NAME	:ONEPLUS ULTRASOUND LAB	LAB NO.	:012404010011

Test Name	Result	Unit	Ref. Range
Others.	NIL	NIL	NIL

STOOL ROUTINE(MANUAL METHOD/MICROSCOPY)

Sample Type:Stool

Physical examination

Colour	BROWNISH		
Consistency	SEMI LOOSE		Semi Formed
Blood	ABSENT		Absent
Mucus	ABSENT		Absent


Chemical examination, stool

pH	6.00		5.0-8.0
Double Indicators Test			

Microscopic examination

Pus cells	0-1	/HPF	
Microscopy			
R.B.C.	NIL	/HPF	NIL
Microscopy			
Ova	NIL		NIL
Microscopy			
Cysts	NIL		NIL
Microscopy			
Bacteria	NIL	/HPF	NIL
Microscopy			
Others	NIL		

*** End Of Report ***

Dr. NITIN AGARWAL
MBBS, MD
Regn. No. DMC-R-1436

DR. NITIN AGARWAL
MBBS,MD(PATHOLOGIST)

Checked By.

47, Harsh Vihar, Pitampura, Delhi-34 ☎ 011-4248 0101, 9599913051

✉ Email: oneplusul@gmail.com 🌐 www.oneplusul.in

Page 8 of 8

- Clinical correlation is essential for final diagnosis. • If test results are unsatisfactory please contact personally or on phone.
- This report is for perusal of doctors only. • All disputes are subject to Delhi jurisdiction only. • Not for medico legal case.
- All congenital anomalies in a foetus may not be diagnosed in routine obstetric ultrasound.

Name	: Mr. YASH YADAV	Age/Sex	: 38 YRS/Male
Ref. By	: Dr. MEDIWHEEL	Lab No	: 012404010011
Date	: 01-Apr-2024	Patient ID	: LSHHI133074

X-ray-Chest PA view

Bony cage and soft tissues are normal.

Cardiothoracic ratio is normal.

Mediastinum is normal.

Both hila are normal.

Both costophrenic angles are clear.

Both domes of diaphragm are normal.

Lung fields are clear. No parenchymal lesion seen.

IMPRESSION: Normal Study.

Dr. POOJA GARG
M.B.B.S., D.M.R.D.
Reg No DMC/R/03398
Radiologist
DR. POOJA GARG
RADIOLOGIST
REG NO- DMC/R/03398

Type By : anubha

47, Harsh Vihar, Pitampura, Delhi-34 ☎ 011-4248 0101, 9599913051

✉ Email: oneplusul@gmail.com 🌐 www.oneplusul.in

- Clinical correlation is essential for final diagnosis. • If test results are unsatisfactory please contact personally or on phone.
- This report is for perusal of doctors only. • All disputes are subject to Delhi jurisdiction only. • Not for medico legal case.
- All congenital anomalies in a foetus may not be diagnosed in routine obstetric ultrasound.

Name	: Mr. YASH YADAV	Age/Sex	: 38 YRS/Male
Ref. By	: Dr. MEDIWHEEL	Lab No	: 012404010011
Date	: 01-Apr-2024	Patient ID	: LSHHI133074

ULTRASOUND EXAMINATION----WHOLE ABDOMEN

Liver is normal in size (15 cm) and outline with normal echopattern. No abscess or mass lesion seen. Hepatic veins, portal vein, IVC and aorta are normal. Intrahepatic biliary radicles are not dilated. CBD is normal in caliber.

Gall bladder is well distended with anechoic lumen. Wall thickness is normal.

Both kidneys are normal in size, shape, position, outline and echopattern. Corticomedullary differentiation is maintained. No pelvicalyceal dilation or calculus or mass lesion is seen.

Spleen is normal in size and echotexture. No mass lesion seen.

Pancreas is normal in size, outline and echotexture.

Urinary bladder is normal in shape and position. No evidence of intravesical stone or mass seen.

Prostate is normal in size, shape and echopattern.

Prostate measures 4.6 x 3.3 x 3.2 cm. **Weight of prostate is 25 grams.**

No abnormal bowel wall thickening seen in right iliac fossa.

No free fluid seen anywhere in abdomen.

IMPRESSION: Normal Study.




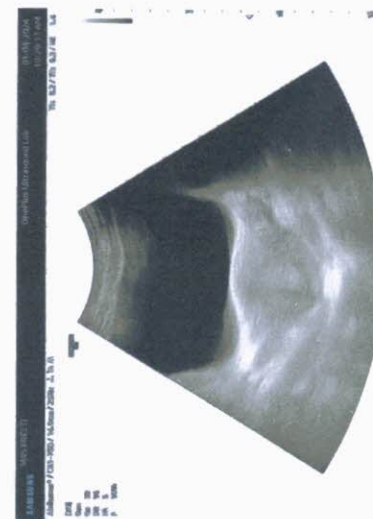

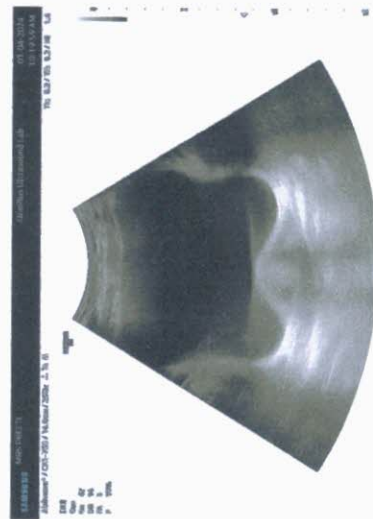
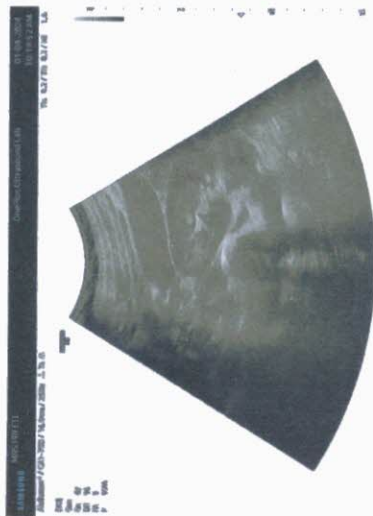

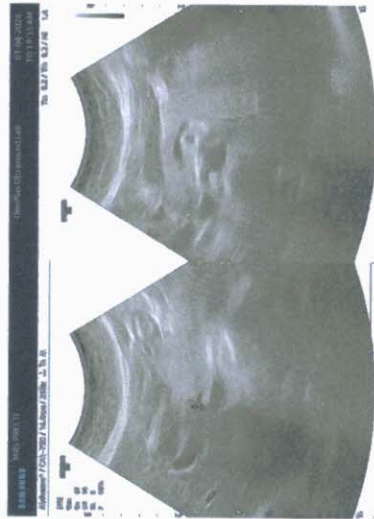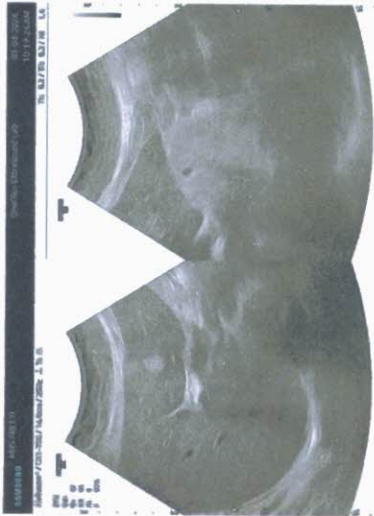
Dr. POOJA GARG
M.B.B.S., D.M.R.D.
Reg No DMC/R/03398
DR. POOJA GARG
RADIOLOGIST
REG NO- DMC/R/03398

Type By : anubha

47, Harsh Vihar, Pitampura, Delhi-34 ☎ 011-4248 0101, 9599913051

✉ Email: oneplusul@gmail.com 🌐 www.oneplusul.in

- Clinical correlation is essential for final diagnosis. • If test results are unsatisfactory please contact personally or on phone.
- This report is for perusal of doctors only. • All disputes are subject to Delhi jurisdiction only. • Not for medico legal case.
- All congenital anomalies in a foetus may not be diagnosed in routine obstetric ultrasound.



ONEPLUS ULTRASOUND LAB

47, HARSH VIHAR, PITAMPURA, DELHI- 110034

Mr. YASH YADAV
 Age : 38M
 Ref. by : MEDIWHEEL
 Indication 1 :
 Indication 2 :
 Indication 3 :
 COMMENTS : Normal ECG.

ID : 2532
 HWT : 181/92
 Recorded : 1-4-2024 10:37
 Medication 1 :
 Medication 2 :
 Medication 3 :

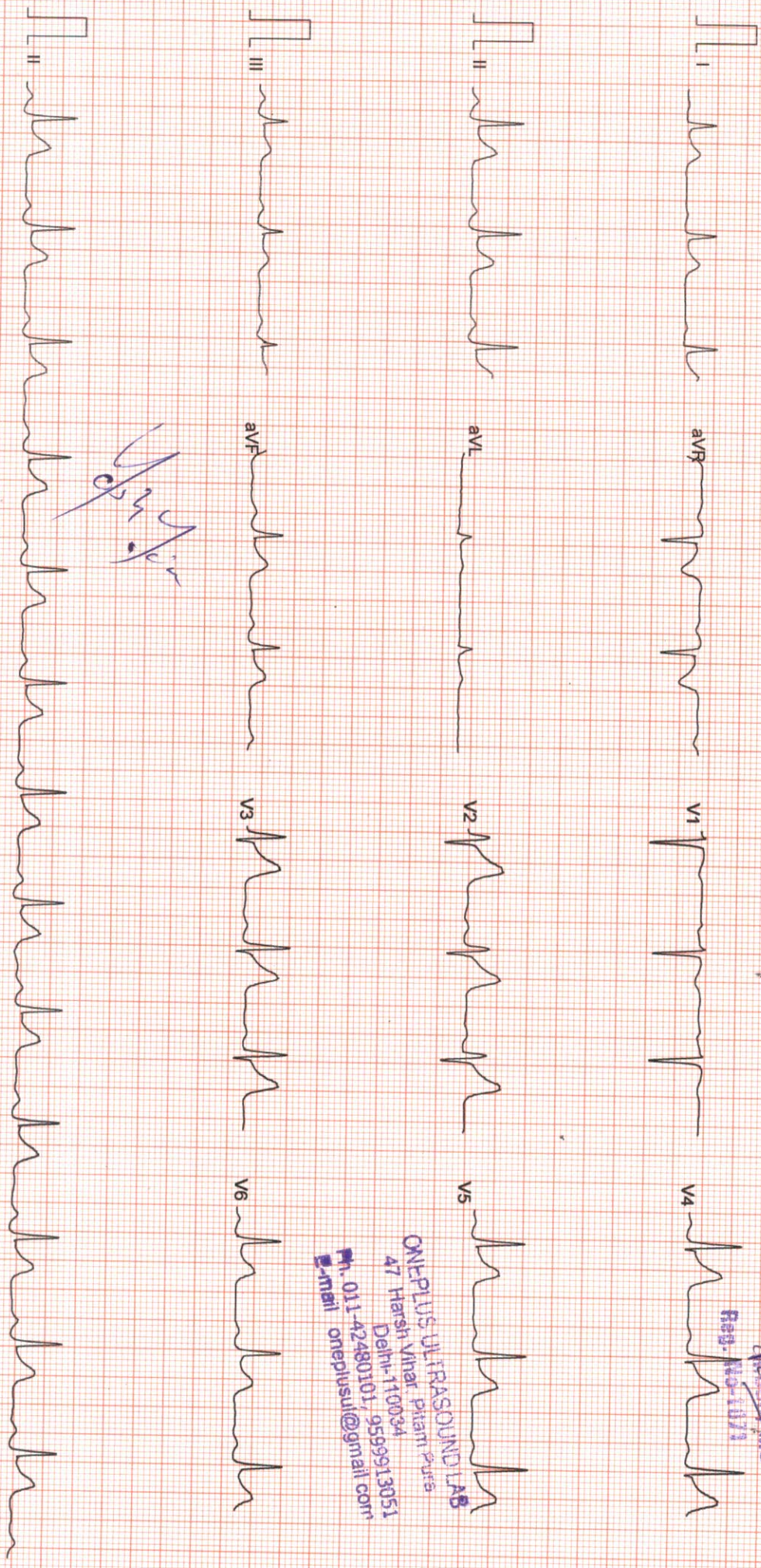
BPM : 80
 BP : 140/90
 P Axis : 67 deg
 QRS Axis : 52 deg
 T Axis : 55 deg

P duration : 100 msec
 PR duration : 176 msec
 QRS duration : 100 msec
 QT interval : 300 msec
 QTc interval : 335 msec
 Raw E.C.G.(Seq)

Unconfirmed Report Reviewed By:
 Cardiologist

Dr. P. Gupta
 Reg. No. 1077

ONEPLUS ULTRASOUND LAB
 47 Harsh Vihar Pitam Pura
 Delhi-110034
 Ph. 011-42480101 / 9599913051
 E-mail oneplusul@gmail.com



Yash Yadav

Filtered

25mm/sec 10mm/mV

Cardicom, INDIA

ONEPLUS ULTRASOUND LAB

47, HARSH VIHAR PITAMPURA DELHI 110034

ID : 973

HWWT : 181/92
Recorded : 1-4-2024 10:41

TREADMILL TEST SUMMARY REPORT
Protocol: BRUCE

Mr. YASH YADAV
Age/Sex : 38/M
Ref. by : MEDIWHEEL
Indication1 :
Indication2 :
Indication3 :

History :
Medication1 :
Medication2 :
Medication3 :

PHASE	PHASE TIME	STAGE TIME	SPEED (Km./Hr.)	GRADE (%)	H.R. (BPM)	B.P. (mmHg)*	RPP X100	II	ST LEVEL (mm) [†]	V2	V5	METS
SUPINE												
STANDING	0:01	0:01										
HYPERVENT												
STAGE 1	2:59	2:59	2.70	10.00	110	150/94	165	2.0	3.7	4.4	2.4	4.80
STAGE 2	5:59	2:59	4.00	12.00	119	160/96	190	2.4	4.4	5.0	2.6	7.10
STAGE 3	8:59	2:59	5.40	14.00	135	170/98	229	2.2	5.0	3.0	3.0	10.00
STAGE 4	9:59	0:59	6.70	16.00	160	180/100	288	1.1	4.3	4.3	2.8	11.32
PEAK EXER	10:00	1:00			161	180/100	289	1.4	4.3	4.3	2.3	11.34
RECOVERY	2:59	2:59	0.00	0.00	90	142/90	127	1.6	3.4	3.4	1.9	


RESULTS

Exercise Duration : 10:00 Minutes
Max Heart Rate : 161 bpm 88 % of target heart rate 182 bpm
Max Blood Pressure : 180/100 mmHg
Max Work Load : 11.34 METS
Reason of Termination :

IMPRESSIONS

Negative for unstable ischaemia.

Dr. Pankaj Gupta
Cardiologist
Regd. No. 1071



ONEPLUS ULTRASOUND LAB
47 Harsh Vihar, Pitampura,
Delhi-110034
Ph. 011-42480101, 9599913051
E-mail: oneplusul@gmail.com

ONEPLUS ULTRASOUND LAB

Mr. YASH YADAV
I.D. : 973
AGE/SEX : 38M

RATE : 81 BPM

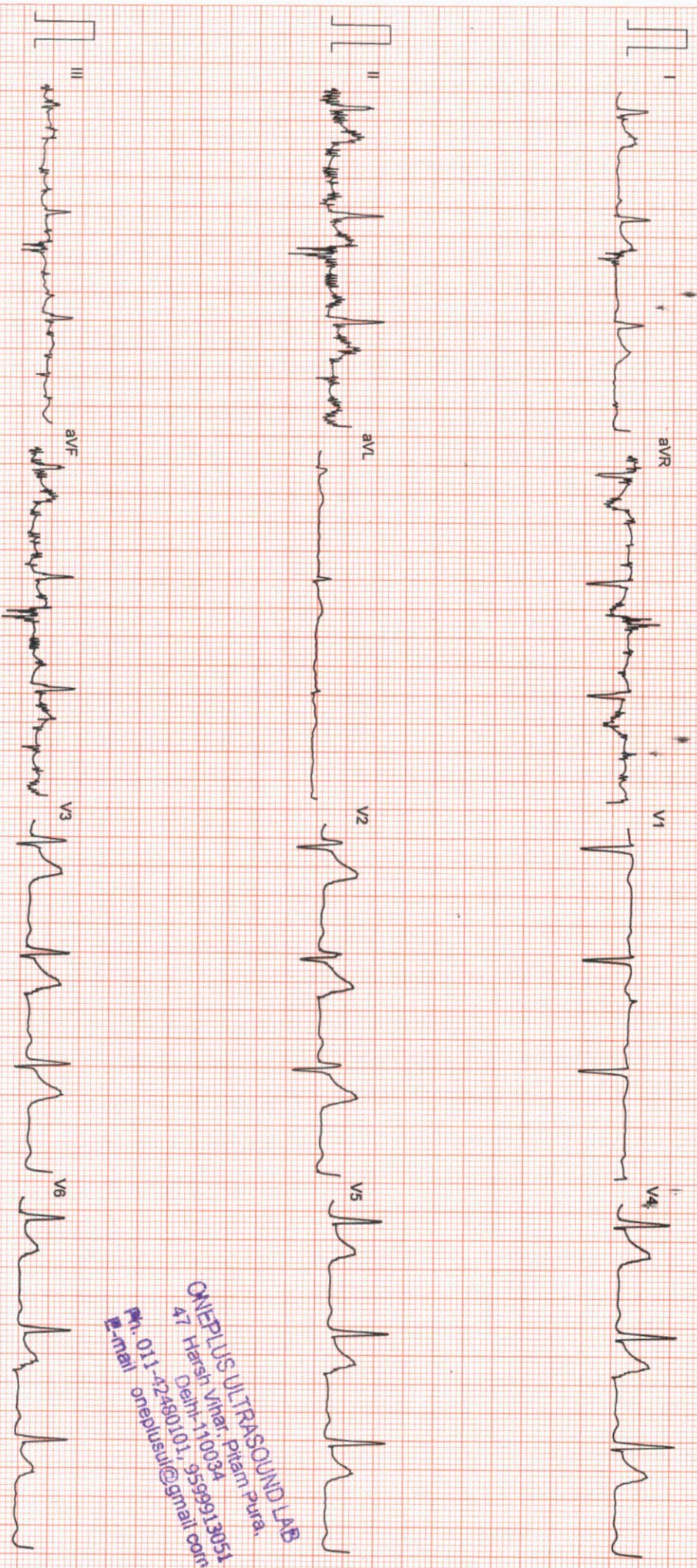
RECORDED : 1-4-2024 10:41

B.P. : 140/90 mmHg

SUPINE
PRETEST

ST @ 10mm/mV
80ms PostJ

RAW E.C.G.



ONEPLUS ULTRASOUND LAB
47, Harsih Vihar, Pitam Pura,
Delhi-110034
Ph. 011-2280101, 959991395
E-mail: oneplusul@gmail.com

Filtered
25mm/sec 10mm/mV

CardiCom, INDIA Ph.:091-731-2620740, TeleFax:091-731-2431214

Mr. YASH YADAV
I.D. : 973
AGE/SEX : 38/M
RECORDED : 1-4-2024 10:41

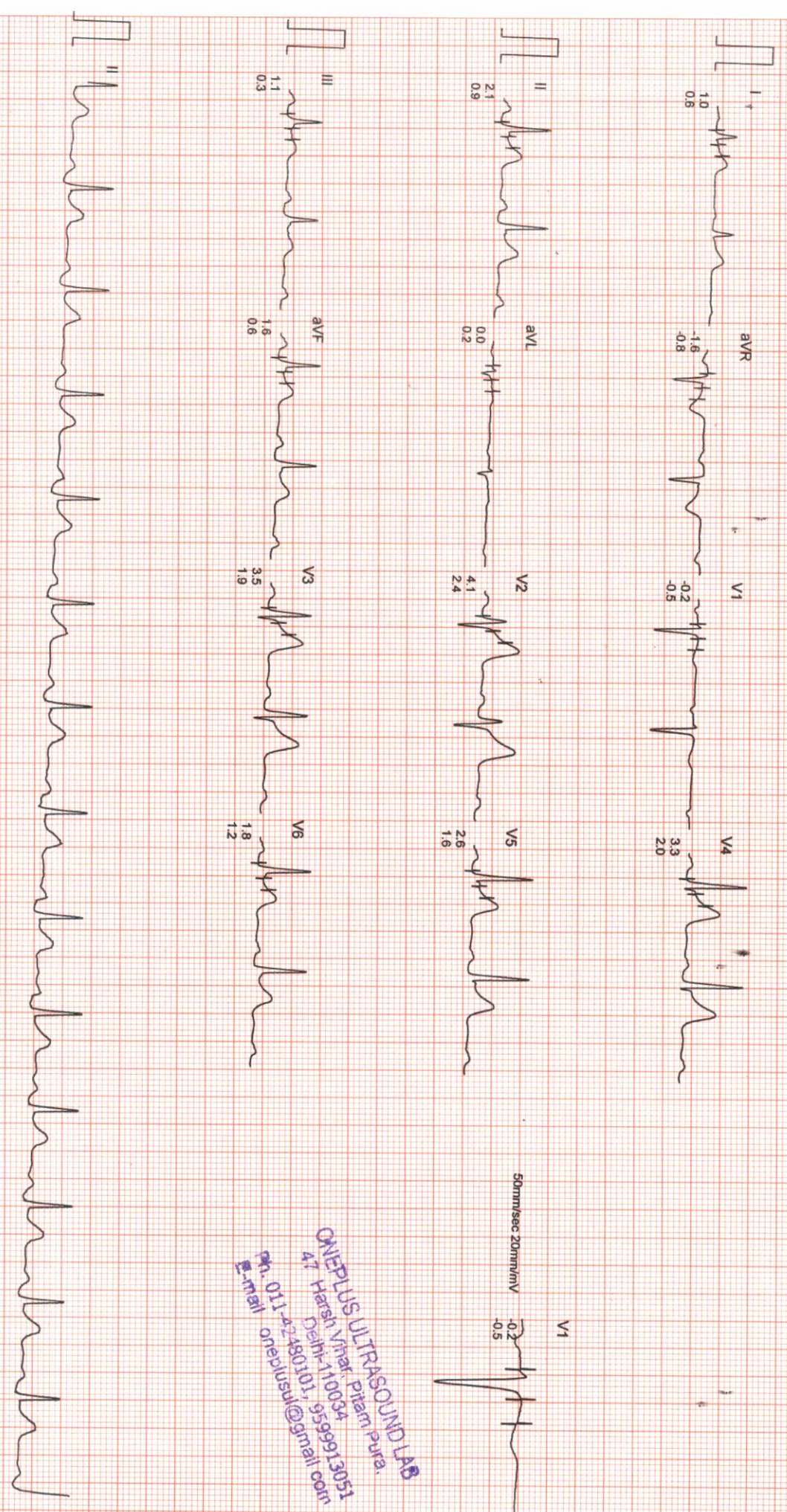
RATE : 87 BPM
B.P. : 140/90 mmHg

ONEPLUS ULTRASOUND LAB

STANDING
PRETEST

ST @ 10mm/mV
80ms PostJ

LINKED MEDIAN



ONEPLUS ULTRASOUND LAB
47, Harsh Vihar, Piram Pura,
Delhi-110034
Ph. 011-42480101, 9599913051
E-mail onepplus@gmail.com
www.onepplus.com

Filtered

Computer Corrected Baseline

25mm/sec 10mm/mV

CardiCom. INDIA Ph.:091-731-2620740, TeleFax:091-731-2431214

Mr. YASH YADAV
I.D. : 973
AGE/SEX : 38/M
RECORDED : 1-4-2024 10:41

RATE : 82 BPM
B.P. : 140/90 mmHg

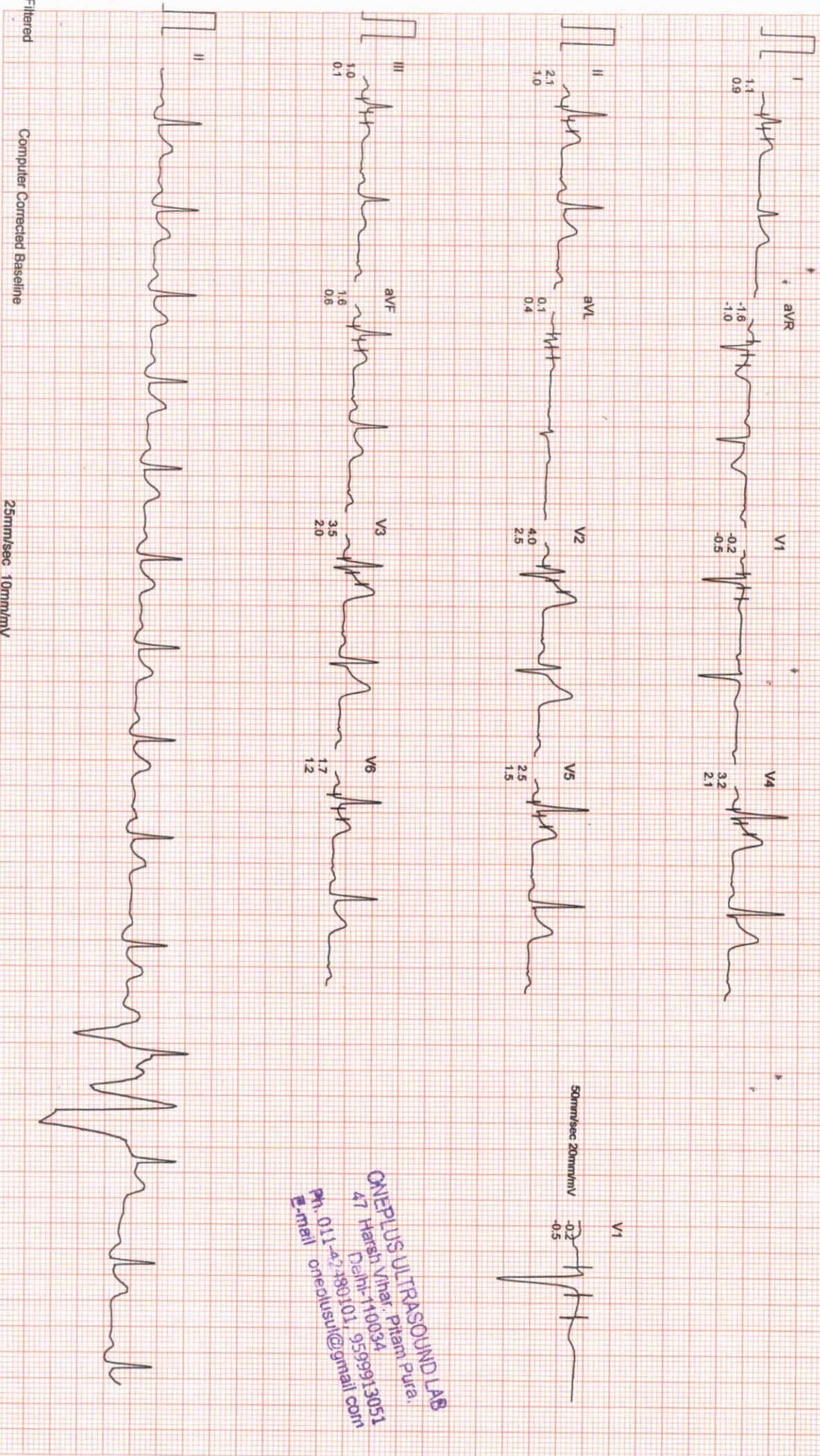
ONEPLUS ULTRASOUND LAB

HYPERVENTILATION
PRETEST

ST @ 10mm/mV
80ms PostJ

STAGE TIME : 0:01

LINKED MEDIAN



ONEPLUS ULTRASOUND LAB
47 Harsih Vihar, Pitampura, Noida
Delhi-110034
Ph. 011-43380101, 955999130351
Email onepulsul@gmail.com

ONEPLUS ULTRASOUND LAB

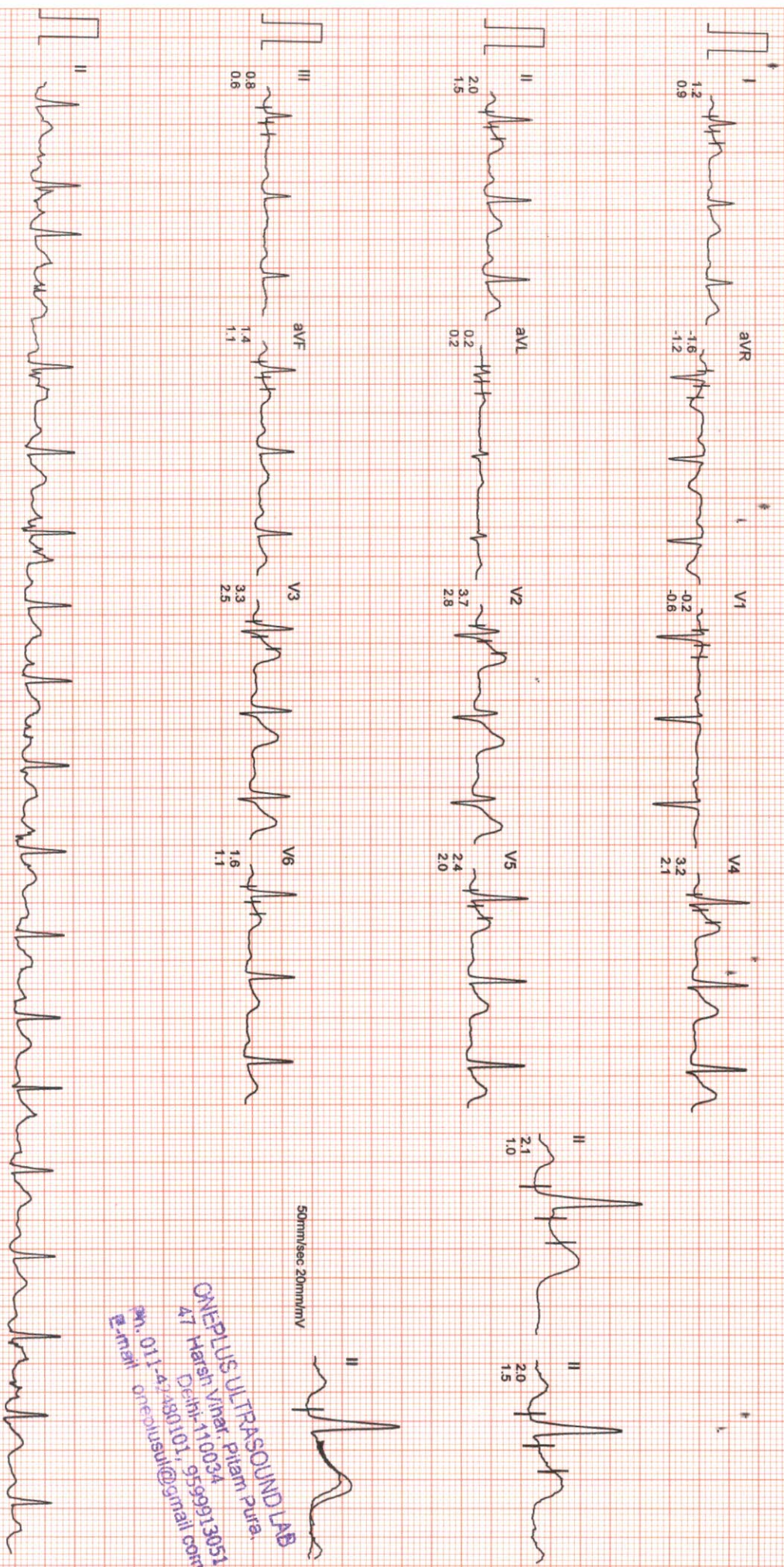
Mr. YASH YADAV
I.D. : 973
AGE/SEX : 38/M
RECORDED : 1-4-2024 10:41

RATE : 110 BPM
B.P. : 150/94 mmHg

BRUCE
EXERCISE 1
PHASE TIME : 2:59
STAGE TIME : 2:59

ST @ 10mm/mV
80ms PostJ
SPEED : 2.7 Km./Hr.
GRADE : 10.0 %

LINKED MEDIAN



50mm/sec 20mm/mV

ONEPLUS ULTRASOUND LAB
47 Harsit Vihar, Pitam Pura,
Delhi-110034
Ph: 011-47488010, 95599913051
Email: oneplusul@gmail.com

Mr. YASH YADAV

I.D. : 973

AGE/SEX : 38/M

RECORDED : 1-4-2024 10:41

ONEPLUS ULTRASOUND LAB

BRUCE

EXERCISE 2

PHASE TIME : 5:59

STAGE TIME : 2:59

RATE : 119 BPM

B.P. : 160/96 mmHg

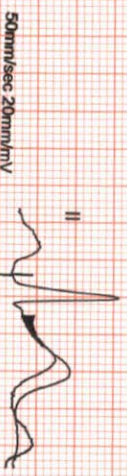
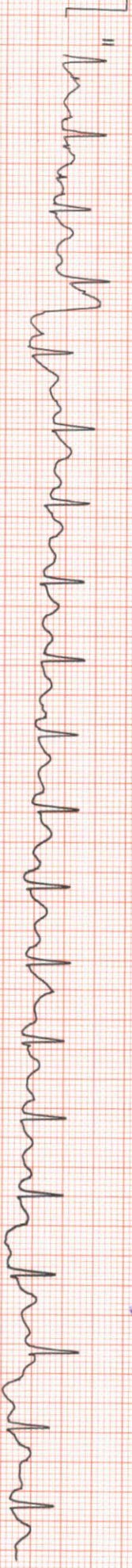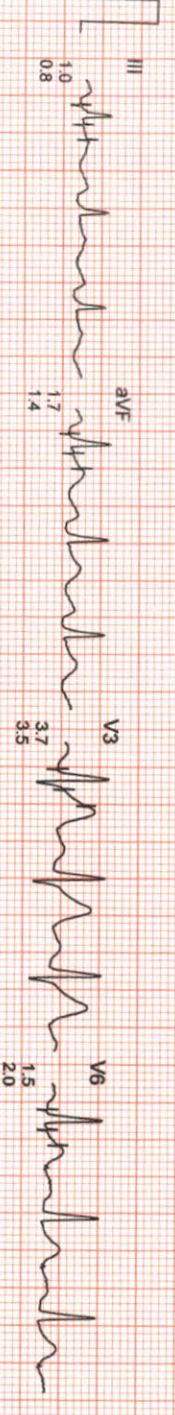
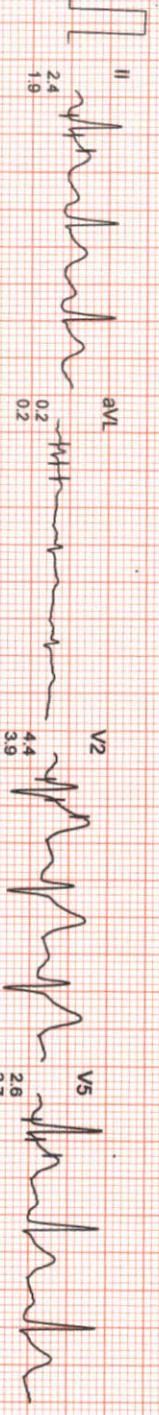
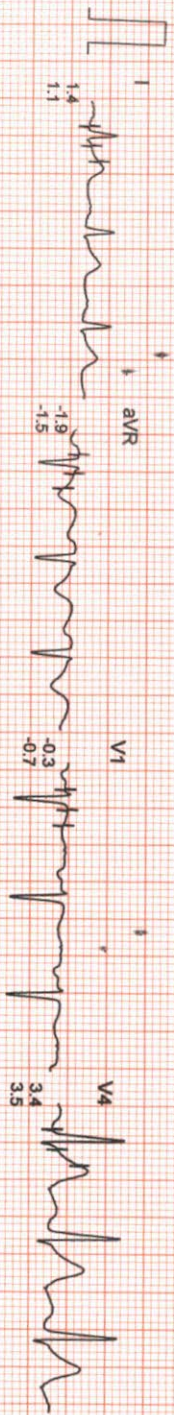
ST @ 10mm/mV

80ms PostJ

SPEED : 4.0 Km./Hr.

GRADE : 12.0 %

LINKED MEDIAN



50mm/sec 20mm/mV

ONEPLUS ULTRASOUND LAB
 47 Harsh Vihar Pitam Pura,
 Delhi-110084
 Delh-110084, 9599913051
 Ph: 011-47480101, 9599913051
 Email: oneplusul@gnail.com

Filtered

Computer Corrected Baseline

25mm/sec 10mm/mV

ONEPLUS ULTRASOUND LAB

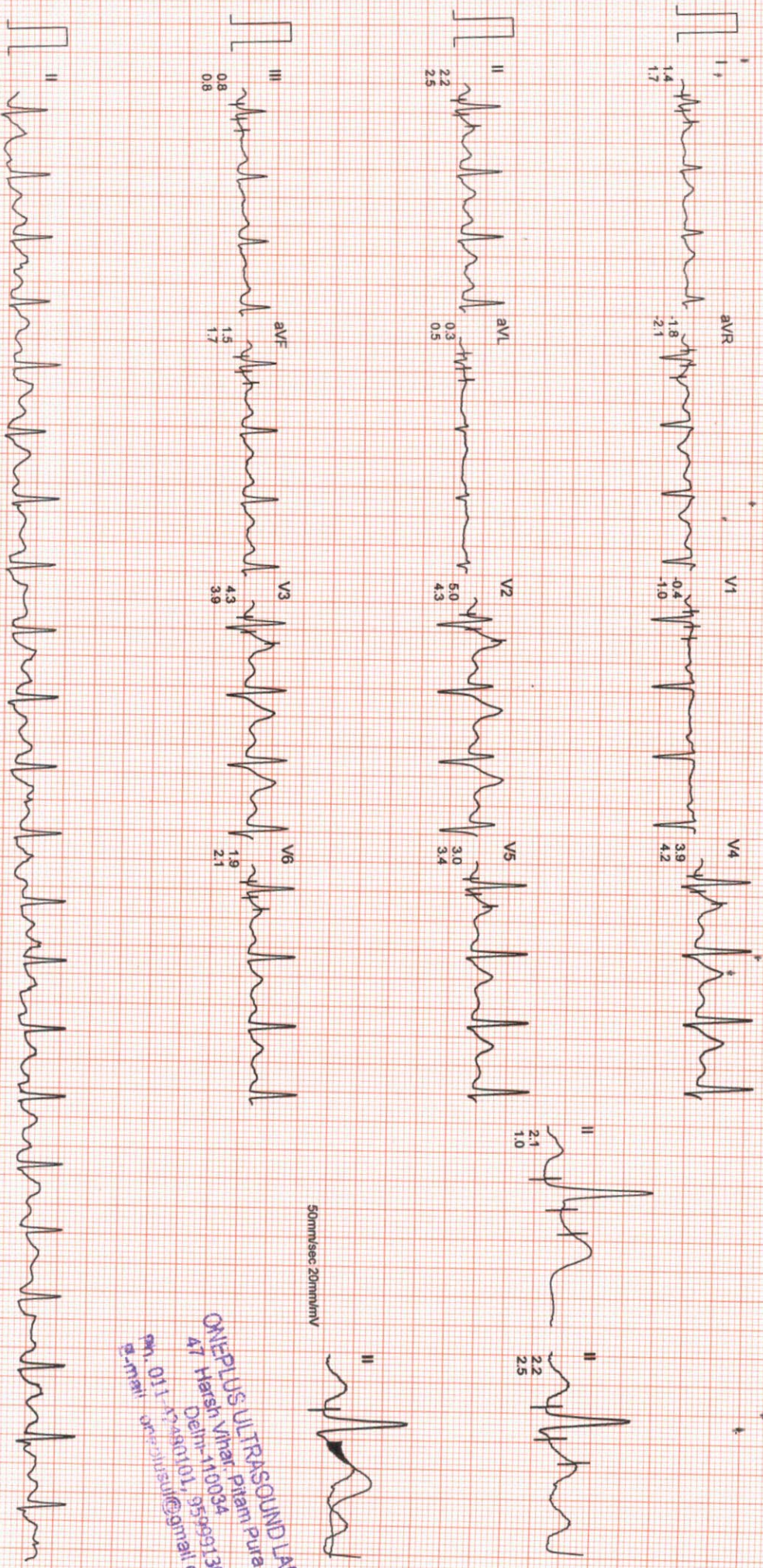
Mr. YASH YADAV
 I.D. : 973
 AGE/SEX : 38/M
 RECORDED : 1-4-2024 10:41

RATE : 135 BPM
 B.P. : 170/98 mmHg

BRUCE
 EXERCISE 3
 PHASE TIME : 8:59
 STAGE TIME : 2:59

ST @ 10mm/mv
 80ms PostJ
 SPEED : 5.4 Km./Hr.
 GRADE : 14.0 %

LINKED MEDIAN



50mm/sec 20mm/mv

ONEPLUS ULTRASOUND LAB
 47 Harsik Nathar, Pitambara
 DC Nehru-1100934
 Ph: 011-42449010/11, 9549913052
 Email: oneplusultrasound@gmail.com
 @oneplusultrasound

Filtered

Computer-Corrected Baseline

25mm/sec 10mm/mv

CardiCom, INDIA Ph.:091-731-2620740, Telefax:091-731-2431214

ONEPLUS ULTRASOUND LAB

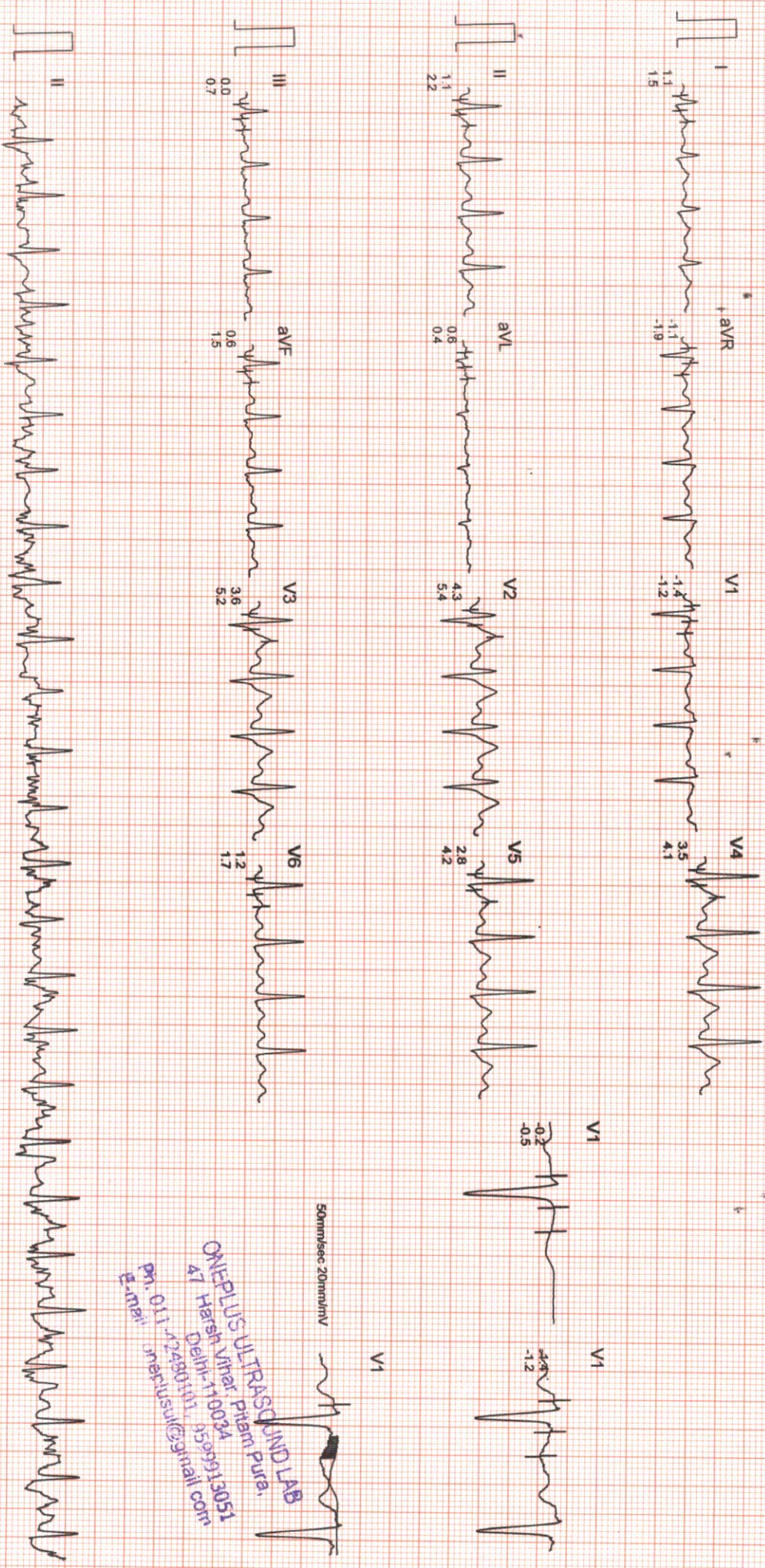
Mr. YASH YADAV
 I.D. : 973
 AGE/SEX : 38/M

RECORDED : 1-4-2024 10:41
 RATE : 160 BPM
 B.P. : 180/100 mmHg

BRUCE
 EXERCISE 4
 PHASE TIME : 9:59
 STAGE TIME : 0:59

ST @ 10mm/mV
 80ms PostJ
 SPEED : 6.7 Km./Hr.
 GRADE : 16.0%

LINKED MEDIAN



ONEPLUS ULTRASOUND LAB
 47 Harsit Vihar, Pitam Pura,
 Delhi-110034
 Ph: 011-2460101, 85999913051
 Email: onepusul@gmail.com

ONEPLUS ULTRASOUND LAB

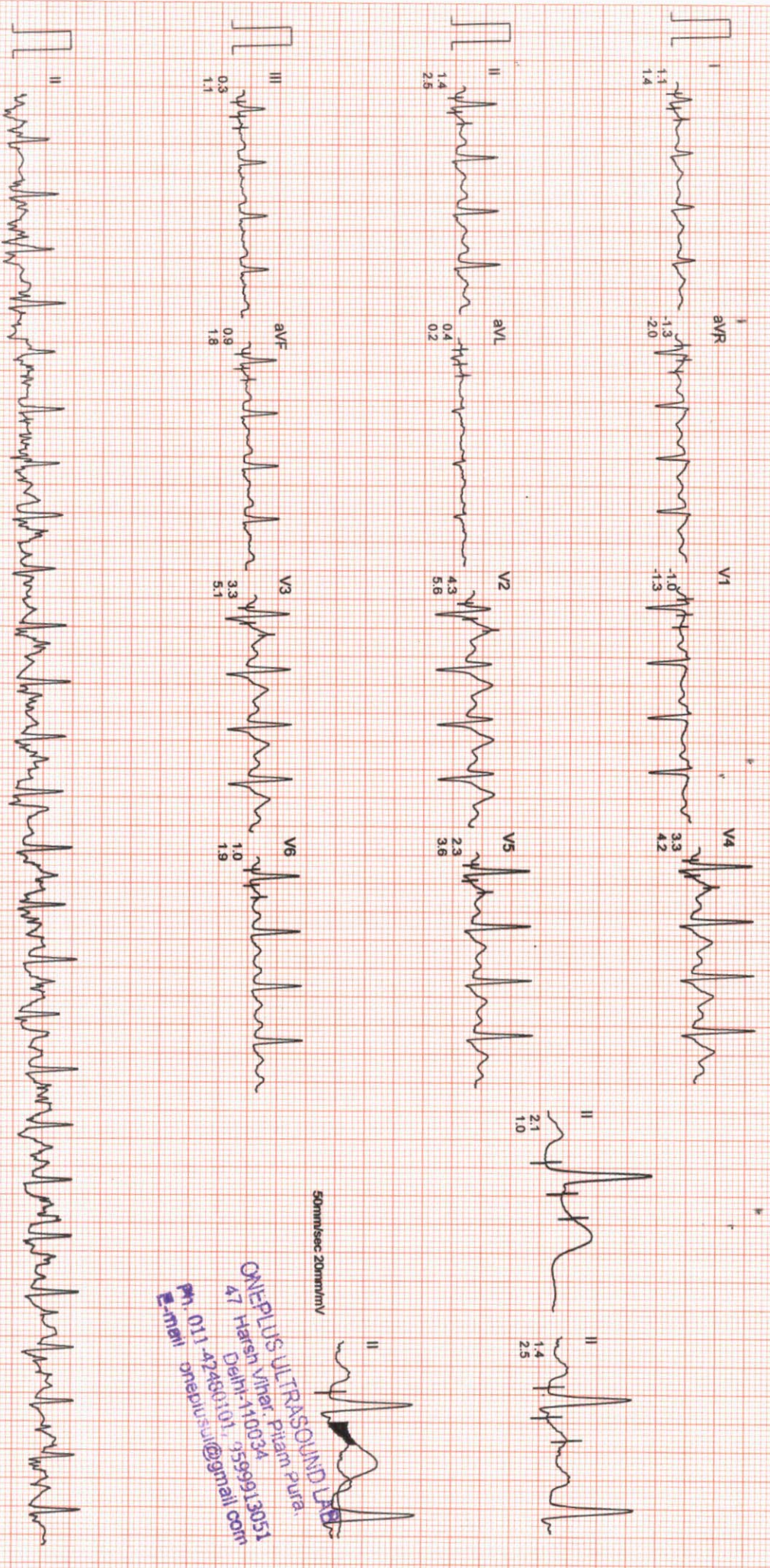MR. YASH YADAV
I.D. : 973
AGE/SEX : 38/M

RATE : 161 BPM
B.P. : 180/100 mmHg

BRUCE
PEAK EXER
PHASE TIME : 10:00
STAGE TIME : 1:00

ST @ 10mm/mV
80ms PostJ
SPEED : 6.7 Km./Hr.
GRADE : 16.0 %

LINKED MEDIAN



50mm/sec 20mm/mV

ONEPLUS ULTRASOUND LAB
47 H. Harsah Vihar, Pitampura
Delhi-110034
Ph. 011-42480101, 255599613051
Email: onepusul@ gmail.com

ONEPLUS ULTRASOUND LAB

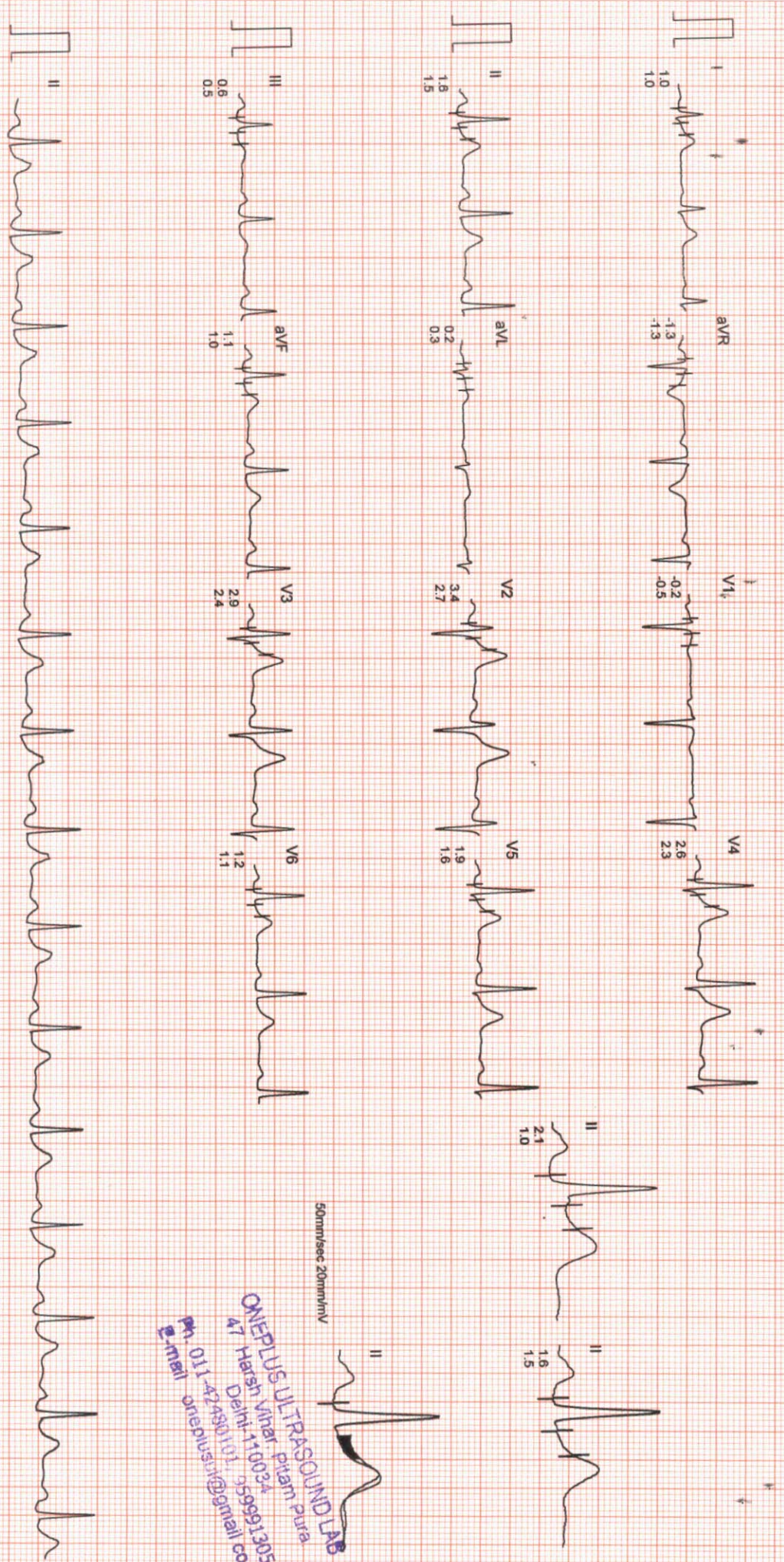
BRUCE
RECOVERY
PHASE TIME : 2:59

ST @ 10mm/mV
80ms PostJ
SPEED : 0.0 Km./hr.
GRADE : 0.0 %

Mr. YASH YADAV
I.D. : 973
AGE/SEX : 38/M

RATE : 90 BPM
B.P. : 142/90 mmHg



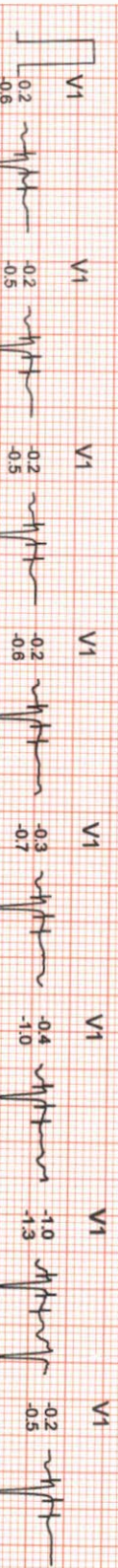

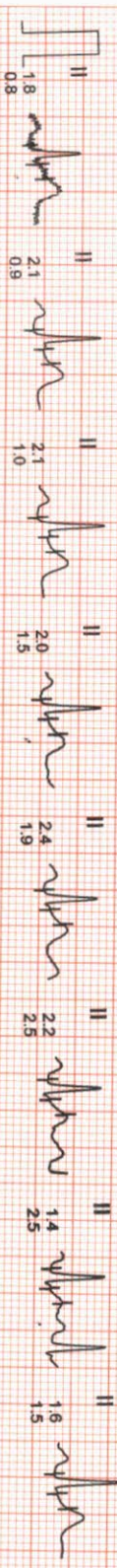
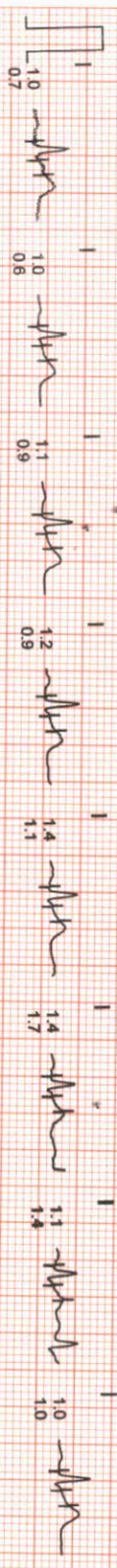
LINKED MEDIAN



50mm/sec 20mm/mV

ONEPLUS ULTRASOUND LAB
 Dr. Harsh Vihar, Pitam Pura
 Delhi-110034
 Ph. 011-42491101, 2599913051
 E-mail: oneplusul@gmail.com

STAGE	HR	BP	SpO2
SUPINE	0.0kmph	81 bpm	80ms PostJ
STANDING	0.0kmph	87 bpm	80ms PostJ
HYPERVENT	0.01	82 bpm	80ms PostJ
STAGE 1	2.59	110 bpm	80ms PostJ
STAGE 2	5.59	119 bpm	80ms PostJ
STAGE 3	8.59	135 bpm	80ms PostJ
PEAK EXERCISE	10:00	161 bpm	80ms PostJ
RECOVERY	2:59	90 bpm	80ms PostJ



ONEPLUS ULTRASOUND LAB
 417 Harsh Vihar Pitam Pura,
 Delhi-110034
 Ph. 011-42450101, 9599913051
 E-mail oneplusul@gmail.com

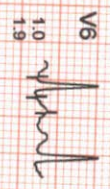
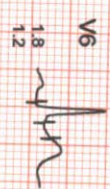
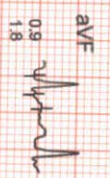

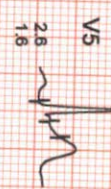


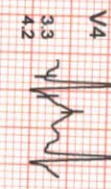
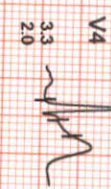

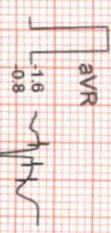
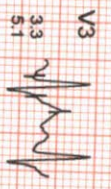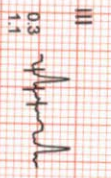

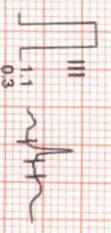
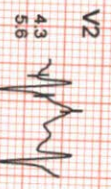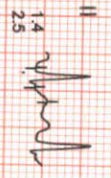

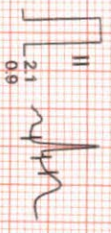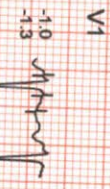
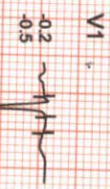
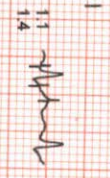

ONEPLUS ULTRASOUND LAB

STANDING
 0.0kmph
 0.0%
 87 bpm
 B.P. 140/90
 80ms PostU

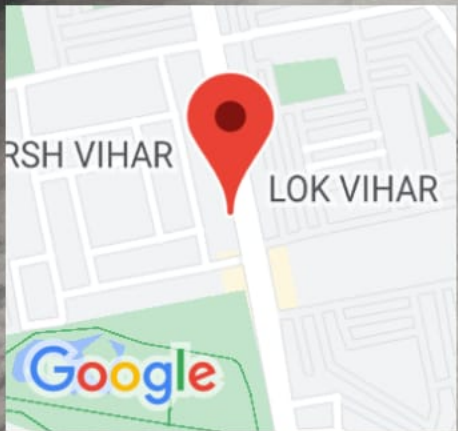PEAK EXERCISE
 10:00
 1:00
 6.7kmph
 16.0%
 161 bpm
 B.P. 180/100
 80ms PostU

STANDING
 0.0kmph
 0.0%
 87 bpm
 B.P. 140/90
 80ms PostU

PEAK EXERCISE
 10:00
 1:00
 6.7kmph
 16.0%
 161 bpm
 B.P. 180/100
 80ms PostU



ONEPLUS ULTRASOUND LAB
 47 H. Harsh Vihar Pitam Pura,
 Delhi-110084
 Ph: 011-26250111, 2566913051
 E-mail: oneplusultrasound@gmail.com



47, Mahatma Hansraj Marg, Harsh Vihar, Pitampura, Delhi, 110034, India

Lat : 28.6935857
Long : 77.1347608

01/04/2024 09:31:55