



# LIFE LINE

Reg No.: 659/25/01/2021

## Multispeciality Hospital Maternity Home & ICU

Plot No. 20, Gut No. 103, Opp. Surya Lawns Beed Bypass, Devlai, Chh. Sambhajinagar. Mob.: 9067028989, 9067038989

Rx

Date 24/03/2024

### Medical Fitness Certificate

This is to certify that below mentioned candidate has been examined on medical parameters and found free from contagious diseases there by medically fit for work. Final investigation reports will be forwarded to you at the earliest.

1. Name : DHIRAJ UPADHYA
2. Age : 39Yrs.
3. Sex : MALE
4. Physical Examination : Normal
5. Systemic Examination : Normal
6. Ophthalmic Examination: Normal
- 7 Vision /Colour Vision : i) Normal - Normal
- ii) Colour Blindness : Normal
- 8 ECG : Normal
- 9 X RAY CHEST : Normal
- 10 USG : Normal
- 12 2DECHO : Normal

Remark- Person is fit to work in Company

Dr. SACHIN BANGAR  
M.B.B.S., M.D., M.B. (MEDI.)  
R.C.I. No. 02/MB/3045  
Medical officer



# LIFE LINE

Reg No.: 659/25/01/2021

## Multispeciality Hospital Maternity Home & ICU

Plot No. 20, Gut No. 103, Opp. Surya Lawns Beed Bypass, Devlai, Chh. Sambhajinagar. Mob.: 9067028989, 9067038989

Rx

NAME: DHIRAJ UPADHYA  
AGE/ SEX: 39/MALE

DATE: 24/03/2024

### PRE-EMPLOYMENT HEALTH CHECKUP 2024

HISTORY :- Nil

ADDICATION: - Nil

### GENERAL MEDICAL EXAMINATION

#### 1. Physical Examination

Height : 166Cms

Weight : 78 Kg

Pulse : 89 Min

B.P. : 130/70mmHg

Skin Examination- Any diseases- :-No

Oral Examination Hygiene- Any diseases- :-No

ENT Examination- Any diseases- :-No

#### 2. SYSTEMIC EXMINATION

a) Abdomen :- Soft, No Organomegaly

b) CVS :- Normal Heart sound

c) Respiratory System :- Normal Air Entry Both Lungs

d) Nervous System :- Normal Clinically

### INVESTIGATIONS (POSITIVE FINDING)

Pathological investigation :- (Reports Enclosed) Annexure

Vision :- (Reports Enclosed) Annexure

Color Vision :- (Reports Enclosed) Annexure

E C G :- (Reports Enclosed) Annexure

X-Ray Chest :- (Reports Enclosed) Annexure

USG :- (Reports Enclosed) Annexure

2DECHO :- (Reports Enclosed) Annexure

Fit for employment

**DR. SACHIN BANGAR**  
M.B.B.S. MD, DNB (MEDI.)  
Reg. No. 02/08/3045  
Medical Examiner

२४ तास अत्यावश्यक सेवा उपलब्ध



# LIFE LINE

Reg No.: 659/25/01/2021

## Multispeciality Hospital Maternity Home & ICU

Plot No. 20, Gut No. 103, Opp. Surya Lawns Beed Bypass, Devlai, Chh. Sambhajinagar. Mob.: 9067028989, 9067038989

Rx

### OPHTHALMIC EXAMINATION

NAME OF EMPLOYEE: DHIRAJ UPADHYA  
AGE: 39/MALE  
DATE OF EXAMINATION: -24/03/2024

		RE (RIGHT EYE)	LE (LEFT EYE)
NEAR VISION	WITH GLASSES	N/6	N/6
	WITH OUT GLASSES		
DISTANCE VISION	WITH GLASSES	6/6	6/6
	WITH OUT GLASSES		

COLOUR VISION: - NORMAL

DR. SACHIN BANGAR  
M.B.B.S. MD, DNB (MEDI.)  
Reg. No. 02/08/3045  
(SIGNATURE)

२४ तास अत्यावश्यक सेवा उपलब्ध



# LIFE LINE

Reg No.: 659/25/01/2021

## Multispeciality Hospital Maternity Home & ICU

Plot No. 20, Gut No. 103, Opp. Surya Lawns Beed Bypass, Devlai, Chh. Sambhajinagar. Mob.: 9067028989, 9067038989

Rx

NAME OF THE PATIENT: DHIRAJ UPADHYA

AGE: 39/MALE

DATE: -24/03/2024

### REPORT:

Condition of Lung pleura: WNL

### Heart & Aorta:

Transverse Diameter of Heart: WNL

Transverse Diameter of Aortic Arch: WNL

Cardio-Thoracic Ratio: WNL

Any changes of Arteriosclerosis or Calcification of Aorta etc.  
WNL

### CONCLUSION & REMARK:

X-RAY CHEST IS WITH IN NORMAL LIMITS.

DR. SACHIN BANGAR  
MD, DNB (MEDI.)  
REG. NO. 02/08/3045  
Medical Examiner



Reg No.: 659/25/01/2021

# LIFE LINE

## Multispeciality Hospital Maternity Home & ICU

Plot No. 20, Gut No. 103, Opp. Surya Lawns Beed Bypass, Devlai, Chh. Sambhajinagar. Mob.: 9067028989, 9067038989

Rx

Patient Name	DHIRAJ UPADHYA	Date: 24/03/2024
Age / Sex	39Yrs /M	Performed By: DR. VIVEK JAJU

### USG ABDOMEN AND PELVIS

**LIVER:** Liver is normal in size measuring 13.4cm & shows normal echo texture. No evidence of any diffuse or focal pathology. Intrahepatic biliary radicals are not dilated. Portal vein & CBD are normal in diameter.

**GALL BLADDER:** is well-distended. No evidence of calculus or mass. Gall bladder wall thickness is normal.

**PANCREAS:** is normal in size and echo texture. Pancreatic duct is not dilated.

**SPLEEN:** Spleen is normal in size measuring 9.1cm & shows normal echo texture. No evidence of any focal lesion.

#### **KIDNEYS:**

Right Kidney measures 9.2 x 4.4 cm in size.

Left Kidney measures 9.5 x 5.4 cm in size.

Both kidneys are normal in size and echo texture. Corticomedullary differentiation is normal. No evidence of calculus or hydronephrosis on both sides.

**Urinary Bladder** is Well-distended.

**Prostate** is normal in size and echo texture.

IVC and aorta are normal. No Para aortic lymphadenopathy.

No evidence of any intra- abdominal or pelvic mass.

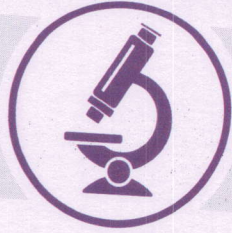No e/o any free fluid in abdomen and pelvis.

High resolution USG was performed with high frequency linear transducer, which reveals normal bowel loops and mesenteric structures. No evidence of significant mesenteric lymphadenopathy.

#### **IMPRESSION:**

**No significant abnormality detected.**

२४ तास अत्यावश्यक सेवा उपलब्ध



# Vaidyanath Diagnostics

PATHOLOGY LABORATORY

PATHOLOGY | X-RAY | SONOGRAPHY | 2-D ECHO | CTMT | PFT | AUDIOMETRY

Accession No : 2024032410

Patient Name : Mr. DHIRAJ UPADHYA

Age / Sex : 39 Year/Male

Referred by : LIFELINE MULTISPECIALITY HOSPITAL

Registered On : 24/03/2024

Reporting On : 24/03/2024

Printed On : 24/03/2024



Test Name	Patient value	Reference Range	Unit
VOLUME	5 ML		
COLOUR	PALE YELLOW	( NORMAL : 2 TO 6 )	
APPERANCE	CLEAR		
<b><u>CHEMICAL EXAMINATION</u></b>			
PROTEIN	NIL	NOT DETECTED	
GLUCOSE	NIL	NOT DETECTED	
<b><u>MICROSCPIC EXAMINATION</u></b>			
EPITHELIAL CELLS	1-2		/hpf
PUS CELL / LEUCOCYTES	2-4		/hpf/Leu/UL
RED BLOOD CELLS/BLD	ABSENT	NIL	/hpf/Ery/UL
CASTS	NOT DETECTED	NOT DETECTED	
CRYSTALS	NOT DETECTED	NOT DETECTED	
BACTERIA	NOT DETECTED	NOT DETECTED	

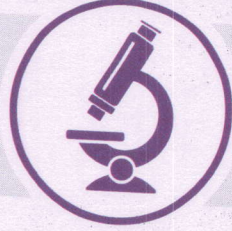## HEMATOLOGY

### COMPLETE BLOOD COUNTS

Hb	14.8	13.0 - 18.0	g/dL
RBC COUNT	5.07	4.50 - 5.50	$10^6/uL$
TLC	6300	4000 - 10000	$10^3/uL$
<b><u>RED CELL ABSOLUTE VALUES</u></b>			
HCT	40.1	35.0 - 60.0	%
MCV	79.09	83.0 - 101.0	f L
MCH	29.19	27.0 - 32.0	pg
MCHC	36.91	31.5 - 34.5	g/dL
<b><u>DLC (DIFFERENTIAL LEUKOCYTE COUNT)</u></b>			
NEUTROPHILS	55	40.0 - 80.0	%
LYMPHOCYTES	36	20.0 - 40.0	%
EOSINOPHILS	05	2.0 - 6.0	%

Plot No.20, Gut No.103, Opp. Surya Lawns, Beed By Pass Road, Deolai, Aurangabad

24 HOURS EMERGENCY SERVICE ☎ Mob No. : 9067028989/9067038989



# Vaidyanath Diagnostics

PATHOLOGY LABORATORY

PATHOLOGY | X-RAY | SONOGRAPHY | 2-D ECHO | CTMT | PFT | AUDIOMETRY

Accession No : 2024032410

Patient Name : Mr. DHIRAJ UPADHYA

Age / Sex : 39 Year/Male

Referred by : LIFELINE MULTISPECIALITY HOSPITAL

Registered On : 24/03/2024

Reporting On : 24/03/2024

Printed On : 24/03/2024



Test Name	Patient value	Reference Range	Unit
<b>BIOCHEMISTRY</b>			
<b>BLOOD SUGAR</b>			
BLOOD SUGAR (FASTING)	85	70 - 110	mg/dl
BLOOD SUGAR (Post Meal )	112	70 - 140	mg/dl
<b>URINE SUGAR</b>			
URINE SUGAR ( Fasting )	SNR		NIL
URINE SUGAR ( Post Meal )	SNR		NIL
<b>LIVER FUNCTION TEST</b>			
BILIRUBIN TOTAL	0.8	0.1 - 1.2	mg/dl
DIRECT	0.2	0.0 - 0.3	mg/dl
INDIRECT	0.6	0.1 - 1.0	mg/dl
SGOT	33	10 - 40	mg/dl
SGPT	29	06 - 40	mg/dl
ALKALINE PHOSPHATASE	93	42 - 141	g/dL
TOTAL PROTINE	6.6	6 - 8	g/dl
ALBUMIN	3.8	3.5 - 4.8	g/dl
GLOBULIN	2.8	2.8 - 3.3	g/dL

## HEMATOLOGY

### BLOOD GROUP

BLOOD GROUP

"B" RH POSITIVE

Note : Grouping & Cross matching is absolutely essential prior to blood transfusion patient identity as disclosed by patients himself/herself.

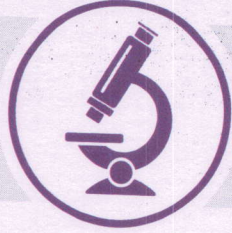## URINE ROUTINE

### URINE ROUTINE EXAMINATION

### PHYSICAL EXAMINATIN

Plot No.20, Gut No.103, Opp. Surya Lawns, Beed By Pass Road, Deolai, Aurangabad

24 HOURS EMERGENCY SERVICE ☎ Mob No. : 9067028989/9067038989



# Vaidyanath Diagnostics

PATHOLOGY LABORATORY

PATHOLOGY | X-RAY | SONOGRAPHY | 2-D ECHO | CTMT | PFT | AUDIOMETRY

Accession No : 2024032410

Patient Name : Mr. DHIRAJ UPADHYA

Age / Sex : 39 Year/Male

Referred by : LIFELINE MULTISPECIALITY HOSPITAL

Registered On : 24/03/2024

Reporting On : 24/03/2024

Printed On : 24/03/2024



Test Name	Patient value	Reference Range	Unit
MONOCYTES	04	1.0 - 8.0	%
BASOPHILS	00	< 1.0	%
<b><u>PLATELET COUNT</u></b>			
PLATELET COUNT	185000	150000 - 450000	10 <sup>3</sup> /ul
E.S.R	10	1 - 20	MM/HRS

## BIOCHEMISTRY

### LIPID PROFILE

S. Cholesterol	185	0 - 200	mg/dl
S. Triglycerides	135	25 - 160	mg/dl
HDL Cholesterol	37	30 - 60	md/dl
LDL Cholestrol	121	85 - 150	mg/dL

### Kidney Function Test

CREATININE	0.9	0.5 - 1.4	mg/dl
UREA	22	10 - 50	mg/dl

### ELECTROLYTE

#### ELECTROLYTES

SODIUM	141	135 - 150	mMol/L
POTASSIUM	4.9	3.5 - 5.0	mMol/L
CHLORIDE	102	96 - 108	mmol/L

Kindly Correlate Clinically !

Thanks for referral !

DR. SANDIP AMBEKAR

MBBS,DPB

Reg.no 2001/02/0426

----- End of Report -----



Package name	Package Inculsions	Customer Name	Gender M/F
ARCOFEMI - MEDIWHEEL - FULL BODY ANNUAL CHECKUP MALE - 2D ECHO - PAN INDIA - FY2324	GLUCOSE - SERUM / PLASMA(FASTING AND POST PRANDIAL,LIVER FUNCTION TEST (PACKAGE),X-Ray Chest PA,Dietician consultation,BMI,Consultation - Dental,Blood Grouping And Typing (Abo And Rh),ECG,Fitness by General Physician,Urine Routine (CUE),GGTP: Gamma Glutamyl Transpeptidase - Serum,Ultrasound - Whole Abdomen,Ophthal by General Physician,HEMOGRAM (CBC+ESR),Package Consultation - ENT,URINE GLUCOSE(FASTING),2 D ECHO,Lipid Profile (all Parameters),Renal Function Test,Audiometry,URINE GLUCOSE(POST PRANDIAL),GAMMA GLUTAMYL TRANFERASE (GGT),GLUCOSE, FASTING,BODY MASS INDEX (BMI),BLOOD GROUP ABO AND RH FACTOR,Doctor,HFA SPEECH AUDIOMETRY,HEMOGRAM + PERIPHERAL SMEAR,PERIPHERAL SMEAR,LIVER FUNCTION TEST (LFT),LIPID PROFILE,DIET CONSULTATION,GLUCOSE, POST PRANDIAL (PP), 2 HOURS (POST MEAL),RENAL PROFILE/RENAL FUNCTION TEST (RFT/KFT),COMPLETE URINE EXAMINATION	MR. UPADHYA DHIRAJ KUMAR	male

भारत सरकार  
Government of India

धिरज कुमार उपाध्याय  
Dhiraj Kumar Upadhyay  
जन्म तारीख/DOB: 12/12/1984  
पुरुष/ MALE

Download Date: 11/01/2021

Issue Date: 09/01/2021

4546 4122 3691  
VID : 9149 7398 4161 3179

माझे आधार, माझी ओळख

NAME: DHIRAJ UPADHYA

AGE: 39YRS/M

DATE: 24/03/2024

## **2D ECHO DOPPLER REPORT**

Patient in tachycardia during study

La Ra Normal in Size and shape.

LV is normal in size and shape.

Good LV Systolic function.

LVEF>55%

NO DIASTOLIC DUSFUNCTION.

NO regional wall motion abnormality

No intra cardiac shunts vegetation.

No MR/TR/AR

NO PERICARDIAL EFFUSION.

**IMPRESSION: ESSENTIALLY NORMAL 2D ECHO DOPPLER STUDY**

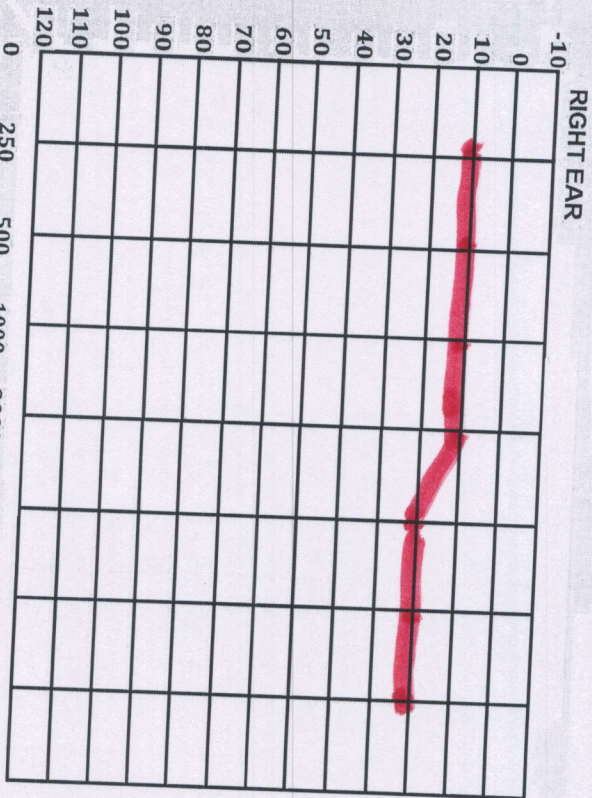
**(SIGNATURE)**

**Screening Test**


*Name: Princy Upadhyaya  
Age: 89/yr.*

**AUDIOGRAM**

HEARING THRESHOLD IN DECIBELS  
Normal Mild Moderate Severe Profound



HEARING THRESHOLD IN DECIBELS  
Normal Mild Moderate Severe Profound



**SYMBOLS**

Mode Ear	Air Condition		Bone Conduction		Color Code
	Masked	Unmasked	Masked	Unmasked	
LEFT	H	X	I	<	BLUE
RIGHT	D	O	J	>	RED

AUDIOMETER : **Arphi.** (MODEL - 500 MK IS)

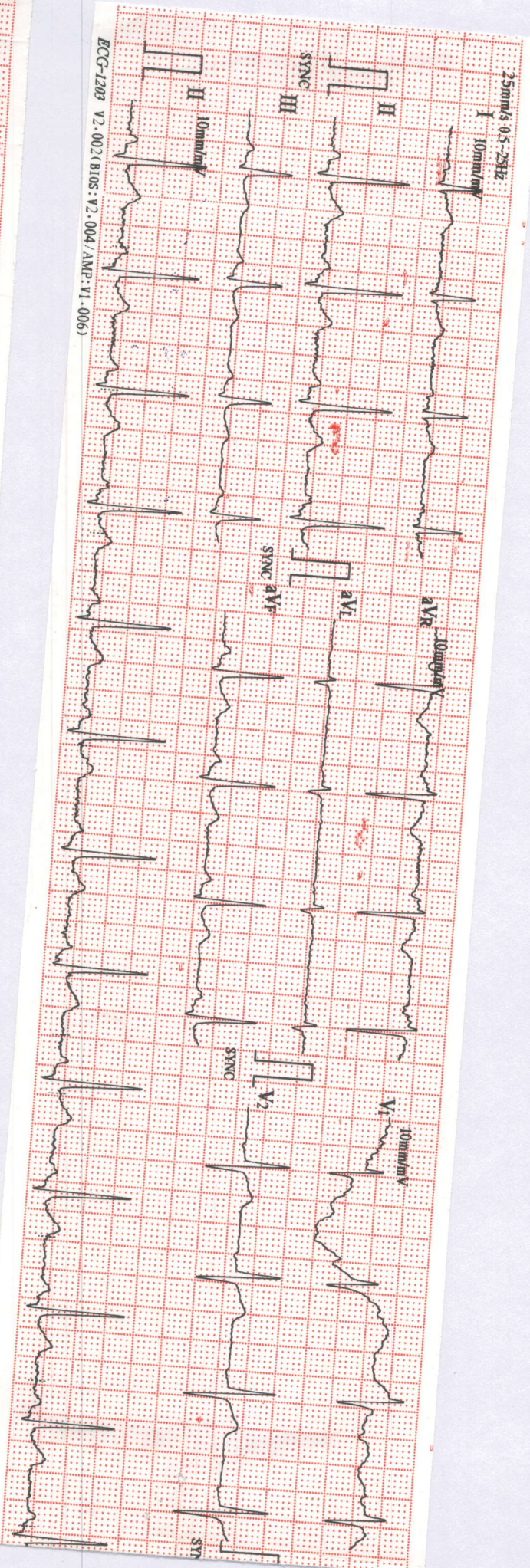
TEST FREQUENCY IN HERTZ  
AIR O -----O  
BONE >

TEST FREQUENCY IN HERTZ  
AIR X -----X  
BONE <

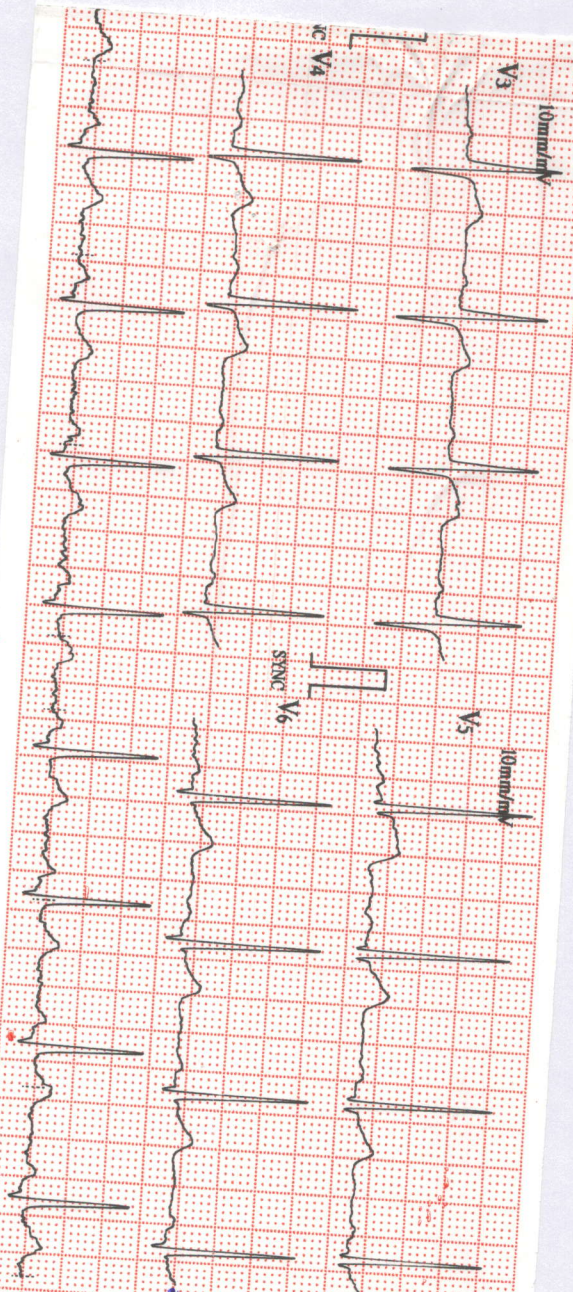
**REMARKS**

*Princy*

**DR. SACHIN BANGAR**  
M.P.H. MD, DNB (MEDI.)  
Reg. No. 02/08/3045



ECG-1203 V2.002(BIOS: V2.004/AMP: V1.006)



03/25/2024 11:31  
 ID: 29  
 Name:   
 Age: 5  
 Sex: M  
 Height: 179  
 Weight: 69.2  
 HR: 105  
 RR: 17  
 SpO2: 98  
 P/QRST: 356/400  
 P/QRS/T: 73/66/78  
 RV5/SVL: 1.880  
 RV5+SVL: 2.560

**DR. BACHIN BANGAS**  
 MD, DNB (MED)  
 REG. NO. 021/08/3045

*Upendra*  
*Princy Kumar*  
*Dr. Bachin Bangas*

Sinus Rhythm  
 Left Atrial Enlargement  
 Slight ST Depression

Physician: *Dr. Bachin Bangas*

03/23/2024  
 11:31 AM