


Patient Name : Mr. KANCHARAPU PHANINDRA Age : 29 Y/M
UHID : CKOR.0000252766 OP Visit No : CKOROPV404638
Conducted By: : Conducted Date : 09-04-2024 10:35
Referred By : SELF

Name : Mr. KANCHARAPU PHANINDRA Address : KMG Plan : ARCOFEMI MEDIWHEEL MALE AHC CREDIT PAN INDIA OP AGREEMENT	Age : 29 Y Sex : M	UHID :CKOR.0000252766  OP Number :CKOROPV404638 Bill No :CKOR-OCR-81723 Date : 23.03.2024 10:10
---	---	---

Sno	Service Type/ServiceName	Department
1	ARCOFEMI - MEDIWHEEL - FULL BODY ANNUAL PLUS MALE - 2D ECHO - PAN INDIA - FY2324	
<input checked="" type="checkbox"/>	GAMMA GLUTAMYL TRANSFERASE (GGT)	
2	D ECHO	
<input checked="" type="checkbox"/>	LIVER FUNCTION TEST (LFT)	
<input checked="" type="checkbox"/>	GLUCOSE, FASTING	
<input checked="" type="checkbox"/>	HEMOGRAM + PERIPHERAL SMEAR	
6	DIET CONSULTATION	
<input checked="" type="checkbox"/>	COMPLETE URINE EXAMINATION	
<input checked="" type="checkbox"/>	URINE GLUCOSE(POST PRANDIAL)	
<input checked="" type="checkbox"/>	PERIPHERAL SMEAR	
<input checked="" type="checkbox"/>	ECG <i>14</i>	
<input checked="" type="checkbox"/>	RENAL PROFILE/RENAL FUNCTION TEST (RFT/KFT)	
<input checked="" type="checkbox"/>	DENTAL CONSULTATION	
<input checked="" type="checkbox"/>	GLUCOSE, POST PRANDIAL (PP), 2 HOURS (POST MEAL)	
<input checked="" type="checkbox"/>	URINE GLUCOSE(FASTING)	
<input checked="" type="checkbox"/>	HbA1c, GLYCATED HEMOGLOBIN	
<input checked="" type="checkbox"/>	X-RAY CHEST PA <i>W - 11</i>	
17	ENT CONSULTATION <i>- ground floor</i>	
18	FITNESS BY GENERAL PHYSICIAN	
<input checked="" type="checkbox"/>	BLOOD GROUP ABO AND RH FACTOR	
<input checked="" type="checkbox"/>	LIPID PROFILE	
21	BODY MASS INDEX (BMI)	
<input checked="" type="checkbox"/>	OPHTHAL BY GENERAL PHYSICIAN	
<input checked="" type="checkbox"/>	ULTRASOUND - WHOLE ABDOMEN	
<input checked="" type="checkbox"/>	THYROID PROFILE (TOTAL T3, TOTAL T4, TSH)	

WT - 77 kg
HT - 163 cm

Apollo Clinic

Consent Form

Patient Name: PHANINDRA.K Age: 29
UHID Number: CKOR00025766 Company Name: BANK OF BARODA

I Mr/Mrs/Miss: Employee of
(Company) want to inform you that I am not getting the.....
Test which is a part of health check package.

Reason If any: ECHO, ENT, CONSULTATION (FRIDAY)
And I claim the above statement in my full consciousness. 29/03/2024

Patient Signature: [Signature] Date: 23/03/2024



Patient Name	: Mr. KANCHARAPU PHANINDRA	Age	: 29 Y M
UHID	: CKOR.0000252766	OP Visit No	: CKOROPV404638
Reported on	: 23-03-2024 16:42	Printed on	: 23-03-2024 17:28
Adm/Consult Doctor	:	Ref Doctor	: SELF

DEPARTMENT OF RADIOLOGY

X-RAY CHEST PA

Both lungs fields appear normal.

Both hila are normal.

Both costophrenic and cardiophrenic angles are normal.


The cardiac mediastinal shadows appear normal.

Bones and soft tissues appear normal.

IMPRESSION : NORMAL STUDY.

Printed on:23-03-2024 16:42

---End of the Report---


For **Dr. VINOD P JOSEPH**
MBBS, DNB, DMRD
Radiology



Patient Name : Mr Kancharapu Phanindra

Patient ID: 252766

Age : 29 Year(s)

Sex : Male

Referring Doctor : H/C

Date : 23.03.2024

ULTRASOUND ABDOMEN AND PELVIS

FINDINGS:

Liver is normal in size and shows normal echotexture. No biliary dilatation. No focal lesion
CBD is not dilated. **Portal vein** is normal in size, course and calibre.

Gall bladder is normal without evidence of calculi, wall thickening or pericholecystic fluid.

Pancreas to the extent visualized, appears normal in size, contour and echogenicity

Spleen is normal in size, shape, contour and echopattern. No evidence of mass or focal lesions.

Right Kidney is normal in size, position, shape and echopattern. Corticomedullary differentiation is maintained. No evidence of calculi or hydronephrosis.

Left Kidney is normal in size, position, shape and echopattern. Corticomedullary differentiation is maintained. No evidence of calculi or hydronephrosis.

Urinary Bladder is well distended. Wall thickness is normal. No evidence of calculi, mass or mural lesion.

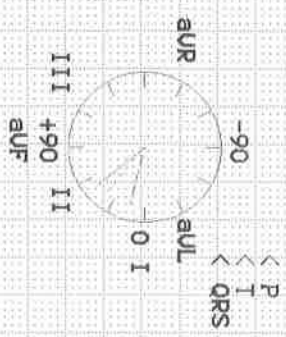
Prostate: normal in size and echotexture.

There is no ascites.

IMPRESSION: NO SIGNIFICANT ABNORMALITIES DETECTED.

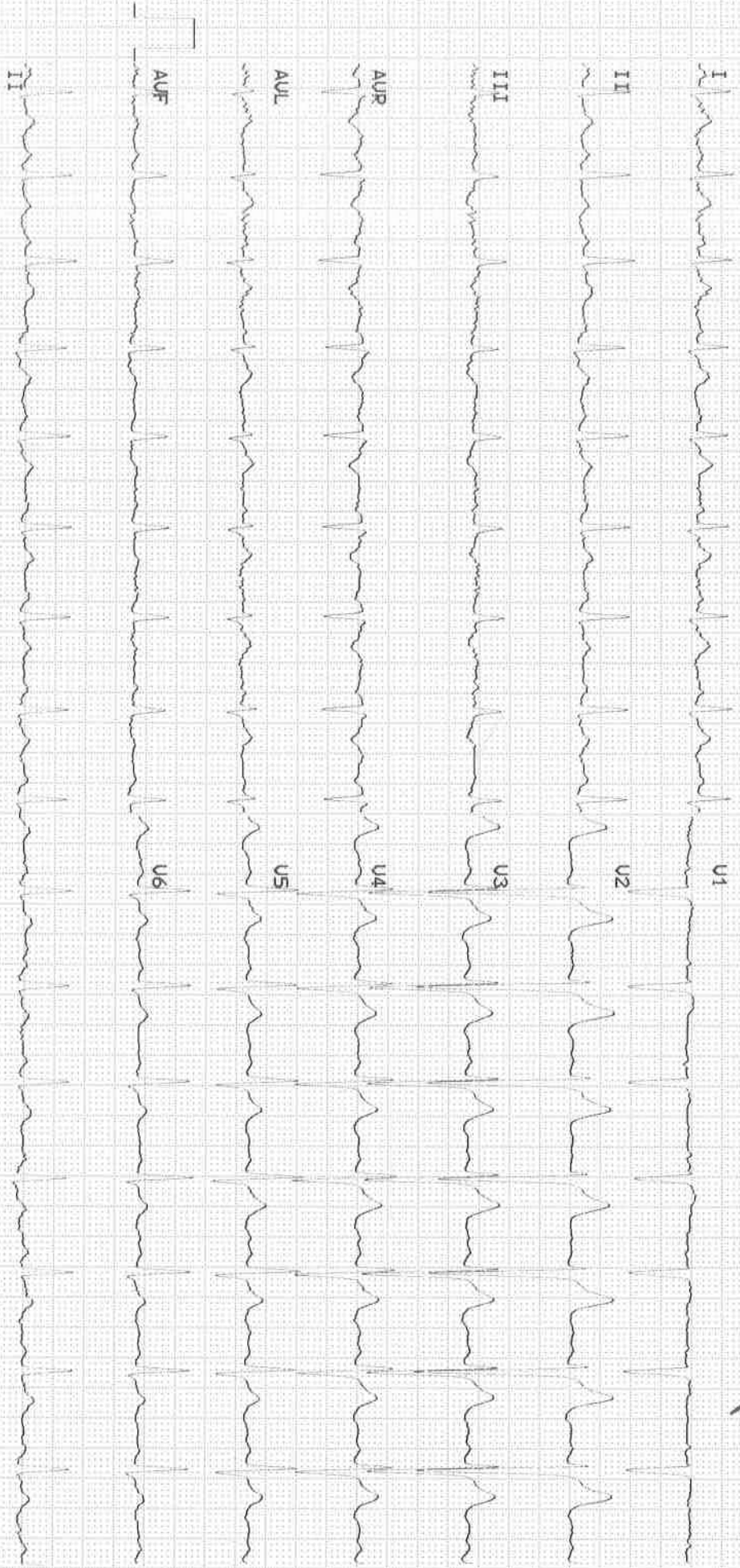
**DR VINOD JOSEPH DNB,DMRD
RADIOLOGIST**

AGE: 29
 Measurement Results:
 QRS : 106 ms
 QT/QTcB : 324 / 415 ms
 PR : 132 ms
 P : 106 ms
 RR/PP : 610 / 595 ms
 P/QRS/T : 40 / 50 / 15 degrees
 QTd/QTcBD : 80 / 102 ms
 Sokolow NK : 1.8 mV
 15



Interpretation: Normal Study.

[Signature]
 Unconfirmed Report.





Patient Name : Mr. KANCHARAPU PHANINDRA
UHID : CKOR.0000252766
Reported By: : Dr. SATHWIK RAJ V A
Referred By : SELF
Age : 29 Y/M
OP Visit No : CKOROPV404638
Conducted Date : 24-03-2024 13:20

ECG REPORT

Observation :-

1. Normal Sinus Rhythm.
2. Heart rate is 98beats per minutes.
3. No pathological Q wave or S-T,T changes seen.
4. Normal P,Q,R,S,T waves and axis.
5. No evidence of chamber, hypertrophy or enlargement seen.

Impression:

NORMAL RESTING ECG.

Dr. SATHWIK RAJ V A
CARDIOLOGIST

NOTE:KINDLY TAKE A PHOTOCOPY OF THE GRAPH
FOR FUTURE REFERENCE IF NEEDED.

----- END OF THE REPORT -----

Original OP Credit Bill

Name	: Mr. KANCHARAPU PHANINDRA	Bill No	: CKOR-OCR-81723
Age/Gender	: 29 Y M	Bill/Reg Date	: 23.03.2024 10:10
Contact No	: +917032323224	Referred by	: SELF
Address	: KMG	Center	: Koramangala
UHID	: CKOR.0000252766	Emp No/Auth Code	: 125067


 * CKOR - 0000252766 *
 ARCOFEMI HEALTHCARE LIMITED

Corporate Name : ARCOFEMI MEDIWHEEL MALE AHC CREDIT PAN INDIA OP AGREEMENT
Plan : ARCOFEMI MEDIWHEEL MALE AHC CREDIT PAN INDIA OP AGREEMENT

#	Department	Service Name	Qty	Rate	Discount	Amount
1	Package Charges	ARCOFEMI - MEDIWHEEL - FULL BODY ANNUAL PLUS MALE - 2D ECHO - PAN INDIA - FY2324	1	2,000.00	0.00	2,000.00

Bill Amount:	2,000.00
Total Discount:	0.00
Net Payment:	0.00
Corporate Due:	2,000.00

Received with thanks: Zero Rupees only

You can download your report from "www.apolloclinic.com" Enter user name as CKOROPV404638 and password as 93154 koramangala

Apollo Health and Lifestyle Limited

 (CIN - U65110TG2000PLC115819)
 Regd. Office: 1-10/60/62, Ashoka Raghupathi Chambers, 5th Floor, Begumpet, Hyderabad, Telangana - 500 016 | Email ID: enquiry@apollohl.com
 Ph No: 040-4904 7777, Fax No: 4904 7744

APOLLO CLINICS NETWORK

Telangana: Hyderabad (AS Rao Nagar | Chanda Nagar | Kondapur | Nallakurita | Nizampet | Manikonda | Uppal) | Andhra Pradesh: Vizag (Seethamma Peta) | Karnataka: Bangalore (Basavanagudi | Bellandur | Electronics City | Fraser Town | HSR | Jayanagar | Indira Nagar | JP Nagar | Kundalahalli | Koramangala | Sarjapur Road) | Mysore (VV Mohalla) | Tamil Nadu: Chennai (Ann Nagar | Kotturpuram | Mogappair | T Nagar | Valasaravakkam) | Velachery | Maharashtra: Pune (Aundh | Nigdi | Pradhikaran) | Wiman Nagar | Wanowrie | Uttar Pradesh: Ghaziabad (Indrapuram) | Gujarat: Ahmedabad (Satellite) | Punjab: Amritsar (Court Road) | Haryana: Faridabad (Railway Station Road)

 **1860 500 7788**

Issue Date: 09/01/2012



Government of India



కంచారపు ఫణింద్ర
Kancharapu Phanindra
పుట్టిన తేదీ / DOB: 15/09/1994
పురుషుడు / Male

3261 0987 5007

సేరా ఆధార్, సేరా పఠచాన



Your appointment is confirmed

noreply@apolloclinics.info <noreply@apolloclinics.info>

Thu 21-03-2024 18:47

To:k.phanindra026@gmail.com <k.phanindra026@gmail.com >

Cc:Koramangala Apolloclinic <koramangala@apolloclinic.com>;Saim Qamar <saim.qamar@apolloclinic.com>;Syamsunder M <syamsunder.m@apollohl.com >

Dear MR. KANCHARAPU PHANINDRA,

Greetings from Apollo Clinics,

Your corporate health check appointment is confirmed at **KORAMANGALA** clinic on **2024-03-23** at **08:15-08:30**.

Payment Mode	
Corporate Name	ARCOFEMI HEALTHCARE LIMITED
Agreement Name	[ARCOFEMI MEDIWHEEL MALE AHC CREDIT PAN INDIA OP AGREEMENT]
Package Name	[ARCOFEMI - MEDIWHEEL - FULL BODY ANNUAL PLUS MALE - 2D ECHO - PAN INDIA - FY2324]

"Kindly carry with you relevant documents such as HR issued authorization letter and or appointment confirmation mail and or valid government ID proof and or company ID card and or voucher as per our agreement with your company or sponsor."

Note: Video recording or taking photos inside the clinic premises or during camps is not allowed and would attract legal consequences.

Note: Also once appointment is booked, based on availability of doctors at clinics tests will happen, any pending test will happen based on doctor availability and clinics will be updating the same to customers.

Instructions to be followed for a health check:

1. Please ensure you are on complete fasting for 10-To-12-Hours prior to check.
2. During fasting time do not take any kind of alcohol, cigarettes, tobacco or any other liquids (except Water) in the morning. If any medications taken, pls inform our staff before health check.
3. Please bring all your medical prescriptions and previous health medical records with you.
4. Kindly inform our staff, if you have a history of diabetes and cardiac problems.

For Women:

Patient Name	: Mr. KANCHARAPU PHANINDRA	Age	: 29 Y/M
UHID	: CKOR.0000252766	OP Visit No	: CKOROPV404638
Reported By:	: Dr. SATHWIK RAJ V A	Conducted Date	: 24-03-2024 13:20
Referred By	: SELF		

ECG REPORT

Observation :-

1. Normal Sinus Rhythm.
2. Heart rate is 98beats per minutes.
3. No pathological Q wave or S-T,T changes seen.
4. Normal P,Q,R,S,T waves and axis.
5. No evidence of chamber, hypertrophy or enlargement seen.

Impression:

NORMAL RESTING ECG.

Dr. SATHWIK RAJ V A
CARDIOLOGIST

NOTE:KINDLY TAKE A PHOTOCOPY OF THE GRAPH
FOR FUTURE REFERENCE IF NEEDED.

Patient Name	: Mr. KANCHARAPU PHANINDRA	Age	: 29 Y/M
UHID	: CKOR.0000252766	OP Visit No	: CKOROPV404638
Reported By:	: Dr. SATHWIK RAJ V A	Conducted Date	: 24-03-2024 13:20
Referred By	: SELF		

----- END OF THE REPORT -----

Patient Name	: Mr. KANCHARAPU PHANINDRA	Age/Gender	: 29 Y/M
UHID/MR No.	: CKOR.0000252766	OP Visit No	: CKOROPV404638
Sample Collected on	:	Reported on	: 23-03-2024 17:06
LRN#	: RAD2279049	Specimen	:
Ref Doctor	: SELF		
Emp/Auth/TPA ID	: 125067		

DEPARTMENT OF RADIOLOGY

ULTRASOUND - WHOLE ABDOMEN

Liver is normal in size and shows normal echotexture. No biliary dilatation. No focal lesion
CBD is not dilated. **Portal vein** is normal in size, course and calibre.

Gall bladder is normal without evidence of calculi, wall thickening or pericholecystic fluid.

Pancreas to the extent visualized, appears normal in size, contour and echogenicity

Spleen is normal in size, shape, contour and echopattern. No evidence of mass or focal lesions.

Right Kidney is normal in size, position, shape and echopattern. Corticomedullary differentiation is maintained. No evidence of calculi or hydronephrosis.

Left Kidney is normal in size, position, shape and echopattern. Corticomedullary differentiation is maintained. No evidence of calculi or hydronephrosis.

Urinary Bladder is well distended. Wall thickness is normal. No evidence of calculi, mass or mural lesion.

Prostate: normal in size and echotexture.

There is no ascites.

IMPRESSION: NO SIGNIFICANT ABNORMALITIES DETECTED.



Patient Name : Mr. KANCHARAPU PHANINDRA

Age/Gender : 29 Y/M

DR VINOD JOSEPH DNB,DMRD
RADIOLOGIST

Dr. VINOD P JOSEPH
MBBS, DNB, DMRD
Radiology

Patient Name : Mr. KANCHARAPU PHANINDRA

Age/Gender : 29 Y/M

UHID/MR No. : CKOR.0000252766

OP Visit No : CKOROPV404638

Sample Collected on :

Reported on : 23-03-2024 16:42

LRN# : RAD2279049

Specimen :

Ref Doctor : SELF

Emp/Auth/TPA ID : 125067

DEPARTMENT OF RADIOLOGY

X-RAY CHEST PA

Both lungs fields appear normal.

Both hila are normal.

Both costophrenic and cardiophrenic angles are normal.

The cardiac mediastinal shadows appear normal.

Bones and soft tissues appear normal.

IMPRESSION : NORMAL STUDY.

Dr. VINOD P JOSEPH
MBBS, DNB, DMRD
Radiology

Name: Mr. KANCHARAPU PHANINDRA
Age/Gender: 29 Y/M
Address: KMG
Location: BANGALORE, KARNATAKA
Doctor:
Department: GENERAL
Rate Plan: KORAMANGALA_06042023
Sponsor: ARCOFEMI HEALTHCARE LIMITED
Consulting Doctor: Dr. GAZALA ANJUM

MR No: CKOR.0000252766
Visit ID: CKOROPV404638
Visit Date: 23-03-2024 10:09
Discharge Date:
Referred By: SELF

HT-CHIEF COMPLAINTS AND PRESENT KNOWN ILLNESS

SYSTEMIC REVIEW

****Weight**

--->: **Stable,**

HT-HISTORY

Past Medical History

PAST MEDICAL HISTORY: Nil,

Cancer: **no,

PHYSICAL EXAMINATION

SYSTEMIC EXAMINATION

IMPRESSION

RECOMMENDATION

DISCLAIMER

Disclaimer: **The health checkup examinations and routine investigations have certain limitations and may not be able to detect all the diseases. Any new or persisting symptoms should be brought to the attention of the consulting physician. Additional tests, consultations and follow up may be required in some cases.,**

Doctor's Signature

Name: Mr. KANCHARAPU PHANINDRA
Age/Gender: 29 Y/M
Address: KMG
Location: BANGALORE, KARNATAKA
Doctor:
Department: GENERAL
Rate Plan: KORAMANGALA_06042023
Sponsor: ARCOFEMI HEALTHCARE LIMITED
Consulting Doctor: Dr. RINITHA RAJAN

MR No: CKOR.0000252766
Visit ID: CKOROPV404638
Visit Date: 23-03-2024 10:09
Discharge Date:
Referred By: SELF

HT-CHIEF COMPLAINTS AND PRESENT KNOWN ILLNESS

SYSTEMIC REVIEW

**Weight

--->: Stable,

HT-HISTORY

Past Medical History

PAST MEDICAL HISTORY: Nil,

**Cancer: no,

PHYSICAL EXAMINATION

SYSTEMIC EXAMINATION

IMPRESSION

RECOMMENDATION

DISCLAIMER

Disclaimer: The health checkup examinations and routine investigations have certain limitations and may not be able to detect all the diseases. Any new or persisting symptoms should be brought to the attention of the consulting physician. Additional tests, consultations and follow up may be required in some cases.,

Doctor's Signature

Name: Mr. KANCHARAPU PHANINDRA
Age/Gender: 29 Y/M
Address: KMG
Location: BANGALORE, KARNATAKA
Doctor:
Department: GENERAL
Rate Plan: KORAMANGALA_06042023
Sponsor: ARCOFEMI HEALTHCARE LIMITED
Consulting Doctor: Dr. MAHABALESWAR

MR No: CKOR.0000252766
Visit ID: CKOROPV404638
Visit Date: 23-03-2024 10:09
Discharge Date:
Referred By: SELF

Doctor's Signature

Name: Mr. KANCHARAPU PHANINDRA
Age/Gender: 29 Y/M
Address: KMG
Location: BANGALORE, KARNATAKA
Doctor:
Department: GENERAL
Rate Plan: KORAMANGALA_06042023
Sponsor: ARCOFEMI HEALTHCARE LIMITED
Consulting Doctor: Dr. VIJAYA LAKSHMI M

MR No: CKOR.0000252766
Visit ID: CKOROPV404638
Visit Date: 23-03-2024 10:09
Discharge Date:
Referred By: SELF

Doctor's Signature