

REDIUS

DIAGNOSTICS



Medical Form & EYE CHECK UP

Demographic Information:

| | | | | | |
|------|---|------------------|------|---|----------|
| Name | : | Ranjanben Parekh | Date | : | 29/03/24 |
| Age | : | 55 | | | |
| Sex | : | F | | | |

VITALS CHECKUP

| | | | | | |
|----------------|----|--------|------------------|----|---------------|
| Blood Pressure | :- | 130/90 | HEIGHT [IN CM] | :- | 143 |
| Heart Rate | :- | 80 | Weight (in Kgs) | :- | 63 |
| Spo2 | :- | 99% | BMI VALUE | :- | 30.8 |
| PULSE | :- | 78 | BMI STATUS | :- | Obese class 1 |

HISTORY

| | |
|---------------------------|-------------------------------|
| Current Health Complaints | Asthma |
| Past History | NO |
| Family History | NO |
| Allergies | Dust - humidity in Atmosphere |
| Ongoing Medication | NO |

Any other problems needing attention / Overall Assessment :

REMARKS :-

(2)

EYE TEST

1. VISION :-

A. NEAR VISION

RIGHT EYE :- (2) with
LEFT EYE :- (2) specs

B. DISTANCE VISION

RIGHT EYE :- 6/
LEFT EYE :- 6/

2. COLOR VISION :-

RIGHT EYE :- (2)
LEFT EYE :- (2)

3. NIGHT VISION :-

RIGHT EYE :- (2)
LEFT EYE :- (2)

REMARKS :- NAD

DOCTOR SIGN

Dr. Chirag Patel
M.B.B.S. G-49432

Revival Diagnostic
401, Aqua Corridor,
B/s. Star Bazar, Surat-395009
Mo. 91062-28601

0261-2747788, 9825947712

4th FLOOR, AQUA CORRIDOR, BESIDE STAR BAZAR ADAJAN 395009



rediusdiagnostics@gmail.com

REVIVAL

DIAGNOSTICS



Dental Checkup

Patient Name: - Ranjanben Parekh

Age: - 55 Sex: - F

Past Medical History

1) Smoking 2) Alcohol 3) Hepatitis B & C 4) Diabetics 6) Tobacco 5) Allergy 6) Asthma

7) Any Other: NO

PDH: - Tooth Extraction + Implant

O/E: - Lower - Both side molar teeth Implant.

Investigation: NO

Treatment: - NO

Doctor's Sign and Stamp

Consent Form:

I, Ranjanben Parekh have given true & total information to the dentist regarding past & present illness as well as ongoing medical treatment. I have been fully informed regarding treatment for present illness. Along with benefit & possible risk from medicines / Surgery / Anesthetic drugs to be used by the dentist in my own understanding language. I hereby willingly permit the dentist to undertake the treatment or surgical intervention.

Patient Signature: Zorava

Revival Diagnostic
401, Aqua Corridor,
B/s. Star Bazar, Surat-395009
Mo. 91062-28601





REVIVAL DIAGNOSTICS

| | | | |
|-----------------|--|----------------------|-----------------------------|
| Name | MRS. PAREKH RANJANBEN DEVESHBHAI | Age/Gender | 55Yrs/Female |
| Reg No. | 3117/24 | Receipt No | 19290 |
| Referred By | Bank of Baroda (BOB) - MEDI WHEEL() | Mode of Payment | CREDIT |
| Collection Type | CENTER | Collection Date/Time | 29-Mar-2024 08:32 AM |

BLOOD GROUP - 290324153 Released at 29-Mar-2024 01:05 PM

| Parameter | Result | Biological Ref.Range | Method |
|--------------|----------|----------------------|--------|
| -Blood Group | "O" | | |
| -Rh Factor | POSITIVE | | |

CBC - 290324153 Released at 29-Mar-2024 10:45 AM

| Parameter | Result | Biological Ref.Range | Method |
|------------------|----------------|-----------------------|--------|
| -Haemoglobin | 12.5 gm/dL | (12 - 16 gm/dL) | Auto |
| -RBC Count | 4.73 mill/cumm | (4.2 - 5.4 mill/cumm) | Auto |
| -Total WBC Count | 5400 /cumm | (4000 - 10000 /cumm) | Auto |
| -Platelet Count | 2.70 lakh/cumm | (1.5 - 4.5 lakh/cumm) | Auto |

Blood Indices

| | | | |
|-------|-------------------|--------------------------|------|
| -HCT | 40.4 % | (40 - 55 %) | Auto |
| -MCV | 85.3 fl | (80 - 92 fl) | Auto |
| -MCH | 26.5 pg | L (27 - 31 pg) | Auto |
| -MCHC | 31.0 gm/dL | L (32 - 36 gm/dL) | Auto |
| -RDW | 14.1 % | (11 - 15 %) | Auto |

Diff WBC Count

| | | | |
|---------------------|---------------------------------|-------------|-----------------|
| -Polymorphs | 65 % | (40 - 80 %) | Microscopically |
| -Lymphocytes | 30 % | (20 - 40 %) | Microscopically |
| -Eosinophils | 03 % | (1 - 6 %) | Microscopically |
| -Monocytes | 02 % | (2 - 7 %) | Microscopically |
| -Basophils | 00 % | (0 - 1 %) | Microscopically |
| -PLATELET ON SMEAR | Adequate | | Microscopically |
| -MALARIAL PARASITES | Malarial Parasites Not Detected | | Microscopically |

[Test performed on Fully Automated Hematology Analyzer ERBA H-360]

Revival Diagnostics
401-Aqua Corridor,
Beside Star Bazar, Adajan,
Surat-395009. Mo. 9825947717

Sg

Dr. Shivangi Gandhi
M.B.B.S, M.D (Pathology)

☎ 0261-2747788, 98259 47712

📍 4th Floor, Aqua Corridor, Hazira Road, Adajan Pal, Surat - 395009.

✉ revivaldiagnostics.surat@gmail.com

🌐 www.revivaldiagnostics.com



REVIVAL DIAGNOSTICS

| | | | |
|-----------------|--|---------------------|----------------------|
| Name | MRS. PAREKH RANJANBEN DEVESHBHAI | Age/Gender | 55Yrs/Female |
| Reg No. | 3117/24 | Receipt No | 19290 |
| Referred By | Bank of Baroda (BOB) - MEDI WHEEL() | Mode of Payment | CREDIT |
| Collection Type | CENTER | Collection DateTime | 29-Mar-2024 08:32 AM |

ESR - 290324153 Released at 29-Mar-2024 11:01 AM

| Parameter | Result | Biological Ref.Range | Method |
|-----------|----------|----------------------|--------|
| -E.S.R | 06 mm/hr | (3 - 15 mm/hr) | |


Revival Diagnostics
401-Aqua Corridor,
Beside Star Bazar, Adajan,
Surat-395009. Mo. 9825947712

☎ 0261-2747788, 98259 47712

📍 4th Floor, Aqua Corridor, Hazira Road, Adajan Pal, Surat - 395009.

✉ revivaldiagnostics.surat@gmail.com

🌐 www.revivaldiagnostics.com


Dr. Shivangi Gandhi
M.B.B.S, M.D (Pathology)



REVIVAL DIAGNOSTICS

| | | | |
|-----------------|--|----------------------|-----------------------------|
| Name | MRS. PAREKH RANJANBEN DEVESHBHAI | Age/Gender | 55Yrs/Female |
| Reg No. | 3117/24 | Receipt No | 19290 |
| Referred By | Bank of Baroda (BOB) - MEDI WHEEL() | Mode of Payment | CREDIT |
| Collection Type | CENTER | Collection Date/Time | 29-Mar-2024 08:32 AM |

FBS & PPBS - 290324154 Released at 29-Mar-2024 04:02 PM

| Parameter | Result | Biological Ref. Range | Method |
|----------------------------|------------------|---|--------|
| -Fasting Blood Sugar (FBS) | 102 mg/dL | H 70-100 mg/dl Impaired Tolerance: 100-125 Diabetes Mellitus: \geq 126 (American diabetes association guidelines 2022) | |
| -Fasting Urine Sugar | Absent | | |
| -Fasting Urine Acetone | Absent | | |
| -PPBS | 121 mg/dL | (90 - 140 mg/dL) | |
| -PP2BS URINE SUGAR | Absent | | |
| -PP2BS URINE ACETONE | Absent | | |

Revival Diagnostics

401-Aqua Corridor,
Beside Star Bazar, Adajan,
Surat-395009. Mo. 9825947712

Dr. Shivangi Gandhi
M.B.B.S, M.D (Pathology)

☎ 0261-2747788, 98259 47712

📍 4th Floor, Aqua Corridor, Hazira Road, Adajan Pal, Surat - 395009.

@ revivaldiagnostics.surat@gmail.com

🌐 www.revivaldiagnostics.com



REVIVAL DIAGNOSTICS

| | | | |
|-----------------|--|----------------------|-----------------------------|
| Name | MRS. PAREKH RANJANBEN DEVESHBHAI | Age/Gender | 55Yrs/Female |
| Reg No. | 3117/24 | Receipt No | 19290 |
| Referred By | Bank of Baroda (BOB) - MEDI WHEEL() | Mode of Payment | CREDIT |
| Collection Type | CENTER | Collection Date/Time | 29-Mar-2024 08:32 AM |

LIVER FUNCTION TEST (LFT) - 290324155 Released at 29-Mar-2024 03:03 PM

| Parameter | Result | Biological Ref.Range | Method |
|---------------------------|------------|----------------------|---|
| -Serum Total Bilirubin | 0.4 mg/dL | (0 - 1.3 mg/dL) | Diazo |
| -Serum Direct Bilirubin | 0.1 mg/dL | (0 - 0.4 mg/dL) | Diazo |
| -Serum InDirect Bilirubin | 0.3 mg/dL | (0.1 - 1.3 mg/dL) | Calculated |
| -Total Protein (TP) | 7.1 gm/dL | (6.4 - 8.3 gm/dL) | Biuret |
| -Albumin (ALB) | 4.1 gm/dL | (3.5 - 5.2 gm/dL) | BCG |
| -Globulin | 3.0 gm/dL | (2.3 - 3.6 gm/dL) | Calculated |
| -A/G Ratio | 1.37 gm/dL | (1 - 2.3 gm/dL) | Calculated |
| -SGPT(ALT) | 16 U/L | (5 - 45 U/L) | IFCC, Kinetic without Pyridoxal Phosphate |
| -SGOT (AST) | 19 U/L | (0 - 35 U/L) | IFCC, Without Pyridoxal Phosphate |
| -Alkaline Phosph. | 89 U/L | (42 - 128 U/L) | ALP-AMP |
| -GGT | 22 U/L | (5 - 50 U/L) | Glupa-C |

[Test performed on Fully Automated Biochemistry Analyzer ERBA EM200]

Revival Diagnostics

401-Aqua Corridor,
Beside Star Bazar, Adajan,
Surat-395009. Mo. 9825947712

Dr. Shivangi Gandhi
M.B.B.S, M.D (Pathology)

0261-2747788, 98259 47712

4th Floor, Aqua Corridor, Hazira Road, Adajan Pal, Surat - 395009.

revivaldiagnostics.surat@gmail.com

www.revivaldiagnostics.com



REVIVAL DIAGNOSTICS

| | | | |
|-----------------|--|---------------------|----------------------|
| Name | MRS. PAREKH RANJANBEN DEVESHBHAI | Age/Gender | 55Yrs/Female |
| Reg No. | 3117/24 | Receipt No | 19290 |
| Referred By | Bank of Baroda (BOB) - MEDI WHEEL() | Mode of Payment | CREDIT |
| Collection Type | CENTER | Collection DateTime | 29-Mar-2024 08:32 AM |

Creatinine - 290324155 Released at 29-Mar-2024 03:04 PM

| Parameter | Result | Biological Ref.Range | Method |
|-------------|-----------|----------------------|-----------|
| -Creatinine | 0.6 mg/dL | (0.6 - 1.14 mg/dL) | ENZYMATIC |

BUN - 290324155 Released at 29-Mar-2024 11:52 AM

| Parameter | Result | Biological Ref.Range | Method |
|----------------------------|----------|----------------------|------------|
| -Blood Urea Nitrogen (BUN) | 11 mg/dL | (6 - 20 mg/dL) | Calculated |

Uric Acid - 290324155 Released at 29-Mar-2024 03:04 PM

| Parameter | Result | Biological Ref.Range | Method |
|------------|-----------|----------------------|-------------|
| -Uric Acid | 5.5 mg/dL | (3.5 - 7.2 mg/dL) | Uricase-POD |

Revival Diagnostics

401-Aqua Corridor,
Beside Star Bazar, Adajan,
Surat-395009. Mo. 9825947712

Dr. Shivangi Gandhi
M.B.B.S, M.D (Pathology)

📞 0261-2747788, 98259 47712

📍 4th Floor, Aqua Corridor, Hazira Road, Adajan Pal, Surat - 395009.

✉️ revivaldiagnostics.surat@gmail.com

🌐 www.revivaldiagnostics.com



REVIVAL DIAGNOSTICS

| | | | |
|-----------------|--|---------------------|-----------------------------|
| Name | MRS. PAREKH RANJANBEN DEVESHBHAI | Age/Gender | 55Yrs/Female |
| Reg No. | 3117/24 | Receipt No | 19290 |
| Referred By | Bank of Baroda (BOB) - MEDI WHEEL() | Mode of Payment | CREDIT |
| Collection Type | CENTER | Collection DateTime | 29-Mar-2024 08:32 AM |

Lipid Profile - 290324155 Released at 29-Mar-2024 03:04 PM

| Parameter | Result | Biological Ref.Range | Method |
|---------------------|-----------|---|---------------------------------------|
| -Serum Cholesterol | 223 mg/dL | Desirable < 200 mg/dl Borderline High : 200-239 mg/dl High : > 240 mg/dl | CHOD-PAP |
| -Serum Triglyceride | 115 mg/dL | Normal < 150 mg/dl Borderline High : 150 - 199 mg/dl High : 200 - 499 mg/dl Very High : 500 mg/dl | GPO-POD Method |
| -Serum HDLD(Direct) | 47 mg/dL | Normal :> 55 mg/dl Borderline : 35-55 mg/dl Undesirable: < 35 mg/dl | PVS-PEGME Precipitation with CHOD-POD |
| -Serum VLDL | 23 mg/dL | (5 - 30 mg/dL) | Calculated |
| -Serum LDL(Direct) | 153 mg/dL | Optimal:< 100 mg/dl Above Optimal : 100- 129 mg/dl Borderline High : 130-159 mg/dl High : > 160-189mg/dl Very High : >190 mg/dl | Calculated |
| -Chol/HDL | 4.74 | Low risk: <3.8 Medium Risk: 3.8 to 5.9 High Risk: > 6 | Calculated |
| -LDL/Chol | 1.46 | Low risk: <3.55 Medium Risk: 3.55 to 4.0 High Risk: > 6 | Calculated |

[Test performed on Fully Automated Biochemistry Analyzer ERBA EM200]

Revival Diagnostics

401-Aqua Corridor,
Beside Star Bazar, Adajan,
Surat-395009. Mo. 9825947712

Dr. Shivangi Gandhi
M.B.B.S, M.D (Pathology)

0261-2747788, 98259 47712

4th Floor, Aqua Corridor, Hazira Road, Adajan Pal, Surat - 395009.

revivaldiagnostics.surat@gmail.com

www.revivaldiagnostics.com



REVIVAL DIAGNOSTICS

| | | | |
|-----------------|-------------------------------------|---------------------|----------------------|
| Name | MRS. PAREKH RANJANBEN DEVESHBHAI | Age/Gender | 55Yrs/Female |
| Reg No. | 3117/24 | Receipt No | 19290 |
| Referred By | Bank of Baroda (BOB) - MEDI WHEEL() | Mode of Payment | CREDIT |
| Collection Type | CENTER | Collection DateTime | 29-Mar-2024 08:32 AM |

Urine Routine & Micro Examination - 290324157 Released at 29-Mar-2024 01:15 PM

| Parameter | Result | Biological Ref.Range | Method |
|--------------------------------|-------------|----------------------|-------------------------|
| Physical Examination | | | |
| -Quantity | 30 | | Manual |
| -Colour | Pale Yellow | Pale Yellow | Manual |
| -Appearance | Clear | Clear | Manual |
| -Reaction (pH) | Acidic | | Dipstick |
| -Specific Gravity | 1.030 | | Dipstick |
| Chemical Examination | | | |
| -Proteins. | Absent | | Dipstick |
| -Sugar | Absent | | Dipstick |
| -Acetone. | Absent | | Dipstick |
| -Bile Salts | Absent | Absent | Dipstick |
| -Bile Pigments | Absent | Absent | Dipstick |
| -Occult Blood Test (OBT). | Negative | | Dipstick |
| Microscopic Examination | | | |
| -Pus Cells | Occasional | | Microscopically |
| -Red Blood Cells | Absent | | Microscopically |
| -Epithelial Cells | Occasional | | Microscopically |
| -Bacteria. | Absent | | Microscopically |
| -Crystals | Absent | Absent | Microscopically |
| -Others | NIL | Absent | Microscopic Examination |

Revival Diagnostics

401-Aqua Corridor,
Beside Star Bazar, Adajan,
Surat-395009. Mo. 9825947712

Dr. Shivangi Gandhi
M.B.B.S, M.D (Pathology)

0261-2747788, 98259 47712

4th Floor, Aqua Corridor, Hazira Road, Adajan Pal, Surat - 395009.

revivaldiagnostics.surat@gmail.com

www.revivaldiagnostics.com



REVIVAL DIAGNOSTICS

| | | | |
|-----------------|--|---------------------|-----------------------------|
| Name | MRS. PAREKH RANJANBEN DEVESHBHAI | Age/Gender | 55Yrs/Female |
| Reg No. | 3117/24 | Receipt No | 19290 |
| Referred By | Bank of Baroda (BOB) - MEDI WHEEL() | Mode of Payment | CREDIT |
| Collection Type | CENTER | Collection DateTime | 29-Mar-2024 08:32 AM |

Total T3 T4 TSH - 290324155 Released at 29-Mar-2024 12:50 PM

| Parameter | Result | Biological Ref.Range | Method |
|-----------|-------------|---|---------------------------------|
| -Total T3 | 0.95 ng/ml | (0.87 - 1.78 ng/ml) | Fluorescence Enzyme Immunoassay |
| -Total T4 | 7.12 ug/dl | (4.6 - 11 ug/dl) | Fluorescence Enzyme Immunoassay |
| -TSH | 1.90 uIU/ml | 0.50 - 5.50 uIU/ml 5.5 to 15 ul U/ml - Suggested Clinical co-relation or Repeat test with new sample as physiological factors can give falsely high TSH Above 15uIU/ml Hypothyroid PREGNANT WOMEN normal ranges for TSH: 1st Trimester : 0.0878 - 2.8293 uIU/ml 2nd Trimester : 0.1998 - 2.7915 uIU/ml 3rd Trimester : 0.307 - 2.9028 uIU/ml Ref: TIETZ Fundamentals of Clinical Chemistry | Fluorescence Enzyme Immunoassay |

[Test performed on Fully Automated Immunology Analyzer Maglumi-600]

Revival Diagnostics

401-Aqua Corridor,
Beside Star Bazar, Adajan,
Surat-395009. Mo. 9825947712

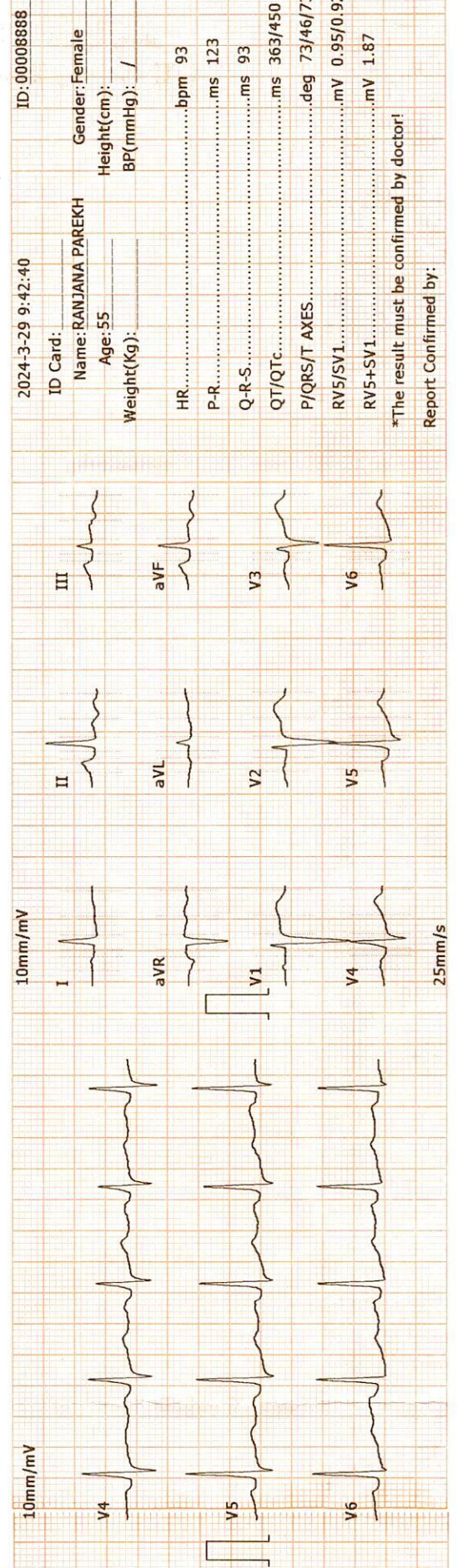
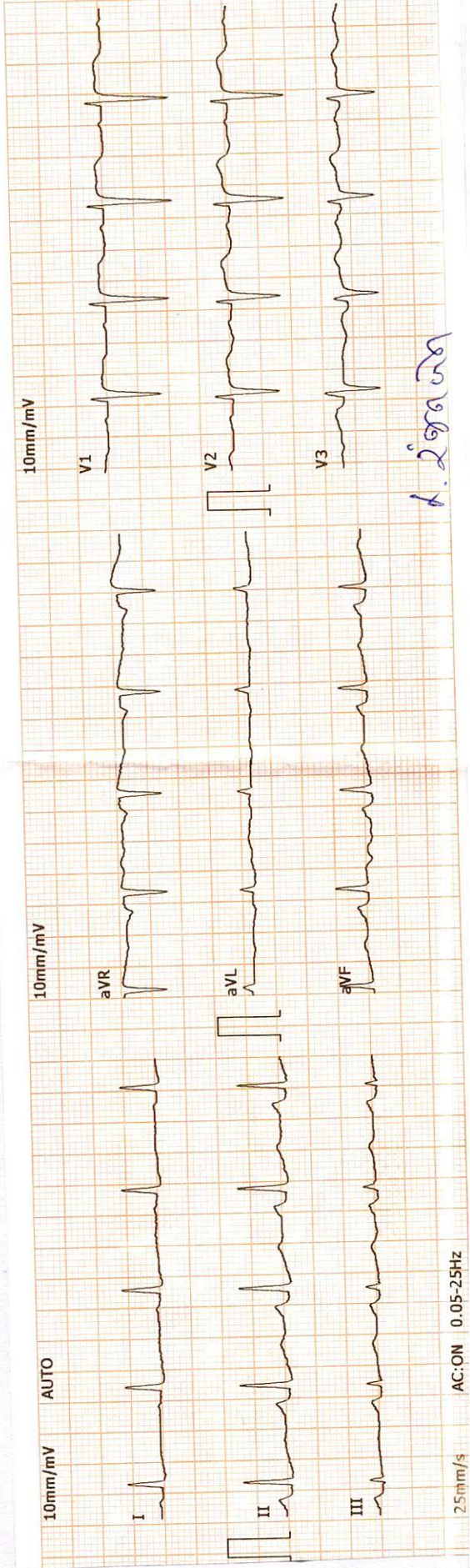
Dr. Shivangi Gandhi
M.B.B.S, M.D (Pathology)

0261-2747788, 98259 47712

4th Floor, Aqua Corridor, Hazira Road, Adajan Pal, Surat - 395009.

revivaldiagnostics.surat@gmail.com

www.revivaldiagnostics.com



2024-3-29 9:42:40 ID: 00008688
 ID Card: Name: RANJANA PAREKH Gender: Female
 Age: 55 Height(cm):
 Weight(Kg): BP(mmHg): /
 HR: bpm 93
 P-R: ms 123
 Q-R-S: ms 93
 QT/QTc: ms 363/450
 P/QRS/T AXES: deg 73/46/73
 RV5/SV1: mV 0.95/0.92
 RV5+SV1: mV 1.87
 *The result must be confirmed by doctor!
 Report Confirmed by:

Revival Diagnostics
 401-Aqua Corridor,
 Beside Star Bazar, Adajan,
 Surat-395009. Mo. 9825947712

DR. ADITYA PANDRA
 MBBS, DNB (CC)
 PHYSICIAN & CLINICAL CARDIOLOGIST
 G-54906



REVIVAL DIAGNOSTICS

| | | | |
|-----------------|--|---------------------|----------------------|
| Name | MRS. PAREKH RANJANBEN DEVESHBHAI | Age/Gender | 55Yrs/Female |
| Reg No. | 3117/24 | Receipt No | 19290 |
| Referred By | Bank of Baroda (BOB) - MEDI WHEEL() | Mode of Payment | CREDIT |
| Collection Type | CENTER | Collection DateTime | 29-Mar-2024 08:04 AM |

Ecg

1. The rhythm is sinus.
2. Heart rate is 93 beats per minute.
3. Normal P,QRS,T wave axis.
4. Normal PR,QRS,Q.T. Duration.
5. No pathological q wave or ST-T changes seen.
6. No evidence of chamber hypertrophy or enlargement seen.

IMPRESSION : ECG WITHIN NORMAL LIMITS

Revival Diagnostics
401-Aqua Corridor,
Beside Star Bazar, Adajan,
Surat-395009. Mo. 9825947712

DR. ADITYA S. BORA
MBBS, DNB, *Signature*
PHYSICIAN & CLINICAL CARDIOLOGIST
G-54906

0261-2747788, 98259 47712

4th Floor, Aqua Corridor, Hazira Road, Adajan Pal, Surat - 395009.

revivaldiagnostics.surat@gmail.com

www.revivaldiagnostics.com



REVIVAL DIAGNOSTICS

| | | | |
|-----------------|--|---------------------|----------------------|
| Name | MRS. PAREKH RANJANBEN DEVESHBHAI | Age/Gender | 55Yrs/Female |
| Reg No. | 3117/24 | Receipt No | 19290 |
| Referred By | Bank of Baroda (BOB) - MEDI WHEEL() | Mode of Payment | CREDIT |
| Collection Type | CENTER | Collection DateTime | 29-Mar-2024 08:04 AM |

2D ECHO

2D ECHOCARDIOGRAPHY & COLOR DOPPLER REPORT

INDICATION: Preventive Health check up

- **CARDIAC CHAMBERS :** Left Ventricle : Normal size , Left Atrium: Normal size.
- NO e/o thrombus in LA/LV
- Right Atrium: Normal size. Right Ventricle: Normal Size,
- **Normal Right Ventricular function.** (TAPSE=20mm)
- **Normal Left Ventricular systolic function.** LVEF = 60%
- **No regional wall abnormality. No thinning / scarring / dyskinesia of LV wall**
- **No Left Ventricular Hypertrophy.** (IVSd= 10 mm),
- **LV Compliance:**
- **NO Left Ventricular Diastolic Dysfunction [LVDD].**

VALVES :

- Structurally Normal Mitral valve/ Aortic valve/Tricuspid valve/ Pulmonary valve .
- No significant Valvular Stenosis
- **Doppler findings: AV max = 1.23 m/s, PV max = 0.91 m/s.**
- Trivial MR, Trivial Tricuspid regurgitation.
- **No Pulmonary Arterial Hypertension. PASP** by TRjet vel.method = 24 mmHg.
- **SEPTAE:** IAS / IVS Appear Intact.
- **IVC :** Normal in dimension and shows good inspiratory 13mm collapse.
- **OTHERS:** No e/o Pericardial effusion / vegetation.

IMPRESSION:

**NORMAL LV SYSTOLIC FUNCTION, LVEF= 60 %, NO RWMA,
NO LVH , NO LVDD , NO PAH.**

Revival Diagnostics
401-Aqua Corridor,
Beside Star Bazar, Adajan,
Surat-395009. Mo. 9825947712

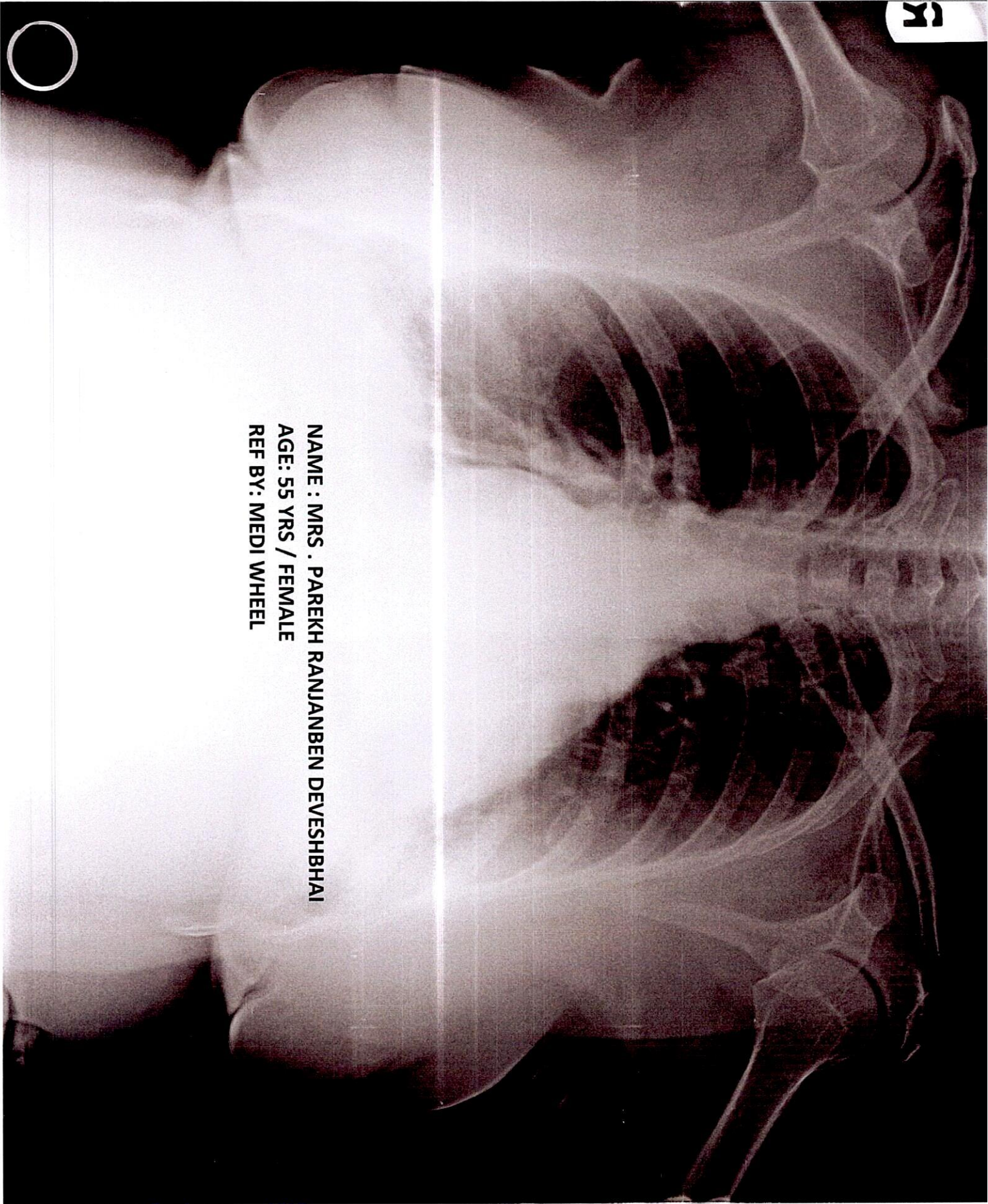
DR. ADITYA S. BOBA
MBBS, DNB, FCCP
PHYSICIAN & CLINICAL CARDIOLOGIST
G-54906
Signature

0261-2747788, 98259 47712

4th Floor, Aqua Corridor, Hazira Road, Adajan Pal, Surat - 395009.

revivaldiagnostics.surat@gmail.com

www.revivaldiagnostics.com



R

NAME : MRS . PAREKH RANJANBEN DEVESHBHAI
AGE: 55 YRS / FEMALE
REF BY: MEDI WHEEL





REVIVAL

DIAGNOSTICS

| | | | |
|-----------------|-------------------------------------|---------------------|----------------------|
| Name | MRS. PAREKH RANJANBEN DEVESHBHAI | Age/Gender | 55Yrs/Female |
| Reg No. | 3117/24 | Receipt No | 19290 |
| Referred By | Bank of Baroda (BOB) - MEDI WHEEL() | Mode of Payment | CREDIT |
| Collection Type | CENTER | Collection DateTime | 29-Mar-2024 08:04 AM |

CHEST RADIOGRAPH (PA VIEW)

- Hilar shadows are within normal limits.
- Pulmonary vasculature appears normal.
- Cardiac appears normal in size.
- Both domeh of the diaphragm are smooth.
- Both costophrenic recesses are clear.
- Both lung fields appear normal.
- Visualized bones and soft tissue shadows appear normal.

IMPRESSION: NORMAL STUDY.

DR. CHIRAG K PATEL
RADIOLOGIST

Dr. Chirag K. Patel
MBBS-DMPD
Reg. No. G-23509
Revival Diagnostic
4th Floor, Aqua Corridor
Nr. Star Bazar, Hazira Main Road,
Adajan, Surat-395009.
Mo. 97266 726683

☎ 0261-2747788, 98259 47712

📍 4th Floor, Aqua Corridor, Hazira Road, Adajan Pal, Surat - 395009.

@ revivaldiagnostics.surat@gmail.com

🌐 www.revivaldiagnostics.com



REVIVAL DIAGNOSTICS

| | | | |
|-----------------|--|---------------------|-----------------------------|
| Name | MRS. PAREKH RANJANBEN DEVESHBHAI | Age/Gender | 55Yrs/Female |
| Reg No. | 3117/24 | Receipt No | 19290 |
| Referred By | Bank of Baroda (BOB) - MEDI WHEEL() | Mode of Payment | CREDIT |
| Collection Type | CENTER | Collection DateTime | 29-Mar-2024 08:04 AM |

USG OF ABDOMEN & PELVIS

LIVER:

Liver is normal in size, shape and echotexture.
No evidence of focal SOL or dilatation of IHBR seen.
Portahepatis appear normal.

GALLBLADDER:

Gallbladder is distended and appears normal.
No e/o calculus, mass lesion or changes of cholecystitis seen.

PANCREAS:

Pancreas appears normal in size, shape and echotexture.
No e/o focal lesion, mass or changes of pancreatitis seen.

SPLEEN:

Spleen appears normal in size, shape and echotexture.

PARAAORTIC REGION:

Aorta grossly appears normal. No e/o paraaortic lymphnodes seen.

KIDNEYS:

Both kidneys appear normal in size, shape, position and echotexture.
Cortex and collecting system of both kidneys appear normal.
No evidence of calculus or obstructive uropathy on either side.

URINARY BLADDER:

Bladder is distended and appears normal.
No calculus, mass lesion or changes of cystitis is seen.

UTERUS:

shows senile atrophic changes.

Both adnexal region appear normal.
No e/o adnexal mass lesion seen on either side.
No evidence of free fluid seen in pelvis.

COMMENTS: NORMAL USG ABDOMEN AND PELVIS.

Dr. Chirag K. Patel

MBBS-DMPD

Reg. No. G-23509

Revival Diagnostics

4th Floor, Aqua Corridor, Signature
Nr. Star Bazar, Hazira Main Road,
Adajan, Surat-395009.
Mo. 97266 726683

0261-2747788, 98259 47712

4th Floor, Aqua Corridor, Hazira Road, Adajan Pal, Surat - 395009.

revivaldiagnostics.surat@gmail.com

www.revivaldiagnostics.com



REVIVAL DIAGNOSTICS

| | | | |
|-----------------|--|---------------------|-----------------------------|
| Name | MRS. PAREKH RANJANBEN DEVESHBHAI | Age/Gender | 55Yrs/Female |
| Reg No. | 3117/24 | Receipt No | 19290 |
| Referred By | Bank of Baroda (BOB) - MEDI WHEEL() | Mode of Payment | CREDIT |
| Collection Type | CENTER | Collection DateTime | 29-Mar-2024 08:04 AM |

SONOGRAPHY OF BOTH BREASTS

TECHNIQUE- USG of both breast done by using 10 mHz high frequency.

FINDINGS -

RT BREAST:

On USG

Right breast shows normal parenchymal pattern.
No e/o skin thickening, nipple retraction, microcalcification.
No e/o focal SOL, architectural distortion.
No e/o lymphadenopathy is noted in right axillary region.

LT BREAST:

On USG

Left breast shows normal parenchymal pattern.
No e/o skin thickening, nipple retraction, microcalcification.
No e/o focal SOL, architectural distortion.
No e/o lymphadenopathy is noted in left axillary region.

COMMENT – Findings suggest ,

Right breast - Normal

Left breast - Normal

Dr. Chirag K. Patel
MBBS-DMPD
Reg/No. G-23509
Chirag K. Patel
Revival Diagnostic
4th Floor, Aqua Corridor
Nr. Star Bazar, Hazira Main Road,
Adajan, Surat-395009.
Mo. 97266 726683