



॥ ॐ गणेशाय नमः ॥

GANESH DIAGNOSTIC

DR. LOKESH GOYAL

MBBS (K GMC), MD (RADIOLOGY)

CONSULTANT INTERVENTIONAL RADIOLOGIST
FORMER SR. REGISTRAR - APOLLO HOSPITAL, NEW DELHI
LIFE MEMBER OF IRIA

Timings : 9:00 am to 9:00 pm, Sunday 9.00 am to 3.00 pm

☎ 8392957683, 6395228718

MR. PRASHANT PAWAR 36/M
DR. NITIN AGARWAL, DM

01-04-2024

REPORT

EXAMINATION PERFORMED: X-RAY CHEST

B/L lung fields are clear

Both of the CP angles are clear.

Both hila show a normal pattern .

Cardiac and mediastinal borders appear normal.

Visualized bony thorax and soft tissue of the chest wall appear normal.

IMPRESSION ---NO SIGNIFICANT ABNORMALITY IS SEEN

Not for medico-legal purpose

DR LOKESH GOYAL
MD
RADIOLOGIST

डिजिटल एक्स-रे, मल्टी स्लाइस
सी. टी. स्कैन सुविधा उपलब्ध है।



NOT VALID FOR
MEDICO LEGAL PURPOSE



Scanned with OKEN Scanner



GANESH DIAGNOSTIC

DR. LOKESH GOYAL
MBBS (KGMC), MD (RADIOLOGY)
CONSULTANT INTERVENTIONAL RADIOLOGIST
FORMER SR. REGISTRAR - APOLLO HOSPITAL, NEW DELHI
LIFE MEMBER OF IRIA

Timings : 9:00 am to 9:00 pm, Sunday 9.00 am to 3.00 pm ☎ 8392957683, 6395228718

MR. PRASHANT PAWAR 36/M
DR. NITIN AGARWAL, DM

01-04-2024

EXAMINATION PERFORMED ULTRASOUND WHOLE ABDOMEN

The Liver is normal in size and outline. It shows uniform echopattern. No obvious focal pathology is seen. The intra and extra hepatic biliary passages are not dilated.

The Gall Bladder is normal in size, with no evidence of calculi. Walls are thin. The CBD appears normal.

The Pancreas is normal in size and echogenicity. Its outlines are distinct. No obvious focal lesion, calcification or ductal dilatation is seen.

Spleen is mildly enlarged 114 mm in size.

Right Kidney is normal in position, outline and echogenicity. No evidence of calculi or calyceal dilatation is seen. Renal mobility is not impaired. Perinephric space is clear.

Left Kidney is normal in position, outline and echogenicity. No evidence of calculi or calyceal dilatation is seen. Renal mobility is not impaired. Perinephric space is clear.

No ascitis or pleural effusion. No retroperitoneal adenopathy.

The Urinary Bladder is partially filled. Walls are thin & smooth. There is no evidence of any obvious intraluminal or perivesical pathology.

The Prostate is normal in size and volume. Homogenous parenchyma. Median lobe is not projecting. The Seminal Vesicles are normally visualized.

Bowel loops are non-dilated; gas filled & show normal peristaltic activity.

IMPRESSION:- MILD SPLENOMEGALY

ADV—clinical correlation for bowel disorder

DR LOKESH GOYAL
MD
RADIODIAGNOSIS

Every imaging has its limitations. This is a professional opinion, not a final diagnosis. For further confirmation of diagnosis, clinical-pathological correlation & relevant next line investigation (TVS for gynecological disorders) (endoscopy / CT scan for bowel pathologies) are required. In case of clinical discrepancy with the report or confusion, reexamination / reevaluation are suggested. Esp. for the surgical cases 2nd opinion is must. Your positive as well as negative feedbacks are most welcome for better results

Counter sign

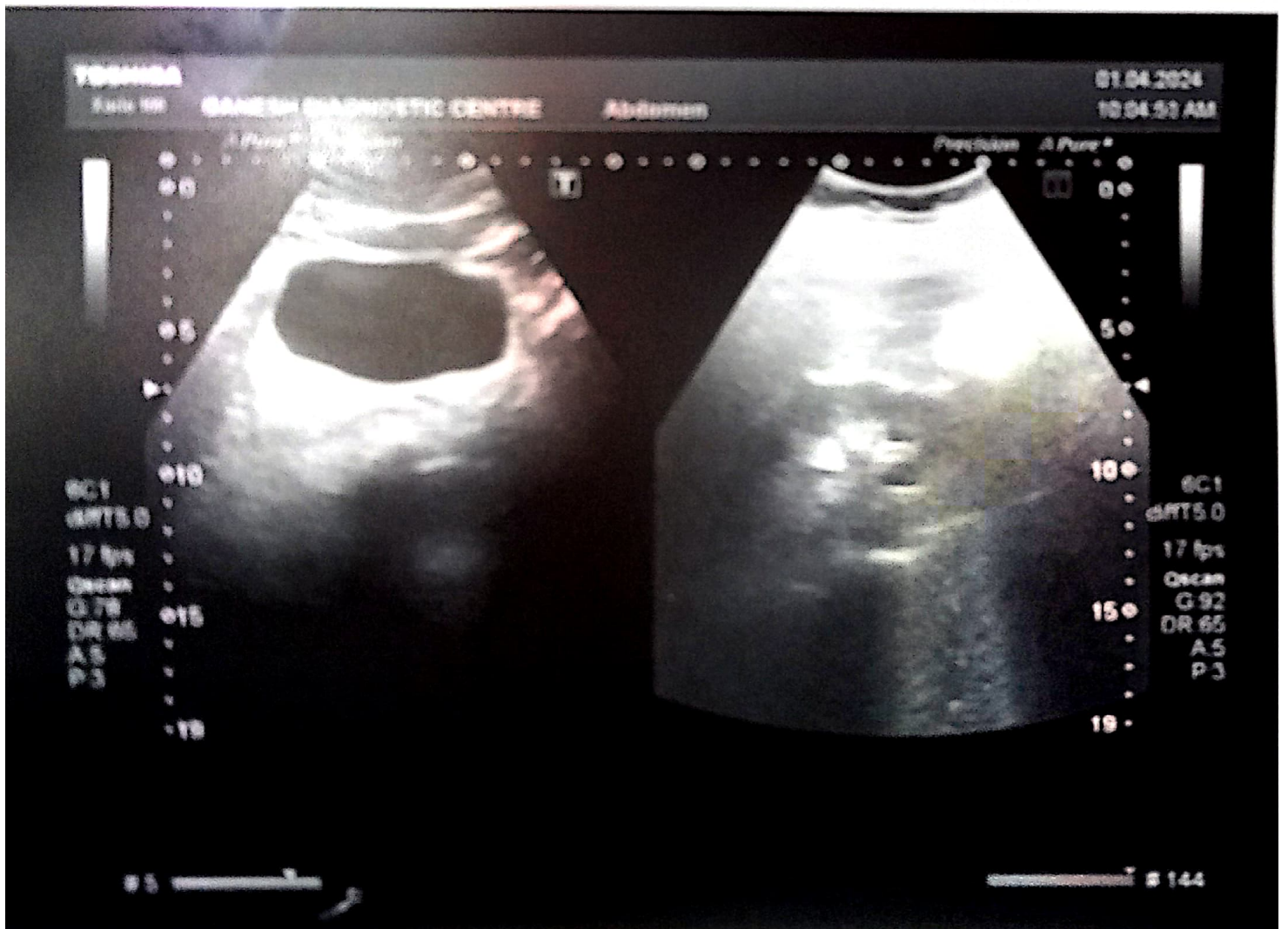
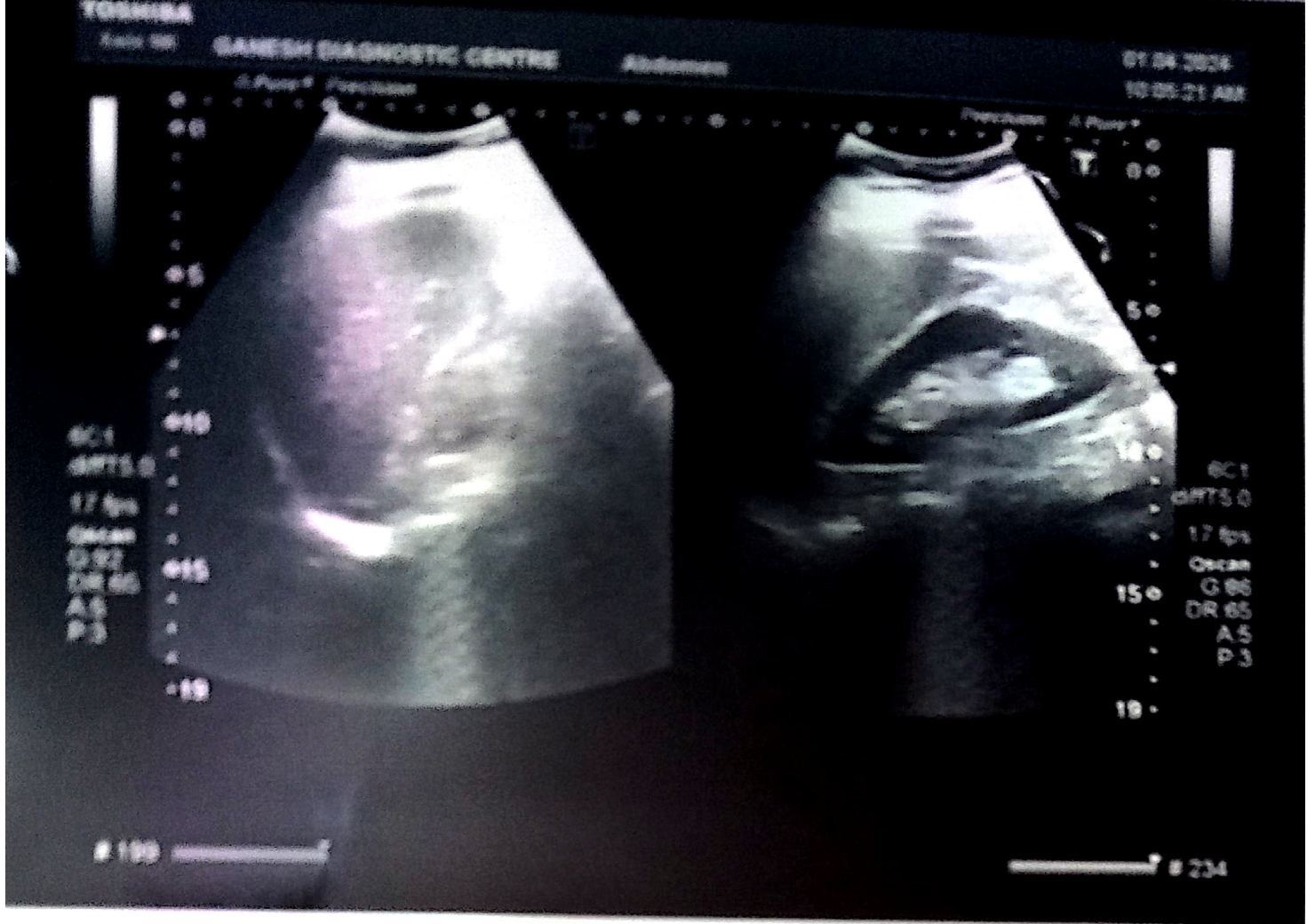

डिजिटल एक्स-रे, मल्टी स्टाईस
सी. टी. स्कैन सुविधा उपलब्ध है।

NOT VALID FOR
MEDICO LEGAL PURPOSE



Scanned with OKEN Scanner





GANESH DIAGNOSTIC

DR. LOKESH GOYAL

MBBS (K GMC), MD (RADIOLOGY)

CONSULTANT INTERVENTIONAL RADIOLOGIST
FORMER SR. REGISTRAR - APOLLO HOSPITAL, NEW DELHI
LIFE MEMBER OF IRIA

Timings : 9:00 am to 9:00 pm, Sunday 9.00 am to 3.00 pm ☎ 8392957683, 6395228718

MRS. RACHNA SINGH 34/F
DR. NITIN AGARWAL, DM

01-04-2024

EXAMINATION PERFORMED ULTRASOUND WHOLE ABDOMEN

The Liver is normal in size and outline. It shows uniform echopattern. No obvious focal pathology is seen. The intra and extra hepatic biliary passages are not dilated.

The Gall Bladder is normal in size. Wall is thin. There is e/o **single calculus 5 mm with distal acoustic shadowing seen within the lumen. No** wall edema or pericholecystic fluid is seen. Sonographic Murphy's sign is negative. CBD is clear.

The Pancreas is normal in size and echogenicity. Its outlines are distinct. No obvious focal lesion, calcification or ductal dilatation is seen.

Spleen is normal in size and echogenicity. There is no evidence of collaterals.

Right Kidney is normal in position, outline and echogenicity. No evidence of calculi or calyceal dilatation is seen. Renal mobility is not impaired. Perinephric space is clear.

Left Kidney is normal in position, outline and echogenicity. No evidence of calculi or calyceal dilatation is seen. Renal mobility is not impaired. Perinephric space is clear.

No ascitis or pleural effusion. No retroperitoneal adenopathy.

The Urinary Bladder is normal in size and outline. Walls are thin & smooth. There is no evidence of any obvious intraluminal or perivesical pathology.

The Uterus is anteverted and normal in size. The myometrial and endometrial echoes are normal.

B/L adnexa are clear. No adnexal mass or cyst seen.

IMPRESSION:- CHOLELITHIASIS (SINGLE CALCULUS 5 MM), CBD CLEAR

DR LOKESH GOYAL
MD
RADIOLOGIST

Every imaging has its limitations. This is a professional opinion, not a final diagnosis. For further confirmation of diagnosis, clinical-pathological correlation & relevant next line investigation (TVS for gynecological disorders) (endoscopy / CT scan for bowel pathologies) are required. In case of clinical discrepancy with the report or confusion, reexamination / reevaluation are suggested. Esp. for the surgical cases 2nd opinion is must. Your positive as well as negative feedbacks are most welcome for better results

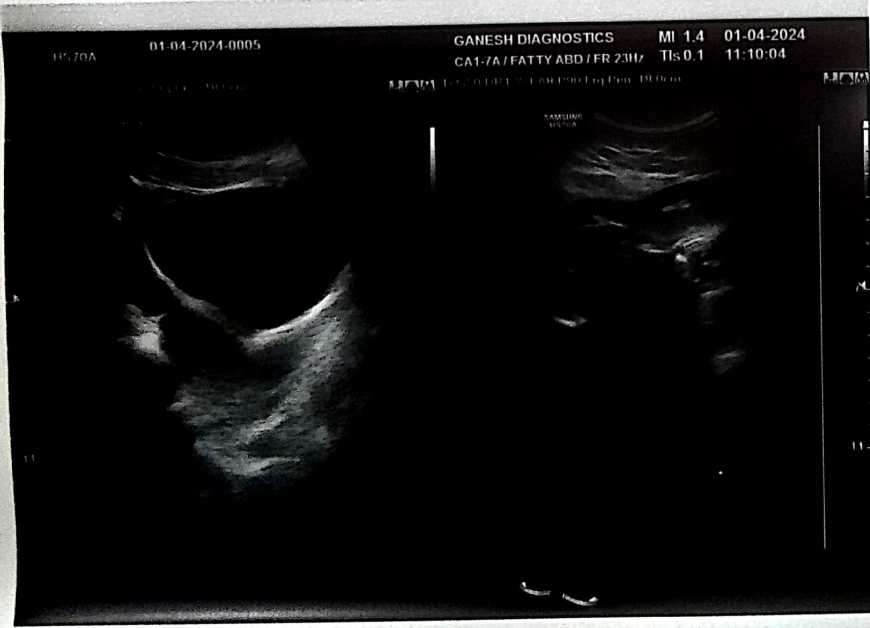
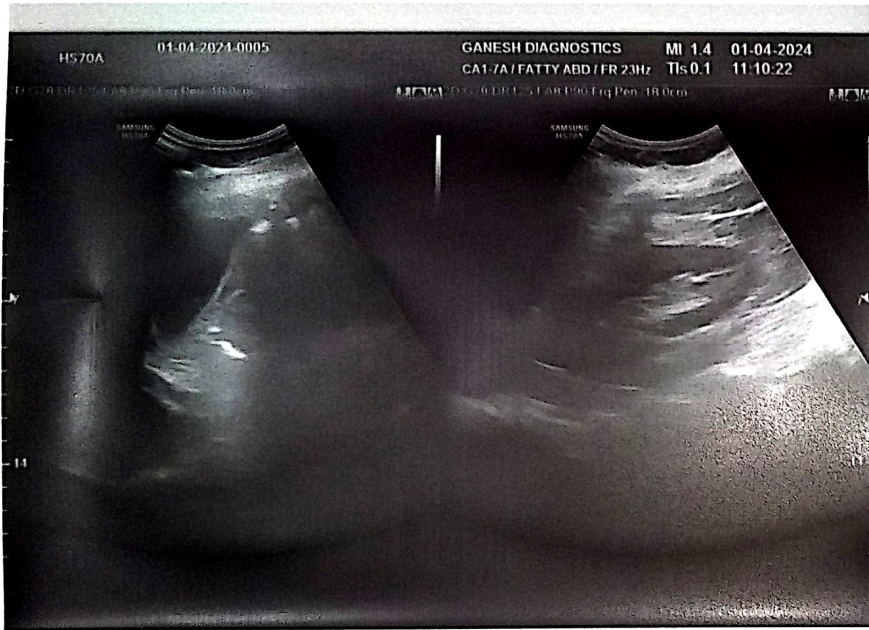
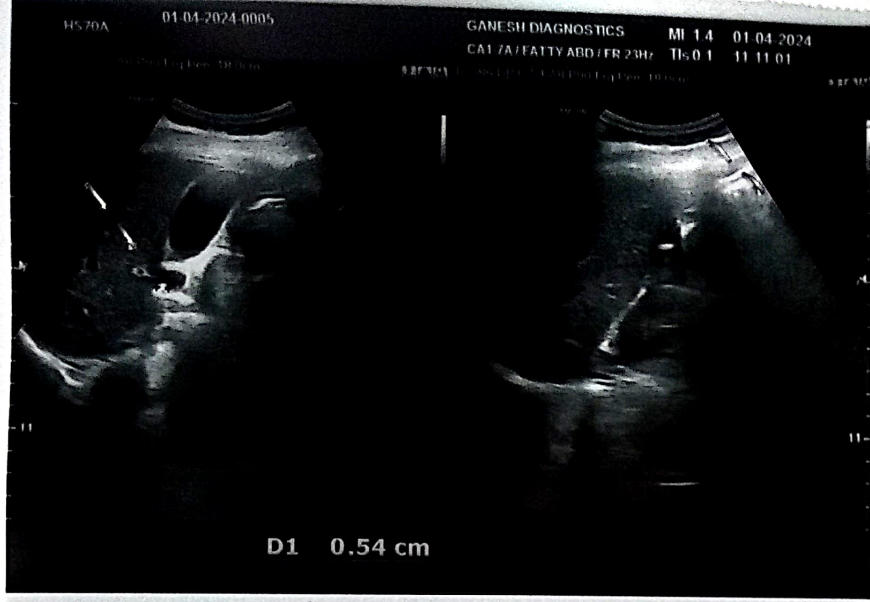
डिजिटल एक्स-रे, मल्टी स्लाईस
सी. टी. स्कैन सुविधा उपलब्ध है।



NOT VALID FOR
MEDICO LEGAL PURPOSE



Scanned with OKEN Scanner





॥ ॐ गणेशाय नमः ॥

GANESH DIAGNOSTIC

DR. LOKESH GOYAL

MBBS (KGMU), MD (RADIOLOGY)
CONSULTANT INTERVENTIONAL RADIOLOGIST
FORMER SR. REGISTRAR - APOLLO HOSPITAL, NEW DELHI
LIFE MEMBER OF IRIA

Timings : 9:00 am to 9:00 pm, Sunday 9.00 am to 3.00 pm

8392957683, 6395228718

01-04-2024

MRS. RACHNA SINGH 34/F
DR. NITIN AGARWAL, DM

REPORT

EXAMINATION PERFORMED: X-RAY CHEST

B/L lung fields are clear

Both of the CP angles are clear.

Both hila show a normal pattern .

Cardiac and mediastinal borders appear normal.

Visualized bony thorax and soft tissue of the chest wall appear normal.

IMPRESSION ---NO SIGNIFICANT ABNORMALITY IS SEEN

Not for medico-legal purpose

DR LOKESH GOYAL
MD
RADIOLOGIST

डिजिटल एक्स-रे, गल्टी रगार्ड्स
सी. टी. स्कैन सुविधा उपलब्ध है।



NOT VALID FOR
MEDICO LEGAL PURPOSE



Scanned with OKEN Scanner

BPL

10mm/mv 25mm/sec \approx 32HZ

I

II

BPL CARDIART 6108T

BPL

III

10mm/mv

Pat

Pat.ID ...

Richard Toshp
01/4/24

CARDIART

I

II

III

10mm/mv 25mm/sec \approx 32HZ

BPL CARDIART 6108T

BPL

10mm/mv 25mm/sec \approx 32HZ

Pat

Richard
01/04/24

CARDIART

Pat.ID



APPLE CARDIAC CARE
EKTA NAGER STADIUM ROAD BAREILLY

Report



4742 / MR. PRASHANT PAWAR / 36 Yrs / M / 169 Cms / 82 Kg Date: 01-Apr-2024 Refd By : NITIN AGARWAL (DM) Examined By: DR. NITIN AGARWAL

Stage	Time	Duration	Speed(mph)	Elevation	METS	Rate	% THR	BP	RPP	PVC	Comments
Standing	00:04	0:04	00.0	00.0	01.0	094	51 %	120/70	112	00	
Supine	00:31	0:27	00.0	00.0	01.0	087	47 %	120/70	104	00	
Standing	00:53	0:22	00.0	00.0	01.0	091	49 %	120/70	109	00	
HV	01:10	0:17	00.0	00.0	01.0	089	48 %	120/70	106	00	
ExStart	01:33	0:23	00.0	00.0	01.0	093	51 %	120/70	111	00	
BRUCE Stage 1	04:33	3:00	01.7	10.0	04.7	136	74 %	125/75	170	00	
BRUCE Stage 2	07:33	3:00	02.5	12.0	07.1	162	88 %	128/78	207	00	
PeakEx	09:18	1:45	03.4	14.0	08.9	181	98 %	130/80	235	00	
Recovery	09:48	0:30	00.0	00.0	04.1	160	87 %	130/80	208	00	
Recovery	10:18	1:00	00.0	00.0	01.1	147	80 %	130/80	191	00	
Recovery	11:18	2:00	00.0	00.0	01.0	133	72 %	130/80	172	00	
Recovery	12:12	2:55	00.0	00.0	01.0	127	69 %	128/78	162	00	

FINDINGS :

TMT-Negative for Ischaemia

Exercise Time : 07:45
 Max HR Attained : 181 bpm 98% of Target 184
 Max BP Attained : 130/80
 Max Workload Attained : 8.9 Fair response to induced stress

Test End Reasons : Test Complete, Heart Rate Achieved, Test Complete, Heart Rate Achieved, Test Complete, heart Rate Ach

REPORT This is Sample Report 3

Heart Rate 87.0 bpm
 Systolic BP 130.0 mmHg
 Diastolic BP 80.0 mmHg
 Maximum Depression 0.3
 Exercise Time 07:45 Mins.
 Ectopic Beats 0.0

A Venture of Apple Cardiac Care

A-3, Ekta Nagar, Stadium Road,
(Opp. Care Hospital),
Bareilly - 248 122 (U.P.) India
Tel. : 07599031977, 09458888448



APPLE
PATHOLOGY
TRUSTED RESULT

Reg. NO. : 17
NAME : **Mr. PRASHANT PAWAR**
REFERRED BY : Dr. Nitin Agarwal (D M)
SAMPLE : BLOOD

DATE : **01/04/2024**
AGE : 36 Yrs.
SEX : MALE

TEST NAME	RESULTS	UNITS	BIOLOGICAL REF. RANGE
-----------	---------	-------	-----------------------

HAEMATATOLOGY

COMPLETE BLOOD COUNT (CBC)

HAEMOGLOBIN 13.5 gm/dl 12.0-18.0

TOTAL LEUCOCYTE COUNT 8,200 /cumm 4,000-11,000

DIFFERENTIAL LEUCOCYTE COUNT(DLC)

Neutrophils 67 % 40-75

Lymphocytes 30 % 20-45

Eosinophils 03 % 01-08

TOTAL R.B.C. COUNT 4.21 million/cumm 3.5-6.5

P.C.V./ Haematocrit value 41.2 % 35-54

M C V 88.3 fL 76-96

M C H 31.2 pg 27.00-32.00

M C H C 32.5 g/dl 30.50-34.50

PLATELET COUNT 1.89 lacs/mm³ 1.50 - 4.50

E.S.R (WINTROBE METHOD)

-in First hour 14 mm 00 - 15

BLOOD GROUP

Blood Group A

Rh POSITIVE





Reg.NO. : 17
NAME : **Mr. PRASHANT PAWAR**
REFERRED BY : Dr.Nitin Agarwal (D M)
SAMPLE : BLOOD

DATE : **01/04/2024**
AGE : 36 Yrs.
SEX : MALE

<u>TEST NAME</u>	<u>RESULTS</u>	<u>UNITS</u>	<u>BIOLOGICAL REF. RANGE</u>
GLYCOSYLATED HAEMOGLOBIN(HBA1C)	6.0		

EXPECTED RESULTS :

Non diabetic patients	: 4.0% to 6.0%
Good Control	: 6.0% to 7.0%
Fair Control	: 7.0% to 8%
Poor Control	: Above 8%

***ADA: American Diabetes Association**

The glycosylated hemoglobin assay has been validated as a reliable indicator of mean blood glucose levels for a period of 8-12 week period prior to HBA1C determination.ADA recommends the testing twice a year in patients with stable blood glucose, and quarterly, if treatment changes, or if blood glucose levels are unstable.

METHOD : ADVANCED IMMUNO ASSAY.

BIOCHEMISTRY

BLOOD SUGAR F.	104	mg/dl	60-100
BLOOD UREA NITROGEN	15	mg/dL.	5 - 25
SERUM CREATININE	0.7	mg/dL.	0.5-1.4
URIC ACID	6.8	mg/dl	3.5-8.0

CLINICAL SIGNIFICANCE:

Analysis of synovial fluid plays a major role in the diagnosis of joint disease.



Reg.NO. : 17
 NAME : **Mr. PRASHANT PAWAR**
 REFERRED BY : Dr.Nitin Agarwal (D M)
 SAMPLE : BLOOD

DATE : **01/04/2024**
 AGE : 36 Yrs.
 SEX : MALE

<u>TEST NAME</u>	<u>RESULTS</u>	<u>UNITS</u>	<u>BIOLOGICAL REF. RANGE</u>
LIVER PROFILE			
SERUM BILIRUBIN			
TOTAL	0.8	mg/dL	0.3-1.2
DIRECT	0.5	mg/dL	0.2-0.6
INDIRECT	0.3	mg/dL	0.1-0.4
SERUM PROTEINS			
Total Proteins	7.4	Gm/dL	6.4 - 8.3
Albumin	4.1	Gm/dL	3.5 - 5.5
Globulin	3.3	Gm/dL	2.3 - 3.5
A : G Ratio	1.24		0.0-2.0
SGOT	50	IU/L	0-40
SGPT	48	IU/L	0-40
SERUM ALK.PHOSPHATASE	97	IU/L	00-115

NORMAL RANGE : BILIRUBIN TOTAL

Premature infants, 0 to 1 day: <8 mg/dL. Premature infants, 1 to 2 days: <12 mg/dL. Adults: 0.3-1 mg/dL.
 Premature infants, 3 to 5 days: <16 mg/dL. Neonates, 0 to 1 day: 1.4-8.7 mg/dL
 Neonates, 1 to 2 days: 3.4-11.5 mg/dL. Neonates, 3 to 5 days: 1.5-12 mg/dL Children 6 days to 18 years: 0.3-1.2 mg/dL

COMMENTS--

Total and direct bilirubin determination in serum is used for the diagnosis, differentiation and follow -up of jaundice. Elevation of SGPT is found in liver and kidney diseases such as infectious or toxic hepatitis, IM and cirrhosis. Organs rich in SGOT are heart, liver and skeletal muscles. When any of these organs are damaged, the serum SGOT level rises in proportion to the severity of damage. Elevation of Alkaline Phosphatase in serum or plasma is found in hepatitis, biliary obstructions, hyperparathyroidism, steatorrhea and bone diseases.

Reg.NO. : 17
NAME : **Mr. PRASHANT PAWAR**
REFERRED BY : Dr. Nitin Agarwal (D M)
SAMPLE : BLOOD

DATE : **01/04/2024**
AGE : 36 Yrs.
SEX : MALE

<u>TEST NAME</u>	<u>RESULTS</u>	<u>UNITS</u>	<u>BIOLOGICAL REF. RANGE</u>
LIPID PROFILE			
SERUM CHOLESTEROL	285	mg/dL.	130 - 200
SERUM TRIGLYCERIDE	385	mg/dl.	30 - 160
HDL CHOLESTEROL	43	mg/dL.	30-70
VLDL CHOLESTEROL	77	mg/dL.	15 - 40
LDL CHOLESTEROL	165	mg/dL.	00-130
CHOL/HDL CHOLESTEROL RATIO	6.63	mg/dl	0-4
LDL/HDL CHOLESTEROL RATIO	3.84	mg/dl	0-3

INTERPRETATION

TRIGLYCERIDE level > 250mg/dL is associated with an approximately 2-fold greater risk of coronary vascular disease. Elevation of triglycerides can be seen with obesity, medication, fast less than 12 hrs., alcohol intake, diabetes mellitus and pancreatitis. CHOLESTEROL, its fractions and triglycerides are the important plasma lipids indefining cardiovascular risk factors and in the management of cardiovascular disease. Highest acceptable and optimum values of cholesterol values of cholesterol vary with age. Values above 220 mgm/dl are associated with increased risk of CHD regardless of HDL & LDL values. HDL-CHOLESTEROL level <35 mg/dL is associated with an increased risk of coronary vascular disease even in the face of desirable levels of cholesterol and LDL - cholesterol.

LDL - CHOLESTEROL & TOTAL CHOLESTEROL levels can be strikingly altered by thyroid, renal and liver disease as well as hereditary factors. Based on total cholesterol, LDL- cholesterol, and total cholesterol/HDL - cholesterol ratio, patients may be divided into the three risk categories.

Gamma Glutamyl Transferase (GGT) 23 U/L 7-32

URINE EXAMINATION



DATE : 01/04/2024
 AGE : 36 Yrs.
 SEX : MALE

Reg.NO. : 17
 NAME : Mr. PRASHANT PAWAR
 REFERRED BY : Dr.Nitin Agarwal (D M)
 SAMPLE : BLOOD

TEST NAME	RESULTS	UNITS	BIOLOGICAL REF. RANGE
URINE EXAMINATION REPORT			
PHYSICAL EXAMINATION			
pH	6.0		
TRANSPARENCY		ml	
Volume	20		
Colour	Light Yellow		Nil
Appearance	Clear		
Sediments	Nil		1.015-1.025
Specific Gravity	1.020		
Reaction	Acidic		
BIOCHEMICAL EXAMINATION			
UROBILINOGEN	Nil		NIL
BILIRUBIN	Nil		NEGATIVE
URINE KETONE	Nil		NEGATIVE
Sugar	Nil		Nil
Albumin	Nil		Nil
Phosphates	Absent		Nil
MICROSCOPIC EXAMINATION			
Red Blood Cells	Nil	/H.P.F.	
Pus Cells	2-3	/H.P.F.	
Epithelial Cells	3-4	/H.P.F.	
Crystals	NIL		NIL
Casts	Nil	/H.P.F.	
DEPOSITS			
Bacteria	NIL		
Other	NIL		

A Venture of Apple Cardiac Care

A-3, Ekta Nagar, Stadium Road,
(Opp. Care Hospital),
Bareilly - 243 122 (U.P.) India
Tel. : 07599031977, 09458888448



APPLE
PATHOLOGY
TRUSTED RESULT

Reg.NO. : 18
NAME : **Mrs. RACHNA SINGH**
REFERRED BY : Dr.Nitin Agarwal (D M)
SAMPLE : BLOOD

DATE : **01/04/2024**
AGE : 34 Yrs.
SEX : FEMALE

<u>TEST NAME</u>	<u>RESULTS</u>	<u>UNITS</u>	<u>BIOLOGICAL REF. RANGE</u>
HAEMATOLOGY			
COMPLETE BLOOD COUNT (CBC)			
HAEMOGLOBIN	11.7	gm/dl	12.0-15.0
TOTAL LEUCOCYTE COUNT	5,100	/cumm	4,000-11,000
DIFFERENTIAL LEUCOCYTE COUNT(DLC)			
Neutrophils	75	%	40-75
Lymphocytes	23	%	20-45
Eosinophils	02	%	01-08
TOTAL R.B.C. COUNT	3.91	million/cumm	3.5-6.5
P.C.V./ Haematocrit value	41.2	%	35-54
M C V	88.5	fL	76-96
M C H	30.2	pg	27.00-32.00
M C H C	32.5	g/dl	30.50-34.50
PLATELET COUNT	1.95	lacs/mm ³	1.50 - 4.50
E.S.R (WINTROBE METHOD)			
-in First hour	13	mm	00- 20
BLOOD GROUP			
Blood Group	B		
Rh	POSITIVE		



Reg. NO. : 18
 NAME : Mrs. RACHNA SINGH
 REFERRED BY : Dr. Nitin Agarwal (D.M.)
 SAMPLE : BLOOD

DATE : 01/04/2024
 AGE : 34 Yrs.
 SEX : FEMALE

TEST NAME	RESULTS	UNITS	BIOLOGICAL REF. RANGE
GLYCOSYLATED HAEMOGLOBIN(HBA1C)	B		
ESTIMATED AVERAGE GLUCOSE	POSITIVE	mg/dl	70 - 140

EXPECTED RESULTS :

Non diabetic patients	: 4.0% to 6.0%
Good Control	: 6.0% to 7.0%
Fair Control	: 7.0% to 8%
Poor Control	: Above 8%

*ADA: American Diabetes Association

The glycosylated hemoglobin assay has been validated as a reliable indicator of mean blood glucose levels for a period of 8-12 week period prior to HBA1C determination. ADA recommends the testing twice a year in patients with stable blood glucose, and quarterly, if treatment changes, or if blood glucose levels are unstable.

METHOD : ADVANCED IMMUNO ASSAY.

BIOCHEMISTRY

BLOOD SUGAR F.	103	mg/dl	60-100
BLOOD UREA NITROGEN	15	mg/dL.	5 - 25
URIC ACID	5.8	mg/dl	3.0-6.0

CLINICAL SIGNIFICANCE:

Analysis of synovial fluid plays a major role in the diagnosis of joint disease.



Reg.NO. : 18
 NAME : Mrs. RACHNA SINGH
 REFERRED BY : Dr.Nitin Agarwal (D M)
 SAMPLE : BLOOD

DATE : 01/04/2024
 AGE : 34 Yrs.
 SEX : FEMALE

TEST NAME	RESULTS	UNITS	BIOLOGICAL REF. RANGE
LIVER PROFILE			
SERUM BILIRUBIN	0.9	mg/dL	0.3-1.2
TOTAL	0.5	mg/dL	0.2-0.6
DIRECT	0.4	mg/dL	0.1-0.4
INDIRECT			
SERUM PROTEINS			
Total Proteins	7.4	Gm/dL	6.4 - 8.3
Albumin	4.1	Gm/dL	3.5 - 5.5
Globulin	3.3	Gm/dL	2.3 - 3.5
A : G Ratio	1.24		0.0-2.0
SGOT	33	IU/L	0-40
SGPT	27	IU/L	0-40
SERUM ALK.PHOSPHATASE	63	IU/L	00-115

NORMAL RANGE : BILIRUBIN TOTAL
 Premature infants. 0 to 1 day: <8 mg/dL. Premature infants. 1 to 2 days: <12 mg/dL. Adults: 0.3-1 mg/dL.
 Premature infants. 3 to 5 days: <16 mg/dL. Neonates. 0 to 1 day: 1.4-8.7 mg/dL.
 Neonates. 1 to 2 days: 3.4-11.5 mg/dL. Neonates. 3 to 5 days: 1.5-12 mg/dL. Children 6 days to 18 years: 0.3-1.2 mg/dL.

COMMENTS:-
 Total and direct bilirubin determination in serum is used for the diagnosis, differentiation and follow-up of jaundice. Elevation of SGPT is found in liver and kidney diseases such as infectious or toxic hepatitis, IM and cirrhosis. Organs rich in SGOT are heart, liver and skeletal muscles. When any of these organs are damaged, the serum SGOT level rises in proportion to the severity of damage. Elevation of Alkaline Phosphatase in serum or plasma is found in hepatitis, biliary obstructions, hyperparathyroidism, steatorrhea and bone diseases.

ire of Apple Cardiac Care
 Kta Nagar, Stadium Road,
 Care Hospital),
 243 122 (U.P.) India
 : 07599031977, 09458888448



APPLE
PATHOLOGY
 TRUSTED RESULT

Reg.NO. : 18
 NAME : Mrs. RACHNA SINGH
 REFERRED BY : Dr.Nitin Agarwal (D M)
 SAMPLE : BLOOD

DATE : 01/04/2024
 AGE : 34 Yrs.
 SEX : FEMALE

TEST NAME	RESULTS	UNITS	BIOLOGICAL REF. RANGE
LIPID PROFILE			
SERUM CHOLESTEROL	290	mg/dL.	130 - 200
SERUM TRIGLYCERIDE	258	mg/dl.	30 - 160
HDL CHOLESTEROL	46	mg/dL.	30-70
VLDL CHOLESTEROL	51.6	mg/dL.	15 - 40
LDL CHOLESTEROL	192.40	mg/dL.	00-130
CHOL/HDL CHOLESTEROL RATIO	6.30	mg/dl	0-4
LDL/HDL CHOLESTEROL RATIO	4.18	mg/dl	0-3

INTERPRETATION

TRIGLYCERIDE level > 250mg/dL is associated with an approximately 2-fold greater risk of coronary vascular disease. Elevation of triglycerides can be seen with obesity, medication, fast less than 12 hrs., alcohol intake, diabetes melitus, and pancreatitis. CHOLESTEROL, its fractions and triglycerides are the important plasma lipids in defining cardiovascular risk factors and in the management of cardiovascular disease. Highest acceptable and optimum values of cholesterol values of cholesterol vary with age. Values above 220 mgm/dl are associated with increased risk of CHD regardless of HDL & LDL values. HDL-CHOLESTEROL level <35 mg/dL is associated with an increased risk of coronary vascular disease even in the face of desirable levels of cholesterol and LDL - cholesterol. LDL - CHOLESTEROL & TOTAL CHOLESTEROL levels can be strikingly altered by thyroid, renal and liver disease as well as hereditary factors. Based on total cholesterol, LDL- cholesterol, and total cholesterol/HDL - cholesterol ratio, patients may be divided into the three risk categories.

Gamma Glutamyl Transferase (GGT) 33 U/L 11-50

URINE EXAMINATION





Reg.NO. : 18
 NAME : Mrs. RACHNA SINGH
 REFERRED BY : Dr.Nitin Agarwal (D M)
 SAMPLE : BLOOD

DATE : 01/04/2024
 AGE : 34 Yrs.
 SEX : FEMALE

TEST NAME	RESULTS	UNITS	BIOLOGICAL REF. RANGE
URINE EXAMINATION REPORT			
PHYSICAL EXAMINATION			
pH	6.0		
TRANSPARENCY			
Volume	20	ml	
Colour	Light Yellow		
Appearance	Clear		Nil
Sediments	Nil		
Specific Gravity	1.020		1.015-1.025
Reaction	Acidic		
BIOCHEMICAL EXAMINATION			
UROBILINOGEN	Nil		NIL
BILIRUBIN	Nil		NEGATIVE
URINE KETONE	Nil		NEGATIVE
Sugar	Nil		Nil
Albumin	Nil		Nil
Phosphates	Absent		Nil
MICROSCOPIC EXAMINATION			
Red Blood Cells	Nil	/H.P.F.	
Pus Cells	1-2	/H.P.F.	
Epithelial Cells	2-3	/H.P.F.	
Crystals	NIL		NIL
Casts	Nil	/H.P.F.	
DEPOSITS	NIL		
Bacteria	NIL		
Other	NIL		

ure of Apple Cardiac Care
kta Nagar, Stadium Road,
Care Hospital),
illy - 243 122 (U.P.) India
: 07599031977, 09458888448



APPLE
PATHOLOGY
TRUSTED RESULT

Reg.NO. : 18
NAME : Mrs. RACHNA SINGH
REFERRED BY : Dr.Nitin Agarwal (D M)
SAMPLE : BLOOD

DATE : 01/04/2024
AGE : 34 Yrs.
SEX : FEMALE

TEST NAME

RESULTS

UNITS **BIOLOGICAL REF. RANGE**

--{End of Report}--

Agarwal
Dr. Shweta Agarwal, M.D.
(Pathologist)





NAME	Mrs. RACHNA SINGH	AGE/SEX	36 Y/F
Reff. By	Dr. NITIN AGARWAL (DM)	DATE	01/04/2024

ECHOCARDIOGRAPHY AND COLOUR DOPPLER STUDY

<u>MEASUREMENTS</u>	<u>VALUE</u>	<u>NORMAL DIMENSIONS</u>
LVID (d)	4.5 cm	(3.7 –5.6 cm)
LVID (s)	2.5 cm	(2.2 –3.9 cm)
RVID (d)	2.4 cm	(0.7 –2.5 cm)
IVS (ed)	1.0 cm	(0.6 –1.1 cm)
LVPW (ed)	1.0 cm	(0.6 –1.1 cm)
AO	2.2 cm	(2.2 –3.7 cm)
LA	3.0 cm	(1.9 –4.0 cm)
<u>LV FUNCTION</u>		
EF	60 %	(54 –76 %)
FS	30 %	(25 –44 %)

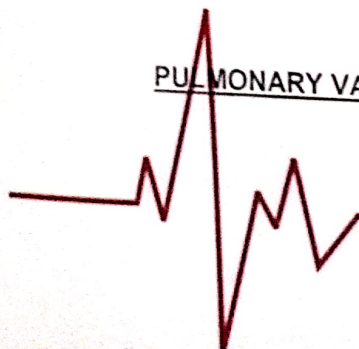
LEFT VENTRICLE : No regional wall motion abnormality
 No concentric left Ventricle Hypertrophy

MITRAL VALVE : Thin, PML moves posteriorly during Diastole
 No SAM, No Subvalvular pathology seen.
 No mitral valve prolapse calcification .

TRICUSPID VALVE : Thin, opening wells. No calcification, No doming .
 No Prolapse.
 Tricuspid inflow velocity= 0.7 m/sec

AORTIC VALVE : Thin, tricuspid, opening well, central closer,
 no flutter.
 No calcification
 Aortic velocity = 1.3 m/sec

PULMONARY VALVE : Thin, opening well, Pulmonary artery is normal
 EF slope is normal.
 Pulmonary Velocity = 0.9 m /sec



FACILITIES : ECG | COLOUR DOPPLER | ECHO CARDIOGRAPHY
 TMT | HOLTER MONITORING | PATHOLOGY



ON DOPPLER INTERROGATION THERE WAS :

- No mitral regurgitation
- No tricuspid regurgitation
- No aortic regurgitation
- No pulmonary regurgitation

MITRAL FLOW

E= 0.8 m/sec

A= 0.6 m/sec

ON COLOUR FLOW:

- No mitral regurgitation
- No tricuspid regurgitation
- No aortic regurgitation
- No pulmonary regurgitation

COMMENTS:

- No LA /LV clot
- No pericardial effusion
- No intracardiac mass
- IAS/IVS Intact
- Inferior vena cava – normal in size with normal respiratory variation

FINAL IMPRESSION

- NO REGIONAL WALL MOTION ABNORMALITY
- NORMAL LV DIASTOLIC FUNCTION
- NORMAL LV SYSTOLIC FUNCTION (LVEF~60%)
- NORMAL CARDIAC CHAMBER DIMENSIONS
- NORMAL VALVULAR COLOUR FLOW PATTERN



DR.NITIN AGARWAL
DM (Cardiology)
Consultant Cardiologist

This opinion is to be correlated with the clinically findings and if required, please re-evaluate / reconfirm with further investigation.