

The Apollo Clinic - Manikonda
PHYSICAL EXAMINATION FORM

DATE 23/3/20

UHID CMAN. 97125

Name 23/3/20

Age 43

Mr. Venkatasatya

Height 163 Cms

Weight 70.4 Kgs

Chest Measurement (In) Cm (Out) Cm

Waist Cm Hip

Pulse 121 Bt. Min. BMI 26

BP 120/80 mm/Hg SPO2 99

MR VENKATA SATYA SUR
ID: CMAN 97125

23.03.2024 13:28:19

Male

APOLLO CLINIC
MANIKONDA
HYDERABAD

Location:
Order Number:
Visit:

Room:

95 bpm

--/-- mmHg

43 years

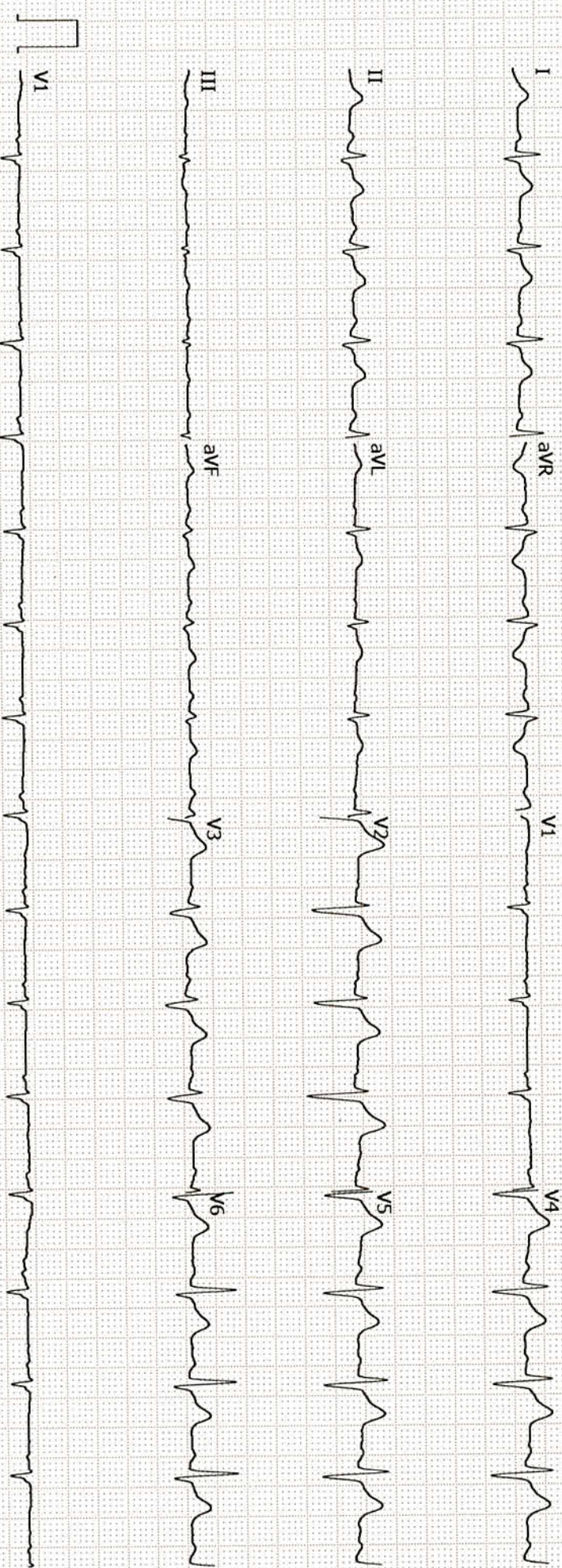
Technician:
Ordering Ph:
Referring Ph:
Attending Ph:

Indication:
Medication 1:
Medication 2:
Medication 3:

QRS : 86 ms
QT / QTcBaz : 356 / 447 ms
PR : 136 ms
P : 100 ms
RR / PP : 628 / 631 ms
P / QRS / T : 51 / 24 / 30 degrees

Normal sinus rhythm
Normal ECG

AMH L
[Signature]



GE MAC2000 1.1 12SL™ V241 25 mm/s 10 mm/mV ADS 0.56-20 Hz 50 Hz 4x2.5x3_25_R1 1/1

Unconfirmed

Name <u>Mr. Venkatasatya</u>	Date <u>25/3/24</u>
Age <u>43</u>	UHID No. <u>97125</u>
<input checked="" type="checkbox"/> Male <input type="checkbox"/> Female	Ref. Physician
Ref. Diagnosis	

Echocardiogram Report

Echogenicity Poor Adequate Good Ht. _____ Wt. _____ BSA _____

DIMENSIONS	NORMAL	DIMENSIONS	NORMAL
Ao (ed) <u>2.12</u> cm	(1.5cm / m2)	IVS (Ed) <u>1.01</u> cm	(0.6 - 1.2 cm)
LA (es) <u>2.3</u> cm	(1.5cm / m2)	LVPW (Ed) <u>0.9</u> cm	(0.6 - 1.1 cm)
RVID (ed) _____ cm	(0.9 cm / m2)	EF <u>62</u>	(0.62 - 0.85)
LVID (ed) <u>3.9</u> cm	(2.6 - 3.4 cm / m2)	% FD <u>21</u>	(2.8% - 42%)
LVID (es) <u>1.8</u>			

MORPHOLOGICAL DATA

Mitral Valve	AML _____	Interatrial septum _____
	PML _____	Interventricular septum <u>Intact</u>
Aortic Valve	_____	Pulmonary artery _____
Tricuspid valve	_____	Aorta _____
Pulmonary valve	_____	Right atrium _____
Right ventricle	_____	Left atrium _____


CERTIFICATE OF MEDICAL FITNESS

This is to certify that I have conducted the clinical examination

of Mr Venkata Satya S on 26/3/2024

After reviewing the medical history and on clinical examination it has been found that he/she is

	Tick
<ul style="list-style-type: none"> • Medically Fit 	<input checked="" type="checkbox"/>
<ul style="list-style-type: none"> • Fit with restrictions/recommendations <p>Though following restrictions have been revealed, in my opinion, these are not impediments to the job.</p> <p>1.....</p> <p>2.....</p> <p>3.....</p> <p>However the employee should follow the advice/medication that has been communicated to him/her.</p> <p>Review after _____</p>	
<ul style="list-style-type: none"> • Currently Unfit. Review after _____ recommended 	
<ul style="list-style-type: none"> • Unfit 	


 Dr. _____
 Medical Officer
 The Apollo Clinic, (Location)

This certificate is not meant for medico-legal purposes

Patient Name	: Mr. YEDURI VEERA VENKATA SATYA SUR	Age/Gender	: 43 Y/M
UHID/MR No.	: CMAN.0000097125	OP Visit No	: CMANOPV198706
Sample Collected on	:	Reported on	: 26-03-2024 12:50
LRN#	: RAD2278801	Specimen	:
Ref Doctor	: SELF		
Emp/Auth/TPA ID	: 408075		

DEPARTMENT OF RADIOLOGY

X-RAY CHEST PA

Cardiac is normal.

Both lung fields and hila are normal .

No obvious active pleuro-parenchymal lesion seen .

Both costophrenic and cardiophrenic angles are clear .

Both diaphragms are normal in position and contour .

Thoracic wall and soft tissues appear normal.

CONCLUSION :

No obvious abnormality seen



Dr. MD RAHEEMUDDIN QURESHI
Radiology

Patient Name	: Mr. YEDURI VEERA VENKATA SATYA SUR	Age/Gender	: 43 Y/M
UHID/MR No.	: CMAN.0000097125	OP Visit No	: CMANOPV198706
Sample Collected on	:	Reported on	: 25-03-2024 11:23
LRN#	: RAD2278801	Specimen	:
Ref Doctor	: SELF		
Emp/Auth/TPA ID	: 408075		

DEPARTMENT OF RADIOLOGY

ULTRASOUND - WHOLE ABDOMEN

Liver appears normal in size and **Increased echotexture**. No focal lesion is seen. PV and CBD normal. No dilatation of the intrahepatic biliary radicals.

Gall bladder is well distended. No evidence of calculus. Wall thickness appears normal. No evidence of periGB collection. No evidence of focal lesion is seen.

Spleen appears normal. No focal lesion seen. Splenic vein appears normal.

Pancreas appears normal in echopattern. No focal/mass lesion/calcification. No evidence of peripancreatic free fluid or collection. Pancreatic duct appears normal.

Both the kidneys appear normal in size, shape and echopattern. Cortical thickness and CM differentiation are maintained. No calculus / hydronephrosis seen on either side.

Urinary Bladder is well distended and appears normal. No evidence of any wall thickening or abnormality. No evidence of any intrinsic or extrinsic bladder abnormality detected.

Prostate is normal in size and echo texture. Volume measuring 19 cc.

No evidence of necrosis/calcification seen.

IMPRESSION:-

- **GRADE - I to II FATTY LIVER.**

Suggest – clinical correlation.

(The sonography findings should always be considered in correlation with the clinical and other investigation finding where applicable.) It is only a professional opinion, Not valid for medico legal purpose.

Dr. MOHD ABDUL RAWOOF

Dr. MOHD ABDUL RAWOOF
MBBS, DNB(RADIO DIAGNOSIS)

Radiology

Home

Reports

Appointments

Corporate Health Checks

Radiology

Doctor Consultation

OPD-IP Consultation

Roster Configuration

Patient First Name
MR. YEDURI VEERA

Patient Last Name
VENKATA SATYA SUR

Patient E-mail ID
Ywssuresh@yahoo.co.in

Date of Birth
01-02-1981

Client
ARCOFEMI HEALTHCARE LIMITED

Agreement Name
(1) ARCOFEMI MEDIWHEEL MALE AHC CREDIT PAN INDIA OP AGREEMENT

Package Name
(1) ARCOFEMI - MEDIWHEEL - FULL BODY ANNUAL PLUS ABOVE 50Y MALE - 2D ECHO - PAN INDIA - FY2324

Visit Type
in-clinic

Visit Status
Report Status

Order Confirmed

City

Clinic
MANIKONDA

Order Date
22-03-2024

Appointment Date
23-03-2024

Slot Time
08:00-08:15

Ref_Appointment ID
bobe17704

Visit ID

MER URL



बैंक ऑफ बड़ौदा
Bank of Baroda

नाम
Name


Y.V.V.S.SURESH

संख्या क्र. /
E.C.No.

62885

प्रमाणित अधिकारी
Issued Authority




धरम के हस्ताक्षर
Signature Of Holder